



Contents lists available at ScienceDirect

International Journal of Surgery Case Reports

journal homepage: www.casereports.com

A unique complication of radiofrequency therapy to the tongue base

Chrysostomos Tornari^{a,*}, Gentle Wong^a, Asit Arora^a, Bhik Kotecha^a^a Royal National Throat, Nose and Ear Hospital, UK

ARTICLE INFO

Article history:

Received 23 September 2014
 Received in revised form 7 December 2014
 Accepted 27 December 2014
 Available online 8 January 2015

Keywords:

Snoring
 Radiofrequency
 Ablation
 Tongue
 Thyroglossal
 Cyst

ABSTRACT

INTRODUCTION: Radiofrequency ablation treatment of the tongue base can be used either alone or as part of a multilevel approach in the treatment of snoring. This involves the generation of thermal energy around the circumvallate papillae of the tongue. Potential complications include ulceration, dysphagia, haematoma and abscess formation.

PRESENTATION OF CASE: We present the case of a 50-year-old patient who developed an anterior neck swelling following a second application of radiofrequency ablation therapy to the tongue base for snoring. This was secondary to an infection of a previously undiagnosed thyroglossal cyst. The patient made a full recovery following intravenous antibiotic therapy and ultrasound-guided needle aspiration.

DISCUSSION: Thyroglossal tract remnants are thought to be present in seven percent of the adult population. An infection in a thyroglossal tract cyst has not previously been reported following radiofrequency ablation of the tongue base. Given the relatively high complication rate of tongue base radiofrequency ablation in some series, this complication may be under-recognised.

CONCLUSION: An infected thyroglossal tract cyst should be suspected in patients with anterior neck swellings following radiofrequency ablation therapy to the tongue base. We advise caution when performing this procedure on patients with known thyroglossal tract remnants though there is insufficient evidence to suggest that this procedure is contraindicated.

© 2015 The Authors. Published by Elsevier Ltd. on behalf of Surgical Associates Ltd. This is an open access article under the CC BY-NC-SA license (<http://creativecommons.org/licenses/by-nc-sa/4.0/>).

1. Introduction

Marked advances have been made in surgery for snoring and obstructive sleep apnoea, particularly in radiofrequency ablation. This technique utilizes thermal energy from high frequency alternating current to cut and coagulate tissue. It can be used alone, in conjunction with other management strategies such as laser assisted uvulopalatoplasty and mandibular advancement devices, or to assist continuous positive airway pressure (CPAP) usage [1]. Snoring surgery typically requires a multilevel approach to the upper airway and radiofrequency treatment is well suited to this, allowing concurrent applications to the soft palate, base of tongue, and resection of redundant palatopharyngeus mucosa [1,2].

The thyroglossal duct begins at the embryological origin of the thyroid gland, the foramen caecum. This is located at the tongue base between the median lingual swelling (anteriorly) and the copula (posteriorly). The thyroid gland descends through the anterior neck to its final location and its duct usually atrophies before birth. A patent thyroglossal tract can cause a thyroglossal cyst which usu-

ally presents in childhood but can often present after the age of 50 [3].

Radiofrequency treatment of the tongue base is applied in the central posterior third of the tongue. This can cause ulceration, dysphagia, and – more rarely – haematoma or abscess formation which can cause airway compromise [4]. We present an unusual case of radiofrequency ablation therapy to the tongue base causing an infected thyroglossal cyst in a previously undiagnosed and asymptomatic patient. This is, to our knowledge, the first reported case of its kind.

2. Presentation of case

A 50-year-old female patient was referred to the ENT clinic due to snoring. A previous septoplasty for nasal obstruction had improved the nasal airway and the patient had allergic rhinitis without polyposis that was treated by a regular nasal steroid spray. There was no history of a neck lump.

A sleep study showed an apnoea-hypopnoea index of 2.0 and a flow-limitation index of 4.3 with a BMI of 33.3 and an Epworth Sleepiness Score of two. Subsequent sleep nasendoscopy demonstrated the level of obstruction to be at the tongue base with no epiglottic involvement, i.e. grade five [5].

Conservative therapy was not possible as the patient did not have adequate dentition to support a mandibular advancement splint. Therefore, tongue base radiofrequency ablation was com-

Abbreviations: ENT, ear, nose and throat; CT, computed tomography.

* Corresponding author at: Royal National Throat, Nose and Ear Hospital, 330 Grays Inn Road, London, WC1X 8DA, UK. Tel.: +44 2034567890.

E-mail address: t.tornari@gmail.com (C. Tornari).

<http://dx.doi.org/10.1016/j.ijscr.2014.12.039>

2210-2612/© 2015 The Authors. Published by Elsevier Ltd. on behalf of Surgical Associates Ltd. This is an open access article under the CC BY-NC-SA license (<http://creativecommons.org/licenses/by-nc-sa/4.0/>).

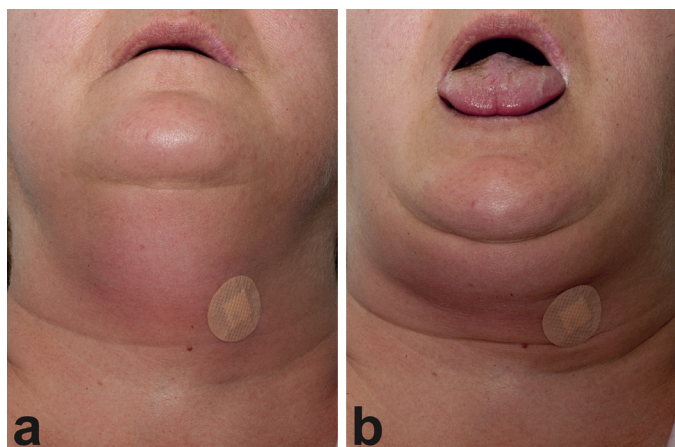

Fig. 1. Clinical photographs of the infected thyroglossal cyst on postoperative day 22. Anterior views are shown with neutral tongue position (a) and tongue protrusion (b). The dressing indicates the location of ultrasound-guided needle aspiration.

menced. Six applications of six watts were delivered to the tongue base at the typical location during the first treatment [1]. The patient subsequently reported an approximately 25% improvement in her symptoms.

Two months later, a second-stage procedure was performed with no immediate complications and the patient was discharged from hospital on the evening of surgery. Two days post-operatively, she developed a right submandibular swelling that spread to the right side of the face prompting attendance at a local accident and emergency department. Though there was mild dysphagia, there was no airway compromise and the patient was discharged with oral Co-Amoxiclav for a presumed post-operative infection. A GP appointment was arranged following completion of the seven day course of antibiotics as the neck swelling persisted, though the facial swelling improved. A second course of oral antibiotics was prescribed and, two weeks post-operatively, the patient was discussed with the on call ENT team who arranged urgent review.

ENT review on the 16th postoperative day showed continuing submandibular swelling, redness and discomfort with no dysphagia or difficulty in breathing (Fig. 1). Oropharyngeal examination and fiberoptic nasolaryngoscopy did not demonstrate any tongue base abnormality (Fig. 2). Subsequent review, on the 20th postoperative day, revealed no improvement and the patient was admitted for further investigation.

A CT scan of the neck demonstrated an infected thyroglossal cyst without any tongue base or deep neck collections (Fig. 3) and a subsequent ultrasound-guided needle aspiration reduced the size

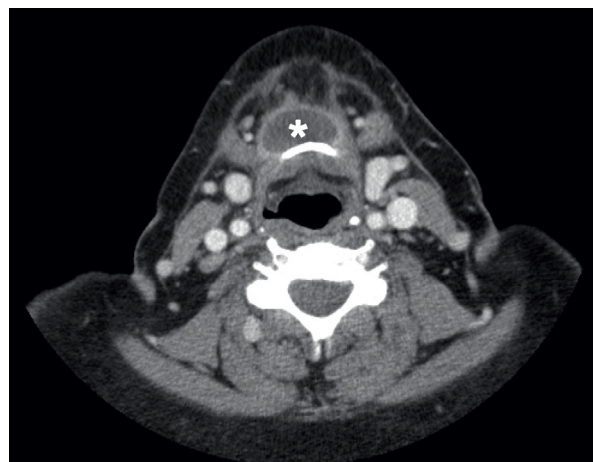

Fig. 3. CT scan of the neck on postoperative day 21. An axial, post-contrast CT scan of the neck at the level of C3. The asterisk denotes the position of a 2.7 cm simple cyst with a thin enhancing wall consistent with an infected thyroglossal cyst. Chrysostomos Tornari and Bhik T Kotecha

of the cyst. This improved the patient's symptoms sufficiently to allow discharge four days after admission. The patient remains under review and has not suffered any recurrence.

3. Discussion

In this case, the patient suffered from simple snoring due to tongue base collapse. Radiofrequency treatment of the tongue base was performed according to our standard technique (indicated in Fig. 2) [1]. Compared to the turbinates and palate – two other sites that are commonly treated with radiofrequency therapy – the tongue base carries the highest rate of moderate and severe complications (6.2%) i.e. serious infection requiring drainage or other significant airway compromise [4]. However, there is a considerable variation, ranging from 0% to 32%, in the reported incidence of mild and moderate complications. The reason for this variability is not known [4].

There are reports of post-operative infections that required drainage following tongue base radiofrequency ablation [4]. However, there is no report of this procedure causing a thyroglossal cyst infection. Thyroglossal cysts are the most common congenital neck cysts and the most common cause of midline neck swellings in the paediatric population though, in terms of age, there is a bimodal distribution for their identification with similar incidence in children and adults [6,7]. They can arise anywhere along a thyroglossal tract remnant and it is thought that such remnants are present in seven

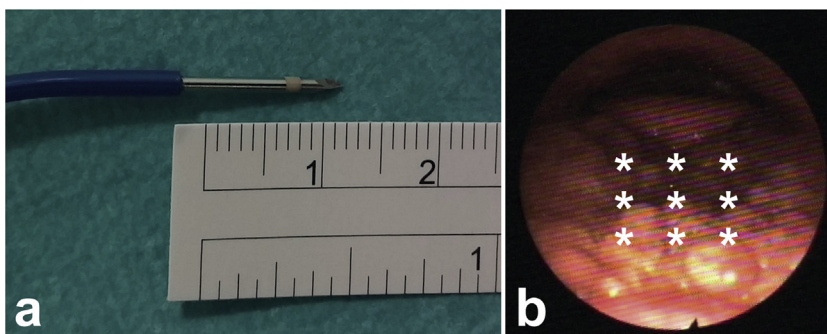


Fig. 2. Radiofrequency ablation of the tongue base. The radiofrequency ablation probe is shown (a) along with a fiberoptic nasendoscopic photograph of the tongue base on postoperative day 23. Asterisks indicate the location of radiofrequency applications according to the operative note.

percent of the adult population. This is significantly lower than the 41.3% prevalence of thyroglossal tract remnants and ectopic thyroid tissue found in 58 serially studied infant and child autopsy specimens [3,8,9]. It has recently been suggested that thyroglossal duct cysts may be associated with obstructive sleep apnoea though a causal relationship has not been established [10].

Our hypothesis is that a temporary connection between the oropharynx and a previously undiagnosed patent thyroglossal tract was created by the radiofrequency treatment probe used in this procedure and acted as an entry point for infection (Fig. 2a). Alternatively, the heat transmission, interstitial oedema and localised haemorrhage induced by radiofrequency treatment could have dissipated along the thyroglossal tract and precipitated subsequent infection [11].

Though our patient experienced mild dysphagia, the location of the collection was primarily in the submental region (i.e. location 2) and, fortunately, not in the intralingual location as cysts in this region can cause stridor and respiratory obstruction [12]. Though the current complication has not been reported previously, it is conceivable that previous post-procedure collections have been treated without the underlying thyroglossal cyst being removed. This is concerning as definitive surgical management of the underlying problem (Sistrunk's procedure) may not be performed in a timely manner and the patient may, therefore, suffer an increased risk of recurrence [13]. We were concerned by the relatively long duration of antibiotic therapy and size of the cyst. These features should have prompted an early discussion with the ENT team which could have shortened this patient's complication. We have revised our patient information leaflets in order to increase awareness of this potential complication so that it may be managed more effectively in the future.

4. Conclusion

Thyroglossal cyst infection is a potential complication of radiofrequency ablation therapy to the tongue base. This should be suspected in patients with postoperative neck swellings and prompt early ENT review. Appropriate antibiotics should be started as soon as such swelling is noted, and ultrasound-guided needle aspiration may be required as it is preferable to defer definitive surgery until acute infection has settled.

Caution should be exercised when operating on patients that have known thyroglossal tract remnants as the radiofrequency probe used during tongue base therapy can introduce infection that could, theoretically, result in airway compromise. This is especially true in patients presenting with known midline neck lumps. However, the anatomy of the patent thyroglossal tract is highly variable and the incidence of post-treatment infection in these patients is likely to be very low. Therefore, there is insufficient evidence to suggest that radiofrequency treatment of the tongue base in the presence of a patent thyroglossal tract is contraindicated.

Conflict of interest

The authors would like to declare no conflicts of interest.

Funding

Not applicable.

Ethical approval

Not applicable.

Consent

Written informed consent was obtained from the patient for publication of this case report and accompanying images. A copy of the written consent is available for review by the Editor-in-Chief of this journal on request.

Author contribution

CT, GW, AA and BK were involved in the concept and design of the case report. CT and GW performed data collection. CT, GW, AA and BK analysed and interpreted the data as well as writing or providing significant amendments to the manuscript. There are no additional contributors. The Medical Illustration Department of UCLH NHS Foundation Trust is acknowledged in the manuscript for their assistance in clinical photography.

Guarantor

Chrysostomos Tornari and Bhik T Kotecha.

Key learning points

- Radiofrequency ablation therapy of the tongue base may introduce infection into an underlying thyroglossal cyst.
- Such infection can be managed with intravenous antibiotic therapy and ultrasound-guided needle aspiration.
- Caution should be exercised when applying radiofrequency ablation therapy to patients with known thyroglossal cysts.

Acknowledgements

We would like to thank the Medical Illustration Department of the Royal National Throat, Nose and Ear Hospital (University College London Hospitals NHS Foundation Trust, UK) for their assistance in clinical photography.

References

- [1] J.S. Virk, R. Nouraei, B. Kotecha, Multilevel radiofrequency ablation to the soft palate and tongue base: tips and pitfalls, *Eur. Arch. Otorhinolaryngol* 271 (2014) 1809–1813.
- [2] B.T. Kotecha, A.C. Hall, Role of surgery in adult obstructive sleep apnoea, *Sleep Med. Rev.* 18 (2014) 405–413.
- [3] J. Chou, A. Walters, R. Hage, A. Zurada, M. Michalak, R.S. Tubbs, et al., Thyroglossal duct cysts: anatomy, embryology and treatment, *Surg. Radiol. Anat.* 35 (2013) 875–881.
- [4] E.J. Kezirian, N.B. Powell, R.W. Riley, J.E. Hester, Incidence of complications in radiofrequency treatment of the upper airway, *Laryngoscope* 115 (2005) 1298–1304.
- [5] M.B. Pringle, C.B. Croft, A grading system for patients with obstructive sleep apnoea – based on sleep nasendoscopy, *Clin. Otolaryngol. Allied Sci.* 18 (1993) 480–484.
- [6] V. Mondin, A. Ferlito, E. Muzzi, C.E. Silver, J.J. Fagan, K.O. Devaney, et al., Thyroglossal duct cyst: personal experience and literature review, *Auris, Nasus, Larynx* 35 (2008) 11–25.
- [7] W. Ren, K. Zhi, L. Zhao, L. Gao, Presentations and management of thyroglossal duct cyst in children versus adults: a review of 106 cases, *Oral Surg. Oral Med. Oral Pathol. Oral Radiol. Endod.* 111 (2011) e1–6.
- [8] A. Kurt, C. Ortug, Y. Aydar, G. Ortug, An incidence study on thyroglossal duct cysts in adults, *Saudi Med. J.* 28 (2007) 593–597.
- [9] G.M. Sprinzl, J. Koebke, J. Wimmers-Klick, H.E. Eckel, W.F. Thumfart, Morphology of the human thyroglossal tract: a histologic and macroscopic study in infants and children, *Ann. Otol. Rhinol. Laryngol* 109 (2000) 1135–1139.
- [10] F. Safruddin, D.L. Mourits, N. de Vries, Thyroglossal duct cysts and obstructive sleep apnoea: three case reports and review of the literature, *J. Laryngol Otol.* 128 (2014) 738–741.
- [11] N.B. Powell, R.W. Riley, R.J. Troell, M.B. Blumen, C. Guilleminault, Radiofrequency volumetric reduction of the tongue: a porcine pilot study for

- the treatment of obstructive sleep apnea syndrome, *Chest* 111 (1997) 1348–1355.
- [12] R. Shah, K. Gow, S.E. Sobol, Outcome of thyroglossal duct cyst excision is independent of presenting age or symptomatology, *Int. J. Pediatr. Otorhinolaryngol* 71 (2007) 1731–1735.
- [13] L.M. Simon, A.E. Magit, Impact of incision and drainage of infected thyroglossal duct cyst on recurrence after Sistrunk procedure, *Arch. Otolaryngol Head Neck Surg.* 138 (2012) 20–24.

Open Access

This article is published Open Access at sciedirect.com. It is distributed under the [IJSCR Supplemental terms and conditions](#), which permits unrestricted non commercial use, distribution, and reproduction in any medium, provided the original authors and source are credited.