



American Society of Hematology  
2021 L Street NW, Suite 900,  
Washington, DC 20036  
Phone: 202-776-0544 | Fax 202-776-0545  
editorial@hematology.org

## **Interleukin-1 blockade in patients with Wiskott-Aldrich Syndrome: a retrospective multinational case series**

Tracking no: BLD-2024-024524R3

Samuele Naviglio (Institute for Maternal and Child Health IRCCS "Burlo Garofolo", Italy) Maria Cicalese (San Raffaele Telethon Institute for Gene Therapy (SR-TIGET), IRCCS San Raffaele Scientific Institute, Italy) Elizabeth Rivers (UCL Great Ormond Street Institute of Child Health, United Kingdom) Francesca Ferrua (San Raffaele Scientific Institute, Italy) Carmem Bonfim (Hospital Pequeno Principe/Pele Pequeno Principe Research Institute, Brazil) Sabina Cenciarelli (San Raffaele Scientific Institute, Italy) Kai-Ning Cheong (Hong Kong Children's Hospital, China) Maura Faraci (IRCCS Istituto Giannina Gaslini, Italy) Stefano Giardino (IRCCS Istituto Giannina Gaslini, Italy) Sujal Ghosh (Universitätsklinikum Düsseldorf, Germany) Pamela P. Lee (LKS Faculty of Medicine, The University of Hong Kong, Hong Kong) Paula Lyra (Instituto de Medicina Integral Prof. Fernando Figueira, Brazil) Roland Meisel (Center for Child & Adolescent Health, Heinrich-Heine-University, Germany) Valentina Sofia (Università Vita-Salute San Raffaele, Italy) Antimo Tessitore (University of Trieste, Italy) Alberto Tommasini (IRCCS Burlo Garofolo and University of Trieste, Italy) Erica Valencic (IRCCS Burlo Garofolo, Italy) Tanja Vallée (Dr. von Hauner Children's Hospital, University Hospital, Ludwig-Maximilians-Universität München, Germany) Stefano Volpi (IRCCS Istituto Giannina Gaslini, Italy) Austen J Worth (Great Ormond Street Hospital, United Kingdom) marco rabusin (Institute of maternal and child health Burlo Garofolo, Italy) Michael Albert (Dr. von Hauner Children's Hospital, University Hospital, LMU Munich, Germany) Adrian Thrasher (UCL Institute of Child Health, United Kingdom) Alessandro Aiuti (IRCCS San Raffaele Scientific Institute, Italy)

### **Abstract:**

Up to 70% of patients with Wiskott-Aldrich Syndrome (WAS) develop autoimmune and inflammatory manifestations. Dysregulation of interleukin (IL)-1 may be involved in their pathogenesis, yet there is little evidence on treatment with anti-IL-1 agents in these patients. We conducted a multicenter retrospective analysis of nine patients with WAS treated with anti-IL-1 agents (anakinra or canakinumab). All patients had prominent inflammatory manifestations, including systemic, cutaneous, articular, and intestinal symptoms; three patients presented with a severe systemic inflammatory syndrome since the first months of life. Corticosteroid therapy was associated with partial or no response, while treatment with anakinra or canakinumab resulted in prompt, often dramatic, responses in all patients, allowing bridging to gene therapy (four patients) or hematopoietic stem cell transplantation (HSCT, five patients). Treatment was overall well tolerated. Low donor myeloid chimerism developed in four patients after HSCT and was associated with the appearance or the recurrence of inflammatory manifestations. A second HSCT was performed in two patients, achieving full-donor chimerism and resolution of inflammatory manifestation, while the other two patients were treated with prolonged therapy with anti-IL-1 agents. Our experience demonstrates that some inflammatory manifestations of WAS are dependent on IL-1 and respond very well to its pharmacologic blockade.

**Conflict of interest:** No COI declared

**COI notes:**

**Preprint server:** No;

**Author contributions and disclosures:** S.N. designed the study, cared for patients, collected and analyzed data, and wrote the first draft of the manuscript. M.P.C., E.R., F.F., A.J.T., A.A. designed the study, cared for patients, and critically reviewed the manuscript. C.B., S.C., K.N.C., M.F., S. Giardino, S. Gosh, PPL, PTL, RM, VS, A. Tessitore, A. Tommasini, E.V., T.C.V., S.V., A.J.W., M.R., M.H.A. cared for patients, collected data and critically reviewed the manuscript.

**Non-author contributions and disclosures:** No;

**Agreement to Share Publication-Related Data and Data Sharing Statement:** email to the corresponding author

**Clinical trial registration information (if any):**

## **Interleukin-1 blockade in patients with Wiskott-Aldrich Syndrome:**

### **a retrospective multinational case series**

Samuele Naviglio<sup>1\*</sup>, Maria Pia Cicalese<sup>2,3,4\*</sup>, Elizabeth Rivers<sup>5\*</sup>, Francesca Ferrua<sup>2,4</sup>,  
Carmem Bonfim<sup>6,7</sup>, Sabina Cenciarelli<sup>2,4</sup>, Kai-Ning Cheong<sup>8</sup>, Maura Faraci<sup>9</sup>, Stefano Giardino<sup>9</sup>,  
Sujal Ghosh<sup>10</sup>, Pamela P Lee<sup>11</sup>, Paula Teixeira Lyra<sup>12,13</sup>, Roland Meisel<sup>10</sup>, Valentina Sofia<sup>3</sup>,  
Antimo Tessitore<sup>14</sup>, Alberto Tommasini<sup>1,14</sup>, Erica Valencic<sup>1</sup>, Tanja Christine Vallée<sup>15</sup>, Stefano Volpi<sup>16,17</sup>,  
Austen J Worth<sup>5,18</sup>, Marco Rabusin<sup>1</sup>, Michael H Albert<sup>15</sup>, Adrian J Thrasher<sup>5,18</sup>, and Alessandro Aiuti<sup>2,3,4</sup>

#### Affiliations

1. Institute for Maternal and Child Health IRCCS “Burlo Garofolo”, Trieste, Italy
2. Pediatric Immunohematology and Bone Marrow Transplantation Unit, IRCCS San Raffaele Scientific Institute, Milan, Italy.
3. Università Vita-Salute San Raffaele, Milan, Italy.
4. San Raffaele Telethon Institute for Gene Therapy (SR-Tiget), IRCCS San Raffaele Scientific Institute, Milan, Italy.
5. Great Ormond Street Institute of Child Health, University College London, London, United Kingdom.
6. Bone Marrow Transplantation Unit, Complexo Hospital de Clínicas, Federal University of Paraná, Curitiba, PR, Brazil.
7. Instituto de Pesquisa Pelé Pequeno Príncipe, Hospital Pequeno Príncipe, Curitiba, PR, Brazil.
8. Hong Kong Children's Hospital, Hong Kong, Hong Kong SAR, China.

9. Hematopoietic Stem Cell Transplantation Unit, Department of Hematology-Oncology, IRCCS Istituto Giannina Gaslini, Genoa, Italy.
10. Department of Pediatric Oncology, Hematology and Clinical Immunology, Medical Faculty, Heinrich-Heine-University - Düsseldorf University Hospital, Düsseldorf, Germany.
11. Department of Paediatrics and Adolescent Medicine, School of Clinical Medicine, Li Ka Shing Faculty of Medicine, The University of Hong Kong, Hong Kong, Hong Kong SAR, China.
12. Department of Clinical Immunology, Instituto de Medicina Integral Prof. Fernando Figueira (IMIP), Recife, Pernambuco, Brazil.
13. Children's Department of Infectious Disease, Oswaldo Cruz University Hospital (HUOC), Universidade de Pernambuco (UPE), Recife, PA, Brazil.
14. Department of Medicine, Surgery and Health Sciences, University of Trieste, Trieste, Italy.
15. Dr. von Hauner University Children's Hospital, Ludwig-Maximilians-Universität, Munich, Germany.
16. UOC Clinica Pediatrica e Reumatologia, Centro per le malattie Autoinfiammatorie e Immunodeficienze, Istituto Giannina Gaslini, Genoa, Italy
17. DINOGMI, Università degli Studi di Genova, Genoa, Italy.
18. Department of Immunology, Great Ormond Street Hospital for Children NHS Foundation Trust, London, United Kingdom.

S.N., M.P.C., and E.R. contributed equally to this study.

Corresponding author: Samuele Naviglio, Institute for Maternal and Child Health IRCCS “Burlo Garofolo”, Trieste, Italy. E-mail: samuele.naviglio@burlo.trieste.it.

Phone number +390403785562, Fax number +390403785494.

Data sharing: For original data, please contact Samuele Naviglio (see correspondence details).

Short title: IL-1 blockade in patients with WAS

Text word count: 1555

Abstract word count: 199

Number of references: 25

Number of figures: 1

Number of tables: 1

### **Key Points**

- Patients with Wiskott-Aldrich Syndrome can develop inflammatory manifestations poorly controlled by corticosteroid therapy.
- Treatment with anti-IL-1 agents resulted in dramatic responses, suggesting an autoinflammatory pathogenesis.

**Abstract**

Up to 70% of patients with Wiskott-Aldrich Syndrome (WAS) develop autoimmune and inflammatory manifestations. Dysregulation of interleukin (IL)-1 may be involved in their pathogenesis, yet there is little evidence on treatment with anti-IL-1 agents in these patients. We conducted a multicenter retrospective analysis of nine patients with WAS treated with anti-IL-1 agents (anakinra or canakinumab). All patients had prominent inflammatory manifestations, including systemic, cutaneous, articular, and intestinal symptoms; three patients presented with a severe systemic inflammatory syndrome since the first months of life. Corticosteroid therapy was associated with partial or no response, while treatment with anakinra or canakinumab resulted in prompt, often dramatic, responses in all patients, allowing bridging to gene therapy (four patients) or hematopoietic stem cell transplantation (HSCT, five patients). Treatment was overall well tolerated. Low donor myeloid chimerism developed in four patients after HSCT and was associated with the appearance or the recurrence of inflammatory manifestations. A second HSCT was performed in two patients, achieving full-donor chimerism and resolution of inflammatory manifestation, while the other two patients were treated with prolonged therapy with anti-IL-1 agents. Our experience demonstrates that some inflammatory manifestations of WAS are dependent on IL-1 and respond very well to its pharmacologic blockade.

## **Introduction**

Wiskott-Aldrich Syndrome (WAS, OMIM 301000) is a rare primary immunodeficiency disorder caused by mutations in the *WAS* gene characterized by immunodeficiency, thrombocytopenia, and eczema.<sup>1</sup> Up to 70% of patients develop autoimmune and inflammatory disorders, including autoimmune cytopenias, arthritis, vasculitis, and inflammatory bowel disease.<sup>2,3</sup> Furthermore, autoimmune and inflammatory disorders complicate allogeneic hematopoietic stem cell transplantation (HSCT) in up to 20% of subjects, particularly when chimerism is low.<sup>4,5</sup> The pathogenesis of autoimmunity in WAS has been shown to be related to defective T and B cell function.<sup>6-8</sup> However, there is increasing evidence for abnormal inflammasome activation and release of proinflammatory cytokines, especially interleukin (IL)-1 and IL-18, in WAS.<sup>9,10</sup> Therapies aimed at IL-1 blockade may, therefore, represent an effective strategy, yet, there is limited clinical information available. Here, we report a cohort of WAS patients treated with anti-IL-1 therapies.

## **Methods**

A retrospective review of clinical records of patients with WAS treated with anti-IL-1 agents (anakinra or canakinumab) was performed at seven pediatric immunology centers. Therapy with anti-IL1 agents was administered off-label after institutional ethical approval and parents/guardians informed consent. All patients were enrolled in locally approved research protocols. The present study has been approved by the Institute for Maternal and Child Health IRCCS “Burlo Garofolo” Institutional Review Board (RC 30/22). Written consent for publication in accordance with the Declaration of Helsinki was obtained from parents or guardians.

## **Results and discussion**

Nine patients were identified; for four patients (patients 5, 6, 8 and 9), partial clinical information had been reported elsewhere.<sup>10-12</sup> Patients' characteristics are summarized in Table 1 (full clinical and therapeutic history in Supplemental data). All patients had prominent inflammatory manifestations (IMs). WAS clinical score, according to Zhu et al.<sup>13</sup>, was 5A in all patients. Most commonly reported IMs included systemic, cutaneous, articular, and intestinal signs/symptoms. Inflammatory cutaneous involvement, eczema aside, was present in 8/9 patients and included cutaneous vasculitis (n=5), pyoderma gangrenosum (n=2), recurrent/migrating erysipelas-like lesions (n=2), sterile abscess, pustular psoriasis, and panniculitis (1 patient each) (fig. 1, A-F). Inflammatory joint involvement and inflammatory bowel disease (IBD) were present in four patients each. Three patients (pt 1, 5, and 8) presented with a severe systemic inflammatory syndrome appearing in the first months of life, characterized by prominent fever and systemic symptoms associated with cutaneous inflammatory involvement (rash, vasculitis, and erysipelas-like lesions), failure to thrive, and marked increase of blood inflammatory markers. In the other patients, IMs were not associated with persistent fever and tended to have a more chronic course.

All patients received treatment with systemic corticosteroids, with only partial or no response in most of them. Anti-IL-1 agents (anakinra or canakinumab) led to very good or complete responses in all patients. In most patients, the treatment effect was very rapid (days); this was particularly evident in the three patients presenting with severe systemic inflammatory syndrome in the first months of life, in whom prompt and complete resolution of IMs, fever, and systemic symptoms was observed immediately after the commencement of anakinra. Very good responses were observed also in the other patients, leading to the resolution of IMs often refractory to several other therapies (e.g., pyoderma gangrenosum in pts 4 and 9). Therapy was also associated with normalization or near-normalization of inflammatory markers (supplemental table S2). In all patients, anti-IL-1 agents were used in addition to corticosteroids, allowing their tapering; in five patients, corticosteroids could eventually be discontinued, and IMs were controlled by anti-IL-1 agents alone. Notably, in most patients, treatment with anti-IL-1 agents had to be administered continuously and could not be withheld since symptoms tended to relapse (most evident in pt. 5, in whom symptoms recurred within hours of a delayed dose of



anakinra). Therapy was well tolerated in all patients, even for very long periods (up to 8 years in one patient), allowing successful bridging to definitive treatment. Most commonly reported adverse effects included injection site lipohypertrophy and injection anxiety with anakinra, which improved switching to canakinumab. Two patients developed hypereosinophilia: in one patient (pt 6), this was considered to be related to immune reconstitution post-gene therapy (GT) and resolved spontaneously; in the second patient (pt 8), anakinra was briefly stopped as a precaution, and hypereosinophilia was successfully treated with low-dose corticosteroids; anakinra was then resumed, in association with low-dose corticosteroids, and continued until GT. Colchicine was used in two patients: in one patient, it led to near-complete resolution of cutaneous vasculitis symptoms for more than one year, yet it eventually lost its efficacy; in the second one, it was added to long-standing anakinra, so it was difficult to determine its contribution; nevertheless, colchicine was stopped after five years since it was felt to be not helping.

All patients underwent definitive treatment for WAS, either by GT (4 patients) or HSCT (5 patients; details in supplementary table S1). Treatment with anti-IL-1 agents was discontinued before HSCT/GT in all patients, except in two patients (pt 6 and 9), in whom anakinra was discontinued only after GT. Four out of five patients who underwent HSCT developed low (0-30%) myeloid donor chimerism, with relatively preserved lymphoid chimerism (80-95%). These patients experienced post-HSCT IMs, either for the first time (pt 2 and 3) or as a recurrence of pre-HSCT symptoms (pt 1 and 5). In three patients (pts 1, 2, 5; fig. 1G), loss of myeloid chimerism was temporally associated with the occurrence of IMs, while in pt 3, post-HSCT IMs occurred in the setting of long-standing low myeloid chimerism. Two patients (pt 1 and 2) underwent a second HSCT, resulting in complete donor chimerism and resolution of IMs, while in the other two patients (pt 3 and 5), therapy with anakinra was continued; both patients were eventually switched to canakinumab due to frequent injections intolerance. Patients who underwent GT maintained a stable myeloid correction, and no patient experienced a recurrence of IMs.

The present clinical experience shows that several inflammatory manifestations of WAS are dependent on IL-1 and respond to its pharmacologic blockade, thus suggesting an autoinflammatory contribution to their pathogenesis. While loss of tolerance due to abnormal T and B cell function has been clearly demonstrated in WAS,<sup>3,6,14-16</sup> our experience underlines the role of inflammatory mechanisms in this condition. Wiskott-Aldrich Syndrome protein (WASP) has a major role in

leukocyte chemotaxis/activation,<sup>17,18</sup> autophagy, and inflammasome activity.<sup>9</sup> Furthermore, mutations in several WASP-interacting, cytoskeleton-related, proteins are associated with autoinflammatory disorders that have been included in a new group of immune defects with autoinflammation called “immune actinopathies” (e.g. PSTPIP1, CDC42).<sup>19,20</sup> Notably, similarly to other monogenic autoinflammatory conditions, some of our patients presented with an early-onset, sepsis-like, severe systemic inflammatory syndrome, while in others, IMs appeared at an older age and had a more chronic course. In all cases, IMs responded very well to anti-IL-1 agents, which often could not be discontinued due to the reappearance of symptoms. Incomplete response to corticosteroids, especially if compared to direct IL-1 blockade, is consistent with what is observed in other monogenic autoinflammatory diseases. IL-1 exerts positive feedback on its production; thus its direct blockade can be more effective than reduced transcription by corticosteroids. Furthermore, corticosteroids also suppress IL-1 receptor antagonist synthesis, resulting in reduced overall inhibitory efficacy.<sup>21</sup> Colchicine, a drug that reduces IL-1b release through inhibition of caspase-1 and of NLRP3 inflammasome oligomerization, was also used in two patients, with mixed results; however, our data are too limited to draw conclusions on its efficacy.

The fact that several patients experienced IMs with declining myeloid (but not lymphoid) chimerism after HSCT suggests a central role for myeloid cells in autoinflammation in WAS. WASP-deficient myeloid cells exhibit impaired polarization, migration, and phagocytosis, but also increased activation of the NLRP3 inflammasome and IL-1b release following chemical or bacterial stimulation.<sup>9,22</sup> Furthermore, WASP-deficient neutrophils are prone to spontaneous neutrophil extracellular traps (NETs) release.<sup>23</sup> The role of preserved lymphoid chimerism in this setting is uncertain; however, the fact that IMs occurred both before and after HSCT in patients with loss of myeloid chimerism suggests a more prominent role of defective myeloid cells. No patient experienced a relapse of IMs after GT, possibly due to more stable myeloid correction (supplemental fig. 1).

Therapy with anti-IL-1 agents was very well tolerated in all patients, without severe adverse effects. This is consistent with their overall record of safety from other conditions. Anti-IL-1 therapies do not have direct organ toxicities, and they are not directly immunosuppressive, nor increase the risk of opportunistic infection; however, they may be associated with a slight increase of severe infections, possibly due to a blunting effect on infection signs and symptoms leading to delayed

diagnoses.<sup>24,25</sup> On the other hand, treatment with anti-IL-1 therapies allowed corticosteroid sparing in all patients, therefore reducing their immunosuppressive effect. Overall, we do not suggest adjunctive anti-infectious therapies in patients treated with anti-IL-1 agents, yet the possibility of a more blunted clinical response to infection should be considered.

This study has several limitations, including its retrospective nature, therefore a reporting bias cannot be excluded. We did not study molecular markers that could help identifying patients most likely to benefit from anti-IL-1 agents; therefore, at present, in consideration of its general safety and short half-life, a therapeutic trial of anakinra could represent the most effective strategy in patients presenting with refractory IMs. Overall, our experience encourages further studies on the use of anti-IL-1 agents as first-line treatment for inflammatory manifestation in WAS patients, possibly in lieu of other immunosuppressive drugs often associated with a less favorable safety profile.

## **Acknowledgments**

This work was supported by the Italian Ministero della Salute (Rome, Italy) in collaboration with the Institute for Maternal and Child Health IRCCS Burlo Garofolo (Trieste, Italy) with grant RC 30/22; and with grant Ricerca Finalizzata GR-2016-02365089 "Role of follicular helper T cells in the humoral immune alterations in patients with mutations in the Wiskott Aldrich Syndrome protein before and after hematopoietic stem cell transplantation"; and by the European Union/Next Generation EU Fund "Implementation of an Italian Network for advanced diagnosis and targeted treatment of Inborn errors of Immunity" (PNRR MR1-2022-12376594) and "Immunogenicity and long term memory maintenance of SARS-CoV2 mRNA vaccination in patients affected by Inborn Errors of Immunity" (PNRR M4C2-2022-ZCLC3X).

**Authors' contribution:** S.N. designed the study, cared for patients, collected and analyzed data, and wrote the first draft of the manuscript. M.P.C., E.R., F.F., A.J.T., A.A. designed the study, cared for patients, and critically reviewed the manuscript. C.B., S.C., K.N.C., M.F., S. Giardino, S. Gosh, PPL, PTL, RM, VS, A. Tessitore, A. Tommasini, E.V., T.C.V., S.V., A.J.W., M.R., M.H.A. cared for patients, collected data and critically reviewed the manuscript.

Conflict-of-interest disclosure: The authors declare no competing financial interests.

Correspondence: Samuele Naviglio, Pediatric Hematology-Oncology, Institute for Maternal and Child Health IRCCS “Burlo Garofolo”, via dell’Istria 65/1, 34139, Trieste, Italy. E-mail: [samuele.naviglio@burlo.trieste.it](mailto:samuele.naviglio@burlo.trieste.it).

## References

1. Derry JM, Ochs HD, Francke U. Isolation of a novel gene mutated in Wiskott-Aldrich syndrome. *Cell*. 1994;79(5):635–644.
2. Sullivan KE, Mullen CA, Blaese RM, Winkelstein JA. A multiinstitutional survey of the Wiskott-Aldrich syndrome. *J. Pediatr*. 1994;125(6 PART 1):876–885.
3. Candotti F. Clinical Manifestations and Pathophysiological Mechanisms of the Wiskott-Aldrich Syndrome. *J. Clin. Immunol*. 2018;38(1):13–27.
4. Ozsahin H, Cavazzana-Calvo M, Notarangelo LD, et al. Long-term outcome following hematopoietic stem-cell transplantation in Wiskott-Aldrich syndrome: Collaborative study of the European Society for Immunodeficiencies and European Group for Blood and Marrow Transplantation. *Blood*. 2008;111(1):439–445.
5. Moratto D, Giliani S, Bonfim C, et al. Long-term outcome and lineage-specific chimerism in 194 patients with Wiskott-Aldrich syndrome treated by hematopoietic cell transplantation in the period 1980-2009: An international collaborative study. *Blood*. 2011;118(6):1675–1684.
6. Rivers E, Thrasher AJ. Wiskott-Aldrich syndrome protein: Emerging mechanisms in immunity. *Eur. J. Immunol*. 2017;47(11):1857–1866.
7. Marangoni F, Trifari S, Scaramuzza S, et al. WASP regulates suppressor activity of human and murine CD4 +CD25+FOXP3+ natural regulatory T cells. *J. Exp. Med*. 2007;204(2):369–380.
8. Kolhatkar NS, Brahmandam A, Thouvene CD, et al. Altered BCR and TLR signals promote enhanced positive selection of autoreactive transitional B cells in Wiskott-Aldrich syndrome. *J. Exp. Med*. 2015;212(10):1663–1667.
9. Lee PP, Lobato-Márquez D, Pramanik N, et al. Wiskott-Aldrich syndrome protein regulates autophagy and inflammasome activity in innate immune cells. *Nat. Commun*. 2017;8(1):1576.
10. Rivers E, Hong Y, Bajaj-Elliott M, Worth A, Thrasher AJ. IL-18: A potential inflammation biomarker in Wiskott–Aldrich syndrome. *Eur. J. Immunol*.

- 2021;51(5):1285–1288.
11. Brigida I, Scaramuzza S, Lazarevic D, et al. A novel genomic inversion in Wiskott-Aldrich–associated autoinflammation. *J. Allergy Clin. Immunol.* 2016;138(2):619-622.e7.
  12. Cenciarelli S, Calbi V, Barzaghi F, et al. Mild SARS-CoV-2 Infection After Gene Therapy in a Child With Wiskott-Aldrich Syndrome: A Case Report. *Front. Immunol.* 2020;11:603428.
  13. Zhu Q, Zhang M, Blaese RM, et al. The Wiskott-Aldrich syndrome and X-linked congenital thrombocytopenia are caused by mutations of the same gene. *Blood.* 1995;86(10):3797–3804.
  14. Humblet-Baron S, Sather B, Anover S, et al. Wiskott-Aldrich syndrome protein is required for regulatory T cell homeostasis. *J. Clin. Invest.* 2007;117(2):407–418.
  15. Nikolov NP, Shimizu M, Cleland S, et al. Systemic autoimmunity and defective Fas ligand secretion in the absence of the Wiskott-Aldrich syndrome protein. *Blood.* 2010;116(5):740–747.
  16. Adriani M, Jones KA, Uchiyama T, et al. Defective inhibition of B-cell proliferation by Wiskott-Aldrich syndrome protein-deficient regulatory T cells. *Blood.* 2011;117(24):6608–6611.
  17. Zicha D, Allen WE, Brickell PM, et al. Chemotaxis of macrophages is abolished in the Wiskott-Aldrich syndrome. *Br. J. Haematol.* 1998;101(4):659–665.
  18. Snapper SB, Rosen FS. The Wiskott-Aldrich syndrome protein (WASP): roles in signaling and cytoskeletal organization. *Annu. Rev. Immunol.* 1999;17:905–29.
  19. Sprenkeler EGG, Webbers SDS, Kuijpers TW. When Actin is Not Actin’ like It Should: A New Category of Distinct Primary Immunodeficiency Disorders. *J. Innate Immun.* 2021;13(1):3–25.

20. Dupré L, Boztug K, Pfajfer L. Actin Dynamics at the T Cell Synapse as Revealed by Immune-Related Actinopathies. *Front. Cell Dev. Biol.* 2021;9:603428.
21. Arzt E, Sauer J, Pollmächer T, et al. Glucocorticoids suppress interleukin-1 receptor antagonist synthesis following induction by endotoxin. *Endocrinology.* 1994;134(2):672–7.
22. Bouma G, Burns SO, Thrasher AJ. Wiskott-Aldrich Syndrome: Immunodeficiency resulting from defective cell migration and impaired immunostimulatory activation. *Immunobiology.* 2009;214(9–10):778–790.
23. Cervantes-Luevano KE, Caronni N, Castiello MC, et al. Neutrophils drive type I interferon production and autoantibodies in patients with Wiskott-Aldrich syndrome. *J. Allergy Clin. Immunol.* 2018;142(5):1605-1617.e4.
24. Buckley LF, Abbate A. Interleukin-1 blockade in cardiovascular diseases: A clinical update. *Eur. Heart J.* 2018;39(22):2063–2069.
25. Mertens M, Singh JA. Anakinra for rheumatoid arthritis. *Cochrane database Syst. Rev.* 2009;(1):CD005121.

**Table 1. Clinical features**

Current status	Skin involvement (beside eczema)	Arthritis	IBD	Response to CS	Anti-IL1 drug (age at first use, yrs)	Drug dose	Response to anti-IL1 therapy	Effect of therapy suspension	Adverse effects of therapy	Duration of therapy, yrs	Reason for discontinuation, duration, yrs	DT	Declining donor chimerism after HSCT (% donor)	IMs after DT ? (% myeloid chimerism at onset)	2 <sup>nd</sup> HSCT	Current status FU duration last DT
	Vasculitis, erythematous papules, scalp blisters	Hands/feet	No	Partial	Anakinra (0.25)	3 mg/kg/d	Complete	Not tried	No	0.25	DT	HSCT (twice)	Yes, after 1 <sup>st</sup> HSCT (CD3 85%, CD14 1%)	Yes, recurrence (CD14 1%)	Yes	CR after 2 <sup>nd</sup> full donor chimerism (3 yrs FU)
	Vasculitis-like lesions left foot / hand	Ankle, hands	No	Complete	Colchicine (5)	50 mcg/kg/d	Partial	Not tried	No	1	Loss of efficacy	HSCT (twice)	Yes, after 1 <sup>st</sup> HSCT (CD3 90% CD15 0%)	Yes, 1 <sup>st</sup> appearance (CD15 0%)	Yes	CR after 2 <sup>nd</sup> full donor chimerism (4 yrs FU)
	Erysipeloid-like inflammation lower limbs	Knees, ankles	No	Partial	Anakinra (14)	3 mg/kg/d	Complete	Not tried	Injection site pain	0.1	Adverse effects	HSCT	Yes, after HSCT (CD3 80%, CD14 30%)	Yes, 1 <sup>st</sup> appearance (CD14 30%)	No	Well-control canakinumab
	Pyoderma gangrenosum, sterile abscesses	No	No	Partial	Canakinuma b (14.2)	2 mg/kg/4 wks	Complete	Not tried	No	1	Ongoing	HSCT	No	No	No	CR after HSCT full donor chimerism (3 yrs FU)
	Necrotizing vasculitis, rash, panniculitis, pustular psoriasis	No	Yes	Partial	Anakinra (0.1)	5 mg/kg/d	Complete	Symptoms recurrence	Lipohypertrophy, injection anxiety	8	Adverse effects	HSCT	Yes, after HSCT (CD3 93%, CD15 15%)	Yes, recurrence (CD15 40%)	No	Well-control canakinumab
	No	No	Yes	Partial	Colchicine (3)	50 mcg/kg/d	ND (given with anakinra)	Yes	No	4	Not effective					CR (5 yrs FU)
	Cutaneous vasculitis and edema	Ankle	Yes	Partial	Canakinuma b (8)	3.5 – 5.6 mg/kg/4 wks	Complete	Symptoms recurrence	No	1	Ongoing					CR (4.4 yrs FU)
	Migrating erysipelas-like lesions; vasculitis	No	No	No	Anakinra (0.3)	5 mg/kg/d	Complete	Symptoms recurrence	Hyper eosinophilia	0.75	DT	GT	NA	No	No	CR (4.1 yrs FU)
	Pyoderma gangrenosum	No	Yes	Partial	Anakinra (11.8)	3 mg/kg/d	Complete	Symptoms recurrence	No	0.6	DT	GT	NA	No	No	CR (8 yrs FU)

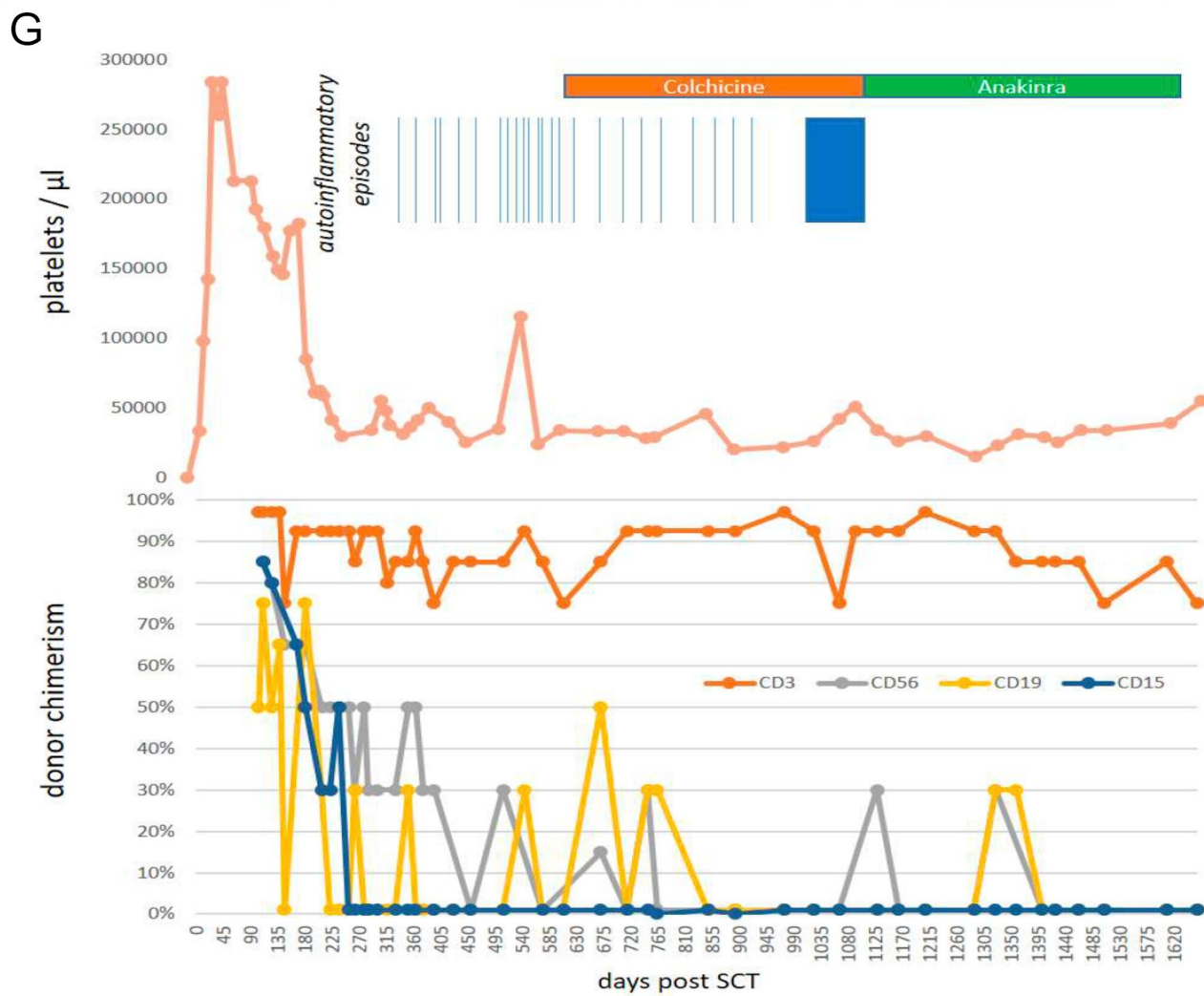
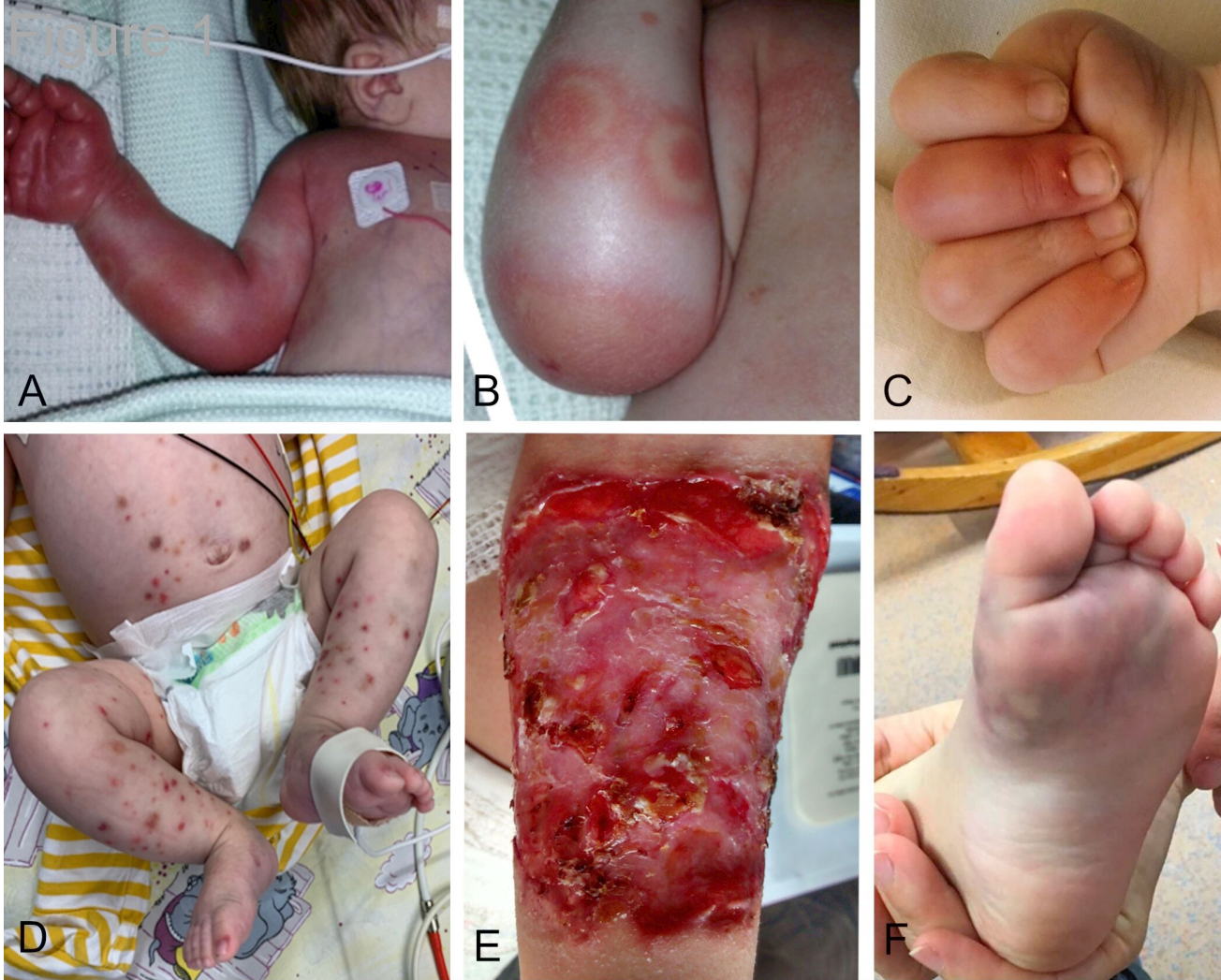DT, Definitive Therapy; HSCT, Hematopoietic Stem Cell Transplantation; GT, Gene Therapy; NA, Not applicable; ND, Non-determinable; CR, Complete resolution; FU, follow-up.



**Figure Legend.**

Fig. 1. Panels A-F: inflammatory skin manifestations of patients. A, B: inflammatory skin rash in patient 5 at the onset of systemic inflammatory symptoms at 4 weeks of life (pre-HSCT). C: Cellulitis-like lesions of the third finger in patient 8 (pre-GT). D: Vasculitic lesions of the trunk and the extremities in patient 1 at 2.5 months of age (pre-HSCT). E: Pyoderma gangrenosum in patient 4 (pre-HSCT). F: Vasculitis-like lesions of the foot in patient 2 (post-HSCT; see also panel G). Panel G: Post-HSCT donor chimerism and time course of inflammatory manifestations in patient 2.

Figure 1



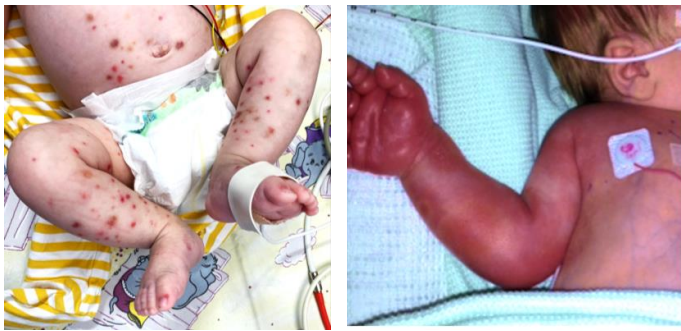# Interleukin-1 Blockade in Patients with Wiskott-Aldrich Syndrome

## Context of research:

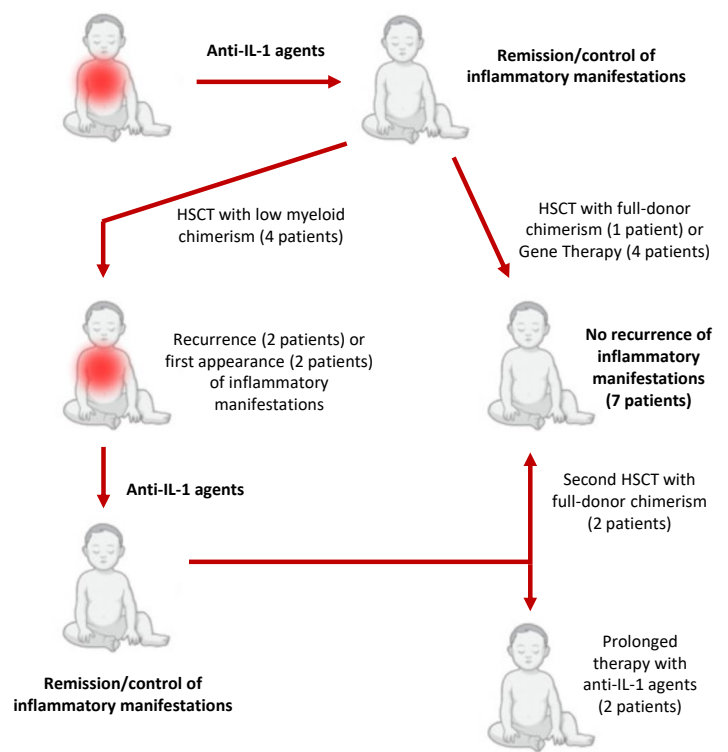
- Autoimmune and inflammatory manifestations are very common in patients with Wiskott-Aldrich Syndrome (WAS) and their pathogenesis may involve dysregulation of interleukin (IL)-1.
- There is little available information on treatment with anti-IL-1 agents (anakinra or canakinumab) in patients with WAS.

## Patients and methods:

- Retrospective review of 9 children with WAS treated with anti-IL-1 agents (anakinra or canakinumab) for inflammatory manifestations at 7 pediatric centers.
- All patients had prominent inflammatory manifestations including systemic, cutaneous, articular, and intestinal symptoms, poorly controlled by systemic corticosteroids.



## Main findings:



**Conclusions:** 1) Patients with Wiskott-Aldrich Syndrome can develop inflammatory manifestations poorly controlled by corticosteroid therapy. 2) Therapy with anti-IL-1 agents resulted in dramatic responses, allowing successful bridging to definitive therapy.