

Ocul Oncol Pathol , DOI: 10.1159/000538984

Received: December 11, 2023

Accepted: April 11, 2024

Published online: May 20, 2024

## **Retinal focal nodular gliosis have varied clinical courses requiring tailored management: a case series**

le A, Sagoo MS, MacLaren R, Cehajic-Kapetanovic J

ISSN: 2296-4681 (Print), eISSN: 2296-4657 (Online)

<https://www.karger.com/OOP>

Ocular Oncology and Pathology

### **Disclaimer:**

Accepted, unedited article not yet assigned to an issue. The statements, opinions and data contained in this publication are solely those of the individual authors and contributors and not of the publisher and the editor(s). The publisher and the editor(s) disclaim responsibility for any injury to persons or property resulting from any ideas, methods, instructions or products referred to the content.

### **Copyright:**

© 2024 S. Karger AG, Basel

# Retinal focal nodular gliosis have varied clinical courses requiring tailored management: a case series

## Authors

Amanda Ie<sup>1</sup>, Mandeep S. Sagoo<sup>2</sup>, Robert MacLaren<sup>1,3</sup>, Jasmina Cehajic-Kapetanovic<sup>1,3</sup>

<sup>1</sup>Oxford Eye Hospital, NHS Foundation Trust, Oxford, UK

<sup>2</sup>UCL Institute of Ophthalmology and Moorfields Eye Hospital NHS Foundation Trust, London, UK

<sup>3</sup> Nuffield Department of Clinical Neurosciences, University of Oxford, Oxford, United Kingdom

Running title: Retinal focal nodular gliosis have varied clinical courses

Key words: retinal vasoproliferative tumors, retinal focal nodular gliosis, retinitis pigmentosa, CRB1

## Corresponding authors

Amanda Ie: [amandaie88@gmail.com](mailto:amandaie88@gmail.com)

Jasmina Cehajic-Kapetanovic: [jasmina.kapetanovic@eye.ox.ac.uk](mailto:jasmina.kapetanovic@eye.ox.ac.uk)

## Abstract:

**Introduction:** Retinal focal nodular gliosis (FNG), also known as vasoproliferative tumors (VPTs), are rare, benign vascular tumors associated with exudation with no current consensus on management. Herein, we describe the varied clinical course and management of three patients with retinal focal nodular gliosis, one of whom is associated with retinitis pigmentosa.

**Case presentations:** Case 1 is a 76-year-old female who presented with reduced vision and distortion secondary to a vitreous hemorrhage and epiretinal membrane (ERM) as complications of a known small peripheral retinal focal nodular gliosis. She underwent vitrectomy for the hemorrhage to relieve vascular traction and the ERM peel and the tumor was kept under observation. Case 2 is a 24-year-old female with genetically uncharacterized retinitis pigmentosa-like phenotype who presented with gradual loss of central vision in one eye due to cystoid macular oedema (CMO). She was found to have two peripheral retinal areas of focal nodular gliosis located inferonasally. Tumors were treated with cryotherapy and adjuvant intraocular steroid implant to control the CMO. Case 3 is a 28-year-old female with retinitis pigmentosa secondary to genetically confirmed variant in *CRB1* gene who presented with intractable right eye cystoid macular oedema and localized inferior serous retinal detachment secondary to a large inferotemporal focal nodular gliosis. Her left eye has no light perception vision due to previous extensive serous retinal detachment and anterior segment ischemia. The right eye tumor was managed with multiple rounds of cryotherapy and laser therapy to control the serous detachment. Despite this, the condition progressed and was ultimately treated with plaque brachytherapy. Unfortunately, this resulted in an extensive retinal inflammation causing annular tractional retinal detachment which was treated with combined pars plana vitrectomy and scleral buckle.

**Conclusion:** We characterized the retinal phenotype of three patients with retinal focal nodular gliosis (vasoproliferative tumors) and found them to have varied clinical courses requiring tailored surgical management. The case associated with retinitis pigmentosa had a known pathogenic variant in *Crumbs homolog-1 (CRB1)* gene affecting retinal structure and exhibited a more severe clinical course. It is therefore important for patients with retinal dystrophies to undergo thorough peripheral examinations and detect FNG early as they may require prompt, aggressive treatment.

## Introduction:

Retinal focal nodular gliosis or vasoproliferative tumors are rare, benign disease entities that may occur as an idiopathic primary lesion (80%) or secondary tumors (in association with other ocular pathologies such as pars planitis, Coats disease, retinitis pigmentosa, familial exudative vitreoretinopathy and toxoplasmosis) and are thought to manifest as a result of gliosis and vascular proliferation [1,2]. They are usually characterized as pink to yellow vascular lesions with a predilection for the inferior retina and can produce an exudative and hemorrhagic retinopathy [3]. Secondary FNG tend to manifest at an earlier age of onset, are often bilateral and multifocal, and confer a poorer visual prognosis [1]. Complications associated with retinal FNG are extensive and can result in severe vision loss. These include lipid exudation, epiretinal membrane, cystoid macular oedema, vitreous hemorrhage, and tractional retinal detachment [1,3]. No standardized treatment for FNG is currently established but management options include photocoagulation, photodynamic therapy (PDT), cryotherapy, plaque radiotherapy, transscleral local resection [2]. Pars plana vitrectomy may be performed for complications associated with VPTs [4]. Herein, we describe the clinical features and management of three cases of retinal focal nodular gliosis, one without and two with retinitis pigmentosa phenotype. Each case needed tailored medical and surgical management, specific to their retinal phenotype. In particular, we found that the case with genetically confirmed *CRB1*-related retinopathy had the most complex clinical course requiring aggressive management and multiple surgical interventions.

## Case 1

A 76-year-old female was referred to the vitreoretinal service for a left epiretinal membrane (ERM) and vitreous hemorrhage with visual acuity of OD 20/25 and OS 20/160. She had a background of a stable inferior focal nodular gliosis (figure 1a) in the left eye and previously declined treatment with plaque radiotherapy. She was offered pars plana vitrectomy with epiretinal membrane peeling due to worsening metamorphopsia from ERM formation (figure 1b) without associated cystoid macular oedema and was noted to have a quiescent FNG in the inferior peripheral

retina. She underwent routine 25-gauge pars plana vitrectomy with epiretinal membrane and inner limiting membrane (ILM) peel and was noted to have a regressed FNG lesion intraoperatively (figure 1c). She remained stable 6-months postoperatively with best corrected visual acuity (BCVA) improving to 20/60 and no recurrence of ERM (figure 1d).

## Case 2

A 24-year-old female was referred to our genetics service for management of unilateral chronic cystoid macular oedema and an inferonasal retinal FNG. She had a known phenotypic resemblance of retinitis pigmentosa (RP) with peripheral bony spicule changes but no causative mutation found on whole genome testing. Visual acuity was OD 20/40 and OS 20/125. Examination demonstrated unilateral CMO in the left eye associated with two inferonasal peripheral retinal yellow-red lesions and localized exudation (figure 2a-d).

She underwent initial intravitreal dexamethasone implant (Ozurdex) for CMO and cryotherapy to the inferior VPT. 1 month post-operatively revealed good response to treatment with reduction of CMO and flat FNG lesions without exudate, with vision improving to 20/60 (figure 2e-f). 6 months post-operatively, lesions remained stable though there was evidence of mild recurrence of CMO with stable vision (figure 2g). The decision was made for conservative management with observation due to concurrent pregnancy. Review at 9 months post-cryotherapy showed further visual deterioration due to progressing cystoid macular oedema as well as peripheral exudation from the FNG. Management options including verteporfin photodynamic therapy (PDT), cryotherapy, and intravitreal steroids were offered. The patient proceeded with cryotherapy and intravitreal Ozurdex implant once she had given birth. A good response to treatment was shown with complete resolution of CMO and regression of the FNG (figure 2h-i), which was also confirmed on b-scan ultrasonography (figure 2j). BCVA remained at 20/60 due to the development of a small posterior subcapsular cataract.

## Case 3

A 28-year-old female is a case of recurrent chronic right eye CMO on a background of severe childhood onset retinal dystrophy secondary to confirmed pathogenic homozygous variants in *CRB1* and inferotemporal FNG lesion with Coats'-type phenotypic.

VA on presentation in 2014 was 20/80 OD with longstanding no light perception (NLP) vision OS from previous extensive serous detachment and subsequent anterior segment ischemia / pupillary block glaucoma (figure 3). Examination revealed a right localized inferior serous retinal detachment associated with an inferior vascular complex, vitreous cells, and CMO (figure 4a-b). Left eye showed a phthisical eye due to chronic retinal detachment.

She exhibited initial good control of CMO with acetazolamide alone (250mg daily), with a waxing and waning disease course of a 7-year period (from age 20 years old). In addition, she required periodic cryotherapy to the lesion and barrier laser retinopexy to control her inferior serous retinal detachment.

However, 7 years after initial presentation, due to worsening CMO associated with increasing peripheral engorgement and exudation and deteriorating vision to 20/100 in her right eye (figure 4c&e) medical therapy was escalated, and she received increasing doses of acetazolamide to 250mg twice daily for four months. In addition, she received two intravitreal anti-VEGF (bevacizumab 1.25mg/0.05mL) injections, 1 month apart. Despite this, the exudative detachment progressed with subsequent visual decline to hand movements (HM) and her tumor thickness was measured to be 3.7mm on b-scan ultrasonography. She was referred to our ocular oncology colleagues at this point and management options were discussed. Due to concerns that further cryotherapy may instigate a massive exudative response and PDT laser could potentially cause a tractional retinal detachment with tumor regression, she ultimately underwent plaque radiotherapy with further intravitreal bevacizumab to the lesion. This stabilized her fundal appearance (figure 4d), but concomitant post-radiation retinopathy and pan-ocular inflammation ensued with worsening CMO (figure 4f). The inflammation was treated with a course of systemic oral prednisolone (60mg daily) for

1 week, tapering by 10mg per week over 6 weeks, and topical dexamethasone 0.1% four times daily. The CMO continued to have a protracted course but was eventually mitigated with addition of sub-tenon triamcinolone 4 months after plaque brachytherapy, with improvement in both subjective visual acuity and OCT appearance after 4 weeks post sub-tenon triamcinolone.

At 14 months post brachytherapy, she developed progressive annular tractional retinal detachment involving the macula (figure 4g) in her right eye and was therefore offered further surgical intervention. A 25-gauge pars plana vitrectomy was performed with segmentation of her tractional membranes, cryotherapy to the tumor and endotamponade with sulfur hexafluoride (SF6). At routine 1-month post-operative review, she was found to have retinal redetachment due to reopening of an entry site break and underwent further 25-gauge pars plana vitrectomy with 276 circumferential scleral buckle and 240 encirclement, endolaser retinopexy, and 5000 centistoke silicone oil. 4-months post-vitrectomy (18-months post-brachytherapy), review showed successful retinal reattachment but significant peri-ocular and intraocular inflammation which were treated with high doses of oral prednisolone. Whilst the retina remained attached, she developed early and significant cataract and subsequently underwent phacoemulsification and intraocular lens insertion combined with silicone oil removal. 6 months post-vitrectomy the steroids were tapered off, there were no signs of clinical inflammation, and the retina was reattached with stable level of chronic cystoid macular oedema and HM vision. The patient's visual acuity and retinal appearance continued to be stable 1 year post retinal detachment surgery and 2 years post brachytherapy at her most recent clinical review (figure 4h).

## Discussion:

Our cases demonstrate the varied clinical course of retinal focal nodular gliosis (vasoproliferative tumors) and the need for tailored management based on visually threatening characteristics. In particular, the case of focal nodular gliosis secondary to *CRB1*-retinitis pigmentosa underwent a more complicated clinical course and required more aggressive treatment. Although there is no genetically confirmed variant of RP in case 2, the retina also exhibits early features of *CRB1*-related retinopathy, including retinal thickening and loss of lamination [5], so it is possible that this patient could also carry unknown pathogenic variants in *CRB1* gene.

Solitary primary retinal FNG as in case 1, tend to confer a better visual prognosis compared to secondary FNG (cases 2 and 3) with poor visual acuity of worse than 20/200 occurring in 15% compared to 28% in secondary tumors [1]. Epiretinal membranes remain a significant cause of visual loss in patients affected by FNG though the relationship between these tumors and the vitreomacular interface remain unclear [1,4]. Moreover, secondary ERMs are associated with worse visual outcomes and increased central macular thickness compared to idiopathic ERMs and should be observed more closely [6]. Although spontaneous avulsion of retinal FNG with resolution of ERM has been described [7], case 1 had persistent and progressive ERM despite involution of their FNG. This case demonstrated the role of pars plana vitrectomy in managing complications of a FNG that is otherwise quiescent. The role of ILM removal in addition to ERM removal remains uncertain in VPT-related ERMs but we found that peeling of both layers in this patient to be effective, without evidence of recurrence at 6 months post-operative review.

Retinitis pigmentosa (RP) accounts for up to 22% of eyes affected by secondary focal nodular gliosis and may even occur as the initial presentation of RP [1,8]. Whilst rare, exudative vasculopathies have been reported in association with RP and can manifest on a spectrum from retinal telangiectasias to focal nodular gliosis (vasoproliferative tumors) - the latter of which were demonstrated in cases 2 and 3 [9,10]. Both cases demonstrated a prolonged disease course with partial clinical regression of vasculopathy and exudation following laser photocoagulation and cryotherapy. Case 3 with *CRB1* variant exhibited a particularly aggressive retinal disease phenotype resulting in early loss of vision in the left eye due to neovascular glaucoma from chronic retinal detachment. Similarly, a combination of *CRB1*-retinopathy and VPTs led to a protracted disease course in the right eye, ultimately requiring radiotherapy treatment to VPTs. For this patient this unfortunately evoked a persistent uveitic response and more aggressive recurrence of tractional and serous peripheral retinal detachments which soon became macula threatening and required complex repair by surgical procedures via pars plana vitrectomy and tamponading with oil and encircling band. This aggressive

inflammatory response is likely to be linked to the underlying *CRB1* variants which can be associated with chronic inflammation [11,12].

*CRB1* gene encodes for a transmembrane protein that functions as cell polarity regulators and has a role in long-term retinal integrity, with mutations disrupting the spatiotemporal aspects of retinogenesis and resulting in retinal degeneration. In addition there are typical structural retinal changes including increased retinal thickness, loss of lamination and photoreceptor degeneration [5,11]. Pathogenic variants in *CRB1* account for up to 6.5% of patients with autosomal recessive RP and are implicated in the cause of a Coats-like manifestation of RP, as in case 3 [10]. Moreover, *CRB1* variants themselves have a predilection for CMO [11]. The protracted nature of the CMO in cases 2 and 3 implies that the cause of the macular oedema was due to the concurrent vasoproliferative tumor, but the underlying *CRB1* variation in case 3 is likely to have a predisposition for ocular inflammation and macular oedema and more likely to be refractory to simple management. A thorough peripheral search for these lesions should thus be performed in such presentations of unilateral CMO.

Despite notable advances in managing focal nodular gliosis (vasoproliferative tumors), secondary VPTs are known to confer a poorer prognosis [1] and remain a clinical challenge as there is still no consensus on management. Vision loss occurs owing to hemorrhagic and exudative sequelae as well as macular complications (epiretinal membrane formation, exudation and cystoid macular oedema) with end-stage disease culminating in neovascular glaucoma [1,13]. Peripheral small tumors with minimal exudation, as in case 1 and 2, can be effectively treated with laser therapy or cautious application of cryotherapy [13] with adjunctive pars plana vitrectomy for macular complications of epiretinal membrane. Larger FNG (>2mm) may be amenable to plaque radiotherapy (ruthenium<sup>106</sup> or iodine<sup>125</sup>) with several large case series showing regression of tumor size and exudation [2,14]. However, it is important to note that secondary FNG have been associated with poorer visual outcomes than primary FNG irrespective of tumor size when treated with I-125 plaque brachytherapy and therefore may explain the poor response for case 3, whose underlying *CRB1* mutation may have provided an impetus for ongoing exudation and retinal thickening refractory to treatment. PDT laser could be considered for these patients, although extensive exudation is more likely to be treatment resistant [13,14]. Therefore, early aggressive treatment for patients with FNG secondary to retinal dystrophies, particularly *CRB1* mutation, is recommended.

## Conclusion:

There is currently no consensus on the management of focal nodular gliosis (vasoproliferative tumors), which may be seen in patients with retinitis pigmentosa and can result in significant vision loss. The cases presented reiterate the need for a tailored management paradigm according to patient factors. More severe presentations may occur with FNG associated with inherited retinal dystrophies. In our series, FNG in the presence of *CRB1*-associated retinopathy led to a complicated clinical course with poor visual outcome.

## Statement of ethics

Ethical approval is not required for this study in accordance with local or national guidelines

Written informed consent was obtained from the patient for publication of the details of their medical case and any accompanying images.

## Conflicts of interest

None of the above authors have any conflicts of interests.

## Funding sources

The following authors receive funding from the following sources: MRC and NIHR Oxford BRC to JCK, NIHR Oxford BRC to REM.

## Author contributions

AI, MSS, REM, and JCK attest they meet the current ICMJE criteria for authorship and all were involved in the clinical care and management of these patients. AI wrote the manuscript with the consultation of MSS, REM, and JCK, all of whom provided critical feedback with regards to the review and editing of the manuscript.

### Data availability

All data generated or analyzed during this study are included in this article. Further enquiries can be directed to the corresponding authors.

### References

1. [Shields, C. L. et al. Retinal vasoproliferative tumors: comparative clinical features of primary vs secondary tumors in 334 cases. \*JAMA Ophthalmol.\* \*\*131\*\*, 328–334 \(2013\).](#)
2. [Heimann, H. et al. Vasoproliferative tumours of the retina. \*Br. J. Ophthalmol.\* \*\*84\*\*, 1162–1169 \(2000\).](#)
3. [Jain, K., Berger, A. R., Yucil, Y. H. & McGowan, H. D. Vasoproliferative tumours of the retina. \*Eye\* vol. 17 364–368 Preprint at <https://doi.org/10.1038/sj.eye.6700311> \(2003\).](#)
4. [Castro-Navarro, V., Saktanasate, J., Say, E. A. T., Chiang, A. & Shields, C. L. Role of pars plana vitrectomy and membrane peel in vitreomacular traction associated with retinal vasoproliferative tumors. \*Oman J. Ophthalmol.\* \*\*9\*\*, 167–169 \(2016\).](#)
5. [Daich Varela, M. et al. CRB1-Associated Retinal Dystrophies: Genetics, Clinical Characteristics, and Natural History. \*Am. J. Ophthalmol.\* \*\*246\*\*, 107–121 \(2023\).](#)
6. [Kim, D. I., Kim, B. H., Bae, K. W. & Park, U. C. Comparison of surgical outcomes after removal of epiretinal membrane associated with retinal break and idiopathic epiretinal membrane. \*Graefes Arch. Clin. Exp. Ophthalmol.\* \*\*260\*\*, 2121–2128 \(2022\).](#)
7. [McGrath, L. A. & Rundle, P. Spontaneous avulsion of a retinal vasoproliferative tumour with resolution of epiretinal membrane. \*Can. J. Ophthalmol.\* \*\*54\*\*, e173–e174 \(2019\).](#)
8. [Li, H. K., Shields, J. A., Shields, C. L., Maguire, J. I. & Garg, S. J. Retinal vasoproliferative tumour as the initial manifestation of retinitis pigmentosa. \*Clin. Experiment. Ophthalmol.\* \*\*36\*\*, 895–897 \(2008\).](#)
9. [Bromeo, A. J., Lerit, S. J., Veloso, A. & Mercado, G. J. Retinal vasoproliferative tumour secondary to retinitis pigmentosa sine pigmento. \*BMJ Case Reports\* vol. 14 e240878 Preprint at <https://doi.org/10.1136/bcr-2020-240878> \(2021\).](#)
10. [Magliyah, M. et al. Clinical spectrum, genetic associations and management outcomes of Coats-like exudative retinal vasculopathy in autosomal recessive retinitis pigmentosa. \*Ophthalmic Genet.\* \*\*42\*\*, 178–185 \(2021\).](#)
11. [Slavotinek, A. M. The Family of Crumbs Genes and Human Disease. \*Mol. Syndromol.\* \*\*7\*\*, 274–281 \(2016\).](#)
12. [Li, A. S. et al. CRB1-associated retinal dystrophy presenting as self-resolving opsochonus and posterior uveitis. \*Am J Ophthalmol Case Rep\* \*\*26\*\*, 101444 \(2022\).](#)
13. [Hussain, R. N., Jmor, F., Damato, B. & Heimann, H. Verteporfin Photodynamic Therapy for the Treatment of Retinal Vasoproliferative Tumors. \*Ophthalmology\* \*\*122\*\*, 2361–2363 \(2015\).](#)
14. [Cohen, V. M. L., Shields, C. L., Demirci, H. & Shields, J. A. Iodine I 125 plaque radiotherapy for vasoproliferative tumors of the retina in 30 eyes. \*Arch. Ophthalmol.\* \*\*126\*\*, 1245–1251 \(2008\).](#)

### Figures

Figure 1: **Phenotype and clinical management of case 1.** (a) Inferotemporal solitary retinal focal nodular gliosis / vasoproliferative tumor (denoted by black arrow) in the left fundus on presentation with unilateral epiretinal membrane secondary to the VPT shown in (b). (c) Quiescent inferior focal nodular gliosis after routine epiretinal membrane peel (d) with resolution of symptoms.

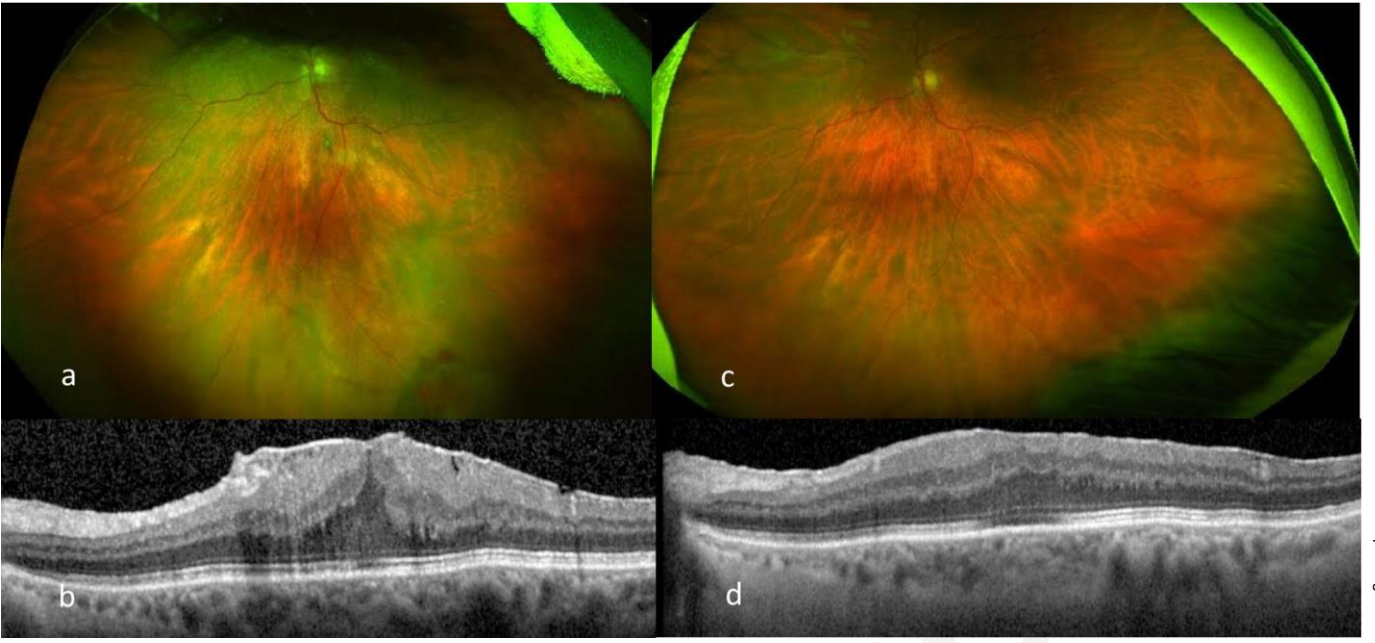
Figure 2: **Background of RP-like phenotype and clinical management of case 2.** (a)-(d) Presentation of unilateral CMO associated with inferior focal nodular gliosis OS (denoted by red arrows) on background of bilateral RP-like phenotype. (e)-(f) Attenuation of CMO 1 month post cryotherapy and dexamethasone intravitreal implant (Ozurdex). (g)

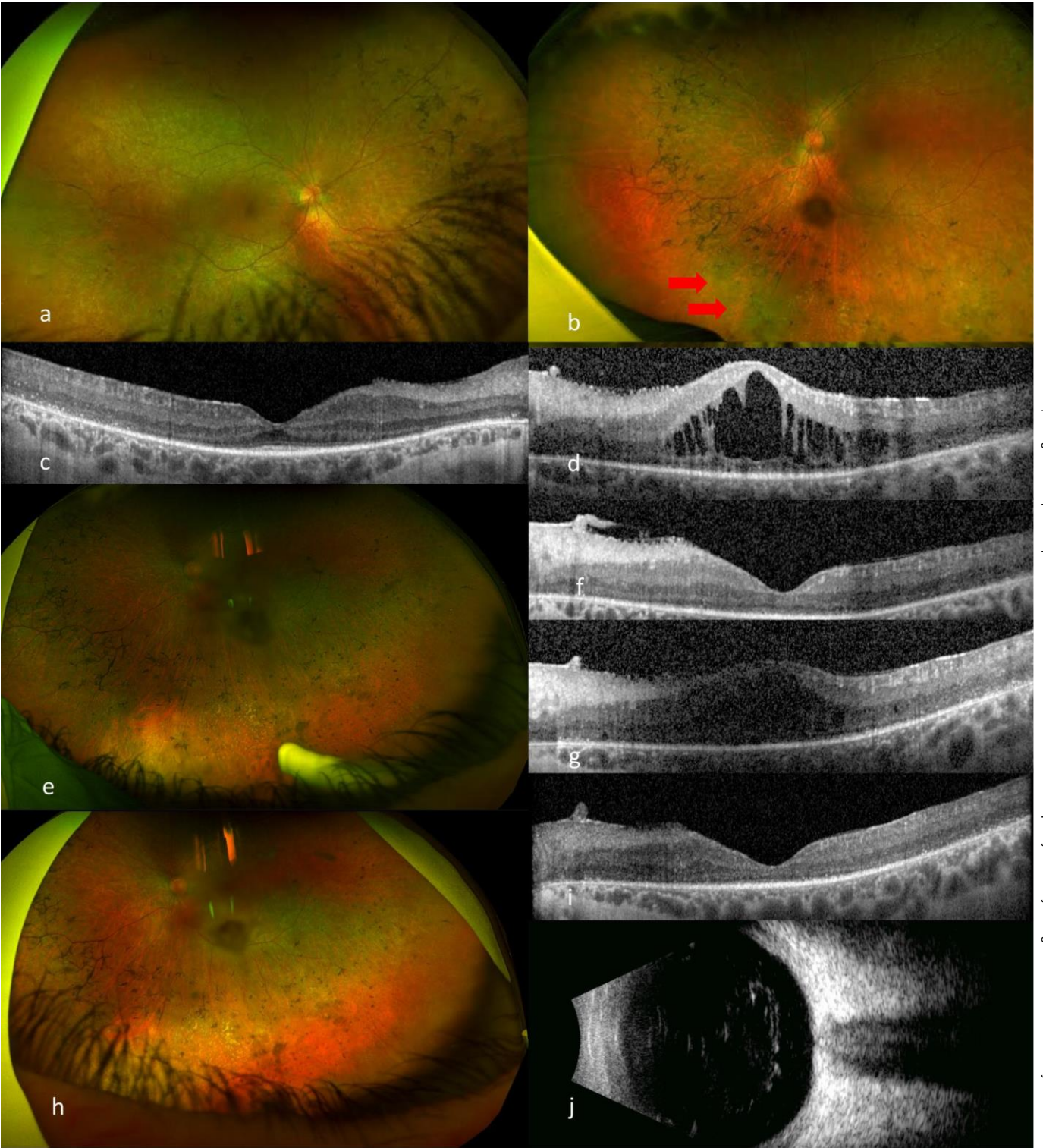Recurrence of CMO during pregnancy – no further treatment given during this period. (h)-(i) Resolution of CMO 3 months post cryotherapy and intravitreal Ozurdex after the patient had given birth, confirmed on ultrasonography (j).

Figure 3: **Timeline of clinical presentation and management of case 3.**

Figure 4: **Phenotype and clinical management of case 3.** (a) – (b) Presenting phenotype with right inferotemporal focal nodular gliosis associated with cystoid macular oedema. (c) & (e) Plaque radiotherapy was offered due to increasing peripheral engorgement and exudation from the FNG, associated with worsening CMO, 7 years post initial presentation. (d) & (f) Attenuated appearance of FNG lesion 2 months after plaque brachytherapy with persistent CMO due to concomitant post-radiation inflammation. (g) Development of progressive annular tractional retinal detachment with increasing macular oedema 14 months after brachytherapy. (h) Stable retinal appearance with improved appearance of chronic CMO 12 months after undergoing vitrectomy and scleral buckle with removal of silicone oil and 24 months post brachytherapy.







## 2014

Patient presented at age 20 years old with Coats-like phenotype on a known background of RP due to homozygous variants in *CRB1*.  
VA 20/80 OD and NLP OS from phthisis secondary to chronic RD

## 2015-2020

Presented with right localized inferior serous RD associated with inferior FNG. Waxing and waning course of CMO controlled by oral acetazolamide supplemented by periodic cryotherapy to the FNG.  
Barrier laser retinopexy given to control inferior RD.

## December, 2020

Worsening VA to 20/100 OD due to increasing CMO and peripheral exudative RD. Intravitreal bevacizumab administered, monthly, for 2 months with initial improvement in CMO.

## March, 2021

Stable CMO but enlarging peripheral exudative RD and deterioration in subjective VA despite bevacizumab. Referral made to ocular oncology colleagues.

## April, 2021

Underwent plaque brachytherapy with further intravitreal bevacizumab.

## August, 2021

Presented with 1 month of worsening vision to LP and eye pain since undergoing plaque brachytherapy. Clinical picture consistent with post-radiation inflammation/retinopathy with moderate anterior segment inflammation and worsening CMO. Oral prednisolone and topical dexamethasone commenced.

## October, 2021

Post-radiation inflammation/retinopathy unchanged. Subtenon triamcinolone administered and oral prednisolone regimen tapered. Subjective improvement in vision and symptoms 2 weeks after periorbital steroids.

## December, 2021

Good response to treatment. Improved pan-ocular inflammation and improvement of CMO.

## July, 2022

Development of combined tractional/exudative retinal detachment with early cataract development.

## October, 2022

Progression of retinal detachment requiring surgical intervention. Underwent pars plana vitrectomy and segmentation of tractional membranes with SF6 endotamponade. Developed redetachment 1 month after surgery, requiring further PPV and scleral buckle with silicone oil endotamponade.

## February, 2023

Stable retinal appearance with attached retina under oil and good indentation from scleral buckle but reduced subjective vision due to worsening cataract.

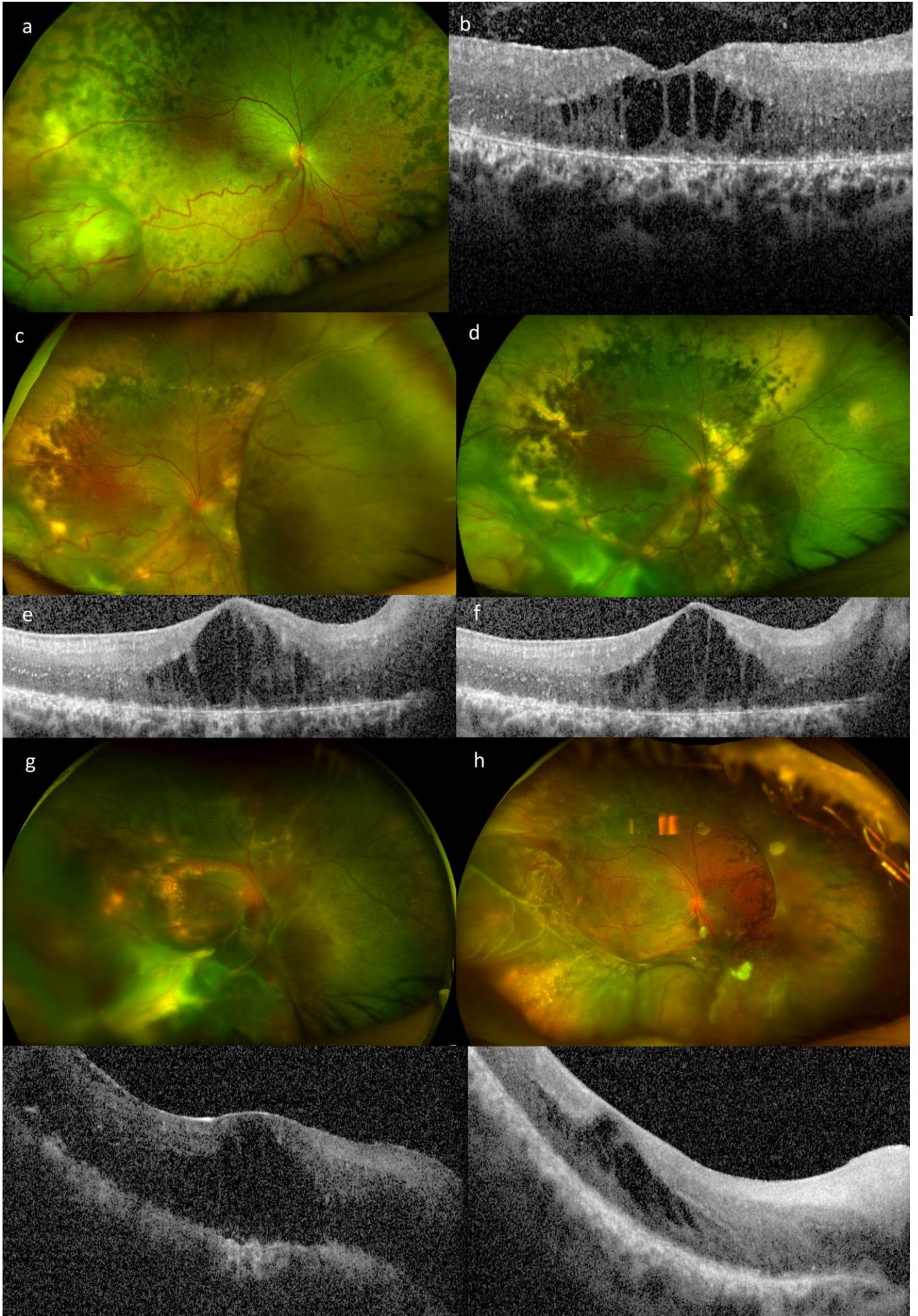
## March, 2023

Underwent routine cataract surgery (phacoemulsification and intraocular lens implant) with combined removal of silicone oil.

## January, 2024

Stable retinal appearance with attached retina and good indentation from scleral buckle with hand movements vision.





Accepted Manuscript