

RESEARCH ARTICLE

The role of bone remodeling in measuring migration of custom implants for large acetabular defects

Sara De Angelis¹  | Anna Di Laura^{1,2} | Angelika Ramesh¹ | Johann Henckel² | Alister Hart^{3,4}

¹Institute of Mechanical Engineering,
University College London, London, UK

²Royal National Orthopaedic Hospital NHS
Trust, Stanmore, UK

³Institute of Orthopaedics and
Musculoskeletal Science, University College
London, London, UK

⁴Cleveland Clinic London, London, UK

Correspondence

Sara De Angelis, Institute of Mechanical
Engineering, University College London,
London, UK.

Email: s.angelis@ucl.ac.uk

Abstract

In revision total hip arthroplasty, achieving robust fixation is difficult and implant movement may occur over time. Bone may also rearrange around the implant as a result of mechanical loading, making the measurement of migration challenging. The study aimed to quantify changes in bone shape and implant position 1 year following acetabular reconstruction using custom three-dimensional-printed cups. This observational retrospective cohort study involved 23 patients with Paprosky type IIIB defects. Postop computed tomography scans taken within 1 week of surgery and at 1-year postsurgery were co-registered and analyzed. Three co-registration strategies were implemented including bone-to-bone and implant-to-implant. (1) Co-registration of the ipsilateral innominate bone (diseased anatomy) was used to measure changes in implant position. (2) Co-registration of the implant was carried out to quantify changes in the ipsilateral innominate bone shape. (3) Co-registration of the contralateral innominate bone (nondiseased anatomy) was performed to measure changes in the ipsilateral innominate bone shape and implant position. The median centroid distances (interquartile range [IQR]) were 2.3 mm (IQR: 3.7–1.7 mm) for changes in implant position, 2.4 mm (IQR: 3.6–1.6 mm) for changes in ipsilateral innominate bone shape, and 3.7 mm (IQR: 4.6–3.5 mm) for changes in ipsilateral innominate bone shape and implant position. Following acetabular reconstruction, implant movements and periprosthetic bone remodeling are physiological and of a similar extent. Surgeons and engineers should consider this when performing implant monitoring in these patients.

KEYWORDS

acetabular defect, biomechanical bone remodeling, custom implants, implant migration, Paprosky IIIB defect

This is an open access article under the terms of the [Creative Commons Attribution](https://creativecommons.org/licenses/by/4.0/) License, which permits use, distribution and reproduction in any medium, provided the original work is properly cited.

© 2024 The Authors. *Journal of Orthopaedic Research*® published by Wiley Periodicals LLC on behalf of Orthopaedic Research Society.

1 | INTRODUCTION

Despite the advances in the design and additive manufacturing of custom implants, achieving robust fixation is challenging and revision rates remain high.^{1,2} The change in the bone's mechanical environment can lead to implant migration and/or bone remodeling. However, determining whether the bone is reorganizing, the implant is moving, or simply fitting onto the bone is challenging due to the irregular shape of the implant and the continuous fitting process. Therefore, controlled monitoring of these implants is essential for assessing their performance.

Radiostereometric analysis (RSA)³ is currently the gold standard for measuring early implant migration.^{4,5} This technique presents several limitations as it relies on the use of fiducial markers, its two-dimensional (2D) nature, the need for specialized experts and equipment and does not provide information on the bone anatomy.⁶ Computed tomography (CT)-based analysis has emerged as a promising approach for three-dimensional (3D) implant motion measurement and survival prediction.⁷⁻¹⁰ While bone density changes have been studied using dual-energy X-ray absorptiometry to assess bone-implant interactions,^{11,12} changes in bone morphology are also important factors to consider.

The aim of the study was to quantify changes in bone shape and implant position following acetabular reconstruction with custom 3D-printed cups. We employed image registration of 3D models generated from CT scans taken at two timepoints: during the first-week and 1-year postsurgery. The outcome measure was the centroid distance between (1) the implants and (2) the ipsilateral hemipelvises at the two timepoints.

2 | METHODS

2.1 | Study design and outcome measures

This single-center retrospective study used the immediate and 1-year postoperative CT scans of patients with Paprosky type IIIB defects,¹³ with or without discontinuity,¹⁴ who received a 3D-printed custom acetabular implant by a single manufacturer (ProMade, Lima Corporate).

The CT scans were rendered using specialized software (Simpleware ScanIP Medial, Version 2022.12; Synopsys Inc.) to produce 3D reconstructions of the patients' pelvis and implant at the two imaging timepoints. Bone-to-bone registration of the ipsilateral innominate bone was used to assess the change in implant position. Implant-to-implant registration was carried out to understand changes in the ipsilateral innominate bone. Bone-to-bone registration of the contralateral innominate bone was used to quantify changes in implant position and ipsilateral innominate bone shape. The study design is shown in Figure 1.

The outcome measure was the centroid distance between (1) the implants and (2) the ipsilateral hemipelvises at the two timepoints.

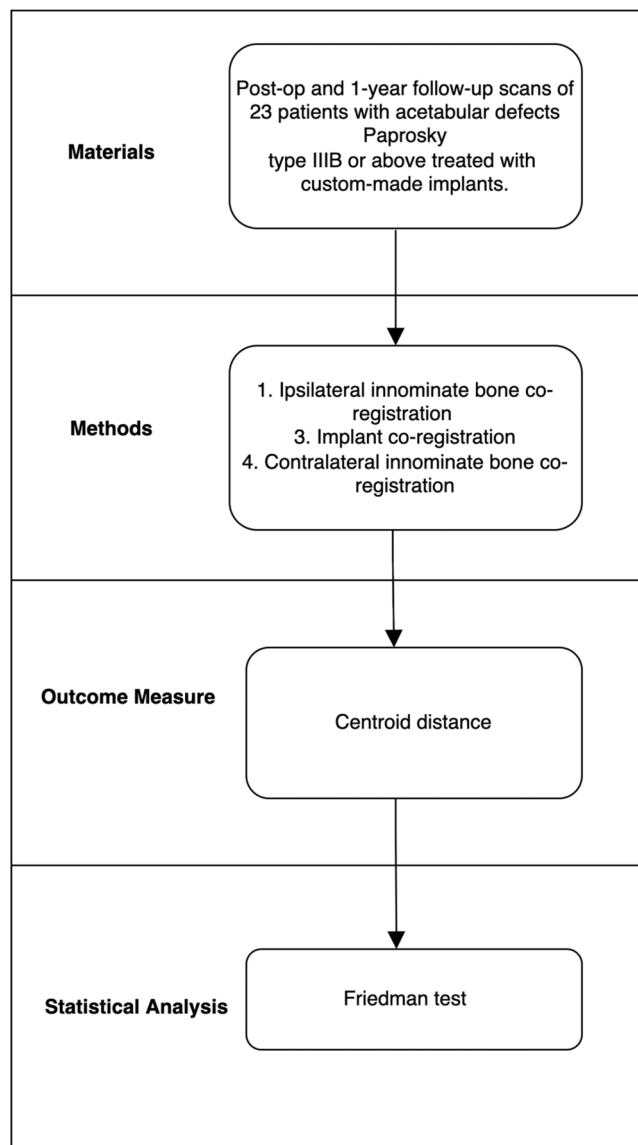


FIGURE 1 Study design.

2.2 | Data preparation

CT scanning of the pelvis was carried out for all patients during the first-week and 1-year postsurgery. Digital Imaging and Communications in Medicine files were imported into Simpleware ScanIP Medical (Version 2022.12; Synopsys Inc.) where intensity-based thresholding and region-splitting tools were implemented to create 3D reconstructions of the pelvises and implants.

2.3 | Radiological analysis

Preoperative pelvic radiographs were analyzed according to the DeLee–Charnley classification¹⁵ for location and extent of periprosthetic osteolysis.

CT images were evaluated by orthopedic surgeons and engineers with expertise in implant imaging to classify the data set between cases with and without pelvic discontinuity.

Bone-to-bone registration of the ipsilateral innominate side allowed to assess changes in implant position. Global rigid registration of the ilium, ischium, and pubis were implemented.¹⁶ A sphere matching technique was used to compute the center of rotation (CoR) of the 3D-printed custom-made acetabular components.^{17,18} The CoR displacement at the two timepoints was reported in three planes: X (mediolateral ML), Y (inferior-superior IS), and Z (anteroposterior AP), relative to the anterior pelvic plane (APP).¹⁹ Positive values corresponded to medial, superior, and anterior deviations. A diagram illustrating the above steps is shown in Figure 2.

To validate the results and investigate whether the ground around the implant was shifting, the metallic components were used as fiducials. Implant-to-implant registration of the 3D-printed custom-made component allowed us to assess the changes in bone shape.¹⁶ Three points were identified as the main anatomical landmarks on all ipsilateral innominate bones: anterior superior iliac spine, posterior superior iliac spine, and pubic tubercle; Figure 3. A plane was fitted

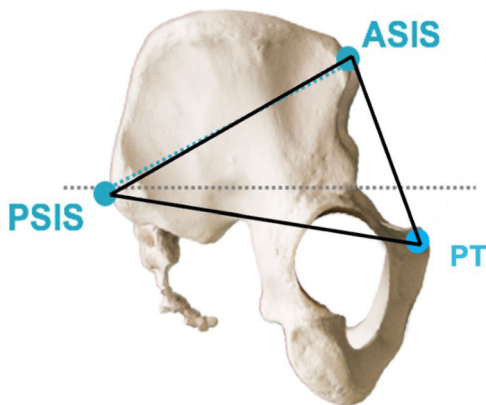


FIGURE 3 Three main anatomical landmarks of the innominate bone used for the analysis: anterior superior iliac spine (ASIS), posterior superior iliac spine (PSIS), and pubic tubercle (PT).

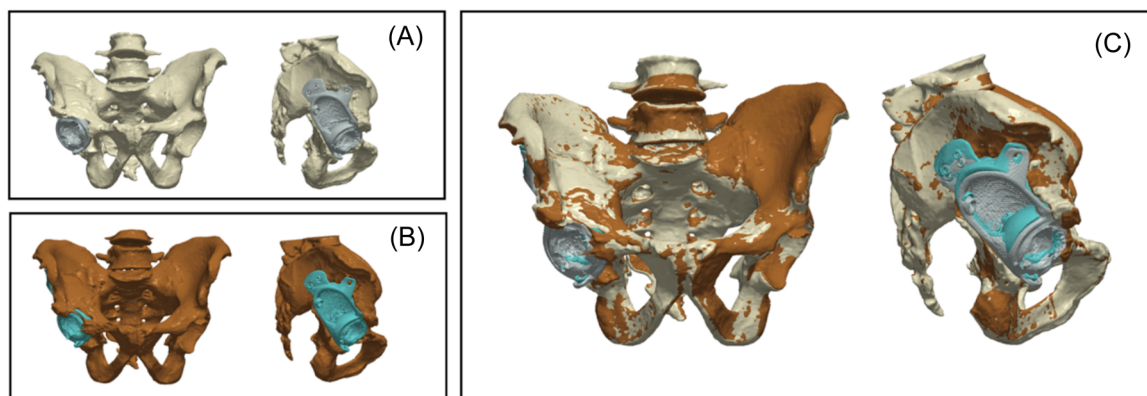


FIGURE 2 (A) Immediate postoperative pelvis and cup. (B) 1-year follow-up pelvis and cup. (C) Change in implant position at 1-year follow-up after bone-to-bone registration of the ipsilateral innominate bone.

onto the three landmarks of the ipsilateral innominate bone of each pelvis. The distance between the postoperative and 1-year follow-up ipsilateral hemipelvises' planes was calculated with respect to the APP.¹⁹ The relative movement of the ipsilateral hemipelvises over time was assessed. A visual representation of the workflow is illustrated in Figure 4.

In functional assessment, bone-to-bone registration of the contralateral innominate side was used to investigate changes in both implant position and ipsilateral innominate bone shape in relation to the other side. Global rigid registration of the contralateral innominate bone was implemented.¹⁶ Whenever the contralateral side presented with an implant, the acetabulum was excluded from the registration and only ischium, ilium, and pubis were co-registered. The sphere matching technique previously described was used to compute the CoR of the acetabular components.^{17,18} The CoR displacement at the two timepoints was then calculated. A diagram illustrating the above steps is shown in Figure 5.

The Jaccard index, or intersection over union (IoU), was used to evaluate the global rigid registration described in the section above. This metric is defined as the area of overlap between two objects divided by the area of union. IoU values range from 0 to 1, where 1 corresponds to a perfect overlap between the objects. If the IoU is ≥ 0.5 , the object detection is classified as true positive.²⁰ To measure similarities between the datasets, the IoU between (1) ipsilateral innominate bones, (2) implants, and (3) contralateral innominate bones at the two timepoints was calculated.

For completeness, AP radiographs were also visually inspected and the deviation in cup positioning was assessed preoperatively, during the first-week postsurgery and at 1-year follow-up.

2.4 | Statistical analysis

Statistical analysis was performed using GraphPad Prism (version 9.1; GraphPad Software).

A D'Agostino normality test was implemented to check if the population was normally distributed. As the data set resulted to be

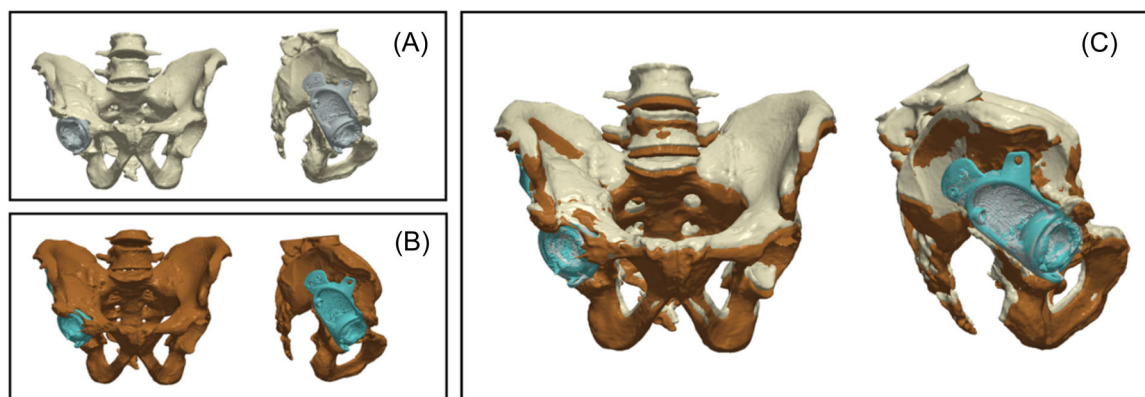


FIGURE 4 (A) Immediate postoperative pelvis and cup. (B) 1-year follow-up pelvis and cup. (C) Change in ipsilateral innominate bone shape at 1-year follow-up after implant-to-implant registration.

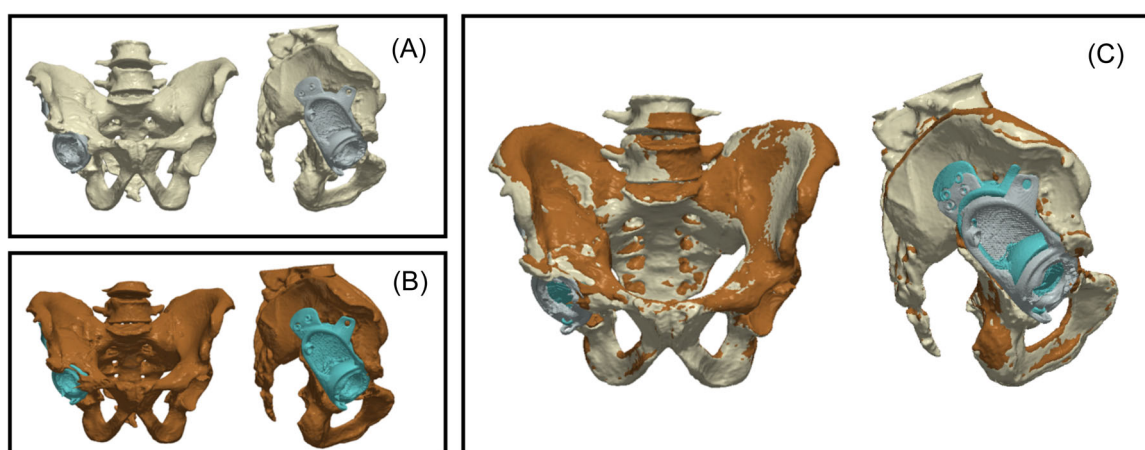


FIGURE 5 (A) Immediate postoperative pelvis and cup. (B) 1-year follow-up pelvis and cup. (C) Change in implant position and ipsilateral innominate bone shape at 1-year follow-up after bone-to-bone registration of the contralateral innominate side.

nonnormally distributed, a nonparametric paired Friedman test was performed to investigate the differences between the three groups. A significance level of 0.05 was used.

2.5 | Clinical outcome

Close patient monitoring was performed by the operating surgeon to record postoperative walking status and complications following the surgical procedure. Suspected migration based on the radiological criteria for loosening described by Gill et al.²¹ was also investigated.

3 | RESULTS

Twenty-three patients with Paprosky type IIIB defects were included in the study. The data set consisted of nine men (39%) and 14 women (61%). Pelvic discontinuity was detected preoperatively and confirmed intraoperatively following the removal of the failed acetabular component in three patients. Mean (range) follow-up was 68 months

(range: 33–92). The majority of the patients had a hip revised due to the loosening of the implant (65%). An overall summary of the characteristics of the patient cohort is displayed in Table 1.

3.1 | Radiological analysis

The median centroid distances (interquartile range [IQR]) were 2.3 mm (IQR: 3.7–1.7 mm) for changes in implant position, 2.4 mm (IQR: 3.6–1.6 mm) for changes in ipsilateral innominate bone shape and 3.7 mm (IQR: 4.6–3.5 mm) for changes in ipsilateral innominate bone shape and implant position. Figure 6 shows the changes in implant position for all cases that did not present with pelvic discontinuity. Figure 7 shows the changes in implant position for all cases that did present with pelvic discontinuity. The highest change in implant position at 1-year follow-up was reported to have a centroid distance of 6.3 mm. The medial deviation was 1.2 mm, the superior deviation was 4.0 mm and anterior deviation was 4.7 mm. Three cases describing no change, moderate change, and substantial change in implant position are displayed in Figure 8.

Changes in ipsilateral innominate bone shape for all cases with no pelvic discontinuity are shown in Figure 9. Figure 10 displays changes in ipsilateral innominate bone shape for cases with pelvic discontinuity. The highest change in ipsilateral innominate bone

shape had a centroid distance of 5.6 mm. Medial deviation was 4.7 mm, inferior deviation was 0.2 mm, and anterior deviation was 3.0 mm. Three cases describing no change, moderate change, and substantial change in ipsilateral innominate bone shape are displayed in Figure 11.

TABLE 1 Characteristics of the patient cohort.

Number of hips	23
Age (year)	
Mean	68
Median	70
Range	50–83
Sex	
Female	14 (61%)
Male	9 (39%)
BMI	
Mean	28
Median	26
Range	22–37
Side	
Right	16 (70%)
Left	7 (30%)
Hips with discontinuity	3 (13%)
Charnley classification	
I and II and III	20 (87%)
I and II	1 (4%)
N/A	2 (9%)
Reason for surgery	
Aseptic loosening	15 (65%)
Septic loosening	6 (26%)
Infection	1 (=4%)
Hip osteoarthritis with acetabular fracture (index surgery)	1 (=4%)

Note: Primary total hip arthroplasty and infection with well-fixed cup. Abbreviations: BMI, body mass index; N/A, not applicable.

Figures 12 and 13 illustrate changes in both implant position and ipsilateral innominate bone shape for cases without and with pelvic discontinuity, respectively. The highest change in implant position and ipsilateral innominate bone shape at 1-year follow-up was found to have a centroid distance of 9.7 mm. The medial deviation was 5.6 mm, the superior deviation was 7.8 mm, and anterior deviation was 1.5 mm. Figure 14 shows two cases that reported moderate and substantial changes in implant position and ipsilateral innominate bone shape.

The median IoU (IQR) was 0.3 (IQR: 0.5–0.3) for ipsilateral innominate bone co-registration, 0.8 (IQR: 0.9–0.8) for implant co-registration, and 0.3 (IQR: 0.6–0.3) the contralateral innominate bone co-registration.

Four cases (17%) showed changes in implant position. Ten cases (43%) reported changes in ipsilateral innominate bone shape. Changes in implant position and ipsilateral innominate bone shape were found in four cases (17%).

When examining the preoperative radiographs, 18 patients (78%) showed a superior migration of the failed acetabular cup, three

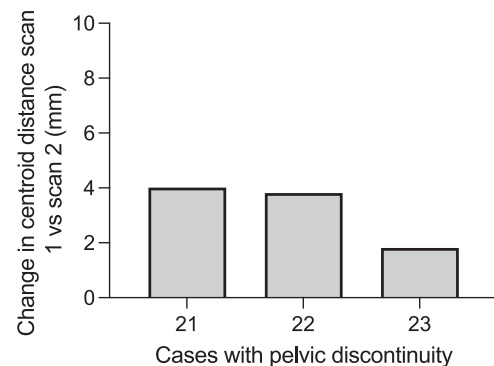


FIGURE 7 Changes in implant position following bone-to-bone registration of the ipsilateral innominate bone for cases with pelvic discontinuity.

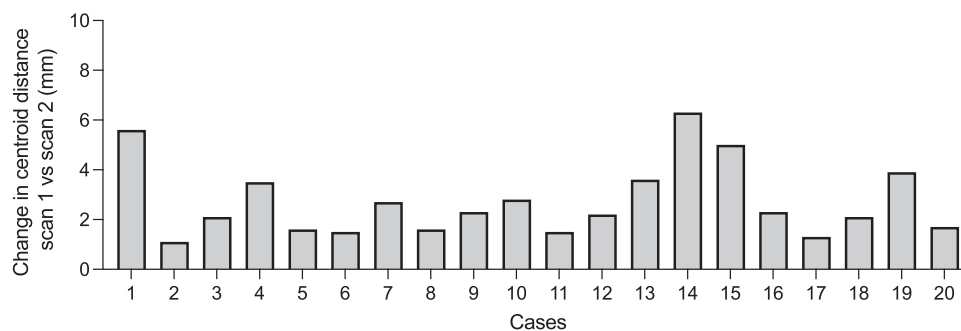


FIGURE 6 Changes in implant position following bone-to-bone registration of the ipsilateral innominate bone for cases without pelvic discontinuity.

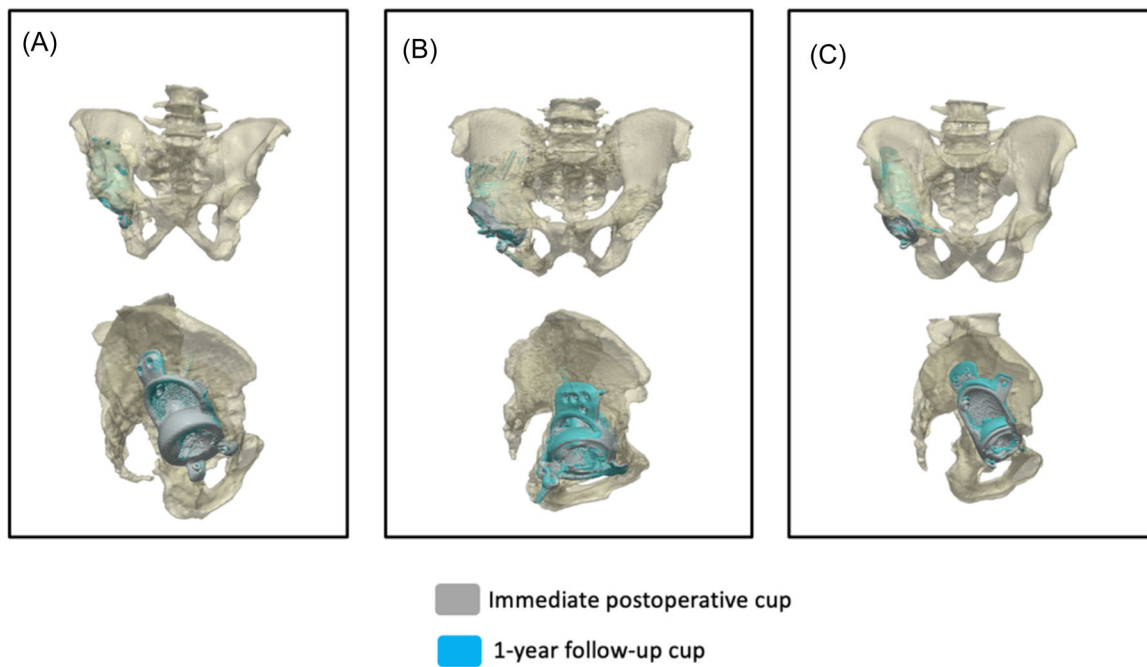


FIGURE 8 Cases showing (A) no change, (B) moderate change, and (C) substantial change in implant position.

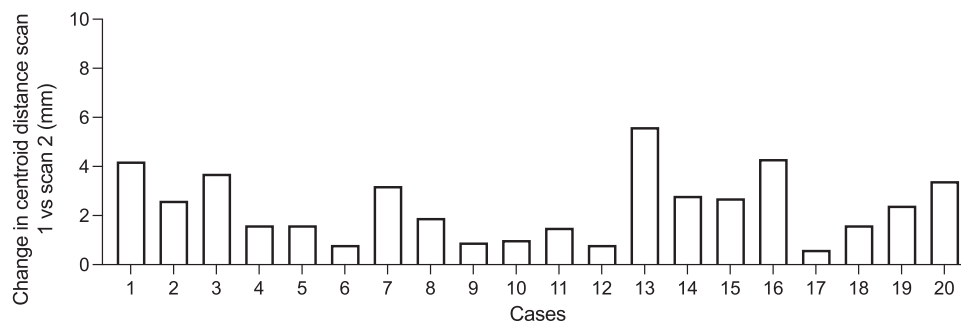


FIGURE 9 Changes in ipsilateral innominate bone shape following implant-to-implant registration for cases without pelvic discontinuity.

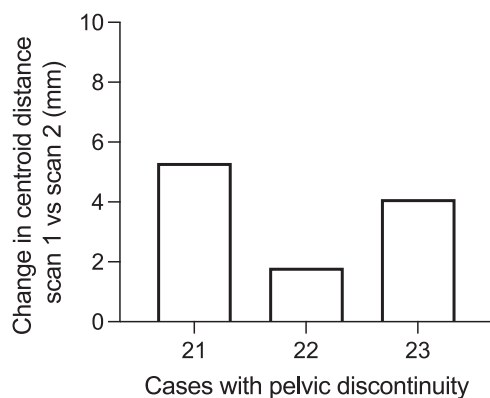


FIGURE 10 Changes in ipsilateral innominate bone shape following implant-to-implant registration for cases with pelvic discontinuity.

patients (13%) reported a medial migration of the failed implant, and one patient presented lateral migration of the component. Only one patient reported no major migration. The immediate postoperative radiographs showed restoration of the hip joint center in 10 cases (43%). A partial restoration was found in 10 other cases (43%). The remaining three cases reported a high CoR postsurgery. This was kept high to maximize bony fixation while accounting for low bone stock availability, and to avoid the risk of nerve injury. The deviation in CoR between the postoperative and the 1-year follow-up radiographs confirmed the 3D analysis performed on CTs.

3.2 | Statistical analysis

Friedman test ($\alpha = 0.05$) showed no statistical significance ($p > 0.9999$) between changes in implant position and changes in ipsilateral

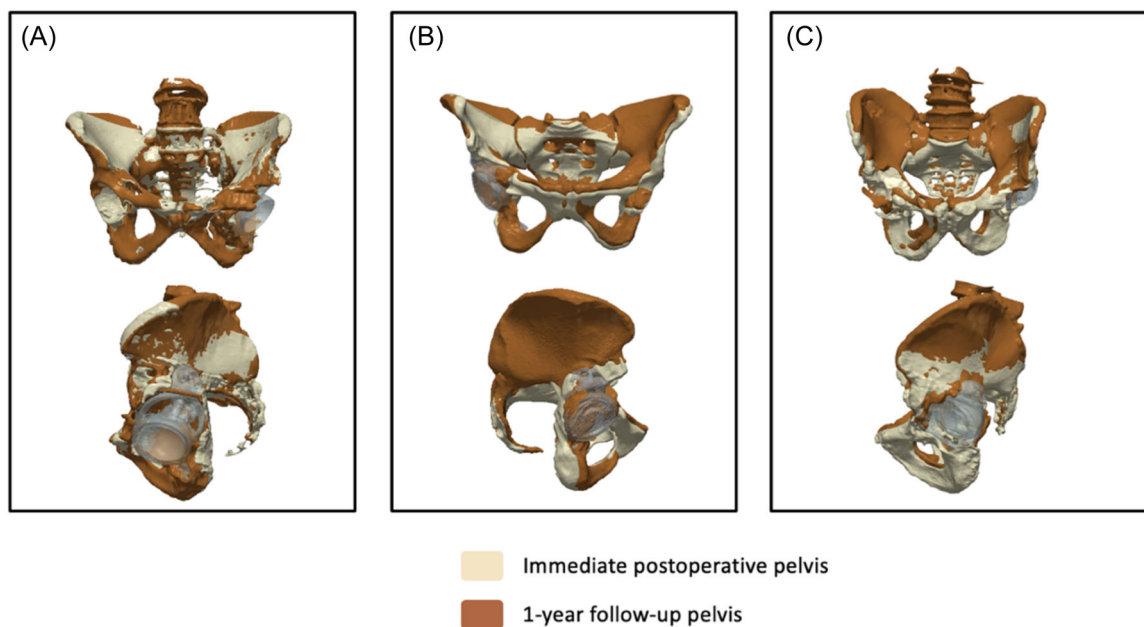


FIGURE 11 Cases showing (A) no change, (B) moderate change, and (C) substantial change of the ipsilateral innominate bone shape.

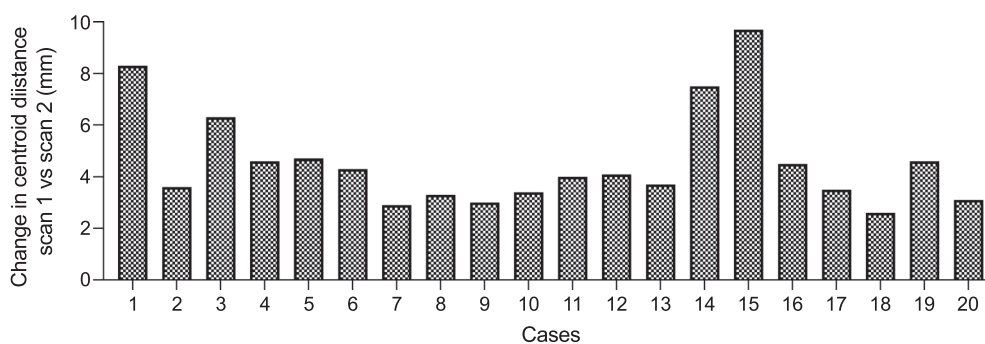


FIGURE 12 Changes in implant position and ipsilateral innominate bone shape following bone-to-bone registration of the contralateral innominate bone for cases without pelvic discontinuity.

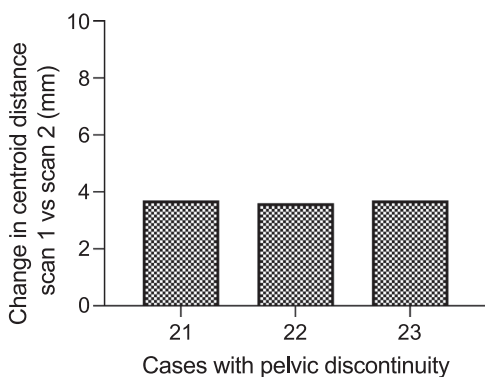


FIGURE 13 Changes in implant position and ipsilateral innominate bone shape following bone-to-bone registration of contralateral innominate bone for cases with pelvic discontinuity.

innominate bone shape. Statistical differences between changes in implant position and the cumulative change as well as between changes in ipsilateral innominate bone shape and the cumulative change were found. The *p* value was 0.0012 for both comparisons.

3.3 | Clinical outcome

An improvement in walking abilities was observed in 18 patients (78%), who required fewer mechanical aids for daily activities, while the remaining 5 (22%) continued using the same walking aids as before the surgery. One patient experienced a transient foot drop, which completely resolved 6 months after the operation. Post-operatively, two dislocations occurred but were successfully resolved through a closed reduction procedure. One patient developed an

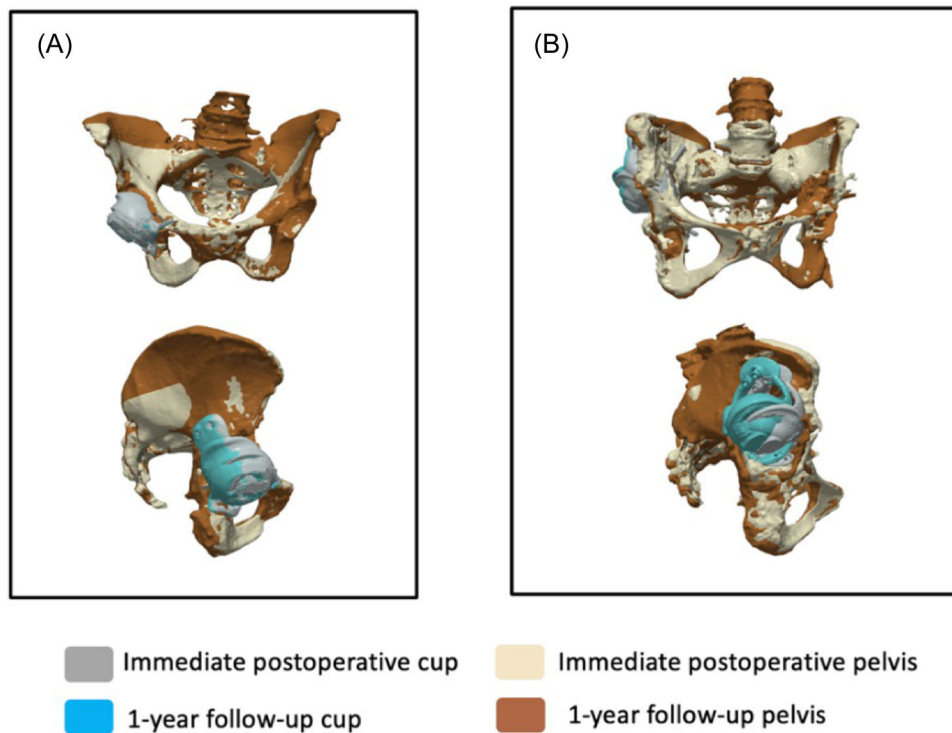


FIGURE 14 Cases showing (A) moderate change and (B) substantial change of implant position and ipsilateral innominate bone shape.

infection after surgery which was managed with antibiotic therapy. Two patients died for reasons unrelated to the hip 38 and 47 months after surgery.

Based on the radiological analysis, one case reported a superior migration of about 5 mm at 1-year follow-up compared to the immediate postoperative cup position. However, no significant movement has been observed thereafter, and currently, the implant remains in place.

4 | DISCUSSION

In the past few years, RSA has been the gold standard for measuring implant migration. However, RSA is limited to its reliance on fiducial markers, its 2D nature, and the need for specialized expertise and equipment. Additionally, RSA does not provide information on the bone anatomy, restricting the analysis to the movement of implants rather than the whole construct. CT analysis offers a promising 3D alternative to measure implant motion and predict their survival and failure mechanisms.^{7–10}

Brodén et al.^{7,8} compared the use of 3D CT analysis to measure the migration of acetabular cups to standard RSA and determined its clinical precision using a plastic pelvic model and a cohort of patients, respectively. Scheerlinck et al.⁹ validated CT-based detection of implant migration by comparing CT measurements to a mechanical model. CT imaging proved to have accuracy and precision comparable to that of RSA. Zampelis and Flivik¹⁰ measured the CoRs of the postoperative and 1-year follow-up CT scans of 10 patients with

custom-made 3D-printed implants. The median migration was found to be -0.08 mm in the AP plane, 0.14 mm in the ML plane, and 0.06 mm in the SI plane. While there are studies investigating implant migration, the movement of the bone in correlation with the migration of acetabular implants for large acetabular defects has not yet been explored. According to Wolff's law,²² the bone adapts to the loads under which it is placed. Bone can reorganize to respond to the loading or stress that is applied onto it.²³ Following hip replacement, the high stiffness of the implants can result in a loss of bone density, known as stress shielding.²⁴ Laursen et al.¹¹ investigated the bone mineral density changes in different regions of interest between cementless HA and non-HA coated cups using a dual-energy X-ray absorptiometer. The same technique was used by Anderl et al.¹² to evaluate the bone density changes around uncemented monoblock acetabular cups.

While the above studies focus on changes in bone mineral density, our study explores how changes in the morphology of the ipsilateral innominate bone can also occur. The measurement of implant migration is affected by changes in the bony structure, and these should, therefore, be considered when monitoring the position of custom implants for large acetabular defects over time. The highest change in implant position at 1-year follow-up was reported to have a centroid distance of 6.3 mm. The highest change in ipsilateral innominate bone shape had a centroid distance of 5.6 mm. The highest change in implant position and ipsilateral innominate bone shape at 1-year follow-up was found to have a centroid distance of 9.7 mm. As no statistical significance was found between changes in implant position and

changes in ipsilateral innominate bone shape, the two groups were found to have a similar trend.

Ten cases (43%) reported changes in ipsilateral innominate bone shape. Four cases (17%) showed changes in implant position. Cumulative changes in implant position and ipsilateral innominate bone shape were found in four cases (17%). All patients with pelvic discontinuity fell within the four cases reporting changes in ipsilateral innominate bone shape. An IoU value < 0.5 was seen when evaluating their ipsilateral innominate bone co-registration. This was expected as they present with extensive bone loss and missing columns which affect their bone mechanical stability.

Nevertheless, this study presents some limitations. First, the periprosthetic bony change could not be confidently quantified due to the presence of metal artefacts. As an accurate segmentation of the bony areas around the implant could not be generated due to metal artefacts, those regions were not included in the bone-to-bone co-registration. Second, as the co-registration was performed using regional painting and landmark selection, correspondence mismatch errors might have occurred during the process. Finally, when co-registering the contralateral innominate bone to assess changes in implant position and ipsilateral innominate bone shape, we assumed no sacroiliac joint or pubic symphysis movement.

5 | CONCLUSION

This is the first study that aimed to investigate how changes of the bone affect the measurement of the migration of custom implants for large acetabular defects. When performing CT implant monitoring in patients with large acetabular defects, changes of the ipsilateral innominate bone can occur over time. It is challenging to accurately quantify implant migration when the bone is remodeling. The study revealed how the reorganization of the bone affected the implant migration results in those cases for which the co-registration of the ipsilateral innominate bone was poor. It was also shown how the contralateral innominate side could be seen as a reflection of what was occurring on the ipsilateral innominate side. By co-registering the contralateral innominate bone, we were able to assess changes in both implant position and ipsilateral innominate bone shape. Therefore, bone remodeling needs to be considered to confidently report how much implants migrate over time.

Following acetabular reconstruction, implant movements and periprosthetic bone remodeling are physiological and appear to have the same extent. Surgeons and engineers should consider this when performing implant monitoring/surveillance in these patients.

AUTHOR CONTRIBUTIONS

Sara De Angelis, Anna Di Laura, Angelika Ramesh, Johann Henckel, and Alister Hart contributed to the study design. Sara De Angelis, Anna Di Laura, Angelika Ramesh, Johann Henckel, and Alister Hart contributed to data acquisition and analysis. Sara De Angelis,

Anna Di Laura, Angelika Ramesh, Johann Henckel, and Alister Hart contributed to the interpretation of data. Sara De Angelis, Anna Di Laura, and Johann Henckel wrote the first draft of the manuscript. Sara De Angelis, Anna Di Laura, Angelika Ramesh, Johann Henckel, and Alister Hart edited the manuscript. All authors have read and approved the final submitted manuscript.

ACKNOWLEDGMENTS

Our Institution receives funding from the Arthroplasty for Arthritis Charity, The Maurice Hatter Foundation, the Royal National Orthopaedic Hospital Charity, the Rosetrees Trust, the Stoneygate Trust, and the University College London Hospitals Biomedical Research Center. No specific funding was received in support of this project.

ORCID

Sara De Angelis  <http://orcid.org/0000-0002-2721-7694>

REFERENCES

- Garellick G, Kärrholm J, Rogmark C, Herberts P. Swedish hip arthroplasty register: annual report. 2012. Department of Orthopaedics, Sahlgrenska University Hospital.
- Gross AE, Goodman S. The current role of structural grafts and cages in revision arthroplasty of the hip. *Clin Orthop Relat Res.* 2004;429:193-200.
- Bottner F, Su E, Nestor B, Azzis B, Sculco TP, Bostrom M. Radiostereometric analysis: the hip. *HSS J.* 2005;1(1):94-99.
- Mjöberg B. Theories of wear and loosening in hip prostheses: wear-induced loosening vs. loosening-induced wear. *Acta Orthop Scand.* 1994;65:361-371.
- Mjöberg B. The theory of early loosening of hip prostheses. *Orthopedics.* 1997;20:1169-1175.
- Kaptein BL, Valstar ER, Stoel BC, Rozing PM, Reiber JHC. A new type of model-based Roentgen stereophotogrammetric analysis for solving the occluded marker problem. *J Biomech.* 2005;38(11):2330-2334.
- Brodén C, Olivecrona H, Maguire, Jr. GQ, Noz ME, Zeleznik MP, Sköldenberg O. Accuracy and precision of three-dimensional low dose CT compared to standard RSA in acetabular cups: an experimental study. *BioMed Res Int.* 2016;2016:5909741.
- Brodén C, Sandberg O, Sköldenberg O, et al. Low-dose CT-based implant motion analysis is a precise tool for early migration measurements of hip cups: a clinical study of 24 patients. *Acta Orthop.* 2020;91:260-265.
- Scheerlinck T, Polfliet M, Deklerck R, Van Gompel G, Buls N, Vandemeulebroucke J. Development and validation of an automated and marker-free CT-based spatial analysis method (CTSA) for assessment of femoral hip implant migration in vitro accuracy and precision comparable to that of radiostereometric analysis (RSA). *Acta Orthop.* 2016;87:139-145.
- Zampelis V, Flivik G. Custom-made 3D-printed cup-cage implants for complex acetabular revisions: evaluation of pre-planned versus achieved positioning and 1-year migration data in 10 patients. *Acta Orthop.* 2020;92(1):23-28.
- Laursen MB, Nielsen PT, Søballe K. Bone remodelling around ha-coated acetabular cups: a DEXA study with a 3-year follow-up in a randomised trial. *Int Orthop.* 2007;31(2):199-204.
- Anderl C, Mattiassich G, Ortmaier R, Steinmair M, Hochreiter J. Peri-acetabular bone remodelling after uncemented total hip arthroplasty with monoblock press-fit cups: an observational study. *BMC Musculoskelet Disord.* 2020;21(1):652.

13. Paprosky WG, Perona PG, Lawrence JM. Acetabular defect classification and surgical reconstruction in revision arthroplasty. A 6-year follow-up evaluation. *J Arthroplasty*. 1994;9:33-44.
14. Berry DJ, Lewallen DG, Hanssen AD, Cabanela ME. Pelvic discontinuity in revision total hip arthroplasty. *J Bone Joint Surg Am*. 1999;81(12):1692-1702.
15. DeLee JG, Charnley J. Radiological demarcation of cemented sockets in total hip replacement. *Clin Orthop Relat Res*. 1976;121:20-32.
16. Oliveira FPM, Tavares JMRS. Medical image registration: a review. *Comput Methods Biomech Biomed Engin*. 2014;17:73-93.
17. Durand-Hill M, Henckel J, Satchithananda K, et al. Calculating the hip center of rotation using contralateral pelvic anatomy. *J Orthop Res*. 2016;34:1077-1083.
18. Ehrig RM, Taylor WR, Duda GN, Heller MO. A survey of formal methods for determining the centre of rotation of ball joints. *J Biomech*. 2006;39:2798-2809.
19. Murray D. The definition and measurement of acetabular orientation. *J Bone Joint Surg Br*. 1993;75(2):228-232.
20. Evaluation metrics. neuralception.com. 2023.
21. Gill TJ, Sledge JB, Müller ME. The Burch-Schneider anti-protrusion cage in revision total hip arthroplasty: indications, principles and long-term results. *J Bone Joint Surg Br*. 1998;80(6):946-953.
22. Hm F. Law and bone's structural adaptations to mechanical usage: an overview for clinicians. *Angle Orthod*. 1994;64(3):175-188.
23. Goharian A. Conception of osseointegration in development of orthopedic implant industry. *Osseointegration of Orthopaedic Implants*, Academic Press. 2019:163-183.
24. Millis DL. Responses of musculoskeletal tissues to disuse and remobilization. In: Millis D, Saunders LD, eds. *Canine Rehabilitation & Physical Therapy*. 2004:113.

How to cite this article: De Angelis S, Di Laura A, Ramesh A, Henckel J, Hart A. The role of bone remodeling in measuring migration of custom implants for large acetabular defects. *J Orthop Res*. 2024;1-10. doi:10.1002/jor.25818