

A semi-automatic tool for thigh muscle segmentation

Mehran Azimbagirad^{1,2,*}, Guillaume Dardenne^{2,3}, Douraid Ben Salem^{2,3},
Eric Stindel^{1,2,3}, Olivier Rémy-Néris^{2,3} and Valérie Burdin^{2,4}

¹ Faculty of Medicine and Health Sciences, University of Western Brittany, Brest, France;

² Laboratory of Medical Information Processing (LaTIM), UMR1101 INSERM, Brest, France;

³ Centre Hospitalier Régional et Universitaire (CHRU) de Brest, France

⁴ IMT Atlantique, Brest, France

* Corresponding author: mehran.azimbagirad@univ-brest.fr

Abstract

In order to follow up volume changes of thigh muscles in either disorders or muscle therapy treatments, several segmentation methods have been introduced. Since the accuracy of such methods is crucial to assess muscle reconstruction, we introduced a semi-automatic tool to segment thigh muscles with the required accuracy. The tool segments each muscle in three steps. First, a few slices are annotated for each muscle. Then, all of these annotated contours are automatically connected using spline interpolation in both transversal and longitudinal directions. Finally, using morphological and image processing techniques, each 3D muscle is reconstructed in order to further analyze their volumes. The accuracy and executing time of this method are compatible with the clinical requirements.

1 Introduction:

The detection of changes in shape (volume, surface, diameter) or texture in muscles can be used to diagnose disease and follow up the impact of rehab exercises or even a treatment plan [1]. Measuring these changes using imaging techniques requires a segmentation step. The gold standard method is manual for the muscle segmentation in MRI images, but it is a hugely time-consuming task. Besides, although automatic segmentation methods [2] for thigh muscles are still an active research topic which will be very useful for a clinical integration, state-of-the-art methods are not usable today because of their lack of accuracy and precision especially for pathological cases [3]. Then it is pertinent to propose a semi-automatic approach.

Generally, semi-automatic segmentation for thigh muscles includes; i) manual label of a few cross-sections area of the MRI volume, and ii) image processing or computer vision techniques to automatically label the whole thigh muscles. There are several studies in which they proposed such methods [4-6]. Although the accuracy of recent methods has been improved, an accurate enough, reliable and easy-to-use tool is still needed in order to be exploited in clinical routine. In this work a 3D slicer¹ [7] module was developed providing a semi-automatic segmentation of

muscles using a combination of mathematical morphology, registration, graph structure and image processing techniques.

2 Methods

Five healthy subjects were invited to scan their thighs using a 3.0 Tesla scanner Philips, Elition X (T1 sequence) (As part of the ethical protocol n° 2019-A01703-54 respecting the Declaration of Helsinki). Seven muscles from each thigh were selected: the Rectus Femoris, Vastus Lateralis, Vastus Intermedius, Vastus Medialis, Biceps Short Head, Semitendinosus and Semimembranosus. The proposed semi-automatic method includes three steps (one manual and two automatic) as following:

- Step 1.** An operator has to manually annotate a few slices for each targeted muscle that we want to segment. An interslice distance inferior to 30 mm between each successive contours pair is recommended to get the highest accuracy at the end of the process.
- Step 2.** All annotated spaced contours are then automatically connected using spline interpolation in both transversal and longitudinal directions.
- Step 3.** Finally, all the interpolated contours are filled by mathematical morphology [8] to obtain the entire segmented volume of each muscle and the mesh is extracted using the marching cube algorithm [9].

For evaluation, an experienced operator (5 years) segmented each slice of data for the same muscles. These fully manual annotations are considered as gold standard method or ground truth (GT). As a baseline, we used the Albu's method, namely "SDF", a well-known semi-automatic segmentation method based on Morphological Contour Interpolation [4]. We used 3 metrics, i.e., the Dice Coefficient (DICE), Hausdorff Distance (HD) and Absolute Volume Distance (AVD), in order to quantitatively compare the accuracy of each method (our Spline method and SDF) versus the GT.

3 Results

Fig. 1 shows an example of thigh muscle segmentation using our tool in Slicer software.

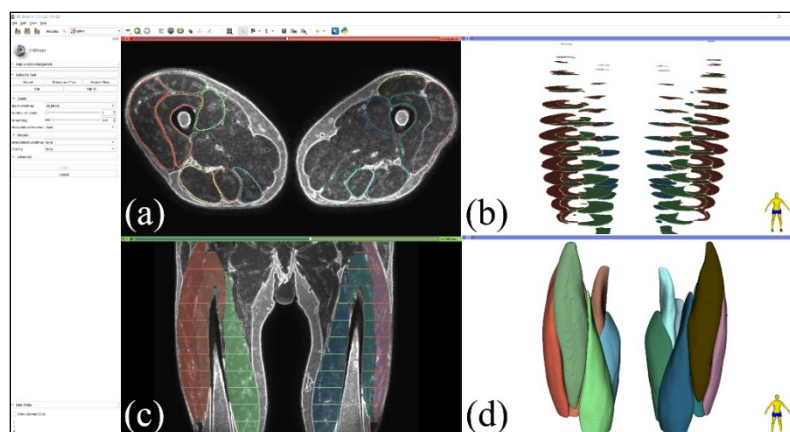


Figure 1. Our tool interface in 3D Slicer, a) manual segmentation (contours), b) 3D view of manual labels before interpolation, c) Frontal view after automated interpolation of muscle regions, d) 3D reconstructed volume of thigh muscles.

¹ www.slicer.org

For the evaluation, we used our tool and SDF method to segment 14 muscles (7 right thigh and 7 left thigh) in 5 patients. Table 1 shows the results comparing our method (Spline) and Albu's one (SDF), both evaluated with regard to the manual ground truth (GT) using the above metrics.

Table 1. Reconstruction errors between our Spline method vs manual GT and, SDF vs manual GT, including 14 thigh muscles of 5 subjects.

Metrics	Method	Mean	STD
DICE [0-1] +	Our method	0.996	0.001
	SDF	0.958	0.007
HD* (mm) –	Our method	4.868	1.830
	SDF	6.094	2.179
AVD** (cm ³) –	Our method	2.975	1.938
	SDF	4.984	5.219

* Hausdorff Distance + better if higher value

** Absolute Volume Distance – better if lower value

4 Discussion

We provided a module for 3D Slicer platform based on the proposed method, i.e., spline semi-automatic segmentation. This module has a user-friendly interface which needs only a few slices to be manually annotated. We used our method to segment 7 thigh muscles in MRI and we compare it with regard to SDF method also including both manual and automatic steps. The most time-consuming part is manual and depends on each muscle and how many slices we select (10 minutes (20mn) for 10 contours (30) on 7 muscles). The automatic part adds 2 minutes more for our method (30 seconds for SDF). Then, the entire segmentation time for 7 thigh muscles is approximatively the same in both methods.

Although the DICE is very high for both methods, Hausdorff Distance and Absolute Volume Distance were improved with our proposed method compared to SDF [4]. Furthermore, standard deviations of all our scores were lower, meaning that the precision was improved, especially for the volume estimation.

One limitation of our method is that the manual phase is still time consuming. Although the needed time could be reduced by increasing the distance between each annotated slice, this can impact the accuracy. This study is in progress.

Our tool can be used for other muscle systems and/or organs with considering a proper interslice distance. For example, for small structures such as shoulder muscle, 10 mm interslice might be an efficient choice while for femur it might exceed 40 mm. In the next step, we will reconstruct such muscle data to assess the generalizability of our tool.

References

1. Azimbagirad, M., et al. *Combined multi-protocols qMRI for thigh muscle analysis: a preliminary study*. in *Proc.SPIE*. 2021.
2. Boutillon, A., et al. *Multi-task, Multi-domain Deep Segmentation with Shared Representations and Contrastive Regularization for Sparse Pediatric Datasets*. in *Medical Image Computing and Computer Assisted Intervention MICCAI 2021*. 2021. Springer International Publishing.
3. Pons, C., et al., *Quantifying skeletal muscle volume and shape in humans using MRI: A systematic review of validity and reliability*. PLOS ONE, 2018. **13**(11): p. 1-26.

4. Albu, A.B., T. Beugeling, and D. Laurendeau, *A Morphology-Based Approach for Interslice Interpolation of Anatomical Slices From Volumetric Images*. IEEE Transactions on Biomedical Engineering, 2008. **55**(8): p. 2022-2038.
5. Jolivet, E., et al., *Skeletal muscle segmentation from MRI dataset using a model-based approach*. Computer Methods in Biomechanics and Biomedical Engineering: Imaging & Visualization, 2014. **2**(3): p. 138-145.
6. Azimbagirad, M., et al. *Towards the definition of a patient-specific rehabilitation program for TKA: A new MRI-based approach for the easy volumetric analysis of thigh muscles* ^{*}_{*}. in *43rd Annual International Conference of the IEEE Engineering in Medicine & Biology Society (EMBC)*. 2021.
7. Pieper, S., et al. *3D slicer as an open platform for the medical image computing community*. in *3rd IEEE International Symposium on Biomedical Imaging: Nano to Macro*. 2006.
8. scipy.org. *Fill the holes in binary objects*. 2015 [cited 2019; Available from: https://docs.scipy.org/doc/scipy-0.15.1/reference/generated/scipy.ndimage.morphology.binary_fill_holes.html].
9. Lorensen, W.E. and H.E. Cline, *Marching cubes: A high resolution 3D surface construction algorithm*, in *Proceedings of the 14th annual conference on Computer Graphics and Interactive Techniques*. 1987, Association for Computing Machinery. p. 163–169.