



European
Reference
Network

for rare or low prevalence
complex diseases

 Network

Eye Diseases (ERN-EYE)

NMO and MOG Optic Neuritis



UCL

Groningen

01-JUN-2023, 11:00-11:20

axel petzold

Expertisecentrum Neuro-ophthalmology AUMC

Disclosures



3-6 JUNE 2024
ROTTERDAM
THE NETHERLANDS

EUNOS

NIHR UK

Zeiss (OCTA, ANGI)

UCSF (RECOVER trial)

Stichting MS Research NL

Heidelberg Academy (speaker)

Amsterdam UMC (RESTORE trial*)

Novartis (SC OCTiMS, QC PASSOS)

The Moorfields Biomedical Research Centre

*Sam Hof: s.n.hof@amsterdamumc.nl



UCL

Expertisecentrum Neuro-ophthalmology AUMC



Overview

- Background: from MS to MOG & NMO
- International view
- Differential diagnoses
- Diagnosis and treatment of NMO-ON & MOG-ON
- Conclusion





Background

- When do we need a syndromic definition of a disease?
 - In absence of a diagnostic test
- Multiple Sclerosis diagnosis:
 - DIS & DIT
- New diagnostic tests
 - AQP4 antibodies
 - MOG antibodies





Syndromic definition of MS

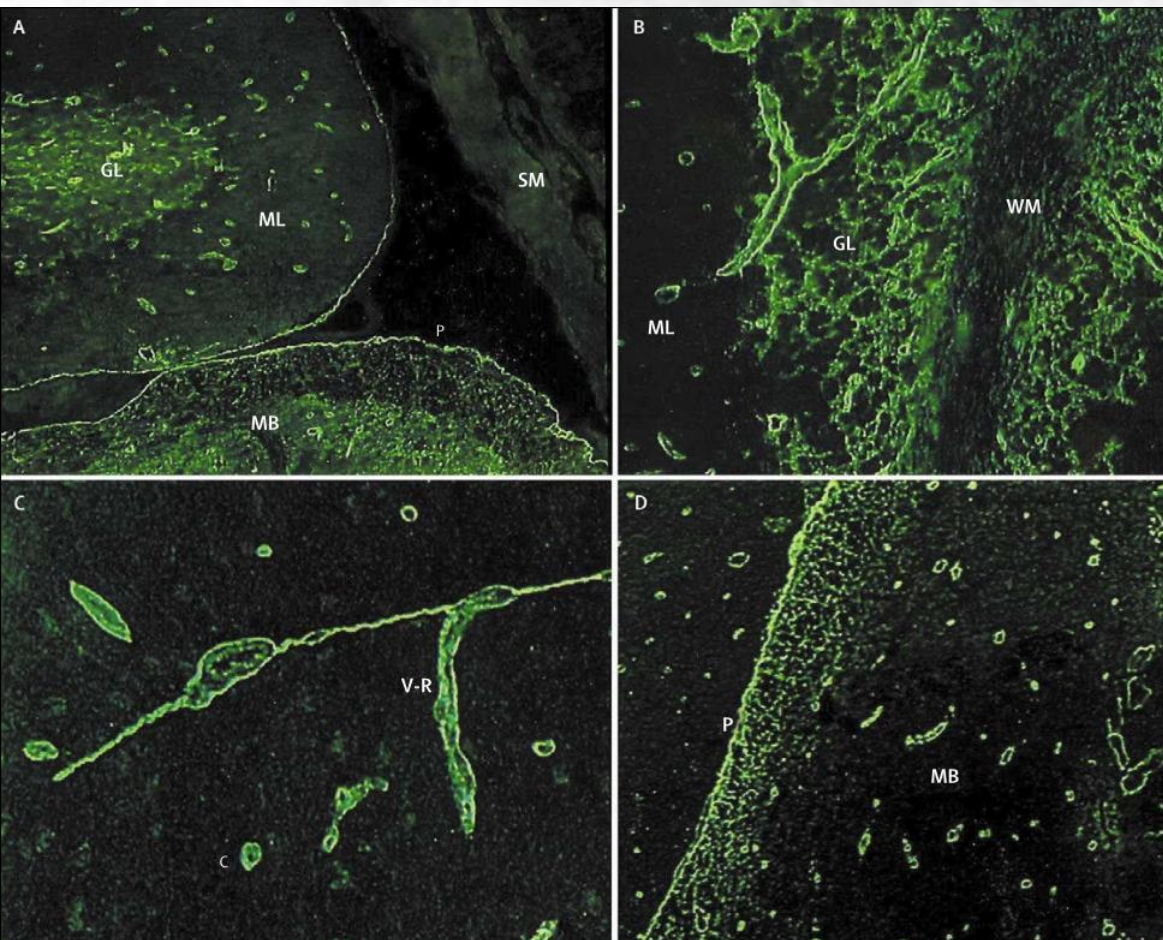
| | Number of lesions with objective clinical evidence | Additional data needed for a diagnosis of multiple sclerosis |
|---------------------|---|---|
| ≥2 clinical attacks | ≥2 | None* |
| ≥2 clinical attacks | 1 (as well as clear-cut historical evidence of a previous attack involving a lesion in a distinct anatomical location†) | None* |
| ≥2 clinical attacks | 1 | Dissemination in space demonstrated by an additional clinical attack implicating a different CNS site or by MRI‡ |
| 1 clinical attack | ≥2 | Dissemination in time demonstrated by an additional clinical attack or by MRI§ OR demonstration of CSF-specific oligoclonal bands¶ |
| 1 clinical attack | 1 | Dissemination in space demonstrated by an additional clinical attack implicating a different CNS site or by MRI‡ AND Dissemination in time demonstrated by an additional clinical attack or by MRI§ OR demonstration of CSF-specific oligoclonal bands¶ |

The small print: * *No additional tests are required to demonstrate dissemination in space and time. However, unless MRI is not possible, brain MRI should be obtained in all patients in whom the diagnosis of multiple sclerosis is being considered. In addition, spinal cord MRI or CSF examination should be considered in patients with insufficient clinical and MRI evidence supporting multiple sclerosis, with a presentation other than a typical clinically isolated syndrome, or with atypical features. If imaging or other tests (eg, CSF) are undertaken and are negative, caution needs to be taken before making a diagnosis of multiple sclerosis, and alternative diagnoses should be considered.*

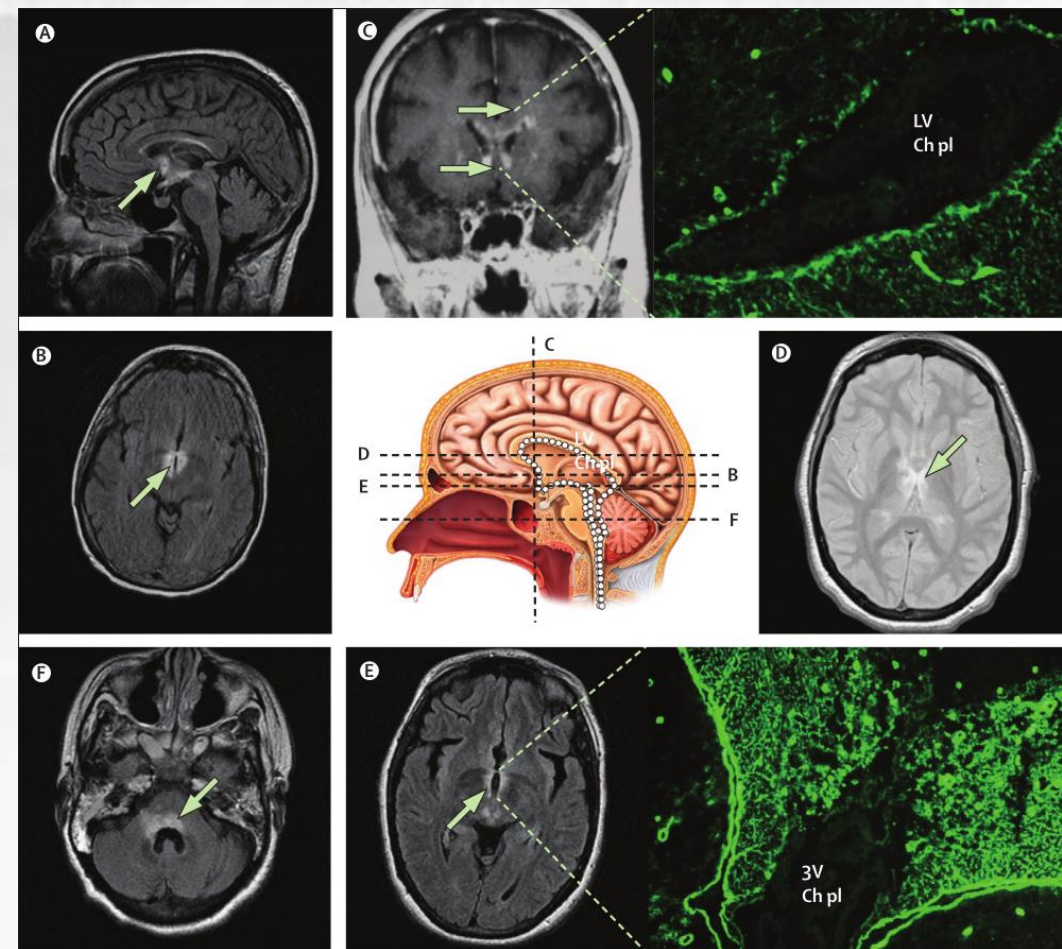




AQP4



V. Lennon et al. 2004



D. Wingerchuk et al. 2007



NMOSD

Table 1 NMOSD diagnostic criteria for adult patients

Diagnostic criteria for NMOSD with AQP4-IgG

1. At least 1 core clinical characteristic
2. Positive test for AQP4-IgG using best available detection method (cell-based assay strongly recommended)
3. Exclusion of alternative diagnoses^a

Diagnostic criteria for NMOSD without AQP4-IgG or NMOSD with unknown AQP4-IgG status

1. At least 2 core clinical characteristics occurring as a result of one or more clinical attacks and meeting all of the following requirements:
 - a. At least 1 core clinical characteristic must be optic neuritis, acute myelitis with LETM, or area postrema syndrome
 - b. Dissemination in space (2 or more different core clinical characteristics)
 - c. Fulfillment of additional MRI requirements, as applicable
2. Negative tests for AQP4-IgG using best available detection method, or testing unavailable
3. Exclusion of alternative diagnoses^a

Core clinical characteristics

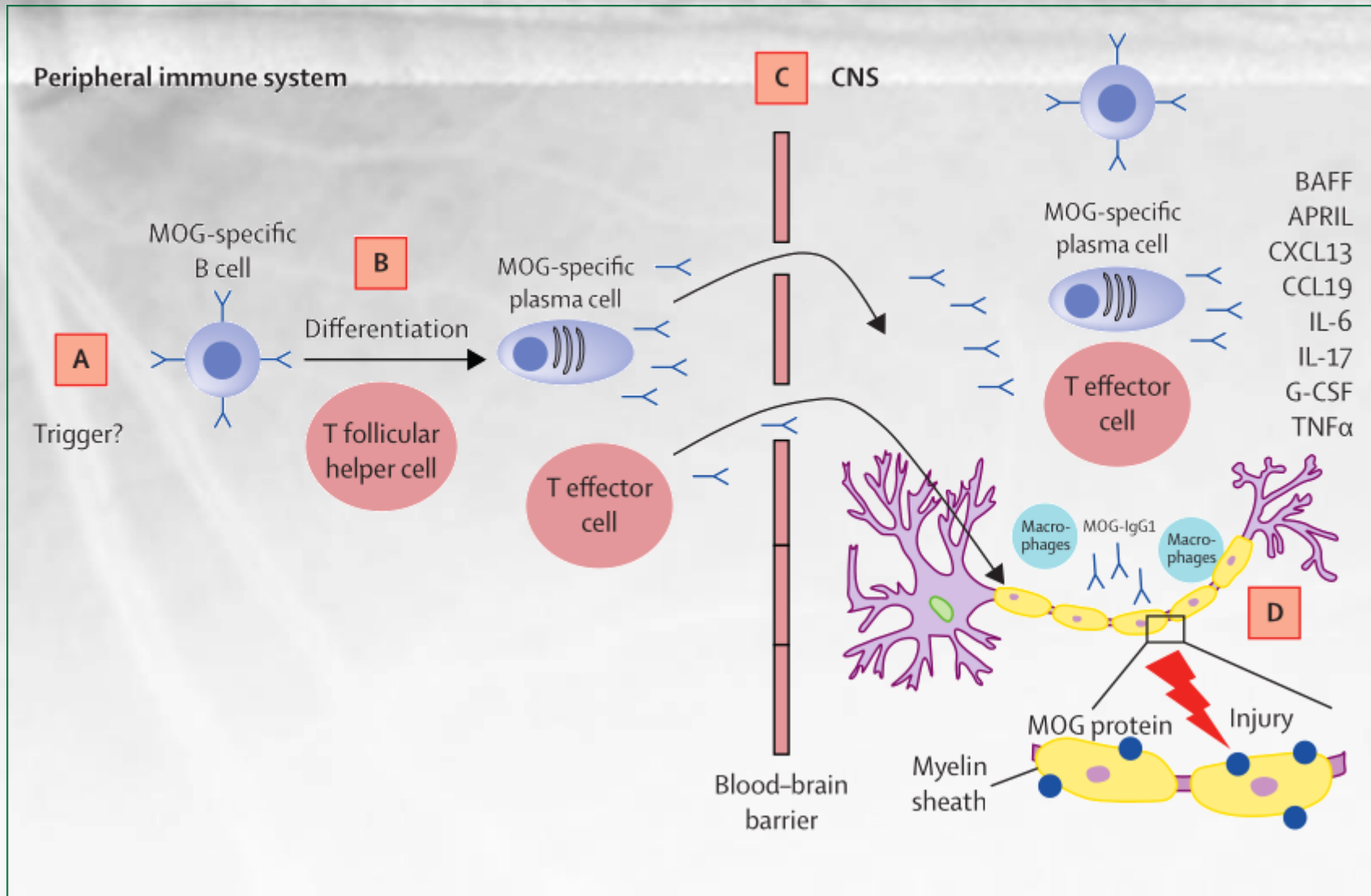
1. Optic neuritis
2. Acute myelitis
3. Area postrema syndrome: episode of otherwise unexplained hiccups or nausea and vomiting
4. Acute brainstem syndrome
5. Symptomatic narcolepsy or acute diencephalic clinical syndrome with NMOSD-typical diencephalic MRI lesions (figure 3)
6. Symptomatic cerebral syndrome with NMOSD-typical brain lesions (figure 3)

Additional MRI requirements for NMOSD without AQP4-IgG and NMOSD with unknown AQP4-IgG status

1. Acute optic neuritis: requires brain MRI showing (a) normal findings or only nonspecific white matter lesions, OR (b) optic nerve MRI with T2-hyperintense lesion or T1-weighted gadolinium-enhancing lesion extending over $>1/2$ optic nerve length or involving optic chiasm (figure 1)
2. Acute myelitis: requires associated intramedullary MRI lesion extending over ≥ 3 contiguous segments (LETM) OR ≥ 3 contiguous segments of focal spinal cord atrophy in patients with history compatible with acute myelitis (figure 1)
3. Area postrema syndrome: requires associated dorsal medulla/area postrema lesions (figure 2)
4. Acute brainstem syndrome: requires associated periependymal brainstem lesions (figure 2)



MOG





MOGAD

| Diagnosis of MOGAD (requires fulfilment of A, B, and C) | | | |
|---|--|--|--|
| (B) Positive MOG-IgG test | Cell-based assay: serum‡‡ | Clear positive** | No additional supporting features required |
| | | Low positive†† | <ul style="list-style-type: none"> • AQP4-IgG seronegative AND • ≥1 supporting clinical or MRI feature |
| | | Positive without reported titre | |
| | | Negative but CSF positive§§ | |
| Supporting clinical or MRI features | <u>Optic neuritis</u> | <ul style="list-style-type: none"> • Bilateral simultaneous clinical involvement • Longitudinal optic nerve involvement (> 50% length of the optic nerve) • Perineural optic sheath enhancement • Optic disc oedema | |
| | Myelitis | <ul style="list-style-type: none"> • Longitudinally extensive myelitis • Central cord lesion or H-sign • Conus lesion | |
| | Brain, brainstem, or cerebral syndrome | <ul style="list-style-type: none"> • Multiple ill-defined T2 hyperintense lesions in supratentorial and often infratentorial white matter • Deep grey matter involvement • Ill-defined T2-hyperintensity involving pons, middle cerebellar peduncle, or medulla • Cortical lesion with or without lesional and overlying meningeal enhancement | |
| (C) Exclusion of better diagnoses including multiple sclerosis¶¶¶ | | | |

B. Banwell et al. 2023



A clinical observation: CRION

- Individuals with optic neuritis
- Corticosteroid responsive
- Relapse on corticosteroid reduction

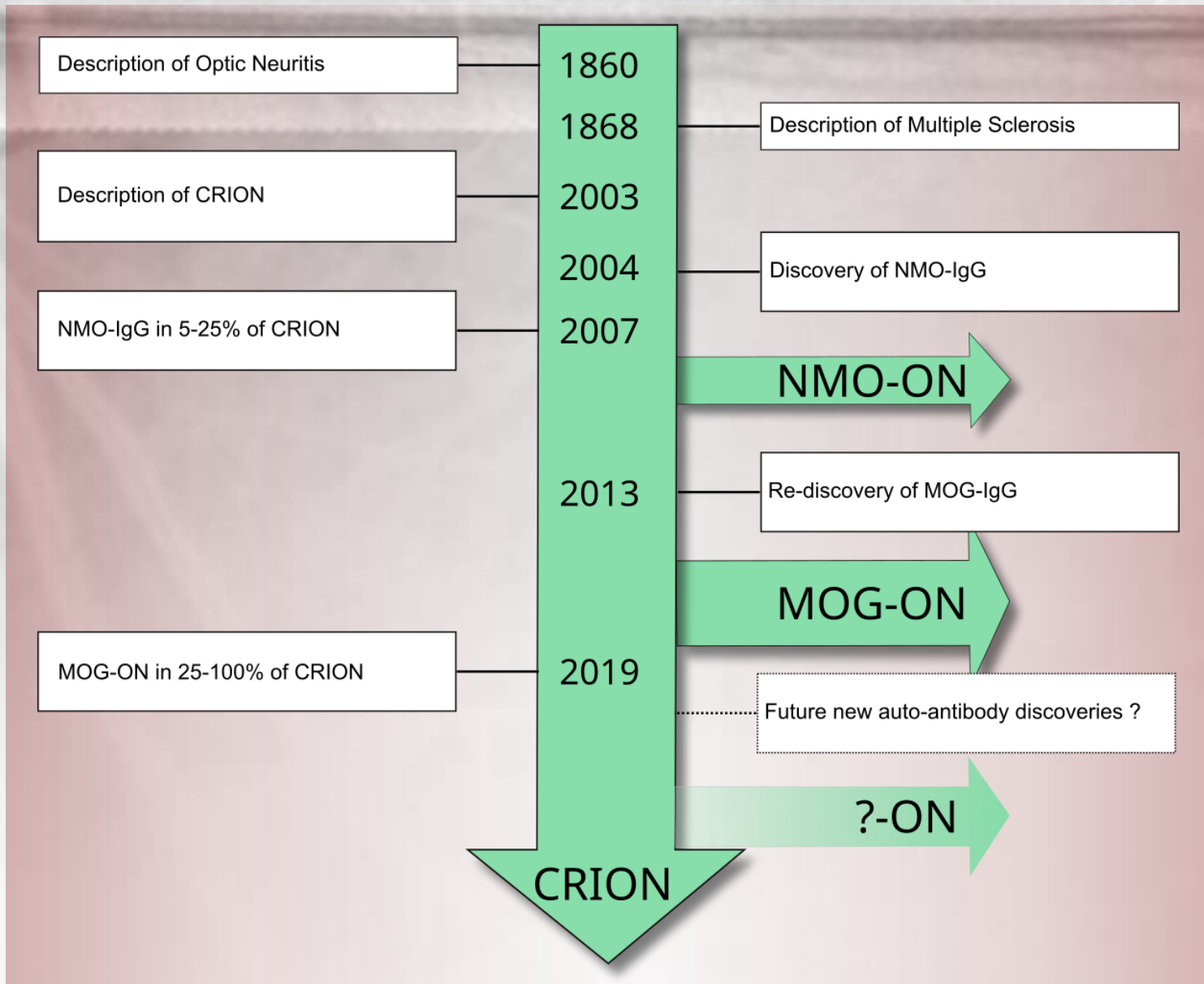
D. Kidd et al. 2003

A. Petzold & G.T. Plant 2014





Summary background





Overview

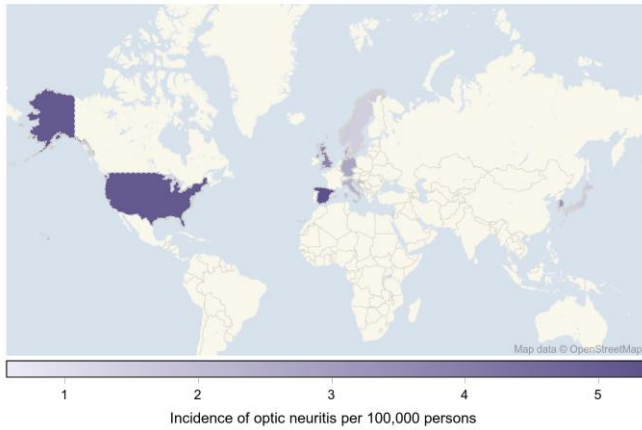
- Background: from MS to MOG & NMO
- **International view**
- Differential diagnoses
- Diagnosis and treatment of NMO-ON & MOG-ON
- Conclusion



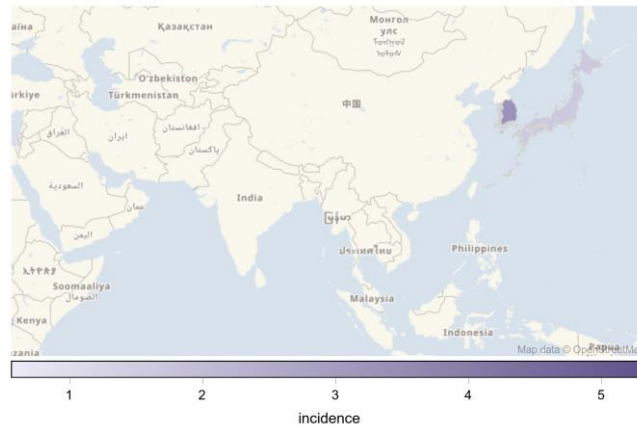


Epidemiology of ON

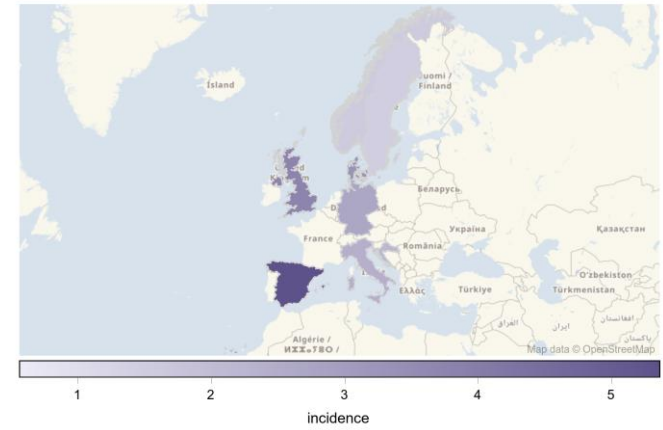
Incidence of optic neuritis



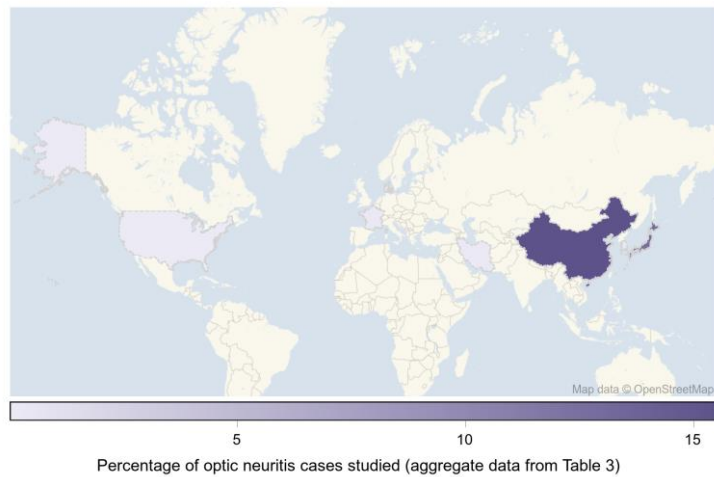
Incidence of optic neuritis



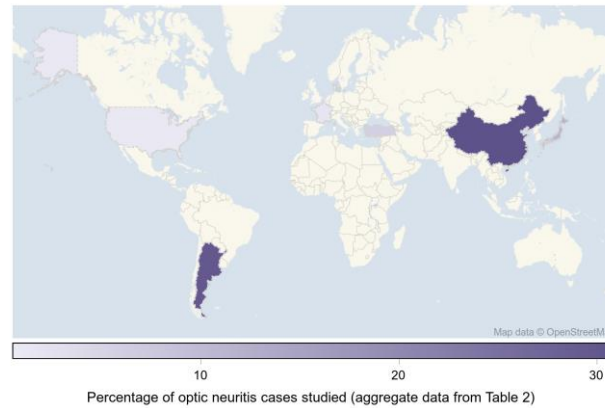
Incidence of optic neuritis



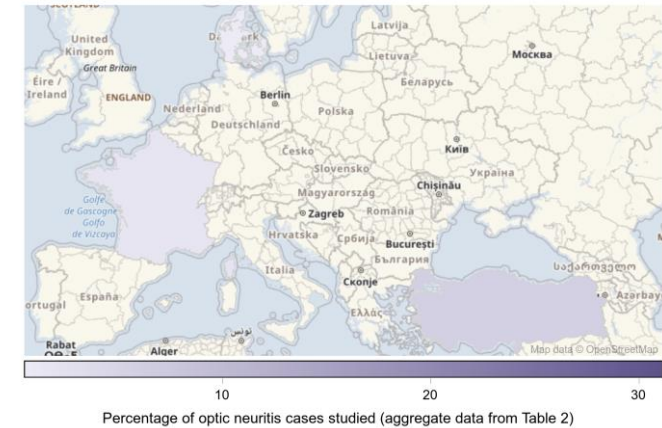MOG seropositive optic neuritis



AQP4 seropositive optic neuritis



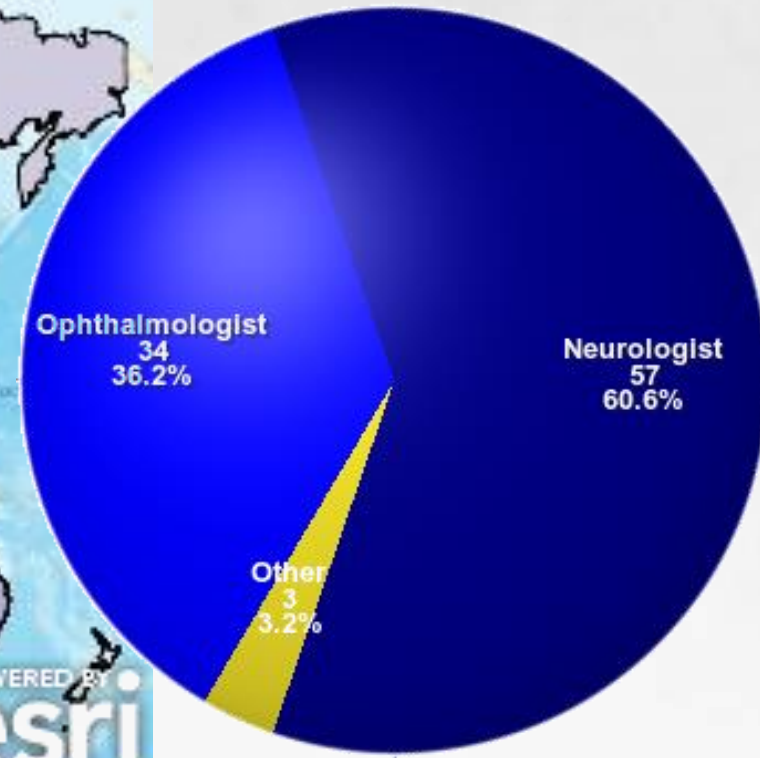
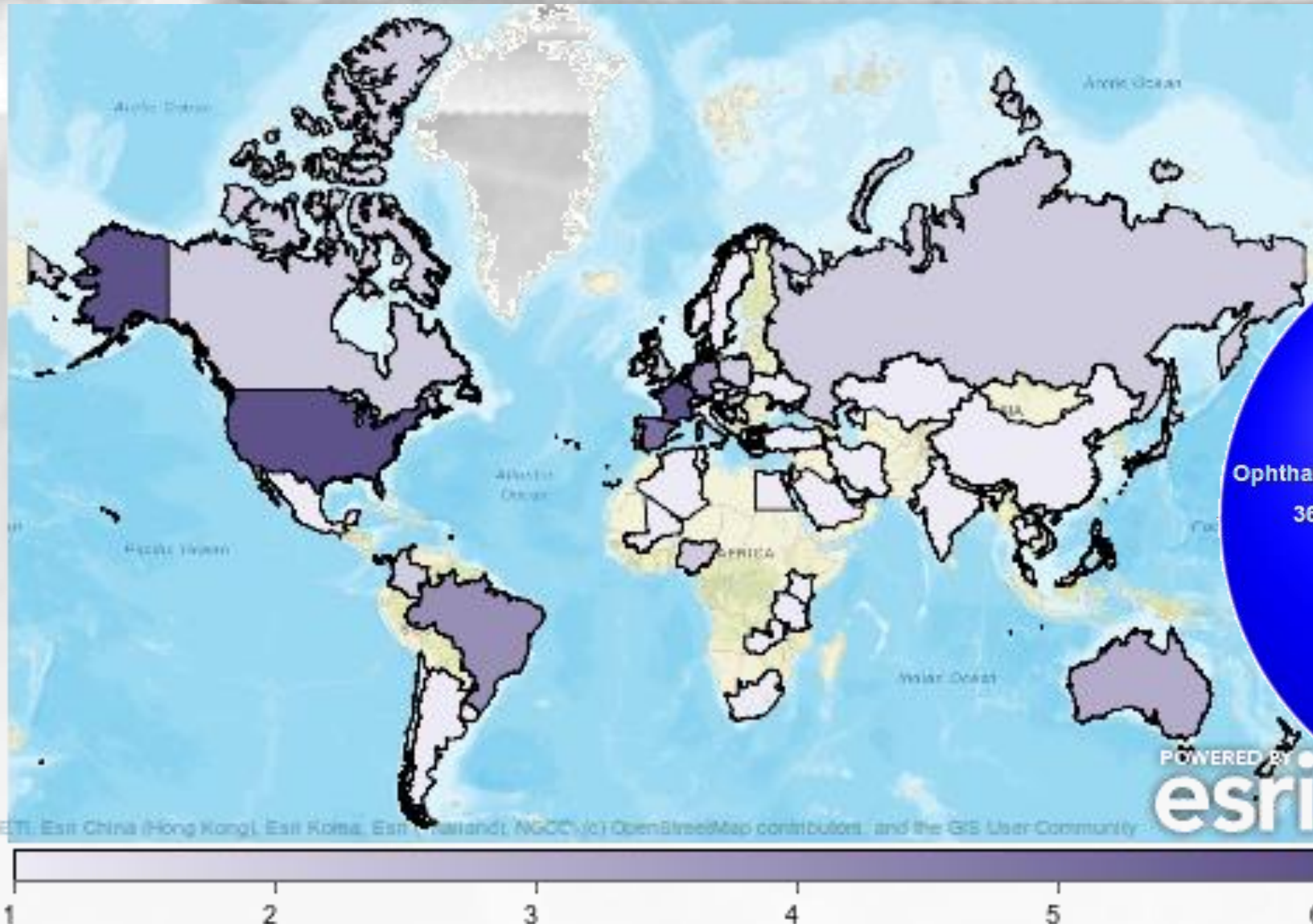

AQP4 seropositive optic neuritis



S. Hickman & A. Petzold 2021



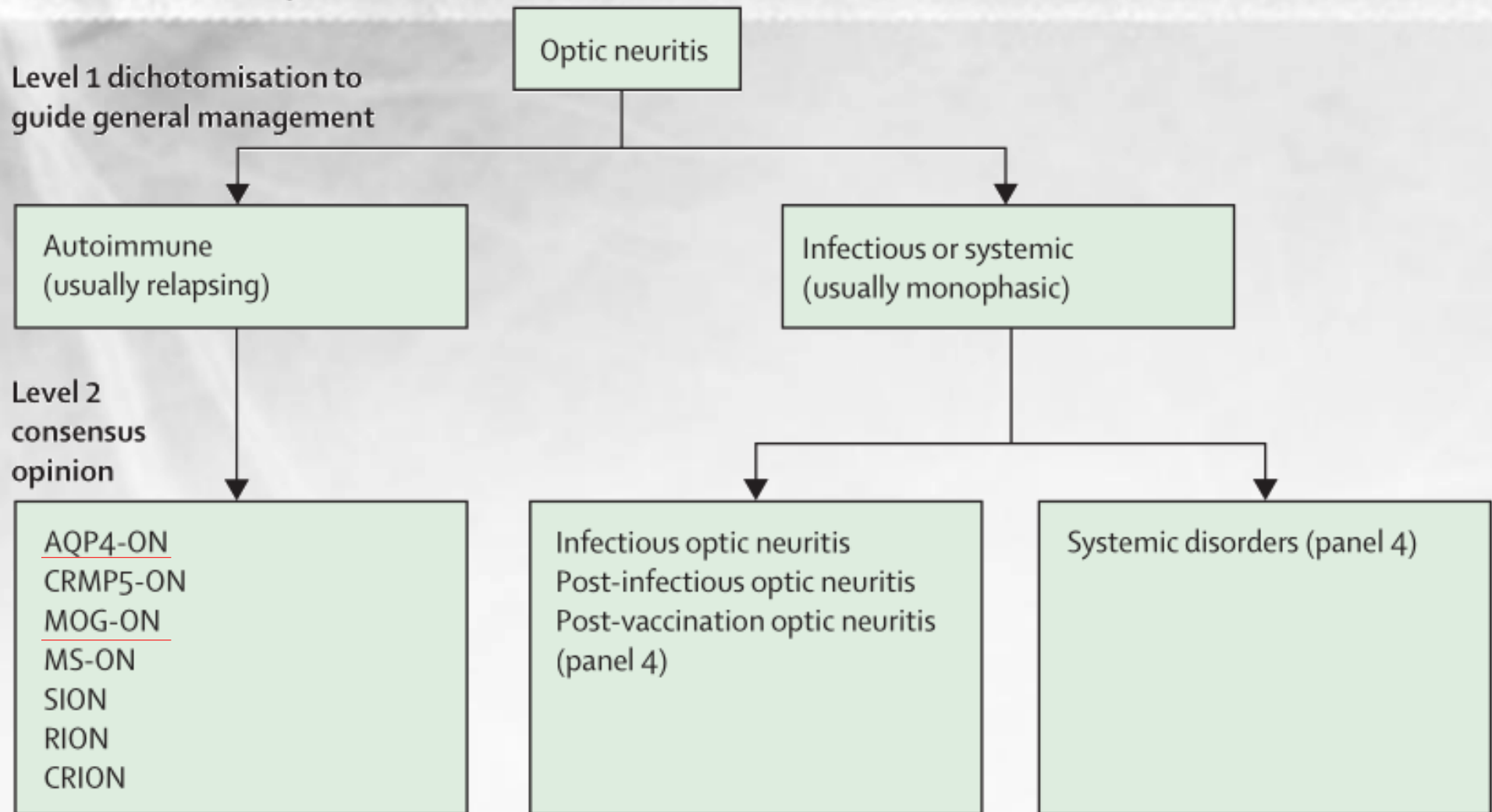
ICON



Classification



Classification of optic neuritis





Overview

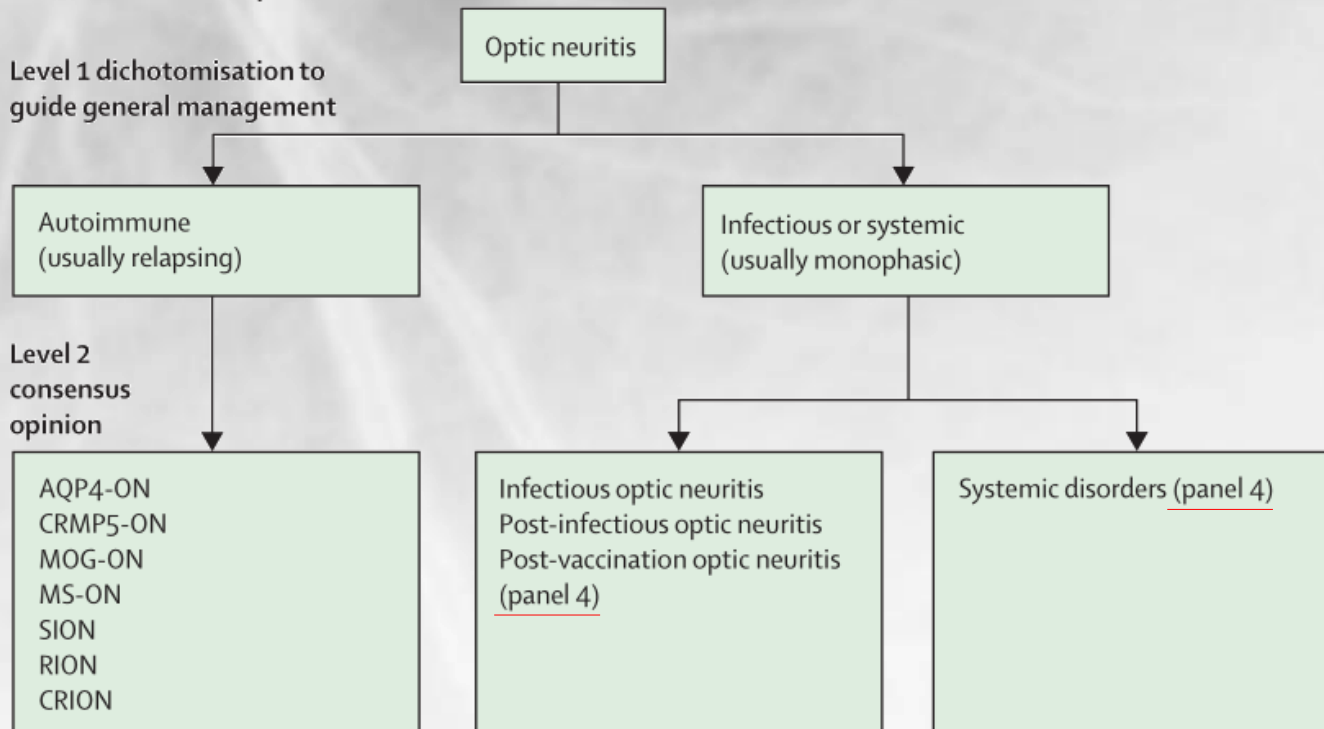
- Background: from MS to MOG & NMO
- International view
- **Differential diagnoses**
- Diagnosis and treatment of NMO-ON & MOG-ON
- Conclusion



Differential Diagnoses



Classification of optic neuritis



Panel 4: Infections and systemic disorders associated with optic neuritis

Causes of infectious and post-infectious optic neuritis

Bartonella, brucella, Chikungunya fever, cytomegalovirus, coronavirus, *Coxiella burnetii*, dengue, Epstein-Barr virus, echovirus, ehrlichiosis, Henoch-Schönlein purpura, hepatitis B and C, herpes simplex, histoplasma, HIV, human herpesvirus 6, hypertrophic pachymeningitis, IgG subclass deficiency, Inoue-Melnick virus, leprosy, Lyme disease, measles, mumps, *Mycoplasma pneumoniae*, neurotoxocarosis, ocular cat-scratch disease, post-vaccination optic neuritis, rubella, streptococcus, syphilis, tick-borne encephalitis, toxoplasmosis, tuberculosis, typhus, varicella zoster virus, West Nile virus, Whipple disease, and Zika virus.

Systemic disorders causing optic neuritis

Allergic granulomatous angiitis, ANCA associated vasculitis, ankylosing spondylitis, Behçet's disease, Churg-Strauss disease, Cogan syndrome, giant cell arteritis, granulomatosis with polyangiitis, IgG 4 disease, Kawasaki disease, microscopic polyangiitis, polyarteritis nodosa, primary antiphospholipid syndrome, rheumatic disease, sarcoidosis, Sjögren syndrome, systemic lupus erythematodes, Susac syndrome, systemic sclerosis, Takayasu arteritis, treatment side-effect,* ulcerative colitis, and Wegener granulomatosis.




Overview

- Background: from MS to MOG & NMO
- International view
- Differential diagnoses
- **Diagnosis and treatment of NMO-ON & MOG-ON**
- Conclusion





Diagnosis



Diagnosis of optic neuritis

Diagnosis based on clinical assessment and paraclinical tests (panel 1)

(a) Subacute monocular loss of vision, dyschromatopsia, pain worsening on eye movements, RAPD + 1 paraclinical test

(b) Like (a) without pain + 2 paraclinical tests

(c) Like (a) or (b) but binocular (RAPD unreliable) + MRI and another paraclinical test

Definite optic neuritis

(d) Clinically seen in acute phase, with features of (a), (b), or (c), with fundus examination consistent with optic neuritis classical disease course and no available paraclinical tests
(e) Retrospective typical history + paraclinical test(s)

Possible optic neuritis

(f) Loss of vision with features from panel 3 being present that suggest alternative pathology and paraclinical tests showing alternative pathology

Not optic neuritis



Time is vision



Occasional essay

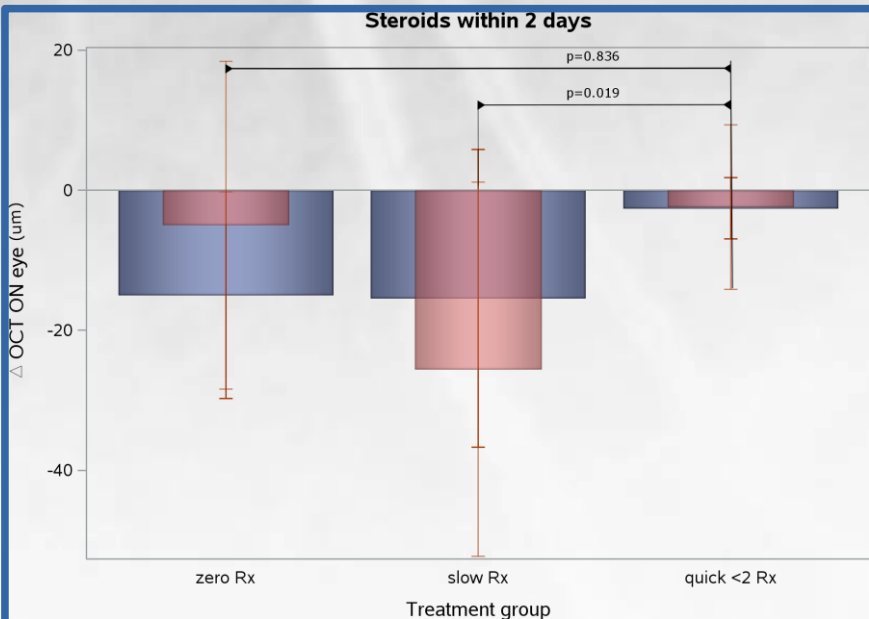
J Neurol Neurosurg Psychiatry:



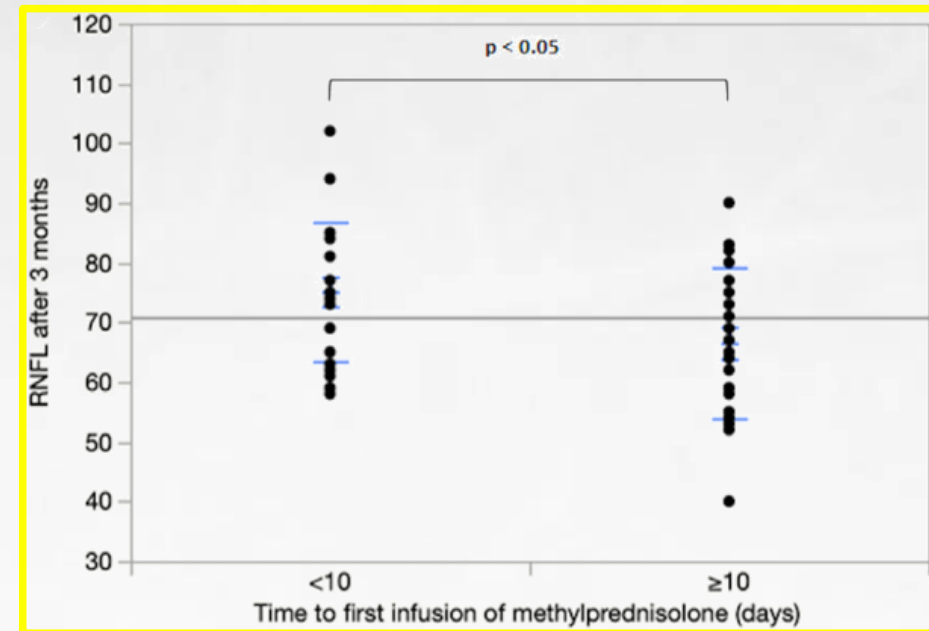
OPEN ACCESS

Case for a new corticosteroid treatment trial in optic neuritis: review of updated evidence

Axel Petzold ^{1,2}, Tasanee Braithwaite,³ Bob W van Oosten,⁴ Lisanne Balk,⁵ Elena H Martinez-Lapiscina ⁶, Russell Wheeler,⁷ Nils Wiegerinck,⁸ Christiaan Waters,⁹ Gordon T Plant¹⁰



MOG-ON
NMO-ON
MS-ON
RION
CRION



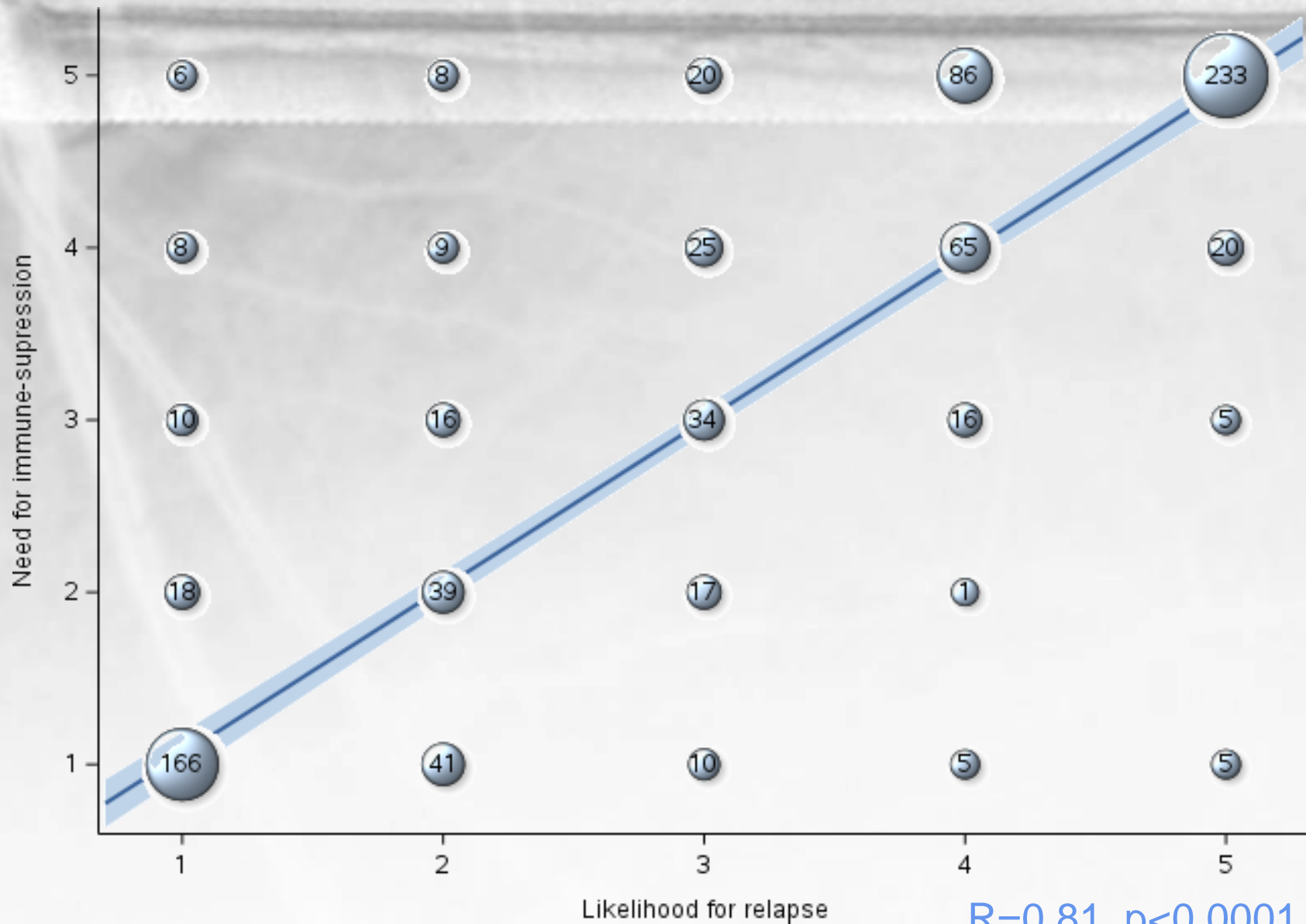
E. Osinga et al 2017

J. Rode et al 2023





Treatment & relapse

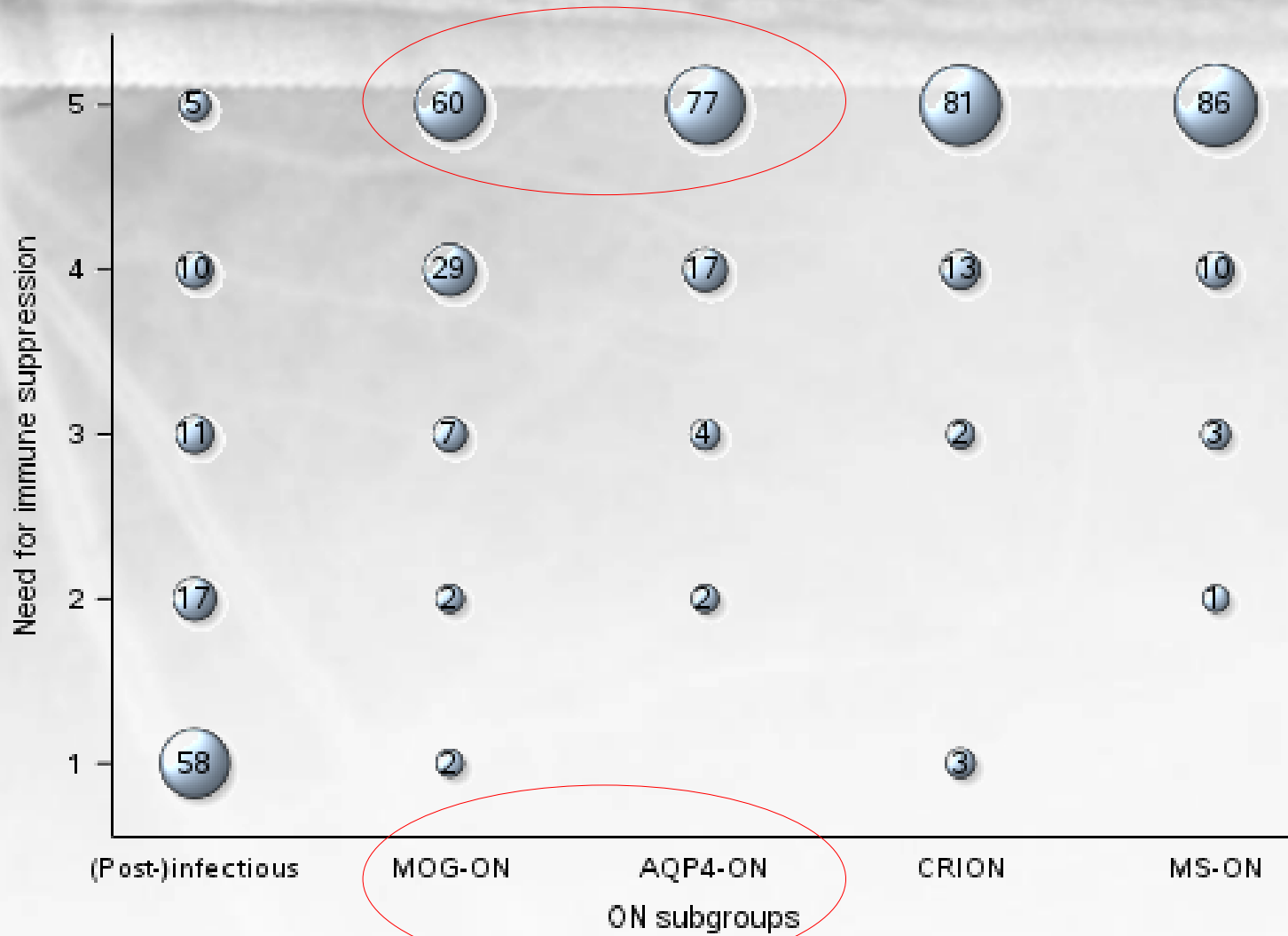


$R=0.81, p<0.0001, n=863$



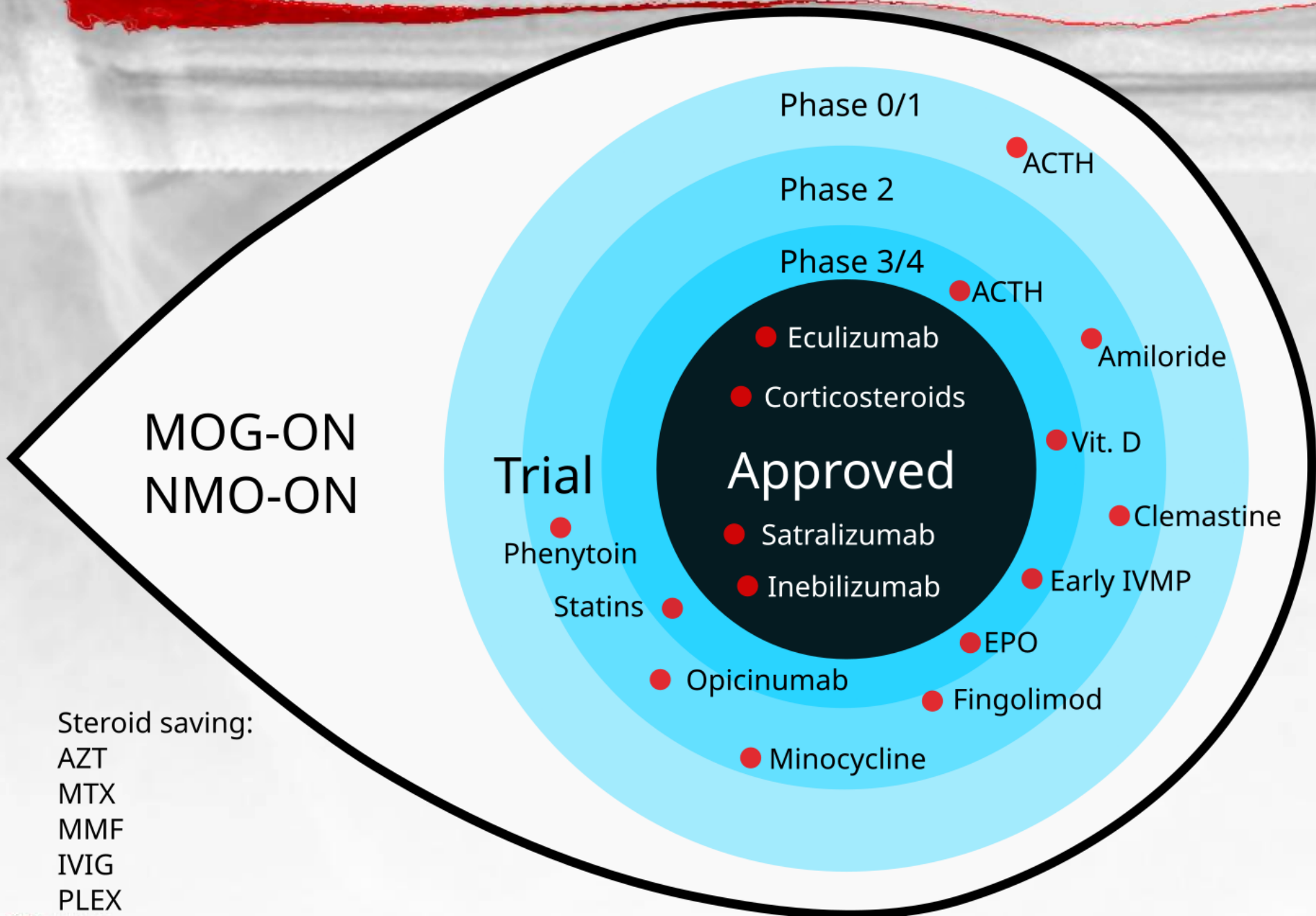


Long term immune suppression





Treatments for MOG & NMO-ON




Steroid saving:

- AZT
- MTX
- MMF
- IVIG
- PLEX
- UCL



Conclusion

- Optic Neuritis: from clinic to tests
- Antibodies are essential for diagnosis
- Novel diagnostic criteria
- Guidance on differential diagnoses
- Update on treatment





3-6 JUNE 2024
ROTTERDAM
THE NETHERLANDS



Thank you

