

ISSN: (Print) (Online) Journal homepage: <https://www.tandfonline.com/loi/iero20>

# Detection of macular atrophy in age-related macular degeneration aided by artificial intelligence

Wei Wei, Rajeevan Anantharanjit, Radhika Pooja Patel & Maria Francesca Cordeiro

To cite this article: Wei Wei, Rajeevan Anantharanjit, Radhika Pooja Patel & Maria Francesca Cordeiro (2023) Detection of macular atrophy in age-related macular degeneration aided by artificial intelligence, Expert Review of Molecular Diagnostics, 23:6, 485-494, DOI: [10.1080/14737159.2023.2208751](https://doi.org/10.1080/14737159.2023.2208751)

To link to this article: <https://doi.org/10.1080/14737159.2023.2208751>



© 2023 The Author(s). Published by Informa UK Limited, trading as Taylor & Francis Group.



Published online: 05 May 2023.



Submit your article to this journal [↗](#)



Article views: 1004

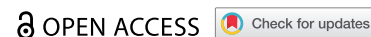

View related articles [↗](#)



View Crossmark data [↗](#)

REVIEW



# Detection of macular atrophy in age-related macular degeneration aided by artificial intelligence

Wei Wei <sup>a,b,c</sup>, Rajeevan Anantharanjit<sup>c,d</sup>, Radhika Pooja Patel <sup>c,d</sup> and Maria Francesca Cordeiro <sup>b,c,d</sup>

<sup>a</sup>Department of Ophthalmology, Ningbo Medical Center Lihuili Hospital, Ningbo, China; <sup>b</sup>Department of Surgery & Cancer, Imperial College London, London, UK; <sup>c</sup>Imperial College Ophthalmology Research Group (ICORG), Imperial College Ophthalmology Research Group, London, UK; <sup>d</sup>Western Eye Hospital, Imperial College Healthcare NHS trust, London, UK

## ABSTRACT

**Introduction:** Age-related macular degeneration (AMD) is a leading cause of irreversible visual impairment worldwide. The endpoint of AMD, both in its dry or wet form, is macular atrophy (MA) which is characterized by the permanent loss of the RPE and overlying photoreceptors either in dry AMD or in wet AMD. A recognized unmet need in AMD is the early detection of MA development.

**Areas covered:** Artificial Intelligence (AI) has demonstrated great impact in detection of retinal diseases, especially with its robust ability to analyze big data afforded by ophthalmic imaging modalities, such as color fundus photography (CFP), fundus autofluorescence (FAF), near-infrared reflectance (NIR), and optical coherence tomography (OCT). Among these, OCT has been shown to have great promise in identifying early MA using the new criteria in 2018.

**Expert opinion:** There are few studies in which AI-OCT methods have been used to identify MA; however, results are very promising when compared to other imaging modalities. In this paper, we review the development and advances of ophthalmic imaging modalities and their combination with AI technology to detect MA in AMD. In addition, we emphasize the application of AI-OCT as an objective, cost-effective tool for the early detection and monitoring of the progression of MA in AMD.

## ARTICLE HISTORY

Received 5 December 2022  
Accepted 26 April 2023

## KEYWORDS

Age-related macular degeneration; artificial intelligence; deep learning; macular atrophy; machine learning; optical coherence tomography

## 1. Introduction of AMD

Age-related macular degeneration (AMD) is a leading cause of visual impairment and irreversible blindness in the elderly population in developed countries. Its prevalence is estimated to increase to 288 million in 2040 [1], approximately 8.7% of all global blindness [2], as the aging population grows due to increased life expectancy.

AMD is a progressive macular degenerative disorder involving drusen deposition, retinal pigment epithelium (RPE) abnormalities, atrophy of the RPE and the choriocapillaris, and neovascularization. The disease is divided into three stages, namely, early, intermediate, and advanced [3]. The early stage is characterized by the presence of drusen deposits in the retina, while the advanced stage can be divided into the dry type with geographic macular atrophy (MA) at the center of the fundus, and the wet type with neovascularization.

## 2. Macular atrophy (MA)

### 2.1. Definition of MA in AMD

Atrophy is a term used to describe shrinking or withering of a body, which may occur as a result of inadequate diet or of inactivity. Macular atrophy in AMD is characterized by the permanent degradation of the RPE and overlying photoreceptors either in dry AMD or in wet AMD.

### 2.2. MA in dry AMD

Atrophy in dry AMD presents various forms of atrophy around the macula, including parafoveal/foveal band formation, unifocal, or multifocal. The growth rate of atrophy is 2 mm<sup>2</sup>/year on average but varies considerably [4]. MA is the end point of dry AMD resulting in functional loss and the presence of scotoma in patient's visual field. The progression of dry AMD occurs more slowly than wet AMD [5], but it produces irreversible visual loss, predominantly central, for which there is currently no established treatment.

Geographic MA is a form of progressive atrophy and it presents in an atrophic form in late disease. This concept was introduced by Gass [6] in 1973 who described demarcated areas of atrophy in the macula which gradually enlarged and coalesced [7]. The area of atrophy was described as 'geography' and this term described confluent loss of the retinal pigment epithelium (RPE) with a strongly delineated boundary between depigmented and normal regions on the surface [8]. MA in dry AMD often begins as a single parafoveal lesion [9] and may present in areas previously occupied by drusenoid pigment epithelial detachments [9]. The atrophy is also associated with a form of morphological change-reticular pseudodrusen (RPD), appearing as yellowish-white net-like patterns located subretinally [10,11]. Studies have demonstrated that RPD is an increased risk factor for progression to the late stages of AMD, in both dry and wet AMD patients [12].

**CONTACT** Maria Francesca Cordeiro  [m.cordeiro@imperial.ac.uk](mailto:m.cordeiro@imperial.ac.uk)  Imperial College London, London, UK

**Article highlights**

- MA is the endpoint of AMD, which leads to irreversible blindness, therefore, early detection of MA is urgent and an unmet need.
- Ophthalmological imaging technology provides a reliable way to detect lesions and the progression of MA.
- OCT enables detailed morphologic and structural changes in cross-sectional level for MA early detection.
- The rapid development of AI has attracted global attention over the last decade, and its wide application will undoubtedly revolutionize the ophthalmic field.
- Many biomarkers that are captured on OCT can be objectively detected by AI-based algorithms and can be used as reliable indicators for MA prediction and progression.

**2.3. MA in wet AMD**

Nowadays, it is well-established that atrophy is a common occurrence in patients with treated neovascular AMD (wet AMD) [13,14], and that both neovascularization and MA can coexist in the same eye [13]. Several studies have confirmed the discovery of atrophy in eyes with treated neovascular AMD [9,15]. Atrophy is cited as the foremost reason for visual loss in patients with wet AMD who have received anti-vascular endothelial growth factor (VEGF) treatments [16,17]. It is still not entirely clear as to why MA occurs in patients with wet AMD – whether it is caused by the underlying degenerative process of AMD or by the anti-VEGF treatment itself. There are three potential hypotheses at present, including the natural evolution of underlying dry AMD (true geographic atrophy), collateral effect of the extension/retraction of macular neovascularization (MNV), and interference with basal VEGF levels [13]. The reason for the latter is partly attributed to anti-VEGF treatment inhibiting the neuroprotective effects of VEGF [18]. Increased VEGF level after injury reduces the number of apoptotic retinal cells and plays a direct role in neuroprotection, but this protective effect is reversed if using VEGF inhibitors. Therefore, long-term anti-VEGF treatments may lead to a significant loss of retinal ganglion cells [18,19]. Recent studies also have revealed that VEGF in addition to their angiogenesis and vascular permeability roles also play important roles in neurotrophic and neuroprotective functions [20], as evidenced in models of retinal neuroprotection in experimental glaucoma [21]. The RIVAL study [22] showed that up to a third of wet AMD patients receiving anti-VEGF treatment develop MA after 24 months of treatment, with no difference in the rate of progression of MA whether ranibizumab or aflibercept was used. As MA is progressive and results in significant and irreversible visual loss once the fovea is involved, it is important to be able to predict or identify the onset of MA development at the earliest opportunity.

**2.4. Treatment for MA**

Up until now, there have not been any effective treatments for MA. However, promising treatments are now beginning to emerge. Recent studies have evaluated the safety and efficacy of intravitreal pegcetacoplan (a pegylated complement C3

inhibitor peptide) and avacincaptad pegol (a C5 inhibitor). Both new treatments show potential in significantly slowing the progression of MA in AMD [23–25].

**3. Imaging technologies to detect MA**

As imaging technologies have rapidly evolved, their applications in AMD and MA diagnosis and monitoring have increased. A summary of these techniques is described below.

**3.1. Conventional imaging technologies****3.1.1. Fundus photography**

Atrophy in dry AMD has historically been defined by the presence of any distinctly demarcated circular or oval patch of retinal hypopigmentation or depigmentation using 30° or 35° in color fundus photography (CFP) images, as well as visibility of the underlying choroidal vessels [3]. However, the boundaries of atrophy were sometimes difficult to differentiate, with a need for better differentiation between healthy and diseased retina.

**3.1.2. Fundus autofluorescence and near-infrared fundus autofluorescence**

Fundus autofluorescence (FAF) imaging is a novel and useful technology with signal derived from lipofuscin in RPE cells appearing as hyperfluorescent patches, and hypofluorescent patches defining atrophy. This became the primary method to identify and quantify atrophy [26,27]. Lipofuscin is a by-product of phagocytosis of the photoreceptor outer segments, which accumulates in the RPE with age. It is strongly associated with the pathogenesis of AMD [28]. The accumulation of lipofuscin presents a sharply demarcated area of decreased signal intensity in blue-light or green-light FAF [29]. FAF has been developed into a repeatable method for accurately analyzing and quantifying lesion region and this technique is used in many clinical trials [30,31]. FAF could be used to provide a quantitative parameter for the enlargement area of MA. However, the primary limitation of using blue-light FAF to detect GA lesions is that the central macular luteal pigment absorbs the blue excitation light, making it impossible to determine foveal activity by using FAF images alone [32].

Near-infrared fundus autofluorescence (NIA) is another noninvasive imaging tool with long wave used to visualize the pathologic process in the retina, especially abnormalities in the RPE. NIA can visualize the distribution of melanin in the retina, which originates from the RPE and is a major protective factor for the RPE [33]. Melanin protects the RPE cells from a variety of threats, including radiation, oxidative stress, and light damage [34]. NIA can complement FAF when evaluating the progression of AMD [34].

**3.2. 3 near-infrared reflectance (NIR)**

Unlike FAF, near-infrared reflectance (NIR) is unaffected by luteal pigment and is often used in combination with blue-light FAF allowing the assessment of the foveal involvement. This makes it comfortable and safe for patients [35]. Although it fails to distinguish junctional features in some cases (e.g.

regions of elevated autofluorescence at the boundary of atrophy), which could suggest a faster rate of enlargement of the MA lesion and needs to be used in combination with blue light FAF [35], it is still reliable to identify MA lesions in dry AMD in many cases. NIR imaging is commonly obtained along with optical coherence tomography (OCT), and therefore NIR-based MA assessment may be a useful surrogate in clinical settings [35].

### 3.3. Optical coherence tomography

Optical coherence tomography (OCT) has become a standard technology to evaluate the macula, because it is widely available, easily performed and provides detailed structural assessment non-invasively. With the development of OCT technology, clinicians can rapidly capture volumetric and en-face images. The near-infrared reflectance image can help evaluate macular lesions in different layers. Furthermore, this technique can determine the extent of cellular loss in macular atrophy and detect changes in different retinal layers.

The development of imaging technology with spectral domain optical coherence tomography (SD-OCT) is a milestone in ophthalmological imaging. SD-OCT scanners have real-time tracking, fast scan rates, high resolution, and high contrast images. The higher scanning speeds help produce high-resolution images and minimize artifacts from eye movements [36]. Another study has also shown that ultra-fast OCT using Graphics Processing Unit (GPU) computing is comparable with the data acquisition thread time, and this real-time display is a promising tool for clinics [37].

Computer-based analysis of features provides quantitative assessment of a considerable volume of imaging data, which offers meaningful evaluation that is simply not feasible in clinical practice. The wide application of OCT has revolutionized the diagnosis and management of wet AMD in everyday clinical practice because it can provide assessment of risk and individual prognosis, including the need for repeated anti-VEGF injections and other therapeutic intervention. The efficacy of anti-VEGF treatment is highly correlated with the morphological features based on OCT imaging [38]. Therefore, OCT is an efficient tool for evaluation of AMD. Despite the ability of OCT to provide a reliable assessment of various pathognomonic features of the disease, comprehensive evaluation of a patient may involve multi-model imaging and ideally include CFP, fluorescein angiography (FA) and FAF to be performed routinely.

### 3.4. Application of OCT as an imaging tool to detect MA

OCT is reliable in detecting drusen in patients with AMD. The internal heterogeneous reflectivity of drusen and the change from homogeneous to heterogeneous reflectivity over time are associated with local RPE atrophy onset, defined as the loss of RPE and ellipsoid zone (EZ) bands [39]. Atrophy will result in increased signal transmission below Bruch's membrane (BM) accompanied by loss of the external limiting membrane (ELM) and outer nuclear layer (ONL) [39]. This in turn translates into hyperreflective signals from the choroid. Furthermore, the drusenoid lesions and drusenoid pigment

epithelium detachment (PED), positively correlate with the risk of local atrophy onset [40] and a decreased photoreceptor thickness [41].

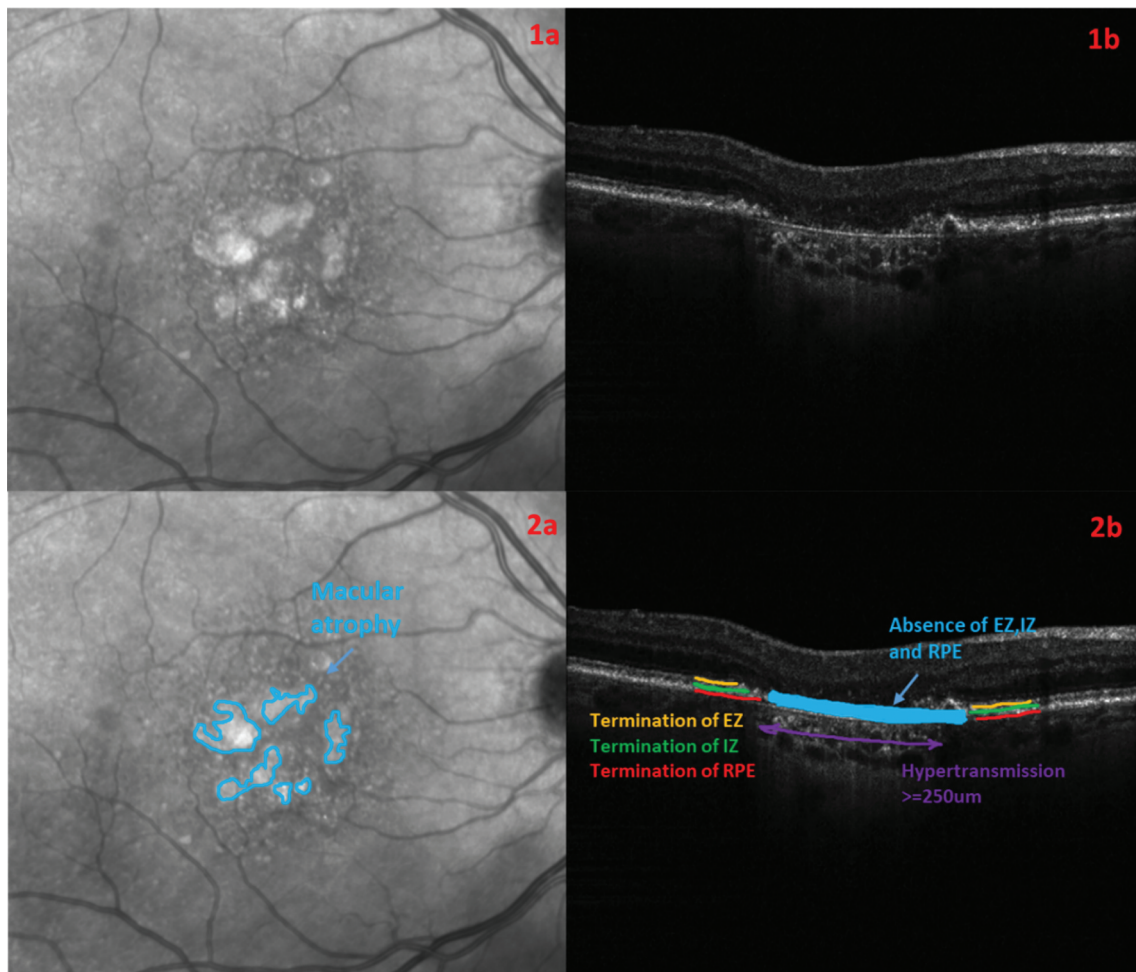
The cross-sectional feature of OCT imaging enables detecting subtle changes in the outer retinal and RPE layers of macular atrophy. Macular atrophy on SD-OCT is characterized by the hyper-transmission of light into the choroid below the Bruch's Membrane (BM), and this is due to the absence of light-scattering on RPE and choriocapillaris [39]. Confluent areas of RPE atrophy are further accompanied by the loss of the overlying photoreceptors and the absence of the ELM, the loss of the ONL and the subsidence of the outer plexiform layer (OPL) [39]. En-face projections of the summed transmitted and reflected light from all layers offer further insights and visualization. These images include the detailed delineation of MA with hyper-reflection signals because of the increased total signals from the choroid. Using both OCT and NIR images, manual and automated quantification of the atrophic area has been shown to be a valid, reproducible, convenient, and reliable method in assessing the growth rate [42]. Furthermore, as a single imaging technique, OCT fundus images allow simultaneous visualization of the atrophy together with the loss of photoreceptors and the RPE that should correlate with the loss of the visual function [42]. Margins of atrophy are characterized by the change from a hyporeflective to hyperreflective choroidal signal on OCT imaging. Also, various morphological alterations of the outer retinal bands can be detected on OCT imaging (Figure 1). Studies have shown abrupt and irregular breaks/disruptions in the EZ, the interdigitation zone (IZ), and the RPE band [43]. In the atrophic areas, these bands are often obscured or absent [43]. In addition, among the various morphological changes in the atrophic area, the remaining structure RPE-BM complex becomes homogenous over time [39]. MA constantly enlarges in all patients due to the expansion of the loss of RPE, photoreceptors, and varying degrees of choriocapillaris [39]. Areas of choroidal hyper-reflectivity, OPL thinning, and the ELM loss can be clearly visualized on OCT. These structural changes underpin a staging category of MA based on the classification consensus [44]. Photoreceptor abnormalities may be an early indicator of AMD progression, because it often precedes the enlargement of the atrophy and extends beyond the borders of atrophy [45,46], which may be helpful in understanding the pathogenesis of AMD better. Interestingly, progressive loss of photoreceptors related to outer retinal thinning has been shown to occur without RPE atrophy [44] or with a preserved RPE layer [47].

In summary, the loss of photoreceptors includes the loss of the IZ, EZ, and ELM and the thinning of the ONL [44]. These features can all be seen on OCT enabling a new classification system to define MA, and also provide a surrogate clinical endpoint to evaluate the effectiveness of potential treatments.

### 3.5. A new classification of MA based on OCT imaging

In 2018, a new classification system to define MA based on OCT technology was published by the Classification of Atrophy Meetings (CAM) group. The criteria showed that atrophy can undergo an evolution of different stages, with four





**Figure 1.** An example of OCT images to detect MA. 1a. NIR image of OCT; 1b. Cross-sectional Image of OCT (also called OCT slice); 2a. Outline of MA characterized by hyperreflective signals; 2b. Annotated morphological alterations of the outer retina and RPE.

histological/OCT features proposed: complete RPE and outer retinal atrophy (cRORA), incomplete RPE and outer retinal atrophy (iRORA), complete outer retinal atrophy, and incomplete outer retinal atrophy [44].

Specific OCT criteria have been suggested to define cRORA: (1) a region of hypertransmission of at least 250  $\mu\text{m}$  in diameter, (2) a zone of attenuation or disruption of the RPE of at least 250  $\mu\text{m}$  in diameter, (3) evidence of overlying photoreceptor degeneration, and (4) absence of scrolled RPE or other signs of an RPE tear [44]. The consensus defined MA as simply a subset of cRORA.

Early atrophy is so-called incomplete RPE and outer retinal atrophy (iRORA), and the diagnostic criteria based on OCT are (1) a region of signal hypertransmission into the choroid ( $<250\mu\text{m}$ ), (2) a corresponding zone of attenuation or disruption of the RPE ( $<250\mu\text{m}$ ), with or without persistence of basal laminar deposits, (3) evidence of overlying photoreceptor degeneration, and (4) absence of scrolled RPE or other signs of an RPE tear [48].

However, sometimes it is hard to define the evidence of overlying photoreceptor degeneration or loss compared with other features, with disagreement among different graders and readers [49]. Hence, a detailed description is used including the presence of subsidence of the inner nuclear layer (INL) and OPL, or a hyporeflective wedge-shaped band in the Henle

fiber layer (HFL) or thinning of the ONL [48,49]. In addition, the findings of photoreceptor degeneration are often accompanied with disruption of the ELM, the EZ, and the IZ [48].

#### 4. Artificial intelligence (AI) applications to MA in AMD

Although FAF is the gold standard in the detection of MA, it demands more resources and clinical time to perform. That means more time being spent on assessing FAF as this is not a procedure that is routinely performed, and in addition to the imaging time needed, there is also a need for expert interpretation, especially when evaluating MA in wet AMD. Moreover, the difficulty in evaluating foveal activity makes it difficult to make clinical decisions alone. Therefore, in conventional healthcare clinical settings, a follow-up treatment decision is made mainly using OCT imaging (for example, absence or presence of MA, rate of progression on MA, etc.) and the interpretation is dependent on the clinician's experience, knowledge, and judgment. This subjectivity may lead to lack of agreement between observers and the variability in interpretation sensitivity and specificity. For this reason, AI, an emerging field of computer science is increasingly being applied to ophthalmology, particularly to OCT imaging which provides big data in the form of multiple volumetric scans

captured at one time. The potential for early identification of disease and predicting progression using AI has been increasingly recognized. Moreover, machine learning (ML), including Deep learning (DL), is becoming a leading analytical approach for ophthalmological images, with the ability to objectively detect structural changes, staging pathological disease and locating detailed lesions in the retina [50]. This technique can be used in multi-model image segmentation, automatic classification, data analysis, and quantification [51]. DL is widely applied to retinal layer segmentation and fluid segmentation [50]. Further work is steadily advancing, focusing on abnormal structures associated with progression.

ML-based methodologies for AMD can be simply divided into several steps: pre-processing, transformation, extraction, feature selection, feature classification, learning, and initial validation. Raw images and data are extracted before undergoing pre-processing and transformation. Feature selection of the data is then performed following which images and data are further categorized in a process called feature classification to capture specific characteristics. After that, ML goes into the learning stage at which computer learns from all these chosen features to make a decision or prediction. Finally, testing is performed to evaluate this learning performance. The aim of this step is to distinguish between normal and disease through specific characteristics that are learnt before by computer itself; all these results are then compared to the ground truth using statistical

criteria including the measurement of accuracy, precision, and recall or kappa scores [50].

ML-based algorithms are currently used in the classification and prediction of progression in MA. However, most studies have a small sample size of raw images as input (Table 1 and Table 2) and are lacking external validation [72]. It is true that OCT offers the opportunity of big data primarily because of the volumetric or 3D data that is available compared to 2D. Analysis of these big data can provide much more detailed information. However, the use of AI analysis of OCT volumetric scans has historically suffered from using a small number of OCT scans in their generation of algorithms. Small sample sizes in machine learning greatly influence the final result, with the possibility of over-training and over-fitting. Another limitation is the lack of diversity in the study populations during the development of models [72].

#### 4.1. Application of OCT-AI based methodology to detect lesions associated with MA in AMD

Apostolopoulos et al. trained a model using OCT to distinguish intermediate AMD from normal retina [73]. However, the model cannot be successfully applied to more severe structural abnormalities, especially those that feature in advanced AMD. More recently, DS Kermary et al. were the first to apply ImageNet (a large visual database designed for the use of visual object recognition) to detect abnormalities of AMD,

**Table 1.** Studies using FAF/CFP-AI-based methods to detect MA.

Purpose of the study	Studies	Imaging modality	Sample size	
Automatic detection and segmentation	Deckert, A. et al. [52] (2005)	FAF	40 images from 40 eyes	
	Lee, N. et al. [53] (2008)	FAF	100 images	
	Ramsey, D. J. et al. [54] (2014)	FAF and CFP	10 patients	
	Feeny et al. [55] (2015)	CFP	143 images from 55 patients	
	Hu, Z. et al. [56] (2015)	FAF	16 eyes	
	Hu, Z. et al. [57](2018)	FAF	50 images	
	Treder, M. et al. [58] (2018)	FAF	460 images from 460 eyes (detection) 220 images from 220 eyes (classification)	
	Keenan, T. D. et al. [59](2019)	CFP	5982 images from 4582 patients	
	Prediction progression	Pfau, M. et al. [60](2019)	FAF and NIR	296 images from 201 patients
		Liefers, B. et al. [61](2020)	CFP	Model development: 409 images from 238 patients (the Rotterdam Study (RS) and Blue Mountain Eye Study (BMES)). Application: 3589 images from 376 eyes (the Age-Related Eye Disease Study (AREDS)).
Schmidt-Erfurth, U. et al. [62] (2020)		OCT and FAF	491 OCT volumes from 87 eyes in 54 patients	

**Table 2.** Studies using OCT-AI-based methods to detect MA.

Purpose of the study	Studies	Sample size
Automatic OCT detection and segmentation	L Fang et.al [63]. (2017)	117 scans from 39 patients (38 eyes)
	Z Ji et. al [64]. (2018)	A: 51 scans from 8 patients (12 eyes) B: 54 volume scans from 54 patients (54 eyes)
	R Xu et.al [65,66]. (2018/2019)	A: 51 scans from 8 patients (12 eyes) B: 54 volume scans from 54 patients (54 eyes)
	Zhang, G. et al. [67] (2021)	Model training :984 volume scans from 200 patients (399 eyes) External validation: 192 scans from 110 patients (192 eyes)
	Liefers, B. et al. [68] (2021)	307 volume scans from 307 eyes
	Derradji, Y. et al. [69] (2021)	62 volume OCT scans from 57patients (62 eyes)
	Chiang, J.N. et al. [70] (2022)	Model training: OCT volumes from 71 patients Testing: A: 1117 volumes from the general population B: 60 OCT B-scans with lesions
Prediction progression	S Niu et.al [71]. (2016)	118 scans from 29 patients (38 eyes)

such as macular neovascularization and drusen [74], which is now commonly used for AMD classification.

Turning to the segmentation step related to lesions in retinal layers, researchers applied U-Net (a cutting-edge convolutional neural network for semantic segmentation) to segment drusen based on an existing dataset with segmentation images for BM and RPE [75] as well as MA in dry AMD [64]. DeepMind's algorithm detects 10 different lesions, some of which are AMD-related lesions [76]. However, improvements in retinal layer segmentation are still needed. The current advancement helps to delineate various lesions, such as subretinal fluid, cysts, and drusen, however, this is mainly useful in diagnosis and not for quantification and monitoring of progression. Several novel OCT-based features have been identified by a number of studies monitoring the risk of AMD progression [77]. Drusen volume, PED, subretinal hyperreflective material, subretinal drusenoid deposits, subretinal/intraretinal fluid are all promising signals that can predict progression. OCT-based biomarkers have been proposed to automatically detect and classify AMD using DL methods. With the help of OCT advancement, DL provides a strong correlation between OCT-based features and AMD and presents detailed structural changes during the progression. However, it also generates very large image data volumes with often up to hundreds of B-scans every examination, which makes manual analysis of OCT laborious and impractical in many circumstances [78]. In order to tackle these issues, a number of approaches have been established using OCT images for automated or semi-automated analysis of AMD [78].

OCT provides a considerable amount of information about the retina and choroid, but manual quantitative analysis of pathognomonic features is difficult and time-consuming. However, computer-based image analysis provides precise quantitative measurement of features in an automated, objective, reliable, and repeatable way. Recently, ML-based algorithms have been validated for OCT image analysis, including segmentation and identifying specific biomarkers in OCT. The accuracy of these automated algorithms is expected to improve in the near future. Another significant clinical application is to individualize prognosis and treatment regimens.

#### 4.2. Development of AI studies to detect MA

Various fully or semi-automated algorithms on measuring areas of atrophy have been developed to assist the assessment of advanced AMD – namely MA. The earliest paper published on AI-MA was in 2005 by Deckert's team. His team developed a novel automated algorithm that removed interfering vascular structures in FAF imaging to segment and quantify MA in dry AMD [52,79]. Subsequently, Lee et al. showed another automated algorithm to delineate MA in dry AMD using FAF images in 2008. They combined the watershed transformation and generalized non-linear gradient operators for interactive segmentation and presented an intuitive and simple approach for MA segmentation [53]. Similarly, Ramsey et al. applied another automated image segmentation based on the fuzzy c-means clustering algorithm to assess MA

segmentation both in FAF and CFP images [54]. Unlike the previous two studies, Feeny et al. employed a random forest classifier for fully automated MA segmentation in patients with dry AMD in 2015. This was the first time ML was used for MA segmentation on CFP images [55]. Following these pioneering studies, many other novel ML algorithms were developed and applied to segmentate MA using FAF and/or CFP images [56–59]. Some studies also combined OCT images aid in further evaluation [80].

Many more studies have focused their efforts on detection of MA progression since 2019. Pfau et al. used linear mixed-effects models to demonstrate the relationship between multiple shape-descriptive variables and MA progression rates on FAF images [60]. Liefers and his team employed and optimized a type of encoder – decoder DL architecture to detect MA on CFP images and then applied this model to predict MA growth rate [61]. Interestingly, U Schmidt-Erfurth predicted the progression of MA based on automatic quantitation of hyperreflective foci (HRF) using OCT and relocated it to FAF images [62]. HRF can be seen as the debris of drusen that turns into collapse because of apoptosis or migrating to the retina [62,81] and they are discrete and well-circumscribed lesions with equal or greater reflectivity than the RPE band in OCT [82]. They revealed a positive correlation between HRF and MA expansion [62]. However, the majority of these studies were focused on MA in dry AMD only and did not include wet AMD. The main reason for this is due to the fact that MA in wet AMD has only been better recognized in the last 5 years [13,14]. Additionally, it is relatively difficult to detect MA in wet AMD using conventional imaging modalities, like CFP and FAF.

#### 4.3. Development and application of AI-OCT based methodology to detect MA

In the past 15 years most algorithms have been based on FAF and CFP (Table 1), however, in the recent 5 years there are more AI-OCT studies (Table 2) because of the increasing development and usage of OCT imaging. As a result, most AI-OCT studies have been carried out using convolution neural networks (CNN), the most recent and advanced AI framework, within the last 5 years. Ultimately, AI-OCT studies may be more in keeping with the recent advancements in retinal medicine than the other conventional imaging modalities. Advances in computational analysis and machine learning in OCT have predicted future potential regions of atrophy growth, enlargement rate, and foveal involvement [39]. Niu et al. made a fully automated algorithm which was able to predict MA growth using OCT segmentation and feature extraction [71]. Zhang, G. et al. applied a DL-OCT-based algorithm to classify the stages of MA in dry AMD with a larger sample size, and performed further external validation, again with a good performance [67]. During the same period, Liefers, B. et al. extracted 13 most common features in the retina and developed a convolutional neural networks (CNN) model for feature segmentation from 307 volume scans including retinal diseases other than AMD [68], including several atrophic features



in wet AMD. This model obtained a similar or higher sensitivity and accuracy compared with human graders [68]. Derradji, Y. et al. [69] developed a fully automated method (CNN) to detect and measure MA in dry AMD and also achieved a good performance. Recently, Chiang, J.N. trained a Resnet18 model to classify iRORA and cRORA in OCT B-scans, and achieved promising AUROC (area under the receiver operating characteristic curve) performance and AUPRC (area under the precision-recall curve) scores in external testing data sets [70].

Overall, high quality published works showed good agreement between human graders and automated algorithms and they achieved a promising DSC (dice similarity coefficient) score using CFP, FAF, or OCT, ranging from 0.68 to 0.89 [83]. All these results are greatly encouraging and reveal a strong potential for clinical application.

## 5. Current limitations

The main AMD studies that have analyzed risk factors about MA development [84]; however, the outcome is not strictly comparable between the studies as different imaging methods were used. Therefore, the relationship between development of atrophy and neovascularization remains unclear as well as the relationship between development of atrophy and anti-VEGF treatment.

A further considerable limitation is that most studies have a small sample size due to the availability of data. This is largely due to the difficulties in collecting sensitive data in line with the GDPR constraints, but also in ensuring uniformity and continuation in data collection. This also results in differences in data collection and regulation for studies in different countries; thus, it largely restricts the co-operation between different regions with different ethnicities. Current studies tend to focus on one population and have a potential risk to generate bias outcomes. Additionally, most studies currently are based on clinical trials or public database which cannot reflect the real-world situations.

Other limitations include the lack of diversity in small study populations. We appreciate this is of course not a limitation of AI itself but of the development and application of algorithms to disparate populations and real-world environments. However, this still seems to be a significant limiting factor.

From the clinical point of view, it is fundamental to construct an extensive, well-labeled database with information collected from multiple centers worldwide. This will enhance the diversity of the database and reduce bias accordingly, for factors including ethnicity, diseases severity, and variances in imaging protocols. However, it is profoundly challenging to acquire large-scale medical images. Furthermore, from the technical point of view, one of the significant disadvantages of the AI strategy itself is the requirement of a large amount of high-quality and well-labeled data for training and validation. Large data also demand a considerable storage space, both physical and digital.

Furthermore, the uninterpretable 'black box' feature is still a concern for medical application, with a need for researchers to hypothesize why certain features have been identified in the process as being important predictors of disease. Hence,

further research should be conducted to better visualize the learning process in the 'black box' and accelerate the DL model's interpretability.

## 6. Conclusion

MA, the endpoint of AMD, is irreversible, therefore there is an urgent and unmet need for early detection and intuitive prediction of the MA progression. OCT-AI-based methods which detect MA objectively are promising especially if they provide better monitoring tools for MA development and progression than manual analysis which is labor intensive and time-consuming. Automated OCT-AI analysis may also enable detection of MA at an earlier stage and thus may increase the therapeutic window of opportunity in the future. In addition, OCT-AI-based analysis could help in the evaluation of new drug efficacy in clinical trials. OCT-AI has strong potential to replace the traditional imaging technologies in clinical settings, but more studies are needed to further validate its superiority, effectiveness, repeatability, and accuracy.

## 7. Expert opinion

Imaging technology in ophthalmology, especially OCT, provides a reliable way to detect lesions and the progression of diseases. However, conventional manual analysis of images is time-consuming, and depends on professional knowledge and experience, which may generate human errors and bias. Therefore, deep integration of AI into ophthalmology may revolutionize the existing diagnostic pathways, which could be objective and time-saving. The strength of AI is its high efficiency, especially when handling an abundance of imaging data. Studies have demonstrated that the accuracy of automated detection is similar to manual assessment [83,85,86]. Thus, automated detection models are promising and present high accuracy, sensitivity, and specificity for disease detection [87]. Furthermore, predicting disease progression is another potential benefit from AI technology, which could provide individualized diagnosis and make personalized treatment plans, particularly suitable for those complex diseases and enhancing the success for both patients and clinicians. Therefore, OCT-AI is useful, not only to detect small MA, but also has the potential for early detection with some morphological changes and biomarkers on cross-sectional level, which is not available to see in conventional imaging modalities.

DL as a branch of ML is based on multi-layered neural network algorithms and applies the algorithm to learn to extract specific morphologic features on images [62]. Although DL may need more data than traditional ML, it has a strong capability of extracting specific lesions that are often invisible or not obvious to human readers [88]. Moreover, with the rapid improvement of AI technology, more unknown biomarkers will be identified and can reveal the potential correlations to pathologic mechanisms and their association with disease progression and pathogenesis. All these advantages provide a possibility for a better and deeper understanding of diseases.

The improvement of AI provides a potential to enhance the effectiveness of disease management. First and foremost, AI-



based prediction can reduce the economic burden of patients and improve follow-up requirements with individualized management plans. Second, this automated detection could reduce the workload of clinicians with the identification of high-risk patients most needing frequent attention improving service efficiency. Thirdly, these objective detection settings could eliminate a large number of misdiagnoses, especially in remote areas due to the lack of professional experts.

Currently, most AI-associated applications are primarily defined by one specific ML or DL architecture to segment and detect lesions. Therefore, potentially combining different AL frameworks and algorithms together can increase the accuracy and specificity of automated detection. In addition, utilizing different databases is most likely to improve the diversity of sample size and help acquire a more reliable and repeatable result. Most current studies have been focused on the automated detection and segmentation of MA, and only a few have explored the application of AI on the detection of MA progression. Better algorithms and a wider range of sample diversity should enable us to develop more accurate models for the prediction of MA advancement, which then can be applied in clinical settings.

Furthermore, most relevant studies have focused their efforts on exploring MA in dry AMD and very little work has been carried out to detect MA in wet AMD [13]. It is estimated that although dry AMD constitutes 80% of total AMD incidence with 10% resulting in severe vision loss, a much higher proportion of wet AMD patient face severe vision impairment []. Despite anti-VEGF treatments being widely administered to patients with wet AMD, visual loss is usually inevitable, and it can ultimately lead to irreversible blindness [9,15] as the endpoint of wet AMD is still MA. Therefore, automated detection of MA in wet AMD still poses a significant unmet need and has a great potential to significantly improve the current clinical practice. Another promising biomarker of atrophy emerging is DARC (Detection of Apoptosing Retinal Cells), which is able to predict progression of MA early in dry AMD and development of sub-retinal fluid in wet AMD by detecting early apoptosing cells [89]. This technology appears to be a promising predictor of retinal cell activity and has encouraging results in early-stage studies [14,15,90–92], however further validation of these early studies are still needed [89].

## Funding

This paper was not funded.

## Declaration of interest

MFC is an inventor on patents on DARC owned by UCL and licensed to Novai Ltd of which MFC is a director and shareholder. All authors have no other conflicts of interest.

## Reviewers disclosure

One reviewer is an employee of Janssen R&D LLC which is developing drug in geographic atrophy as well as developing AI algorithm. Peer reviewers on this manuscript have no other relevant financial relationships or otherwise to disclose.

## ORCID

Wei Wei  <http://orcid.org/0000-0003-3716-8395>

Radhika Pooja Patel  <http://orcid.org/0000-0003-3147-3452>

Maria Francesca Cordeiro  <http://orcid.org/0000-0001-8663-6525>

## References

1. Wong WL, Su X, Li X, et al. Global prevalence of age-related macular degeneration and disease burden projection for 2020 and 2040: a systematic review and meta-analysis. *Lancet Glob Health*. 2014 Feb;2(2):e106–16.
2. Ricci F, Bandello F, Navarra P, et al. Neovascular age-related macular degeneration: therapeutic management and new-upcoming approaches. *Int J Mol Sci*. 2020 Nov 3;21(21):8242. doi: [10.3390/ijms21218242](https://doi.org/10.3390/ijms21218242)
3. Bird AC, Bressler NM, Bressler SB, et al. An international classification and grading system for age-related maculopathy and age-related macular degeneration. The international ARM epidemiological study group. *Surv Ophthalmol*. 1995 Mar;39(5):367–374.
4. Joachim N, Mitchell P, Kifley A, et al. Incidence and progression of geographic atrophy: observations from a population-based cohort. *Ophthalmol*. 2013 Oct;120(10):2042–2050.
5. Lindblad AS, Lloyd PC, Clemons TE, et al. Change in area of geographic atrophy in the age-related eye disease study: aREDS report number 26. *Arch Ophthalmol*. 2009 Sep;127(9):1168–1174.
6. Gass JD. Drusen and disciform macular detachment and degeneration. *Arch Ophthalmol*. 1973 Sep;90(3):206–217.
7. Keenan TD, Agrón E, Domalpally A, et al. Progression of geographic atrophy in age-related macular degeneration: aREDS2 report number 16. *Ophthalmol*. 2018 Dec;125(12):1913–1928.
8. Schmitz-Valckenberg S, Sadda S, Staurenghi G, et al. GEOGRAPHIC ATROPHY: semantic considerations and literature review. *Retina*. 2016 Dec;36(12):2250–2264.
9. Chakravarthy U, Harding SP, Rogers CA, et al. Alternative treatments to inhibit VEGF in age-related choroidal neovascularisation: 2-year findings of the IVAN randomised controlled trial. *Lancet*. 2013 Oct 12;382(9900):1258–1267. doi: [10.1016/S0140-6736\(13\)61501-9](https://doi.org/10.1016/S0140-6736(13)61501-9)
10. Brown DM, Michels M, Kaiser PK, et al. Ranibizumab versus verteporfin photodynamic therapy for neovascular age-related macular degeneration: two-year results of the ANCHOR study. *Ophthalmol*. 2009 Jan;116(1):57–65.e5.
11. Heimes B, Lommatzsch A, Zeimer M, et al. Long-term visual course after anti-VEGF therapy for exudative AMD in clinical practice evaluation of the german reinjection scheme. *Graefes Arch Clin Exp Ophthalmol*. 2011 May;249(5):639–644.
12. Wightman AJ, Guymer RH. Reticular pseudodrusen: current understanding. *Clin Exp Optom*. 2019 Sep;102(5):455–462.
13. Sadda SR, Tuomi LL, Ding B, et al. Macular atrophy in the HARBOR study for neovascular age-related macular degeneration. *Ophthalmol*. 2018 Jun;125(6):878–886.
14. Abdelfattah NS, Al-Sheikh M, Pitetta S, et al. Macular atrophy in neovascular age-related macular degeneration with monthly versus treat-and-extend ranibizumab: findings from the TREX-AMD trial. *Ophthalmol*. 2017 Feb;124(2):215–223.
15. Grunwald JE, Daniel E, Huang J, et al. Risk of geographic atrophy in the comparison of age-related macular degeneration treatments trials. *Ophthalmol*. 2014 Jan;121(1):150–161.
16. Rosenfeld PJ, Shapiro H, Tuomi L, et al. Characteristics of patients losing vision after 2 years of monthly dosing in the phase III ranibizumab clinical trials. *Ophthalmol*. 2011 Mar;118(3):523–530.
17. Gillies MC, Campain A, Barthelmes D, et al. Long-term outcomes of treatment of neovascular age-related macular degeneration: data from an observational study. *Ophthalmol*. 2015 Sep;122(9):1837–1845.
18. Nishijima K, Y-S N, Zhong L, et al. Vascular endothelial growth factor-A is a survival factor for retinal neurons and a critical neuro-protectant during the adaptive response to ischemic injury. *Am J Pathol*. 2007;171(1):53–67. DOI:[10.2353/ajpath.2007.061237](https://doi.org/10.2353/ajpath.2007.061237)

19. Kilic Ü, Kilic E, Järve A, et al. Human vascular endothelial growth factor protects axotomized retinal ganglion cells in vivo by activating ERK-1/2 and akt pathways. *J Neurosci.* 2006;26(48):12439–12446. DOI:10.1523/JNEUROSCI.0434-06.2006
20. Nowacka MM, Obuchowicz E. Vascular endothelial growth factor (VEGF) and its role in the central nervous system: a new element in the neurotrophic hypothesis of antidepressant drug action. *Neuropeptides.* 2012;46(1):1–10.
21. Foxton RH, Finkelstein A, Vijay S, et al. VEGF-A is necessary and sufficient for retinal neuroprotection in models of experimental glaucoma. *Am J Pathol.* 2013;182(4):1379–1390. DOI:10.1016/j.ajpath.2012.12.032
22. Gillies MC, Hunyor AP, Arnold JJ, et al. Macular atrophy in neovascular age-related macular degeneration: a randomized clinical trial comparing ranibizumab and aflibercept (RIVAL study). *Ophthalmol.* 2020;127(2):198–210. DOI:10.1016/j.ophtha.2019.08.023
23. Steinle NC, Pearce I, Monés J, et al. Impact of baseline characteristics on geographic atrophy progression in the FILLY trial evaluating the complement C3 inhibitor pegcetacoplan. *Am J Ophthalmol.* 2021;227:116–124.
24. Goldberg R, Heier JS, Wyckoff CC, et al. Efficacy of intravitreal pegcetacoplan in patients with geographic atrophy (GA): 12-month results from the phase 3 OAKS and DERBY studies. *Invest Ophthalmol Vis Sci.* 2022;63(7):1500.
25. Jaffe GJ, Westby K, Csaky KG, et al. C5 inhibitor avacincaptad pegol for geographic atrophy due to age-related macular degeneration: a randomized pivotal phase 2/3 trial. *Ophthalmol.* 2021;128(4):576–586. DOI:10.1016/j.ophtha.2020.08.027
26. Schmitz-Valckenberg S, Sahel JA, Danis R, et al. Natural history of geographic atrophy progression secondary to age-related macular degeneration (geographic atrophy progression study). *Ophthalmol.* 2016 Feb;123(2):361–368.
27. Jaffe GJ, Schmitz-Valckenberg S, Boyer D, et al. Randomized trial to evaluate tandoespiron in geographic atrophy secondary to age-related macular degeneration: the GATE study. *Am J Ophthalmol.* 2015 Dec;160(6):1226–1234.
28. Vujosevic S, Toma C, Sarao V, et al. Color fundus autofluorescence to determine activity of macular neovascularization in age-related macular degeneration [article]. *Transl Vis Sci Technol.* 2021 Feb;10(2):10.
29. von Rückmann A, Fitzke FW, Bird AC. Distribution of fundus autofluorescence with a scanning laser ophthalmoscope. *Br J Ophthalmol.* 1995 May;79(5):407–412.
30. Schmitz-Valckenberg S, Brinkmann CK, Alten F, et al. Semiautomated image processing method for identification and quantification of geographic atrophy in age-related macular degeneration. *Invest Ophthalmol Vis Sci.* 2011 Sep 29;52(10):7640–7646. doi: 10.1167/iovs.11-7457
31. Hwang JC, Chan JW, Chang S, et al. Predictive value of fundus autofluorescence for development of geographic atrophy in age-related macular degeneration. *Invest Ophthalmol Vis Sci.* 2006 Jun;47(6):2655–2661.
32. Lindner M, Böker A, Mauschitz MM, et al. Directional kinetics of geographic atrophy progression in age-related macular degeneration with foveal sparing. *Ophthalmol.* 2015 Jul;122(7):1356–1365.
33. Keilhauer CN, Delori FC. Near-infrared autofluorescence imaging of the fundus: visualization of ocular melanin. *Invest Ophthalmol Vis Sci.* 2006;47(8):3556–3564.
34. Kellner U, Kellner S, Weinitz S. Fundus autofluorescence (488 NM) and near-infrared autofluorescence (787 NM) visualize different retinal pigment epithelium alterations in patients with age-related macular degeneration. *Retina.* 2010;30(1):6–15.
35. Abdelfattah NS, Sadda J, Wang Z, et al. Near-infrared reflectance imaging for quantification of atrophy associated with age-related macular degeneration. *Am J Ophthalmol.* 2020 Apr;212:169–174.
36. Bussel II, Wollstein G, JS S. OCT for glaucoma diagnosis, screening and detection of glaucoma progression. *Br J Ophthalmol.* 2014 Jul;98(Suppl 2):ii15–9.
37. Jeong H, Cho NH, Jung U, et al. Ultra-fast displaying spectral domain optical doppler tomography system using a graphics processing unit. *Sensors.* 2012;12(6):6920–6929. DOI:10.3390/s120606920
38. Schmidt-Erfurth U, Waldstein SM. A paradigm shift in imaging biomarkers in neovascular age-related macular degeneration. *Prog Retin Eye Res.* 2016 Jan;50:1–24.
39. Schmidt-Erfurth U, Klmscha S, Waldstein SM, et al. A view of the current and future role of optical coherence tomography in the management of age-related macular degeneration. *Eye (Lond).* 2017 Jan;31(1):26–44.
40. Ouyang Y, Heussen FM, Hariri A, et al. Optical coherence tomography-based observation of the natural history of drusenoid lesion in eyes with dry age-related macular degeneration. *Ophthalmol.* 2013 Dec;120(12):2656–2665.
41. Schuman SG, Koreishi AF, Farsiou S, et al. Photoreceptor layer thinning over drusen in eyes with age-related macular degeneration imaged in vivo with spectral-domain optical coherence tomography. *Ophthalmol.* 2009 Mar;116(3):488–496.e2.
42. Yehoshua Z, Rosenfeld PJ, Gregori G, et al. Progression of geographic atrophy in age-related macular degeneration imaged with spectral domain optical coherence tomography. *Ophthalmol.* 2011 Apr;118(4):679–686.
43. Fleckenstein M, Charbel Issa P, Helb HM, et al. High-resolution spectral domain-OCT imaging in geographic atrophy associated with age-related macular degeneration. *Invest Ophthalmol Vis Sci.* 2008 Sep;49(9):4137–4144.
44. Sadda SR, Guymer R, Holz FG, et al. Consensus definition for atrophy associated with age-related macular degeneration on OCT: classification of atrophy report 3. *Ophthalmol.* 2018;125(4):537–548. DOI:10.1016/j.ophtha.2017.09.028
45. Fleckenstein M, Schmitz-Valckenberg S, Adrien C, et al. Tracking progression with spectral-domain optical coherence tomography in geographic atrophy caused by age-related macular degeneration. *Invest Ophthalmol Vis Sci.* 2010 Aug;51(8):3846–3852.
46. Bearely S, Chau FY, Koreishi A, et al. Spectral domain optical coherence tomography imaging of geographic atrophy margins. *Ophthalmol.* 2009 Sep;116(9):1762–1769.
47. Spaide RF. Outer retinal atrophy after regression of subretinal drusenoid deposits as a newly recognized form of late age-related macular degeneration. *Retina.* 2013 Oct;33(9):1800–1808.
48. Guymer RH, Rosenfeld PJ, Curcio CA, et al. Incomplete retinal pigment epithelial and outer retinal atrophy in age-related macular degeneration: classification of atrophy meeting report 4. *Ophthalmol.* 2020 Mar;127(3):394–409.
49. Wu Z, Pfau M, Blodi BA, et al. OCT signs of early atrophy in age-related macular degeneration: interreader agreement: classification of atrophy meetings report 6. *Ophthalmol Retina.* 2021 Mar 23;6(1):4–14. doi: 10.1016/j.oret.2021.03.008
50. Sarhan MH, Nasser MA, Zapp D, et al. Machine learning techniques for ophthalmic data processing: a review. *IEEE J Biomed Health Inform.* 2020;24(12):3338–3350. DOI:10.1109/JBHI.2020.3012134
51. Lu W, Tong Y, Yu Y, et al. Applications of artificial intelligence in ophthalmology: general overview. *J Ophthalmol.* 2018;2018:5278196.
52. Deckert A, Schmitz-Valckenberg S, Jorzik J, et al. Automated analysis of digital fundus autofluorescence images of geographic atrophy in advanced age-related macular degeneration using confocal scanning laser ophthalmoscopy (cSLO). *BMC Ophthalmol.* 2005;5(1):1–8. DOI:10.1186/1471-2415-5-8
53. Lee N, Smith RT, Laine AF, editors. Interactive segmentation for geographic atrophy in retinal fundus images. 2008 42nd Asilomar Conference on Signals, Systems and Computers, 26–29 October 2008, Pacific Grove, California; 2008: IEEE.
54. Ramsey DJ, Sunness JS, Malviya P, et al. Automated image alignment and segmentation to follow progression of geographic atrophy in age-related macular degeneration. *Retina.* 2014;34(7):1296–1307. DOI:10.1097/IAE.0000000000000069
55. Feeny AK, Tadarati M, Freund DE, et al. Automated segmentation of geographic atrophy of the retinal epithelium via random forests in AREDS color fundus images. *Comput Biol Med.* 2015;65:124–136.

56. Hu Z, Medioni GG, Hernandez M, et al. Automated segmentation of geographic atrophy in fundus autofluorescence images using supervised pixel classification. *J Med Imaging*. 2015;2(1):014501. DOI:10.1117/1.JMI.2.1.014501
57. Hu Z, Wang Z, Sadda SR. Automated segmentation of geographic atrophy using deep convolutional neural networks. *Medical imaging 2018: computer-aided diagnosis*. SPIE; 2018:1057511.
58. Treder M, Lauer mann JL, Eter N. Deep learning-based detection and classification of geographic atrophy using a deep convolutional neural network classifier. *Graefes Arch Clin Exp Ophthalmol*. 2018;256(11):2053–2060.
59. Keenan TD, Dharssi S, Peng Y, et al. A deep learning approach for automated detection of geographic atrophy from color fundus photographs. *Ophthalmol*. 2019;126(11):1533–1540. DOI:10.1016/j.ophtha.2019.06.005
60. Pfau M, Lindner M, Goerdt L, et al. Prognostic value of shape-descriptive factors for the progression of geographic atrophy secondary to age-related macular degeneration. *Retina*. 2019;39(8):1527–1540. DOI:10.1097/IAE.0000000000002206
61. Liefers B, Colijn JM, González-Gonzalo C, et al. A deep learning model for segmentation of geographic atrophy to study its long-term natural history. *Ophthalmol*. 2020;127(8):1086–1096. DOI:10.1016/j.ophtha.2020.02.009
62. Schmidt-Erfurth U, Bogunovic H, Grechenig C, et al. Role of deep learning-quantified hyperreflective foci for the prediction of geographic atrophy progression. *Am J Ophthalmol*. 2020 Aug;216:257–270.
63. Fang L, Cunefare D, Wang C, et al. Automatic segmentation of nine retinal layer boundaries in OCT images of non-exudative AMD patients using deep learning and graph search. *Biomed Opt Express*. 2017;8(5):2732–2744. DOI:10.1364/BOE.8.002732
64. Ji Z, Chen Q, Niu S, et al. Beyond retinal layers: a deep voting model for automated geographic atrophy segmentation in SD-OCT images. *Transl Vis Sci Technol*. 2018;7(1):1. DOI:10.1167/tvst.7.1.1
65. Xu R, Niu S, Gao K, et al., editors. *Intelligent Computing Theories and Application: 14th International Conference, ICIC 2018, Wuhan, China, August 15-18, 2018, Proceedings, Part II 14*; 2018:493–503. Springer.
66. Xu R, Niu S, Chen Q, et al. Automated geographic atrophy segmentation for SD-OCT images based on two-stage learning model. *Comput Biol Med*. 2019;105:102–111.
67. Zhang G, Fu DJ, Liefers B, et al. Clinically relevant deep learning for detection and quantification of geographic atrophy from optical coherence tomography: a model development and external validation study. *Lancet Digit Health*. 2021 Oct;3(10):e665–675.
68. Liefers B, Taylor P, Alsaedi A, et al. Quantification of key retinal features in early and late age-related macular degeneration using deep learning. *Am J Ophthalmol*. 2021 Jun;226:1–12.
69. Derradji Y, Mosinska A, Apostolopoulos S, et al. Fully-automated atrophy segmentation in dry age-related macular degeneration in optical coherence tomography. *Sci Rep*. 2021 Nov 8;11(1):21893. doi: 10.1038/s41598-021-01227-0
70. Chiang JN, Corradetti G, Nittala MG, et al. Automated identification of incomplete and complete retinal epithelial pigment and outer retinal atrophy using machine learning. *Ophthalmol Retina*. 2022;7(2):118–126. DOI:10.1016/j.oret.2022.08.016
71. Niu S, de Sisternes L, Chen Q, et al. Fully automated prediction of geographic atrophy growth using quantitative spectral-domain optical coherence tomography biomarkers. *Ophthalmol*. 2016 Aug;123(8):1737–1750.
72. Romond K, Alam M, Kravets S, et al. Imaging and artificial intelligence for progression of age-related macular degeneration. *Exp Biol Med*. 2021;246(20):15353702211031547. DOI:10.1177/15353702211031547
73. Apostolopoulos S, Ciller C, De Zanet S, et al. RetiNet: automatic AMD identification in OCT volumetric data. *Invest Ophthalmol Visual Sci*. 2017;58(8):387.
74. Kermany DS, Goldbaum M, Cai W, et al. Identifying medical diagnoses and treatable diseases by image-based deep learning. *Cell*. 2018;172(5):1122–1131. e9. DOI:10.1016/j.cell.2018.02.010
75. Ronneberger O, Fischer P, Brox T, editors. 18th International Conference, Munich, Germany. *Proceedings, Part III 18*, October 5–9, 2015; 2015:234–241. Springer International Publishing.
76. De Fauw J, Ledsam JR, Romera-Paredes B, et al. Clinically applicable deep learning for diagnosis and referral in retinal disease. *Nature Med*. 2018;24(9):1342–1350. DOI:10.1038/s41591-018-0107-6
77. Lei J, Balasubramanian S, Abdelfattah NS, et al. Proposal of a simple optical coherence tomography-based scoring system for progression of age-related macular degeneration. *Graefes Arch Clin Exp Ophthalmol*. 2017 Aug;255(8):1551–1558.
78. Saha S, Nassisi M, Wang M, et al. Automated detection and classification of early AMD biomarkers using deep learning. *Sci Rep*. 2019 Jul 29;9(1):10990. doi: 10.1038/s41598-019-47390-3
79. Arslan J, Samarasinghe G, Benke KK, et al. Artificial intelligence algorithms for analysis of geographic atrophy: a review and evaluation. *Transl Vis Sci Technol*. 2020;9(2):57. DOI:10.1167/tvst.9.2.57
80. Yang Q, Dong Y, Tokuda K, et al. Automated geographic atrophy detection in OCT volumes. *Invest Ophthalmol Visual Sci*. 2018;59(9):3225.
81. Christenbury JG, Folgar FA, O'Connell RV, et al. Progression of intermediate age-related macular degeneration with proliferation and inner retinal migration of hyperreflective foci. *Ophthalmol*. 2013;120(5):1038–1045. DOI:10.1016/j.ophtha.2012.10.018
82. Ho J, Witkin AJ, Liu J, et al. Documentation of intraretinal retinal pigment epithelium migration via high-speed ultrahigh-resolution optical coherence tomography. *Ophthalmol*. 2011;118(4):687–693. DOI:10.1016/j.ophtha.2010.08.010
83. Chu Z, Wang L, Zhou X, et al. Automatic geographic atrophy segmentation using optical attenuation in OCT scans with deep learning. *Biomed Opt Express*. 2022;13(3):1328–1343. DOI:10.1364/BOE.449314
84. Sadda SR, Guymer R, Monés JM, et al. Anti-vascular endothelial growth factor use and atrophy in neovascular age-related macular degeneration: systematic literature review and expert opinion. *Ophthalmol*. 2020 May;127(5):648–659.
85. van Grinsven MJ, Buitendijk GH, Brussee C, et al. Automatic identification of reticular pseudodrusen using multimodal retinal image analysis. *Invest Ophthalmol Vis Sci*. 2015 Jan 8;56(1):633–639. doi: 10.1167/iovs.14-15019
86. Schlegl T, Waldstein SM, Bogunovic H, et al. Fully automated detection and quantification of macular fluid in OCT using deep learning. *Ophthalmol*. 2018 Apr;125(4):549–558.
87. Balyen L, Peto T. Promising artificial intelligence-machine learning-deep learning algorithms in ophthalmology. *Asia Pac J Ophthalmol (Phila)*. 2019 May;8(3):264–272.
88. Schmidt-Erfurth U, Sadeghipour A, Gerendas BS, et al. Artificial intelligence in retina. *Prog Retin Eye Res*. 2018 Nov;67:1–29.
89. Cordeiro MF, Hill D, Patel R, et al. Detecting retinal cell stress and apoptosis with DARC: progression from lab to clinic. *Prog Retin Eye Res*. 2021;86:100976.
90. Chakravarthy U, Harding SP, Rogers CA, et al. A randomised controlled trial to assess the clinical effectiveness and cost-effectiveness of alternative treatments to inhibit VEGF in age-related choroidal neovascularisation (IVAN). *Health Technol Assess*. 2015;19(78):1. DOI:10.3310/hta19780
91. Sitnitska V, Altay L, Enders P, et al. Onset of retinal pigment epithelium atrophy subsequent to anti-VEGF therapy in patients with neovascular age-related macular degeneration. *Ophthalmologica*. 2019;241(3):154–160. DOI:10.1159/000492924
92. Kuehlewein L, Dustin L, Sagong M, et al. Predictors of macular atrophy detected by fundus autofluorescence in patients with neovascular age-related macular degeneration after long-term ranibizumab treatment. *Ophthalmic Surg Lasers Imaging Retina*. 2016;47(3):224–231. DOI:10.3928/23258160-20160229-04