

## REVIEW ARTICLE

# Factors that influence the outcomes of surgical endodontic treatment

Yuan-Ling Ng  | Kishor Gulabivala 

Unit of Endodontology, Department of Restorative Dentistry, UCL Eastman Dental Institute, London, UK

**Correspondence**

Yuan-Ling Ng, Unit of Endodontology, Department of Restorative Dentistry, UCL Eastman Dental Institute, Bloomsbury Campus, Rockefeller Building, 21 University Street, London WC1E 6DE, UK.  
Email: [y.ng@ucl.ac.uk](mailto:y.ng@ucl.ac.uk)

**Abstract**

Surgical endodontic treatment encompasses a broad spectrum of procedures, amongst which root-end cavity preparation and filling, retrograde root canal treatment and through-and-through endodontic surgery, may be classified under the umbrella term 'Root-end surgery'. This narrative review considers the available data on periapical healing, soft tissue healing, tooth survival and oral health-related quality of life (OHRQoL), following root-end surgery and the factors that affect its outcomes. The pooled periapical healed rate for the studies published up to 2021 was 69% (95% CI: 65%, 73%) but increased to 76% (95% CI: 66%, 86%) when only data from the 2020's studies were analysed. The prognostic factors consistently reported for periapical healing have included: pre-operative periapical lesion with complete loss of buccal plate, quality of root-end preparation, remaining thickness of apical root dentine and restorative status. Soft tissue healing of the reflected flap was found to have a positive association with periapical healing. The survival rates following root-end surgery range from 48% to 93%, with failure of periapical healing associated with root and crown fracture, being the predominant reasons for tooth extraction. The factors influencing impact of root-end surgery on patients' quality of life could not be adequately evaluated due to design flaws in the available studies. In conclusion, if root canal treatment failure due to leakage through cracks, fractures or restoration margin are excluded, the remaining cases may represent localized residual infection and inflammation at the periapex that should be amenable to predictable management with the aid of modern root-end surgery.

**KEYWORDS**

endodontic surgery, outcomes, patient reported outcome, periapical healing, soft tissue healing, tooth survival

**INTRODUCTION**

Surgical endodontic treatment is normally employed to manage apical periodontitis when the orthograde approach (root canal treatment or retreatment) to the apical

root anatomy (and infection) is irretrievably obstructed. In addition, a surgical approach maybe indicated when the periradicular tissues require direct visualization, debridement, excision, biopsy or management due to biomechanical failures. This treatment modality is not normally

This is an open access article under the terms of the [Creative Commons Attribution-NonCommercial-NoDerivs](https://creativecommons.org/licenses/by-nc-nd/4.0/) License, which permits use and distribution in any medium, provided the original work is properly cited, the use is non-commercial and no modifications or adaptations are made.

© 2023 The Authors. *International Endodontic Journal* published by John Wiley & Sons Ltd on behalf of British Endodontic Society.

considered to be the first line of periapical disease management and usually follows (primary) root canal treatment or (secondary) root canal retreatment. Given the high and predictable periapical healing rates (over 80%) following root canal treatment or root canal retreatment (Ng et al., 2011), the number of cases requiring surgical endodontics should constitute a relatively small proportion of those with periapical disease requiring management. Furthermore, the spreading insight about the efficacy of root canal retreatment (Roda et al., 2021) should lead to a relative decline in the need for surgical endodontic treatment. However, it is unknown, whether this is universally, or actually the case (Johnson et al., 2021). By virtue of these circumstances, surgical cases are highly likely to include teeth that are biologically or biomechanically compromised. It would be clinically valuable to be able to segregate such cases into those with favourable or unfavourable prognosis based on observable pre-operative factors.

Root-end surgery is one of a broad spectrum of surgical endodontic treatment modalities that may include amongst them root amputation, removal of fractured apical root fragments and repair of iatrogenic perforations or cervical resorptive defects. Root-end surgery is probably the most commonly performed of the surgical procedures. This narrative review focuses on the factors influencing periapical healing following root-end surgery, which is further classified here into: apicectomy plus root-end cavity preparation and filling (Harty et al., 1970); retrograde root canal treatment (Reit & Hirsch, 1986); or through-and-through endodontic surgery (Harty et al., 1970). Also included in the consideration are such cases requiring adjunctive decompression or concurrent tissue regenerative procedures. The review also reports on other outcomes following root-end surgery, including, soft tissue healing of the reflected muco-gingival flap, tooth survival and oral health-related quality of life (OHRQoL).

## Outcome measures for root-end surgery

An outcome measure for a treatment intervention may constitute any consistently anticipated and measurable consequence of the treatment (Velentgas et al., 2013). The particular outcome investigated or reported may depend on the perspective or context of the study interest. The PICOTS framework formulated by the European Society of Endodontology for the ESE S3-level clinical practice guidelines consensus (Duncan et al., 2021) classified and prioritized a number of main and additional patient- and clinician-reported outcomes. The most 'critical outcomes' were deemed to be 'tooth survival', 'pain, tenderness, swelling, need for medication (analgesics,

antibiotics)', 'presence of sinus tract', 'satisfactory soft tissue healing', 'radiographic evidence of reduction of apical lesion size (loose criteria)' and 'radiographic evidence of return to normal periodontal ligament space (strict criteria)'. The next level, 'important outcomes' included 'tooth function (fracture, restoration longevity)', 'need for further intervention', 'OHRQoL' and 'tooth mobility' (Duncan et al., 2021). From a clinician's perspective, the most important outcome for root-end surgery is typically restoration of periapical health or periapical inflammation resolution, and this forms the prime focus of this review. Periradicular inflammation arises from *interaction between* intra or extracanal microbiota (and their products) with host defences, consequently, its resolution depends upon prevention or termination of such *interaction*. Chronic inflammation, without superimposed acute exacerbation, is typically asymptomatic and thus remains undetected without direct imaging. Image interpretation, in turn, requires surrogate measures that are correlated to histology. Symptomatic lesions typically manifest one or a host of clinical presenting signs and symptoms that may point to the source and nature of the problem. Clinicians would normally make interpretive judgements about such gathered data to synthesize a mental histological picture of the source tooth. Therefore, categorizing such presenting signs and symptoms as discrete outcomes (pain, tenderness, swelling and radiographic evidence of return to normal periodontal ligament space) independently, as suggested (Duncan et al., 2021; Shah et al., 2022), may not prove clinically meaningful.

The ideal healing outcome should include periapical tissue regeneration with cementum formation over the resected root-end and the root-end cavity filling material, together with regeneration of the destroyed cortical plates. The radiographic criteria (or surrogate measures) for determining periapical healing after root-end surgery, based on periapical radiographs, are well established (Molven et al., 1987; Rud et al., 1972a; Tables 1 and 2). Whilst the new imaging modality of *cone beam* computed tomography (CBCT) has attracted the development of adapted criteria (Schloss et al., 2017; von Arx et al., 2016; Tables 1 and 2). The CBCT-PAI criteria use a six-point scoring system (0 representing intact periapical bone structure to five representing diameter of periapical radiolucency >8 mm) with two additional variables, expansion of cortical bone and destruction of cortical bone (Estrela et al., 2008). As for conventional radiography, CBCT is also prone to artefacts. One such problematic artefact is beam hardening caused by highly radiodense objects such root fillings and metal restorations, which may compromise diagnostic sensitivity (Kruse et al., 2019). Furthermore, CBCT-detected periapical lesions following repeat root-end surgery may be free of inflammation, as found from biopsy in 42% of

**TABLE 1** Classification of periapical healing following apical surgery (for use with periapical radiographs)

Rud et al. (1972a) and Molven et al. (1987)	Schloss et al. (2017)
<p>Complete healing</p> <ul style="list-style-type: none"> <li>Reformation of a periodontal space with:               <ul style="list-style-type: none"> <li>Normal width &amp; lamina dura to be followed around the apex,</li> <li>Slight increase in width of apical periodontal space but less than twice the width of noninvolved parts of the root, or</li> <li>Tiny defect in the lamina dura (maximum 1 mm<sup>2</sup>) adjacent to the root filling; or</li> </ul> </li> <li>Complete bone repair with:               <ul style="list-style-type: none"> <li>Bone bordering the apical area does not have the same density as surrounding noninvolved bone, or</li> <li>No apical periodontal space can be discerned</li> </ul> </li> </ul> <p>Incomplete healing (scar tissue)</p> <ul style="list-style-type: none"> <li>The rarefaction has decreased in size or remained stationary with:               <ul style="list-style-type: none"> <li>Bone structure recognized within the rarefaction,</li> <li>The irregular periphery of the rarefaction and demarcation by a compact bone border,</li> <li>The rarefaction located asymmetrically around the apex, or</li> <li>Angular connection between the rarefaction and the periodontal space; or</li> </ul> </li> <li>An isolated scar tissue in the bone with findings above</li> </ul> <p>Uncertain healing</p> <ul style="list-style-type: none"> <li>The rarefaction has decreased in size with:               <ul style="list-style-type: none"> <li>The size larger than twice the width of the periodontal space,</li> <li>Lamina dura-like bone structures around the border,</li> <li>A circular or semicircular periphery,</li> <li>Symmetrical location around the apex as a funnel-shaped extension of the periodontal space,</li> <li>Bone structure discernible within the bony cavity, or</li> <li>A collar-shaped increase in width of lamina dura coronal to the radiolucency</li> </ul> </li> </ul> <p>Unsatisfactory healing (failures)</p> <ul style="list-style-type: none"> <li>The rarefaction has enlarged or is unchanged</li> <li>If a case still demonstrated 'uncertain healing' four years post-operatively, the treatment should be considered a failure (Rud et al., 1972a)</li> </ul>	<p>Complete healing</p> <ul style="list-style-type: none"> <li>Reformation of periodontal space of normal width and lamina dura over the entire resected and un-resected root surfaces</li> <li>Slight increase in width of apical periodontal space over the resected root surface, but less than twice the width of noninvolved parts of the root</li> <li>Small defect in the lamina dura surrounding the root-end filling</li> <li>Complete bone repair with discernible lamina dura; bone bordering the apical area does not have the same density as surrounding noninvolved bone</li> <li>Complete bone repair. Hard tissue covering the resected root-end surface completely. No apical periodontal space can be discerned</li> </ul> <p>Limited healing</p> <p>Complete healing can be observed in immediate vicinity of the resected root surface, but the site demonstrates one of the following conditions</p> <ul style="list-style-type: none"> <li>The continuity of the cortical plate is interrupted by an area of lower density</li> <li>A low density area remains asymmetrically located around the apex or has an angular connection with the periodontal space</li> <li>Bone has not fully formed in the area of the former access osteotomy</li> <li>In areas with pre-existing periodontal disease or physiologic fenestrations un-resected root surfaces do not demonstrate bone coverage and/or periodontal reattachment</li> </ul> <p>Uncertain healing</p> <p>The volume of the low density area appears decreased and demonstrates one of the following conditions:</p> <ul style="list-style-type: none"> <li>The thickness is larger than twice the width of the periodontal space</li> <li>The location is symmetrically around the apex as funnel-shaped extension of the periodontal space</li> </ul> <p>Unsatisfactory healing</p> <ul style="list-style-type: none"> <li>The volume of the low density area appears enlarged or unchanged</li> </ul>

such cases (Kruse et al., 2017). Therefore, radiolucencies may not always equate to inflammation, especially post-surgery.

## Outcomes related to duration of follow-up

Any measurement of periapical healing should be cognizant of the healing dynamics and, therefore, duration of follow-up. Data on periapical healing after root-end surgery collected following the principles of systematic review and meta-analyses (Ng et al., 2007) up to the end of 2021,

showed that complete periapical healing was reached after 24 to 48 months with a slight decline thereafter (Figure 1). The trajectory is depicted by the following data: 51% (95% CI: 42%, 60%) after 6 months, 70% (95% CI: 65%, 74%) after 12 months, 75% (95% CI: 65%, 83%) after 24 months, 76% (95% CI: 55%, 93%) after 48 months and 70% (95% CI: 64%, 77%) after more than 48 months. To complicate matters, early 'complete healing' may not be permanent, as delayed failure (13%–42%) has been reported 5–10 years later, irrespective of type of technique (traditional or modern) or materials used (Frank et al., 1992; Huang et al., 2020; Song et al., 2012; von Arx, Jensen, et al., 2019). Further delving

**TABLE 2** Classification of periapical healing following apical surgery (for use with CBCT; Chen et al., 2015 and von Arx et al., 2016)

<b>Chen et al. (2015)</b>				
<b>Index</b>	<b>Definition</b>	<b>Score 0</b>	<b>Score 1</b>	<b>Score 2</b>
R	Resection plane (cut root face)	No bone deposition (no formation of PDL space)	Partial bone deposition (partial formation of PDL space)	Complete bone deposition (complete formation of PDL space of normal width)
A	Apical area (former bone defect)	No apparent bone formation	Partial bone formation	Complete bone formation
C	Cortical plate (access bone window)	Not reestablished	Re-established, but concave	Re-established and flat

<b>B index (combining the A and C indices above; von Arx et al., 2016)</b>				
<ul style="list-style-type: none"> <li>• B-score 2: Complete hard tissue ('bony trabecular') fill of former lesion/osteotomy site and formation of an intact cortical plate in its anatomically correct shape</li> <li>• B-score 1: Any situation not attributable to B-scores 0 or 2</li> <li>• B-score 0: Neither hard tissue fill of former lesion/osteotomy site nor formation of cortical plate</li> </ul>				

into these failures reveals that the majority constitute maxillary incisors with a history of childhood dentoalveolar trauma, or maxillary premolars and mandibular molars with complex apical root canal anatomy. If such cases could be filtered out, the predictive value of healing at 1 year may remain high (87%) over the following 10 years (von Arx, Jensen, et al., 2019).

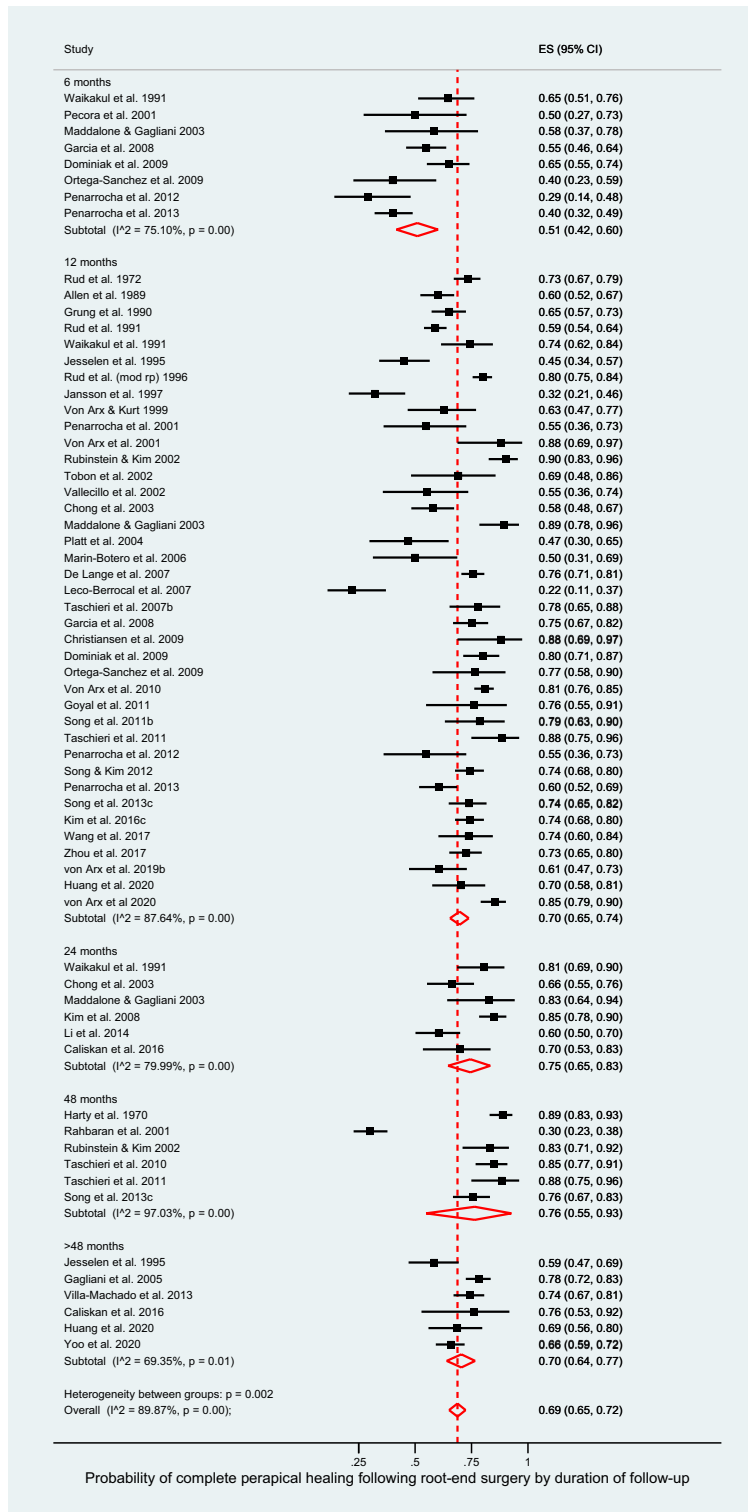
Periodic long-term follow-up is ideal for tracking healing dynamics but is prone to high drop-out rates at the longer durations. This has prompted the adoption of shorter recall periods coupled with acceptance of 'incompletely healed' cases as 'successful'. Unfortunately, charting the long-term healing trajectory of cases classified as 'incompletely healed' reveals variations in healing rates and patterns and even reversals. For example, 50% of lesions classified as 'incompletely healed' at 1 year did not progress to complete healing at 4 years and 15% even regressed after the first year (Song et al., 2014). Furthermore, 5.8% of 'incompletely healed' cases remained within the same category, whilst 6.7% regressed to 'diseased' status (Song et al., 2012). Analysing long-term failures revealed that all (except one) had been classified as 'incompletely healed' at an earlier stage, suggesting reversals in periapical status; the category is, therefore, a poor predictor of long-term healing after surgery (Song et al., 2014).

The consensus-based ESE S3-level clinical practice guidelines established a minimum of 12 months follow-up for most main outcome measures including periapical healing, and a minimum of 6 months for OHRQoL (Duncan et al., 2021). However, the data presented above suggest it may be wiser to adopt strict radiographic criteria to determine periapical healing after root-end surgery and to follow-up cases for a minimum of 2 years, or better still, for as long as possible (Duncan et al., 2021).

## Factors influencing periapical healing

Determination of the outcomes of surgical interventions and the factors that may influence such outcomes is complicated by variations in and the interactions between the pre-operative status, nature and quality of the intra-operative management and the post-operative care and tooth restoration. Surgical procedures vary in detail despite standardization of protocols due to the operator's interpretations, technical skills and decision-making. Root-end surgery involves a set of sequential steps, the outcome of each step dependent on the effectiveness of the previous. Clinical research on factors influencing the outcomes of root-end surgery is, therefore, reliant on accurate data gathering on each step, as well as interactions between successive steps (Ng et al., 2007, 2008).

The factors influencing periapical healing following root-end surgery (prognostic factors) have been evaluated in many systematic reviews (Del Fabbro et al., 2007; Del Fabbro & Taschieri, 2010; Del Fabbro, Taschieri, Lodi, et al., 2009; Niederman & Theodosopoulou, 2003; Setzer et al., 2010, 2012; Tsisis et al., 2009, 2011, 2013; Von Arx et al., 2010). The quality of available data on individual steps varies from study to study but in general may contain well-categorized procedural data per study, although perhaps not directly comparable between studies. The main deficiency lies in the adoption by most studies of 'loose' radiographic criteria for judging periapical healing without standardization of follow-up duration, resulting in considerable variation in the outcome data. A meta-analysis by the authors, of extracted data from 65 studies published up to the end of 2021, revealed 69% (95% CI: 65%, 73%) pooled periapical healed rates, which increased to 76% (95% CI: 66%, 86%) when only data from the 2020's studies were analysed. The improvement could



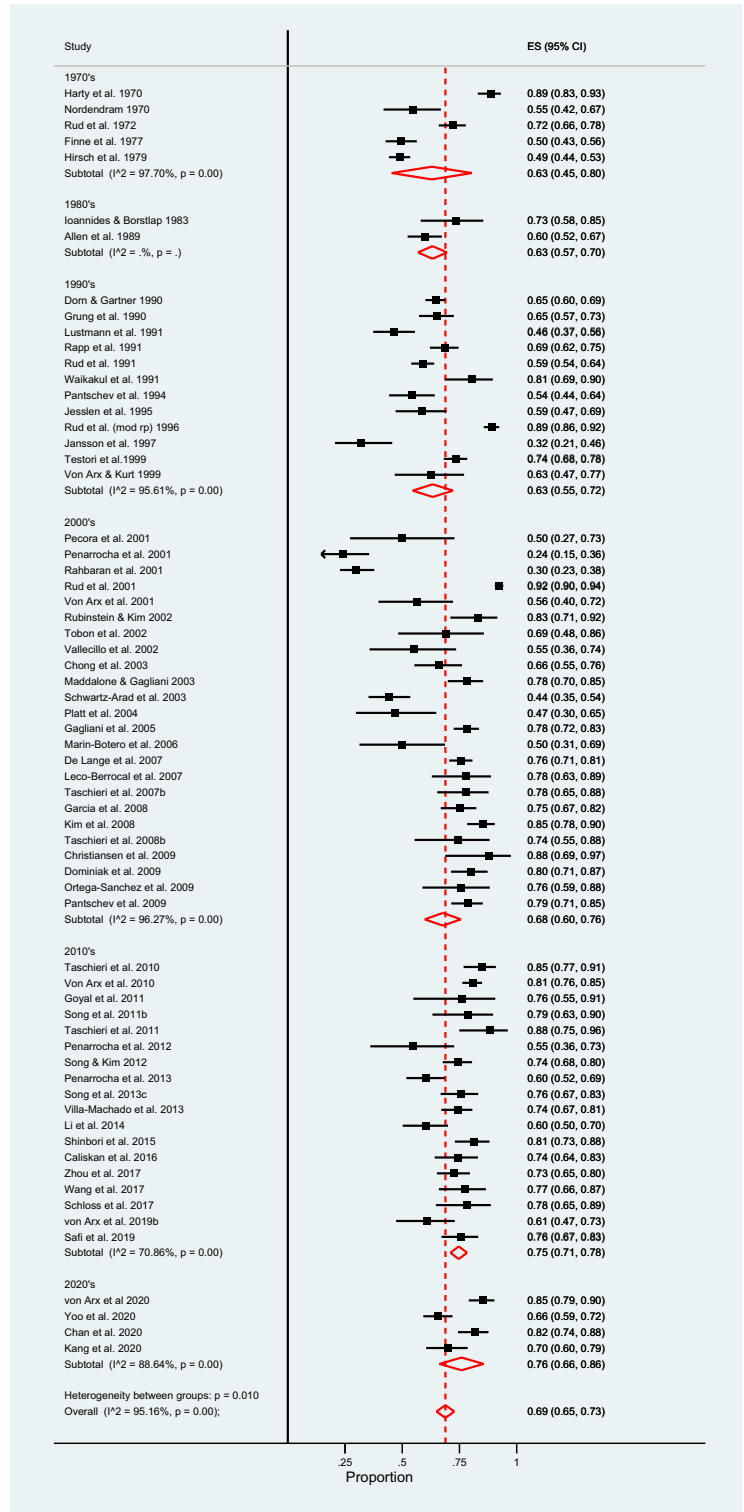
**FIGURE 1** Forest plot showing pooled and individual study's probability of complete periapical healing following apical surgery by 'duration of follow-up'.

be attributed to the adoption of the so-called 'modern' technique (involving magnification, root-end resection with minimal or no bevel, retrograde cavity preparation with ultrasonic tips and modern retrograde root canal filling materials) in the recent studies (Figure 2). The previously reported pooled success rate of 92% (95% CI: 86%, 95%) for root-end surgeries performed using the 'modern' technique was even higher, due to the use of loose criteria

for periapical healing in most studies (Tsesis et al., 2009, 2013). An earlier meta-analysis (Setzer et al., 2010) also revealed substantially higher pooled periapical healing rates associated with 'microsurgical' (94%; 95% CI: 89%, 98%) compared to 'traditional' root-end surgeries (59%; 95% CI: 55%, 63%). Unfortunately, the latter analysis is likely to have favoured microsurgical rather than the traditional approach. The reasons for this suggestion include



**FIGURE 2** Forest plot showing pooled and individual study's probability of complete periapical healing following apical surgery, stratified by 'decade of publication'.



the observations that most of the reviewed studies on the 'traditional approach' had used strict criteria for judging periapical healing, did not confirm coronal restoration quality or quality of previous root canal treatments, and included cases with a diverse range of follow-up durations (6 to 276 months). In contrast, most of the microsurgical outcome studies adopted strict selection criteria (adequate coronal restoration, free of pre-existing cracks) and judged

periapical healing using loose criteria with follow-up durations of only 12–24 months. Such deviations in study characteristics should be considered to exert potential confounding effects in the analyses of individual prognostic factors. The prognostic factors may be grouped into pre-operative patient factors, intra-operative treatment factors and post-operative functional factors and are analysed below accordingly.

## Patient and tooth factors

### *Effect of age, sex and health*

Previous data on the potential impact of the patient's age and sex on periapical healing following root-end surgery have been inconclusive (Barone et al., 2010; Bliggenstorfer et al., 2021; Çalışkan et al., 2016; Chan et al., 2020; Harty et al., 1970; Kreisler et al., 2013; Li et al., 2014; Mehta et al., 2014; Pallarés-Serrano et al., 2021; Peñarrocha-Diago et al., 2018; Shinbori et al., 2015; Song, Jung, et al., 2011; Song, Kim, Shin, et al., 2013; Taha et al., 2021; Truschnegg et al., 2020; Villa-Machado et al., 2013; von Arx et al., 2012; von Arx, Janner, et al., 2020; von Arx, Jensen, et al., 2019; Wang et al., 2017; Yoo et al., 2020; Zhou et al., 2017; Zuolo et al., 2000). Most studies dichotomized the patients' ages ( $\leq 45$  vs.  $> 45$  years) for analyses, consequently losing valuable information. The Toronto study phases 1–5 (Barone et al., 2010; Wang, Knight, et al., 2004) reported significantly better outcomes in patients older than 45 years, having accounted for 'intra-operative periapical crypt size' as a confounding factor. However, their overall drop-out rate at 4–10-years post-operatively was high (50%), being more than 10% higher in the younger age group, leading to a potentially biased conclusion. In contrast, analysis of the impact of age as a continuous variable in a logistic regression model accounting for potential confounding, revealed that every additional year in age at the time of surgery, was associated with 6% higher odds of failure (Kim et al., 2020). Unfortunately, the study had failed to incorporate the follow-up period in their regression model to investigate the effect of age by duration of follow-up. Another study with a high recall rate (87%) found a 10% higher 1-year healed rate in the younger group ( $< 45$  years old) but no obvious differences in healed rates between the two age groups at the 5-year follow-up (von Arx et al., 2012). It is plausible that younger patients experience more rapid initial healing but observed over longer periods, the differences between the age groups may vanish.

All except two studies (Mehta et al., 2014; Villa-Machado et al., 2013) restricted their surgical management to patients in good general health, and consequently were unable to report any significant influence attributable to this factor. Where specifically evaluated, tobacco-smoking showed no significant influence on periapical healing after root-end surgery (Kreisler et al., 2013; Villa-Machado et al., 2013; von Arx et al., 2012), despite having a negative impact on periodontal surgery (Ng et al., 2015). The only exception was reported by Truschnegg et al. (2020), who found the 10–13-year failure rate of root-end surgery based on periapical health was higher amongst smokers. They attributed the finding to the development of apico-marginal

or furcation involvements. It may be concluded that smoking could have an indirect effect on periapical healing via compromised surgical flap healing, leading to periodontal breakdown, whilst the effect of other medical conditions could not be ascertained as surgical treatments were performed mostly in healthy patients.

### *Effect of tooth type*

The root-end surgery outcome data published up to the early 1990s predominantly originated from studies on single-rooted anterior teeth, but posterior teeth have been increasingly managed and evaluated for periapical healing outcomes in studies since then. The higher success rates associated with anterior (compared to posterior; Kim et al., 2020; Lai et al., 2022; Song, Jung, et al., 2011; von Arx et al., 2012; Yoo et al., 2020) or maxillary (compared to mandibular; Testori et al., 1999) teeth even after controlling for confounding in statistical analyses, may possibly be related to superior surgical access for anterior and maxillary teeth. Maxillary lateral incisors famously carry the reputation for higher failure rates, but this may be related to a higher frequency of scar tissue healing (Grung et al., 1990; Rud & Andreasen, 1972). This has been attributed to the propensity for perforation of the palatal cortical plate due to a palatal root curvature, resulting in the development of 'through-and-through' periapical defects after labial surgical access. Other teeth/roots with a higher predilection for failure include those with an isthmus between two-canals, such as in molars (Kim, Song, et al., 2016). This is attributed to vertical root fractures caused by the practice of inclusion of the isthmus in the retrograde preparation, which may weaken the root-end (Kim, Song, et al., 2016; von Arx, Jensen, et al., 2019). A revised guideline for canal isthmus management may perhaps need to be considered.

### *Effect of periapical status*

The extent and nature of pre-operative periapical disease can be characterized by clinical (swelling, sinus, pain), radiographic (size and anatomical extent of radiolucency) and histopathological features, which may all have a profound influence on periapical healing outcome. These general trends are consistent with those observed for non-surgical root canal (re)treatment.

Signs of infection and inflammation (swelling, sinus tract, symptoms) at the time of periapical surgery have a significant negative impact on periapical healing (Kreisler et al., 2013; Peñarrocha et al., 2011; Villa-Machado et al., 2013; Von Arx et al., 2010; von Arx, Vinzens-Majaniemi, et al., 2007). This may be attributed to a more-difficult-to-eradicate infection, due either to its virulence or 'extraradicular' location (Von Arx et al., 2010).

The size of the pre-operative periapical bony crypt has a strong negative impact on root-end surgery outcome,

although the exact biological causes are a matter of speculation. Possible explanations for the observation include the nature of the host-microbial interaction that wrought the extensive pre-operative tissue destruction in the first place. Such pathological tissue may be less amenable to complete removal, and bony repair in such lesions may take longer, involving fibrous repair, particularly when both buccal and palatal cortical plates have been eroded (through and through). Incomplete healing is the predominant healing pattern associated with through-and-through lesions (Lai et al., 2022; Taschieri, Del Fabbro, Testori, Saita, & Weinstein, 2008) and may be classified as ‘unsuccessful healing’ in studies using strict criteria.

The prognostic impact of lesion size has been analysed by dichotomization of a continuous range of values using several thresholds, including 5 mm diameter (Li et al., 2014; Zhou et al., 2017), 10 mm diameter (Villa-Machado et al., 2013) or 50 mm<sup>3</sup> volume (Kim, Jung, et al., 2016). Data may be categorized into 3 (Çalışkan et al., 2016) or 6 (Kim & Kratchman, 2006; von Arx & Cochran, 2001) groups (Table 3) for analyses. Çalışkan et al. (2016) supported the view that larger lesions took longer to heal and reported that the average healing times in ascending order were: 6, 9.5 and 16 months for small (2–5.9 mm), medium (6–9.9 mm) and large (10–20 mm) lesions, respectively. Larger lesions may also additionally display periodontal communication with the apical lesion or complete dehiscence of the buccal plate, falling into groupings categorized as classes IIB–IIIb (von Arx & Cochran, 2001) or categories D–F (Kim & Kratchman, 2006).

Root-end surgery typically involves elevation of labial and/or lingual muco-gingival tissues with putatively healthy marginal and periodontal structures, to expose the periapical lesion. The presence of a sinus tract may tether the flap to the granuloma causing a more complicated elevation. In addition, the elevated flap may reveal a prior and natural absence of the labial buccal bone, known as root dehiscence. This results in the so-called apico-marginal or endodontic-periodontal defect (Lai et al., 2022; Yoo et al., 2020), which may heal with a junctional epithelial attachment along the denuded root surface. Such healing may potentially extend to the periapical bony crypt (Andreassen & Rud, 1972), resulting in periapical scar healing (Kreisler et al., 2013; Song, Kim, Lee, et al., 2013) or even failure to heal (Kim et al., 2008, 2020; Lai et al., 2022; Song et al., 2018; Song, Jung, et al., 2011; Song, Kim, Lee, et al., 2013). The suggestion that an epithelial attachment may be more susceptible to periodontal breakdown (Tsesis et al., 2011) does not, however, accord with the periodontal literature (Beaumont et al., 1984). Unfortunately, none of the studies had characterized the periodontal communication profile (narrow vs. broad periodontal pocket) or the primary origin of the defect (endodontic vs. periodontal),

TABLE 3 Classification of lesions (Kim & Kratchman, 2006; von Arx & Cochran, 2001)

Categories of lesion	
von Arx and Cochran (2001)	<p><b>Ia:</b> Bone defect confined to periapical region</p> <p><b>Ib:</b> Periapical bone defect with erosion of lingual cortical plate</p> <p><b>IIa:</b> Periapical and concomitant marginal lesion without communication</p> <p><b>IIb:</b> Periapical and concomitant marginal lesion with communication</p> <p><b>IIIa:</b> Lateral juxtarradicular lesion</p> <p><b>IIIb:</b> Lateral juxtarradicular lesion with communication to marginal lesion</p>
Kim and Kratchman (2006)	<p><b>A:</b> Absence of a periapical lesion, no mobility and normal pocket depth, but unresolved symptoms after nonsurgical approaches have been exhausted. Clinical symptoms are the only reason for the surgery</p> <p><b>B:</b> Presence of a small periapical lesion together with clinical symptoms. The tooth has normal periodontal probing depth and no mobility</p> <p><b>C:</b> Large periapical lesion progressing coronally but without periodontal pocket and mobility</p> <p><b>D:</b> Clinically similar to those in class C, but have deep periodontal pockets</p> <p><b>E:</b> Deep periapical lesion with an endodontic-periodontal communication to the apex but no obvious fracture</p> <p><b>F:</b> Apical lesion with complete denudement of the buccal plate but no mobility (dehiscence)</p>



nor analysed whether the dehiscence was a consequence of natural anatomical, physiological or pathological mechanisms. When such cases had been managed with a resorbable collagen membrane, the bony dehiscence reportedly had no significant influence on periapical healing (Zhou et al., 2017). However, their findings should be interpreted with caution as the radiodensity of resorbable membrane and graft materials may interfere with radiographic interpretation of periapical healing.

Biopsied periapical tissues most frequently return a histopathological diagnosis of 'granuloma' or 'cyst' (Hirsch et al., 1979), however, once successfully enucleated and infection source controlled, the nature of the diseased tissue is unlikely to influence the healing mechanisms (Hirsch et al., 1979; Li et al., 2014; Li & Jin, 2010; Mehta et al., 2014; Sutter et al., 2020; Taha et al., 2021; Wälivaara et al., 2011; Zuolo et al., 2000).

In summary, the *size* of periapical lesion may affect the time to heal after surgery or the type of healing but not whether it will ultimately heal. Soft tissue healing dominates in through-and-through lesions or in the presence of dehiscence. Although periodontal involvement with periapical lesions, classified as IIB–IIIb (von Arx & Cochran, 2001) or D–F (Kim & Kratchman, 2006), had a significant negative impact on healing, there is a possibility that it may be overcome by periodontal regenerative procedures, although definitive evidence is pending.

#### *Effect of prior endodontic and restorative status*

The quality of previous root canal treatment (judged by root filling quality) and coronal restoration, as well as any history of nonsurgical retreatment or root-end surgery may all influence the surgical outcome. The quality of the coronal restoration independently has a huge influence on the outcome of root canal treatment (Ng et al., 2011). Although not many root-end surgery studies provide equivalent data on restorative status, an adequate coronal restoration is considered a prerequisite for embarking on such surgery (Azim et al., 2021; Çalışkan et al., 2016; Chan et al., 2020; Rahbaran et al., 2001; Safi et al., 2019; Shinbori et al., 2015; Taha et al., 2021; Truschnegg et al., 2020). Unfortunately, many recent studies fail to declare the quality of the pre-operative coronal restoration (Buniag et al., 2021; Kim et al., 2020; Pallarés-Serrano et al., 2021; Sutter et al., 2020; von Arx, Janner, et al., 2020; von Arx, Jensen, et al., 2019; Von Arx, Marwik, & Bornstein, 2019; Yoo et al., 2020).

The presence of an intra-radicular post might be deemed to have a negative impact on periapical healing due to the perceived risks of de-cementation or coronal leakage. In fact, a more realistic risk is posed by potential for developing cracks through stress concentration in root dentine pre- or post-surgery. Two studies (Lustmann

et al., 1991; Rahbaran et al., 2001) confirm this supposition with a significantly lower (11%–14%) healed rate (strict criteria) in the presence of a post. Consistent with these observations, vertical root fracture was revealed to be the predominant reason for nonhealing following root-end surgery (Chan et al., 2020), as well as the main reason for regression of complete healing (Song et al., 2014) amongst teeth with a post. In contrast, some studies show minimal or insignificant difference in healing rates (loose criteria; Bliggenstorfer et al., 2021; Pallarés-Serrano et al., 2021; Tsesis et al., 2013), but their short recall intervals may not allow detection of incipient cracks, and loose criteria for periapical healing may not allow sufficient discrimination of outcome.

Although a satisfactorily disinfected and obturated root canal system is sometimes considered a prerequisite for root-end surgery (Chan et al., 2020), a key indicator for surgical management is the inability to access the apical canal termini in orthograde fashion. A number of studies show no significant prognostic influence attributable to the root-filling density (Mehta et al., 2014; Rahbaran et al., 2001; Song, Jung, et al., 2011; Yoo et al., 2020), its apical extent (Mehta et al., 2014; Pallarés-Serrano et al., 2021; Song et al., 2018; Song, Jung, et al., 2011; Song, Kim, Shin, et al., 2013; Villa-Machado et al., 2013; von Arx et al., 2012; Yoo et al., 2020) or overall compaction quality (Bliggenstorfer et al., 2021; Çalışkan et al., 2016; Huang et al., 2020; Kim et al., 2020; Lai et al., 2022; Sutter et al., 2020; Taha et al., 2021; Wälivaara et al., 2011; Wang et al., 2017). Meanwhile other studies have reported contrary findings, for example, Zhou et al. (2017) using bivariate analyses found the pre-existing root filling quality to be a major prognostic factor. Whilst the Toronto study (Barone et al., 2010) reported that pre-operative root fillings of 'adequate length' (compared with short or over-extended root fillings) were associated with an increased odds of disease-persistence after surgery, despite apparently accounting for confounding factors. It may be noteworthy though that in their 'adequate root filling' group, retrograde root-end fillings had *not* been placed in 11% ( $n = 15$ ) of cases, similar to the number of failed cases ( $n = 19$ ) in the group. It may be argued that the apical extent of pre-existing root filling may exert no prognostic value if an adequate retrograde root filling were placed.

Arguably better circumstances for periapical healing may be provided by performing 'more complete retrograde root canal treatment'. That is, extending retrograde root canal instrumentation and obturation as far as possible coronally (Reit & Hirsch, 1986). Such retrograde root canal treatment has been deployed with promising results in teeth without prior root canal treatment to avoid damaging complex coronal restorations, including bridge abutments (Jonasson et al., 2008, 2017).

In conclusion, the quality of coronal restoration has a significant influence on periapical healing after surgery, consistent with the findings for nonsurgical root canal (re) treatment and should be a prior requirement. In contrast, the quality of the pre-existing root filling does not exert a predictable effect on periapical healing after root-end surgery, presumably because of the adequacy of root-end management.

#### *Effect of repeat surgery*

Failure of technically well-performed root-end surgery may be caused by residual intra-radicular infection or new intra-radicular infection (through coronal leakage or root fracture), coupled with poor apical seal or extraradicular infection. Repeat surgery adopting the same strategy may succumb to the same biological or biomechanical causes of failure. A modified strategy may also fail if the cause is not identified and addressed, explaining the higher failure rate in such cases (Mehta et al., 2014; Peterson & Gutmann, 2001; Von Arx et al., 2010).

After excluding root-end surgery failures due to periodontal disease, root fracture or perforation, the predominant reasons for first-time surgery failures identified in one study were absence of root-end filling, incorrect root-end preparation and untreated apical canal or isthmus (Song, Shin, & Kim, 2011). Such failures ( $n = 42$ ) could be managed using modern (contemporary) microsurgery and materials, achieving complete healing in 79% of cases (Song, Shin, & Kim, 2011). Therefore, *repeat surgeries* addressing the cause of failure and performed to current guideline standards may achieve similar periapical healing outcomes as *primary surgery*.

### Surgical treatment factors

The principles and operative protocols of root-end surgery were established over a hundred years ago (Gutmann & Harrison, 1991) and evolved relatively slowly until the introduction of magnification coupled with microsurgical instruments and bioactive root-end filling materials around 30 years ago (Setzer & Kratchman, 2022). Meanwhile improvements in surgical principles and techniques have also diffused across to endodontics from surgical advances in periodontics over a similar timeframe. These have included guided tissue and bone regeneration, as well as flap design and management (Setzer & Kratchman, 2022). In addition, three-dimensional workflows (3D workflows) have diffused across from prosthodontics based on CBCT imaging and digital technology. The 3D workflows allow enhanced pre-operative *in-silico* planning, 3D-printed surgical training models and guided surgical execution

(surgical guide templates and guided navigation; Setzer & Kratchman, 2022). The efficacy of some of these contemporary techniques and materials has been investigated in randomized trials and observational studies (Setzer & Kratchman, 2022) but are at an early stage of development with little definitive data to comment on service delivery impact.

#### *Effect of magnification and illumination*

The available data on the impact of magnification and illumination on root-end surgery outcomes are contradictory and open to interpretation. In one study, the use of magnification was attributed a significantly higher success rate compared to absence of its use (Tsesis et al., 2006), but unfortunately, the results were not adjusted for potentially confounding surgical details, such as traditional versus contemporary approaches. Another study (Villa-Machado et al., 2013) found use of magnification to be an insignificant prognostic factor.

A systematic review and meta-analyses (Del Fabbro & Taschieri, 2010) including three studies (Taschieri et al., 2006; Taschieri, Del Fabbro, Testori, & Weinstein, 2008; von Arx et al., 2003) concluded that the type of magnification (magnifying loupes, surgical microscope or endoscope) had no significant impact on root-end surgery outcome. However, adoption of a different analytical approach (Tsesis et al., 2013) led to the conclusion that a surgical microscope or endoscope might achieve significantly better outcomes than loupes. Although this finding did not hold true when the analyses were stratified by root-end filling material, once again showing the impact of underlying confounding factors. Whilst advocates of microscope-use may be keen to convey the beneficial impact of magnification on periapical healing outcomes, the evidence is simply absent at present. Nevertheless, there can be no doubting the benefit of improved magnification and illumination for clarity of view of the surgical site and the potential for improved detection of problems. Whether this advantage is then converted into the ability to better execute the procedure or enhance healing remains to be proven.

#### *Effect of surgical crypt size*

Investigation of the effect of the size of *surgical crypt* on periapical healing is limited by its significant correlation with *pre-osteotomy lesion* size (Barone et al., 2010; Mehta et al., 2014; Rud et al., 1972b). Curiously, the Toronto study phases 1–5 revealed that whilst the pre-operative lesion size (dichotomized by 5 mm) was *not* a significant prognostic factor for periapical healing, the intra-operative crypt size (dichotomized by 10 mm) was (Barone et al., 2010). Their rationale for selecting

different thresholds for dichotomization in the two scenarios was not given and the distribution of small (88%) versus larger (12%) bony crypts was substantially uneven. The 'significant finding' might have been a type I error. Ideally, the median value should be chosen at the cut-off point, and better still, the size of lesion or bone crypt could have been analysed as a continuous variable. Amongst the potential parameters of the surgical crypt size and extent (*width, height [ $\leq 3$  mm vs.  $> 3$  mm], depth, estimated volume, relationship to any marginal bone loss and complete loss of the buccal plate pre-operatively*), only height and complete loss of buccal plate were found to be significant predictors for periapical healing (Song, Kim, Shin, et al., 2013). However, all the failed cases in the  $\leq 3$  mm height group had complete loss of the buccal plate, inferring that height was not the negative predictor.

In addition to the listed surgical crypt size parameters, proximity of the periapical lesion(s) or root apices of maxillary posterior teeth to the floor of the maxillary sinus was a key consideration when making decisions on root-end surgery (Qualtrough et al., 2020). The perceived problem is related to the risk of Schneiderian membrane perforation, potentially resulting in maxillary sinusitis and compromised periapical healing. The reported incidence of maxillary sinus perforation during root-end surgery ranges from 10% to 50% (Oberli et al., 2007) with a higher risk when separated by less than 1 mm (von Arx, Kach, et al., 2020). Apart from post-operative nose bleeding, four of the six teeth with maxillary sinus perforation displayed complete healing, 1 year post-operatively, and none of them displayed altered physiology of the maxillary sinus (Taschieri et al., 2021).

Apart from the single parameter, 'complete loss of buccal cortical plate', the evidence does not support the notion of surgical crypt parameters exerting a significant influence on periapical healing. All efforts should be made to preserve remaining buccal cortical bone over the root surface, balancing the most conservative crypt opening size with the requirements for optimal visualization and surgical access for lesion enucleation and root-end management.

#### *Effect of apical resection bevel, root-end cavity preparation and filling*

The key goal of root-end surgery is resection of the root-end containing the complex infected anatomy (Wada et al., 1998), identification and location of main canals, their negotiation, preparation, debridement and *effectively sealing* the exposed termini with an appropriate filling material. Each of these interventional steps requires precise surgical manipulation with appropriate tools, used

correctly, in the right orientation, and with light interfacial forces to avoid iatrogenic damage.

The tools for driving the burs for cutting have successively improved, progressing from air-motor handpieces to micromotor and then air-rotor handpieces to facilitate the osteotomy and root-end resection. Back exhaust air-rotor handpieces were introduced to avoid iatrogenic air embolism during these steps. However, their contribution, if any, to enhancing periapical healing, has not been evaluated. Other major advances in these procedural steps have included more efficient cutting tools (burs and ultrasonic tips), minimal bevel root-end resection aided by microsurgery to minimize the number of exposed dentinal tubules, better aligned more conservative and deeper cavity preparations using ultrasonically driven tools, and modern root-end filling materials with better bacterial sealing and biological healing responses.

Many of the earlier outcome studies (August, 1996; Grung et al., 1990; Harty et al., 1970; Nordenram, 1970; Rapp et al., 1991; Rud et al., 1972b) included data from cases with root resections without any form of root-end cavity preparation or filling. These studies reported that root-end surgery adopting satisfactorily performed traditional root-end cavity fillings conferred no advantage, or even had a negative effect on periapical healing, when the orthograde root filling was also satisfactory. However, it should be noted that in most of these studies (August, 1996; Grung et al., 1990; Harty et al., 1970; Rud et al., 1972b), the orthograde root filling was *placed at the time of the surgery*. The inference is that the procedure was more akin to the so-called 'through-and-through approach'. That is, orthograde canal preparation coupled with orthograde root filling at the time of surgery, enabling direct visual inspection of apical canal debridement, cleanliness and sealing. Their reported negative effect of 'root-end cavity and filling' was a reference to the more traditional surgical approaches using a class 1 cavity.

The 'through-and-through surgical approach' is generally advocated in the presence of uncontrolled persistent inflammatory exudation into the root canal system. Obturation in the presence of such exudate, a sign of persistent infection, would potentially risk adaptation of a root-filling material against a contaminated canal surface, which as well as compromising the setting of the accompanying sealer, would create a higher prospect of failure. A 'through-and-through surgical approach' should allow a more direct and thorough decontamination of the apical root canal and external root surfaces, enabling the root-filling material to be compacted against a clean and relatively drier surface. Such an approach whilst more feasible in maxillary anterior teeth, may be less so in some posterior and mandibular teeth or roots.

Apical resection of satisfactorily filled roots coupled with 'reverse compaction and burnishing' of the pre-existing orthograde gutta-percha root filling without retrograde filling is associated with lower success rates. The 1-year (Christiansen et al., 2009) and 6-year (Kruse et al., 2016) healing rates in a randomized controlled trial for such an approach were significantly lower (52% and 55%, respectively) than those managed using root-end cavities and MTA fillings (97% and 86%, respectively). Opting not to use a root-end cavity plus filling to seal the canal terminus is regarded as one of the most common causes of root-end surgery failure (Song, Shin, & Kim, 2011).

Minimal bevel resections, coupled with ultrasonic retrotip cavity preparations extending 3 mm coronally into the canals, have consistently shown better periapical healing rates compared to the traditional approach of high bevel angles, coupled with a bur-cut root-end class 1 cavity (de Lange et al., 2007; Mehta et al., 2014; Setzer et al., 2010; Testori et al., 1999; Tsesis et al., 2006; Villa-Machado et al., 2013). Even deeper retrograde penetration into the root canals may be achieved using 'retrograde root canal treatment' (wherein *root canals are prepared in retrograde fashion using stainless steel files*). Such an approach could prepare the canal from the terminus to the end of an intra-radicular post, yielding a 71% healed rate (Reit & Hirsch, 1986). These authors advocated such an approach for anterior teeth with sub-optimal prior root fillings and a desire to retain the integrity of the coronal restoration. Reit and Hirsch (1986) concluded that gutta-percha retrofillings extending to within 0.5 mm of the post (78%) was associated with better healed rates compared with those with more than 0.5 mm of unfilled space up to the post (50%). Consistent with this principle, some advocate the use of 5–9 mm long ultrasonic tips, except that the tools are too rigid for manipulation in the manner of the original procedure. The outcomes of such an approach remained unreported at the time of writing.

Thus far, the outcomes of the three approaches have only been compared in an unpublished Eastman study (Mehta et al., 2014). 'Retrograde root canal treatment' yielded the highest periapical healing rates (strict 59%, loose 88%), followed by the 'conventional ultrasonic retro-preparation approach' (strict 53%, loose 80%), followed by the 'through-and-through approach' (strict 48%, loose 74%; Mehta et al., 2014). The effect of coronal extent of the retrograde cleaning in the first two approaches was not further investigated (Mehta et al., 2014). However, the question was explored in another study using CBCT for periapical healing measurement (Safi et al., 2019). They found that the coronal extent of the root-end filling had a profoundly positive effect on periapical healing (odds ratio = 14; 95% confidence interval: 4, 49). Unfortunately, the data on the range of filling penetrations and any interactive effect of

post presence or orthograde root-filling quality were absent. Furthermore, their analyses did not control for potential confounding effects. In contrast, two other studies using periapical radiographs for assessment, reported that the coronal extent of root-end filling ( $\leq 2$  mm vs.  $> 2$  mm) had no significant influence on periapical healing (Barone et al., 2010; Villa-Machado et al., 2013). Similarly, von Arx, Kach, et al. (2020) reported that the coronal extent of MTA root-end fillings and their width, as well as the residual peripheral root dentine thickness did not have any significant influence on periapical healing outcome. However, it is worth noting that the surgeries were performed by an experienced oral surgeon and the mean coronal extent of root-end filling was only  $2.02 \pm 1.24$  mm (range: 0.78–3.80 mm). The reported peripheral root dentine in all cases was 1 mm or thicker and more than 90% of the retro-cavities were aligned with the long-axis of the root. Their data may imply that an optimal standard of root-end management should leave at least 1 mm of sound peripheral root dentine without major deviation of the root-end cavity from the canal axis. The Buffalo study (Azim et al., 2021) concurred that occurrence of 'major procedural errors' (*excessive damage to the root or supporting structure, or improper sealing of portals of exit*) was the only significant prognostic factor for surgical procedures performed by their endodontic residents and faculty. They did not further analyse the effect of each type of error.

In summary, root-end cavity preparation and filling should normally be performed as a standard procedure during root-end surgery unless the adopted procedure was 'through-and-through surgery'. The coronal extent and width of the preparation would depend on the quality of existing root filling, the potential to cut the retrograde cavity along with the main canal axis without deviation, and root dentine thickness.

#### *Effect of root-end filling material*

An array of root-end cavity filling materials has been used and tested over the years. Root-end filling materials evaluated in outcome studies have included: amalgam, super ethoxybenzoic acid (super-EBA<sup>®</sup>), zinc oxide eugenol based intermediate restorative material (IRM<sup>®</sup>), gutta-percha, composite resin, glass ionomer cement (GIC), Cavit<sup>®</sup>, mineral trioxide aggregate (MTA) and other calcium silicate-based materials. The influence on periapical healing attributed to root-end filling materials in observational studies should be interpreted with caution due to the potential confounding effects of all preceding root-end management steps. For example, amalgam is used in traditional bur-cut 'class I type' root-end cavities, whilst, flowable composite (Retropast<sup>™</sup>) is used in 'saucer-shaped' cavities in conjunction with a dentine bonding agent (Rud et al., 1991). The rationale for the latter design is to increase



the surface area for adhesion and encourage polymerization shrinkage towards, rather than away from the dentine surface. The Retroplast™ cavity and filling yielded significantly better periapical healing (73%) than GIC (31%) in a randomized controlled trial (Jensen et al., 2002). Other randomized controlled trials on root-end surgery have found no significant differences in periapical healing between a variety of root-end filling materials (gutta-percha with AH plus sealer, IRM, super-EBA, MTA, bioceramic-based material; Chong et al., 2003; Lindeboom et al., 2005; Kim, Ku, et al., 2016; Safi et al., 2019; Song & Kim, 2012; Wälivaara et al., 2009; Wälivaara et al., 2011; Zhou et al., 2017; Table 4). It is, once again, noteworthy that most of these trials followed their cases for only 1 year and adopted loose criteria for judging periapical healing.

#### Effect of haemostatic agents

Haemostatic agents are often used to control intra-operative bleeding during surgery and may include adrenalin-impregnated cotton pellets, local anaesthetic-saturated pellets with epinephrine, ferric sulphate, bone wax, thrombin, calcium sulphate, gelatine-based foam, oxidized cellulose or bovine-derived collagen. Their use (Wang, Knight, et al., 2004) regardless of type (4% articaine with adrenaline 1:100 000 or epinephrine impregnated dressing vs. aluminium chloride paste [Expasyl™, Produits Dentaires Pierre Rolland]; Peñarrocha-Diago et al., 2013, Peñarrocha-Diago et al., 2018) did not confer any significant influence on periapical healing outcomes. Peñarrocha-Diago et al. (2018) further concluded that the efficacy of haemostasis was not a significant periapical healing predictor.

#### Effect of application of regenerative techniques

Techniques for guided tissue regeneration (GTR) used in periodontics, including use of membranes and grafting

materials have been seen as potential solutions for some endodontic problems. Their use has been advocated for management of 'through-and-through' (missing both buccal and palatal cortical plates) periapical defects but evidence for their benefit in randomized controlled trials is inconsistent (Pecora et al., 2001, Tobón et al., 2002, Taschieri et al., 2007, Taschieri, Del Fabbro, Testori, Saita, & Weinstein, 2008; Table 5). A cohort study (Azim et al., 2021) assessing the pattern of apical bone healing with CBCT revealed that GTR did not improve tissue healing around the resected root-end or in the periradicular region but may enhance complete reestablishment of the cortical plates. In addition, GTR may have a beneficial role in cases with 'perio-endo' bone defects or a pre-existing dehiscence (Zhou et al., 2017). Future innovations may potentially expand the spectrum of cases indicated for root-end surgeries, but the current evidence is sparse and relatively weak.

#### Novel targeted endodontic microsurgery approaches

Digital or three-dimensional work-flow technology has recently been adopted and applied to root-end surgery, following its successful use for dental implant placement (Rosenfeld et al., 2006a, 2006b, 2006c). One such application involves the design, fabrication and application of a surgical guide based on pre-operative 3D CBCT data. The purpose of the guide is to aid precise location, direction and control of the osteotomy dimensions to access the periapical lesion and root-end without damaging adjacent teeth, vital structures or excessive sacrifice of bone. Such 'Targeted endodontic microsurgery' has been used to guide root-end resection in anatomically complex cases (Buniag et al., 2021). The reported 1–2-year periapical healed rate for this approach was 92% (20/24), on par with the freehand approach.

**TABLE 4** Randomized trials comparing different retrograde filling materials

Study	Duration (year)	Criteria for healing	Healed rates							
			GP (%)	IRM® (%)	Super-EBA™ (%)	GIC (%)	RP (%)	MTA (%)	BS (%)	Findings
Jensen et al. (2002)	1	R				31	73			$p < .001$
Chong et al. (2003)	2	M		87				92		NS
Lindeboom et al. (2005)	1	R		87				92		NS
Wälivaara et al. (2009)	1	M	90	85						NS
Wälivaara et al. (2011)	1–2	M		91	82					NS
Song and Kim (2012)	1	M			96			96		NS
Kim, Song, et al. (2016)	4	M			90			92		NS
Zhou et al. (2017)	1	R, M, S						93	94	NS
Safi et al. (2019)	1	R & M						95	92	NS

Abbreviations: R = Rud et al. (1972a); M = Molven et al. (1987); S = Shinbori et al. (2015); BS, bioceramic-based material; GP = Gutta-percha and AH plus sealer; GIC, Glass ionomer cement; NS, no significant difference.



**TABLE 5** Randomized trials evaluating efficacy of guided tissue regeneration on bone healing

Study	Duration (year)	Lesion type	Comparisons	Healed/healing rates
Pecora et al. (2001)	1	T&T (>10 mm)	<b>Test:</b> calcium silicate ( $n = 9$ ) <b>Control:</b> No graft ( $n = 9$ )	L: 100%; S: 78% L: 89%; S: 33%
Tobón et al. (2002)	1	Not specified	<b>Test 1:</b> Nonbioabsorbable CoreTex® membrane ( $n = 10$ ) <b>Test 2:</b> GoreTex® membrane + graft (PsteoGen®; $n = 10$ ) <sup>a</sup> <b>Control:</b> No graft or membrane ( $n = 10$ ) <sup>a</sup>	L: 78%; S: 67% L: 100%; S: 100% L: 88%; S: 44%
Taschieri et al. (2007)	1	>10 mm (PD ≤5 mm)	<b>Test:</b> Anorganic bovine bone graft + membrane ( $n = 24$ ) <b>Control:</b> No graft or membrane ( $n = 35$ )	S: 88% (4w); 75% (T&T) S: 82% (4w); 62% (T&T)
Taschieri, Del Fabbro, Testori, Saita, & Weinstein (2008)	1	T&T (>10 mm) (PD ≤5 mm)	<b>Test:</b> Anorganic bovine bone graft + membrane ( $n = 17$ ) <sup>a</sup> <b>Control:</b> No graft or membrane ( $n = 14$ ) <sup>a</sup>	S: 88% S: 57%

Abbreviations: L, loose criteria; PD, periodontal probing depth; S, strict criteria; T&T, Through-and-through defect; 4w, 4-wall defect.

<sup>a</sup>Indicate significant difference between the groups under comparison.

In parallel, the so-called ‘bony-lid’ technique has been tested in posterior sites, where intact thick buccal cortical plates are retrieved using a piezo-guided surgical approach (Niemczyk, Barnett, Johnson, Ordinola-Zapata, Glinianska, Julianna Bair, & Jang, 2022). In this novel surgical method, a piezo ultrasonic handpiece and bone cutting tip follow the predesigned guide to cut and elevate a window in the cortical plate to access the periapical lesion and root-end. The retrieved buccal cortical lid is stored in 0.9% sterile saline for replacement with calcium sulphate after root-end management. The 1–2-year periapical healing outcome of two cases showed promise, although the root-end cavities in the mandibular molar appeared deviated from the root axis (Niemczyk, Barnett, Johnson, Ordinola-Zapata, Glinianska, Julianna Bair, & Jang, 2022; Niemczyk, Barnett, Johnson, Ordinola-Zapata, Glinianska, Julianna Bair, Jang, & Vo, 2022).

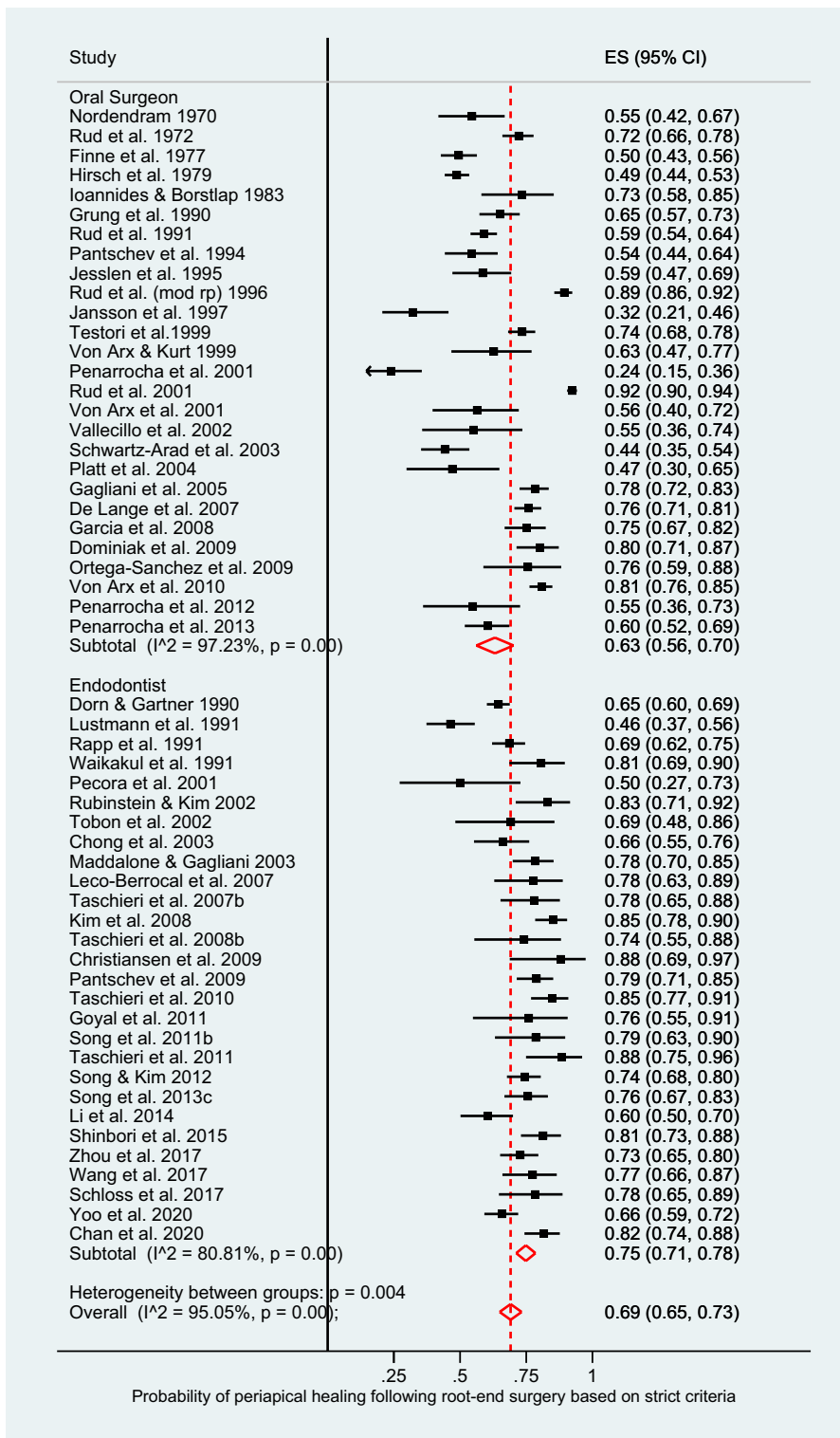
#### Operator background and skill

Root-end surgery falls within the scope of both the Oral Surgery and Endodontic disciplines, although the former group was the dominant provider in earlier studies (Amagasa et al., 1989; Finne et al., 1977; Grung et al., 1990; Hirsch et al., 1979; Ioannides & Borstlap, 1983; Jansson et al., 1997; Jesslén et al., 1995; Nordenram, 1970; Pantshev et al., 1994; Rud et al., 1972b; Rud et al., 1991; Rud et al., 1996; Sumi et al., 1996; Testori et al., 1999; von Arx & Kurt, 1999). The background culture, knowledge, training, skills and performance may, however, vary substantially between these two groups of clinicians (Rahbaran et al., 2001). The results of the authors’ meta-analysis concurred with the conclusion drawn by this study, revealing a higher pooled healed rate for endodontists over oral surgeons. The 95% confidence interval for oral surgeons (56%, 71%) was much wider in comparison

to endodontists (71%, 78%), implying greater variation of performance and outcomes within oral surgeon group (Figure 3). The wider variation may also be accounted for by the fact that in earlier studies, oral surgeons used the traditional root-end surgery approach, which accrue relatively low success rates. Conversely, oral surgeons have also achieved high success rates in more recent studies, where they exhibit expert knowledge and skills in application of modern principles and techniques (Von Arx, Marwik, & Bornstein, 2019).

Given that the quality of root-end management has a profound effect on periapical healing (Azim et al., 2021; Von Arx, Marwik, & Bornstein, 2019), the operator’s understanding of the biological rationale, possession of fine tactile and 3D visualization skills should dominate considerations of their specialty background. More specifically, the operator’s ability to visualize the correct canal path to avoid excessive stresses via the ultrasonic tip on thin root dentine are of utmost importance. The authors’ subjective observation is that in general, oral surgeons exhibit a boldness in osteotomy and enucleation procedures, whilst endodontists may be more attentive to the details of root-end and soft tissue flap management. The focus in specific training on root-end surgical procedures should be appropriately tailored to develop the relevant expertise for service delivery (Ericsson, 2009; Ericsson et al., 2018).

Given that root-end surgery outcomes are influenced by pre-operative, intra-operative and post-operative factors, the operator, regardless of specialty background should be informed on all these aspects. Therefore, they must have insight about the quality of prior root canal treatment, any prior surgical intervention, as well as the integrity of the tooth and restoration. The operator embarking on root-end surgery must obtain informed consent first, including an appropriate options analysis of



**FIGURE 3** Forest plot showing pooled and individual study's probability of periapical healing of teeth having undergone apical surgery, stratified by 'oral surgeons versus endodontists'.

different approaches, coupled with their post-operative prognoses. Therefore, root-end surgery should not be undertaken solely as a surgical exercise to enucleate the periapical tissue and place a root-end filling, but rather as a planned procedure that has fully evaluated the

tooth, alternative forms of treatment and replacement options, should the tooth need extraction. These principles should guide the training of individuals performing root-end surgery, regardless of their affiliation to Oral Surgery or Endodontics.

## Post-operative factors

### *Effect of post-operative surgical condition*

When root-end surgery proceeds uneventfully and smoothly, being performed gently and skilfully with little intra-operative complication, the post-operative healing is generally rapid, with little pain or swelling. In marked contrast, periodontal surgery, particularly involving repositioned flaps with releasing incisions as often required in regenerative procedures (Tan et al., 2014) has greater morbidity of pain, swelling and bruising. Root-end surgery on teeth with poorer access (small mouth, taut cheeks, shallow sulci, posterior teeth) or in the hands of novices, may take longer and be less-sure-handed, increasing the propensity for surgical trauma and thus post-operative pain, swelling and bruising (Harrison & Jurosky, 1991a, 1991b).

Although it has been observed that in the immediate post-operative period, serohaemorrhagic exudate abscess under the flap, may not significantly compromise periapical healing (Rud et al., 1972b), two studies (Taha et al., 2021; von Arx et al., 2012) showed more than 10% difference in healing rates. As the incidence of post-operative complications is low (<10% of all cases), there is usually insufficient statistical power to analyse the influence of potential causative factors. Nevertheless, unpublished Eastman data (Mehta et al., 2014) found that tenderness to percussion of the treated tooth, at 1 week post-operatively, was associated with a significantly reduced chance of ultimate periapical healing. Prophylactic antibiotics post-surgery may prevent wound infection, but this practice has not been proven, either in a randomized controlled trial (Lindeboom et al., 2005) or a meta-analysis of observational data (Von Arx et al., 2010).

A point worthy of note is the fashion for post-root-end surgery suture removal as early as 3–4 days post-operatively in the interests of preventing suture tract infection (Gutmann & Regan, 2010; Kim & Kratchman, 2006). The incidence of infection of the suture tracts is miniscule and furthermore, the risk of such infections compromising periapical healing vanishingly small to the point of being nonexistent. The timing of suture removal should, therefore, be more rationally judged by its need; that of preventing accidental displacement of the flap in oral function, post-operatively. It has been suggested that suture removal may proceed soon after the epithelial attachment is secured. However, epithelial reattachment does not predict optimal wound strength; a better predictor is consolidation of tethering of the flap to underlying tissues (Burkhardt & Lang, 2015; Susin et al., 2015), which occurs around 7 days post-operatively. By this stage, any pain or swelling is also likely to have subsided, making suture removal infinitely more comfortable for the patient and

dentist and the likelihood of accidental flap displacement post-operatively, less likely.

### *Effect of quality of coronal restoration*

The influence of the quality of coronal restoration at review is consistent with the literature on nonsurgical root canal treatment. Teeth with satisfactory coronal restorations at recall (whether new or old) are associated with better periapical healing outcomes (Allen et al., 1989; Mehta et al., 2014; Pallarés-Serrano et al., 2021; Rahbaran et al., 2001; Rapp et al., 1991; Song, Jung, et al., 2011; Villa-Machado et al., 2013; Yoo et al., 2020), presumably through the same mechanisms proposed for root canal treatment outcomes. That is, by helping to maintain the integrity of the tooth/restoration unit and prevention of any leakage that might support the reactivation of intraradicular infection. There is little insight about the level of such leakage, which cannot be measured clinically. Unfortunately, the consequences of leakage may manifest late, if caries advances undetected (Arora et al., 2022), resulting in tooth fracture or extraction (Yoo et al., 2020).

Unfortunately, most recent studies on root-end surgery have failed to report or analyse the effect of restoration quality at review (Buniag et al., 2021; Kim et al., 2020; Sutter et al., 2020; von Arx, Janner, et al., 2020; von Arx, Jensen, et al., 2019; Von Arx, Marwik, & Bornstein, 2019), in particular, those following-up the cases long-term (Kim et al., 2020; von Arx, Jensen, et al., 2019).

## Factors influencing gingival and periodontal tissue healing

Gingival and periodontal soft tissue management during root-end surgery has important roles in ensuring sufficient access to the surgical site as well as wound closure to prevent reinfection and ensure primary healing. The post-operative periodontal healing measured by changes of gingival margin level (von Arx et al., 2017) or clinical attachment loss (Jansson et al., 1997; von Arx et al., 2017) has been significantly associated with periapical healing. Jansson et al. (1997) attributed the positive association to a spread of inflammation from marginal to the apical tissues or drainage of apical suppuration into the periodontal attachment.

Gingival and periodontal tissue healing is assessed by measuring changes in parameters such as gingival margin level, periodontal probing depths, clinical attachment loss, width of keratinised tissue, width of attached gingivae and crestal bone level (Albanyan et al., 2020; Castro-Calderon et al., 2021; Kreisler et al., 2009; Taschieri et al., 2014, 2016; Velvart et al., 2004; von Arx et al., 2017; von Arx, Jensen, & Hänni, 2007). All of these parameters mostly remain stable

after modern root-end surgery (Albanyan et al., 2020; von Arx et al., 2017), and therefore, no significant associations with sex, age, gingival biotype or incision technique have been found, except between gingival recession and age (von Arx et al., 2017).

Amongst the different soft tissue incision techniques (intrasulcular incision with or without involvement of interproximal papilla, submarginal, papilla base), all studies reported negligible marginal recession when adopting a flap design avoiding the interproximal papilla (Castro-Calderon et al., 2021; Kreisler et al., 2009; Velvart, 2002; Velvart et al., 2003, 2004). However, successful execution of the papilla-base incision requires careful planning and high technical precision, leading Kirkevart et al. (2018) to recommend that novices avoid it.

## Factors affecting tooth survival

Root-end surgery may be the last resort for teeth with failed nonsurgical root canal treatment. Long-term data on tooth survival following root-end surgery should be a valuable resource to inform patients and clinicians alike about prognosis and preparation for failure. Unfortunately, such data are sparse and only available

from five studies at the time of writing (Azim et al., 2021; Beck-Broichsitter et al., 2018; Huang et al., 2020; Wang, Cheung, & Ng, 2004; Yoo et al., 2020; Table 6). Wang, Cheung, and Ng (2004) defined failure events as tooth extraction, retreatment or clinical and radiographic signs of periapical disease after treatment. The rate of tooth extraction could be extracted from the presented data. The reported long-term (up to 14 years) survival rates ranged from 48% to 93% with the predominant reasons for extraction being vertical root fracture, crown fracture and failure to heal (Table 6). Significant risk factors for tooth extraction after root-end surgery were repeat surgery (Wang, Cheung, & Ng, 2004), apicectomy without root-end filling (Beck-Broichsitter et al., 2018), incursion into maxillary sinus during surgery (Yoo et al., 2020), posterior teeth without full veneer crown or use of the tooth as an abutment for removable partial denture (Yoo et al., 2020; Table 6).

## Factors associated with impact of root-end surgery on quality of life

Root-end surgery should resolve any prior apical periodontitis plus related signs and symptoms. However,

**TABLE 6** Summary of studies' findings on tooth survival after root-end surgeries

Study	Sample size (teeth)	Operator	Treatment period	Follow-up duration (years)	Survival rate (%)	Average time to extraction (months)	Reasons for extraction	Risk factors
Wang, Cheung, et al. (2004)	194	E, OS	1991–2001	1–12	89	NR	NR	• Repeat surgery
Beck-Broichsitter et al. (2018)	149	OS	2001–2006	10	60 (5 y) 48 (10 y)	NR	NR	• No root-end filling
Huang et al. (2020)	116	E	2007–2010	9	93	98	<ul style="list-style-type: none"> <li>• VRF</li> <li>• Endodontic failure</li> <li>• Crown #</li> <li>• Caries,</li> <li>• Periodontal disease</li> <li>• Horizontal root #</li> <li>• Prosthodontic TP</li> <li>• Cemental tear</li> </ul>	NR
Yoo et al. (2020)	225	E	2006–2015	5–14	83	142	<ul style="list-style-type: none"> <li>• Crown #</li> <li>• Root #</li> <li>• Periodontal disease</li> <li>• Endodontic failure</li> <li>• Pain</li> </ul>	<ul style="list-style-type: none"> <li>• Molar teeth,</li> <li>• No full veneer restoration,</li> <li>• Removable partial denture abutment,</li> <li>• Maxillary sinus involvement</li> </ul>
Azim et al. (2021)	83	E	2015–2018	1–3	93	NR	<ul style="list-style-type: none"> <li>• VRF</li> <li>• Endodontic failure</li> </ul>	NR

Abbreviations: E, Endodontist/endodontic residents; NR, not reported; OS, oral surgeons; TP, treatment plan; VRF, vertical root fracture; y, years; # = fracture.



the invasive nature of such procedures may incur intra-operative pain and anxiety (Georgelin-Gurgel et al., 2009), as well as immediate post-operative pain, difficulty in mouth opening, mastication and speaking. All of these have a short-term negative impact on patients' OHRQoL, usually lasting for around 7 days post-operatively (Tsesis et al., 2005). Post-operative pain may be short lasting with the intensity reportedly peaking at 3–5 h after surgery and progressively decreasing with time (Chong & Pitt Ford, 2005; Christiansen et al., 2008). The post-operative swelling, in contrast may peak within 1 day after surgery (Christiansen et al., 2008). The earlier peak for post-operative pain may be due to analgesic use.

The impact of root-end surgery on patient's OHRQoL has only been evaluated for the first 7 days post-operatively, using the Patient Perception Questionnaire of Oral Surgery. This includes three domains: physical function (mouth opening, chewing, talking, sleeping, daily routine and work), physical pain and other physical symptoms (swelling, bleeding, nausea, bad taste/breath; Del Fabbro, Taschieri, & Weinstein, 2009; Del Fabbro et al., 2012; Tsesis et al., 2005). Unfortunately, none of these studies assessed the *pre-operative* OHRQoL, which is a major design flaw, given OHRQoL is a relative and not an absolute measure. Nevertheless, accepting this drawback, their conclusion was that more rapid reduction of symptoms and analgesic use could be achieved by two measures. These were as follows: (1) the use of the papilla-base incision flap design and (2) the application of platelet concentrate (Del Fabbro et al., 2012; Del Fabbro, Taschieri, & Weinstein, 2009). Definitive evidence for OHRQoL improvement could not be elucidated from available studies and further well-planned studies are needed to demonstrate the effectiveness of root-end surgery in eliminating the burden of periapical disease on OHRQoL in patients.

## CONCLUDING REMARKS

Root-end surgery, as a second-line procedure for management of failed nonsurgical root canal treatment or previous root-end surgery, may already have a bias towards lower periapical healing outcomes. The causes of root canal treatment failure may be biological (persistent infection [intra- or extraradicular], cysts, foreign-body response) or biomechanical (cracks, fractures, tooth weakening, restoration interface compromise). Some of these causes can be resolved but others, such as biomechanical and some biological factors may not be resolvable. A thorough pre-operative assessment of tooth and restoration integrity should help to filter out those with the poorest prognosis to improve root-end surgery outcomes by appropriate case selection. In some cases, there may be insufficient

confidence in the diagnostic data to definitively determine the cause until after surgical exploration, at which stage the procedure could be aborted. Patients should be mentally prepared for such eventualities.

When persistent apical inflammation is due to contained infection (intra-radicular or localized extraradicular) or a contained inflammatory source that can be excised or controlled by sealing the root with minimal weakening of tooth structure, the predictability of root-end surgery is very high. It can be enhanced by the aid of modern instrumentation and materials.

When persistent apical inflammation is due to uncontrolled biomechanical or biological problems, failure is almost a certainty. Appropriate decision-making in case selection and execution is paramount for predictable outcomes.

## AUTHOR CONTRIBUTION

The two authors contributed equally to conception, data analysis, writing and critical appraisal.

## FUNDING INFORMATION

None.

## CONFLICT OF INTEREST STATEMENT

The authors have stated explicitly that there are no conflicts of interest in connection with this article.

## DATA AVAILABILITY STATEMENT

Data sharing is not applicable to this article as no new data were created or analyzed in this study.

## ETHICAL APPROVAL

This investigation did not involve human or animal subjects.

## ORCID

Yuan-Ling Ng  <https://orcid.org/0000-0003-3712-8836>

Kishor Gulabivala  <https://orcid.org/0000-0002-2384-608X>

## REFERENCES

- Albanyan, H., Aksel, H. & Azim, A.A. (2020) Soft and hard tissue remodeling after endodontic microsurgery: a cohort study. *Journal of Endodontics*, 46, 1824–1831.
- Allen, R.K., Newton, C.W. & Brown, C.E., Jr. (1989) A statistical analysis of surgical and nonsurgical endodontic retreatment cases. *Journal of Endodontics*, 15, 261–266.
- Amagasa, T., Nagase, M., Sato, T. & Shioda, S. (1989) Apicoectomy with retrograde gutta-percha root filling. *Oral Surgery, Oral Medicine, and Oral Pathology*, 68, 339–342.
- Andreasen, J.O. & Rud, J. (1972) Modes of healing histologically after endodontic surgery in 70 cases. *International Journal of Oral Surgery*, 1, 148–160.



- Arora, R.K., Mordan, N.J., Spratt, D.A., Ng, Y.L. & Gulabivala, K. (2022) Bacteria in the cavity-restoration interface after varying periods of clinical service—SEM description of distribution and 16S rRNA gene sequence identification of isolates. *Clinical Oral Investigations*, 26, 5029–5044.
- August, D.S. (1996) Long-term, postsurgical results on teeth with periapical radiolucencies. *Journal of Endodontics*, 22, 380–383.
- Azim, A.A., Albanyan, H., Azim, K.A. & Piasecki, L. (2021) The Buffalo study: outcome and associated predictors in endodontic microsurgery—a cohort study. *International Endodontic Journal*, 54, 301–318.
- Barone, C., Dao, T.T., Basrani, B.B., Wang, N. & Friedman, S. (2010) Treatment outcome in endodontics: the Toronto study—phases 3, 4, and 5: apical surgery. *Journal of Endodontics*, 36, 28–35.
- Beaumont, R.H., O'Leary, T.J. & Kafrawy, A.H. (1984) Relative resistance of long junctional epithelial adhesions and connective tissue attachments to plaque-induced inflammation. *Journal of Periodontology*, 55, 213–223.
- Beck-Broichsitter, B.E., Schmid, H., Busch, H.P., Wiltfang, J. & Becker, S.T. (2018) Long-term survival of teeth in the posterior region after apical surgery. *Journal of Craniomaxillofacial Surgery*, 46, 1934–1938.
- Bliggenstorfer, S., Chappuis, V. & von Arx, T. (2021) Outcome of periapical surgery in molars: a retrospective analysis of 424 teeth. *Journal of Endodontics*, 47, 1703–1714.
- Buniag, A.G., Pratt, A.M. & Ray, J.J. (2021) Targeted endodontic microsurgery: a retrospective outcomes assessment of 24 cases. *Journal of Endodontics*, 47, 762–769.
- Burkhardt, R. & Lang, N.P. (2015) Influence of suturing on wound healing. *Periodontology 2000*, 68, 270–281.
- Çalışkan, M.K., Tekin, U., Kaval, M.E. & Solmaz, M.C. (2016) The outcome of apical microsurgery using MTA as the root-end filling material: 2- to 6-year follow-up study. *International Endodontic Journal*, 49, 245–254.
- Castro-Calderon, A., Toledano-Serrabona, J., Sanchez-Torres, A., Camps-Font, O., Sanchez-Garces, M.A. & Gay-Escoda, C. (2021) Influence of incision on periodontal parameters after apical surgery: a meta-analysis. *Clinical Oral Investigations*, 25, 4495–4506.
- Chan, S., Glickman, G.N., Woodmansey, K.F. & He, J. (2020) Retrospective analysis of root-end microsurgery outcomes in a postgraduate program in endodontics using calcium silicate-based cements as root-end filling materials. *Journal of Endodontics*, 46, 345–351.
- Chen, I., Karabucak, B., Wang, C., Wang, H.G., Koyama, E., Kohli, M.R., et al. (2015) Healing after root-end microsurgery by using mineral trioxide aggregate and a new calcium silicate-based bioceramic material as root-end filling materials in dogs. *Journal of Endodontics*, 41, 389–399.
- Chong, B.S. & Pitt Ford, T.R. (2005) Postoperative pain after root-end resection and filling. *Oral Surgery, Oral Medicine, Oral Pathology, Oral Radiology, and Endodontics*, 100, 762–766.
- Chong, B.S., Pitt Ford, T.R. & Hudson, M.B. (2003) A prospective clinical study of mineral trioxide aggregate and IRM when used as root-end filling materials in endodontic surgery. *International Endodontic Journal*, 36, 520–526.
- Christiansen, R., Kirkevang, L.L., Hørsted-Bindslev, P. & Wenzel, A. (2008) Patient discomfort following periapical surgery. *Oral Surgery, Oral Medicine, Oral Pathology, Oral Radiology, and Endodontics*, 105, 245–250.
- Christiansen, R., Kirkevang, L.L., Hørsted-Bindslev, P. & Wenzel, A. (2009) Randomized clinical trial of root-end resection followed by root-end filling with mineral trioxide aggregate or smoothing of the orthograde gutta-percha root filling—1-year follow-up. *International Endodontic Journal*, 42, 105–114.
- de Lange, J., Putters, T., Baas, E.M. & van Ingen, J.M. (2007) Ultrasonic root-end preparation in apical surgery: a prospective randomized study. *Oral Surgery, Oral Medicine, Oral Pathology, Oral Radiology, and Endodontics*, 104, 841–845.
- Del Fabbro, M., Ceresoli, V., Lolato, A. & Taschieri, S. (2012) Effect of platelet concentrate on quality of life after periradicular surgery: a randomized clinical study. *Journal of Endodontics*, 38, 733–739.
- Del Fabbro, M. & Taschieri, S. (2010) Endodontic therapy using magnification devices: a systematic review. *Journal of Dentistry*, 38, 269–275.
- Del Fabbro, M., Taschieri, S., Lodi, G., Banfi, G. & Weinstein, R.L. (2009) Magnification devices for endodontic therapy. *The Cochrane Database of Systematic Reviews*, 3, CD005969.
- Del Fabbro, M., Taschieri, S., Testori, T., Francetti, L. & Weinstein Roberto, L. (2007) Surgical versus non-surgical endodontic re-treatment for periradicular lesions. *Cochrane Database of Systematic Reviews*, 18, CD005511.
- Del Fabbro, M., Taschieri, S. & Weinstein, R. (2009) Quality of life after microscopic periradicular surgery using two different incision techniques: a randomized clinical study. *International Endodontic Journal*, 42, 360–367.
- Duncan, H.F., Nagendrababu, V., El-Karim, I. & Dummer, P.M.H. (2021) Outcome measures to assess the effectiveness of endodontic treatment for pulpitis and apical periodontitis for use in the development of European society of endodontology S3-level clinical practice guidelines: a consensus-based development. *International Endodontic Journal*, 54, 2184–2194.
- Ericsson, K.A. (2009) *Development of professional expertise*. New York: Cambridge University Press.
- Ericsson, K.A., Hoffman, R.R., Kozbelt, A. & Williams, A.M. (2018) *The Cambridge handbook of expertise and expert performance*. Cambridge: Cambridge University Press.
- Estrela, C., Bueno, M.R., Azevedo, B.C., Azevedo, J.R. & Pecora, J.D. (2008) A new periapical index based on cone beam computed tomography. *Journal of Endodontics*, 34, 1325–1331.
- Finne, K., Nord, P.G., Persson, G. & Lennartsson, B. (1977) Retrograde root filling with amalgam and Cavit. *Oral Surgery, Oral Medicine, and Oral Pathology*, 43, 621–626.
- Frank, A.L., Glick, D.H., Patterson, S.S. & Weine, F.S. (1992) Long-term evaluation of surgically placed amalgam fillings. *Journal of Endodontics*, 18, 391–398.
- Georgelin-Gurgel, M., Diemer, F., Nicolas, E. & Hennequin, M. (2009) Surgical and nonsurgical endodontic treatment-induced stress. *Journal of Endodontics*, 35, 19–22.
- Grung, B., Molven, O. & Halse, A. (1990) Periapical surgery in a Norwegian county hospital: follow-up findings of 477 teeth. *Journal of Endodontics*, 16, 411–417.
- Gutmann, J. & Harrison, J. (1991) Historical, anatomical and biological perspectives. In: *Surgical Endodontics*. Oxford: Boston Blackwell Scientific Publications, pp. 3–41.
- Gutmann, J.L. & Regan, J. (2010) Surgical endodontics. In: *Harty's endodontics in clinical practice*. Bristol: Elsevier, pp. 159–195.
- Harrison, J.W. & Jurosky, K.A. (1991a) Wound healing in the tissues of the periodontium following periradicular surgery. I. the incisional wound. *Journal of Endodontics*, 17, 425–435.

- Harrison, J.W. & Jurosky, K.A. (1991b) Wound healing in the tissues of the periodontium following periradicular surgery. 2. The dissectional wound. *Journal of Endodontics*, 17, 544–552.
- Harty, F.J., Parkins, B.J. & Wengraf, A.M. (1970) The success rate of apicectomy. A retrospective study of 1,016 cases. *British Dental Journal*, 129, 407–413.
- Hirsch, J.M., Ahlström, U., Henrikson, P.A., Heyden, G. & Peterson, L.E. (1979) Periapical surgery. *International Journal of Oral Surgery*, 8, 173–185.
- Huang, S., Chen, N.N., Yu, V.S.H., Lim, H.A. & Lui, J.N. (2020) Long-term success and survival of endodontic microsurgery. *Journal of Endodontics*, 46, 149–57 e4.
- Ioannides, C. & Borstlap, W.A. (1983) Apicoectomy on molars: a clinical and radiographical study. *International Journal of Oral Surgery*, 12, 73–79.
- Jansson, L., Sandstedt, P., Låftman, A.C. & Skoglund, A. (1997) Relationship between apical and marginal healing in periradicular surgery. *Oral Surgery, Oral Medicine, Oral Pathology, Oral Radiology, and Endodontics*, 83, 596–601.
- Jensen, S.S., Nattestad, A., Egdø, P., Sewerin, I., Munksgaard, E.C. & Schou, S. (2002) A prospective, randomized, comparative clinical study of resin composite and glass ionomer cement for retrograde root filling. *Clinical Oral Investigations*, 6, 236–243.
- Jesslén, P., Zetterqvist, L. & Heimdahl, A. (1995) Long-term results of amalgam versus glass ionomer cement as apical sealant after apicectomy. *Oral Surgery, Oral Medicine, Oral Pathology, Oral Radiology, and Endodontics*, 79, 101–103.
- Johnson, B.R., Fayad, M.I. & Berman, L.H. (2021) Periradicular surgery. In: Berman, L., Hargreaves, K. & Rotstein, I. (Eds.) *Cohen's pathways of the pulp*, 12th edition. St Louis: Elsevier, pp. 411–474.
- Jonasson, P., Lennholm, C. & Kvist, T. (2017) Retrograde root canal treatment: a prospective case series. *International Endodontic Journal*, 50, 515–521.
- Jonasson, P., Reit, C. & Kvist, T. (2008) A preliminary study on the technical feasibility and outcome of retrograde root canal treatment. *International Endodontic Journal*, 41, 807–813.
- Kim, D., Ku, H., Nam, T., Yoon, T.C., Lee, C.Y. & Kim, E. (2016) Influence of size and volume of periapical lesions on the outcome of endodontic microsurgery: 3-dimensional analysis using cone-beam computed tomography. *Journal of Endodontics*, 42, 1196–1201.
- Kim, D., Lee, H., Chung, M., Kim, S., Song, M. & Kim, E. (2020) Effects of fast- and slow-setting calcium silicate-based root-end filling materials on the outcome of endodontic microsurgery: a retrospective study up to 6 years. *Clinical Oral Investigations*, 24, 247–255.
- Kim, E., Song, J.S., Jung, I.Y., Lee, S.J. & Kim, S. (2008) Prospective clinical study evaluating endodontic microsurgery outcomes for cases with lesions of endodontic origin compared with cases with lesions of combined periodontal-endodontic origin. *Journal of Endodontics*, 34, 546–551.
- Kim, S., Jung, H., Kim, S., Shin, S.J. & Kim, E. (2016) The influence of an isthmus on the outcomes of surgically treated molars: a retrospective study. *Journal of Endodontics*, 42, 1029–1034.
- Kim, S. & Kratchman, S. (2006) Modern endodontic surgery concepts and practice: a review. *Journal of Endodontics*, 32, 601–623.
- Kim, S., Song, M., Shin, S.J. & Kim, E. (2016) A randomized controlled study of mineral trioxide aggregate and super Ethoxybenzoic acid as root-end filling materials in endodontic microsurgery: long-term outcomes. *Journal of Endodontics*, 42, 997–1002.
- Kirkevants, L.-L., Rud, V. & Kvist, T. (2018) Surgical endodontics. In: Bjørndal, L., Kirkevants, L.-L. & Whitworth, J. (Eds.) *Textbook of endodontology*, 3rd edition. Oxford: John Wiley & Sons Ltd, pp. 361–377.
- Kreisler, M., Gockel, R., Aubell-Falkenberg, S., Kreisler, T., Weihe, C., Filippi, A. et al. (2013) Clinical outcome in periradicular surgery: effect of patient- and tooth-related factors—a multicenter study. *Quintessence International*, 44, 53–60.
- Kreisler, M., Gockel, R., Schmidt, I., Kuhl, S. & d'Hoedt, B. (2009) Clinical evaluation of a modified marginal sulcular incision technique in endodontic surgery. *Oral Surgery, Oral Medicine, Oral Pathology, Oral Radiology, and Endodontics*, 108, e22–e28.
- Kruse, C., Spin-Neto, R., Christiansen, R., Wenzel, A. & Kirkevants, L.L. (2016) Periapical bone healing after apicectomy with and without retrograde root filling with mineral trioxide aggregate: a 6-year follow-up of a randomized controlled trial. *Journal of Endodontics*, 42, 533–537.
- Kruse, C., Spin-Neto, R., Evar Kraft, D.C., Vaeth, M. & Kirkevants, L.L. (2019) Diagnostic accuracy of cone beam computed tomography used for assessment of apical periodontitis: an ex vivo histopathological study on human cadavers. *International Endodontic Journal*, 52, 439–450.
- Kruse, C., Spin-Neto, R., Reibel, J., Wenzel, A. & Kirkevants, L.L. (2017) Diagnostic validity of periapical radiography and CBCT for assessing periapical lesions that persist after endodontic surgery. *Dentomaxillofacial Radiology*, 46, 20170210.
- Lai, P.T., Wu, S.L., Huang, C.Y. & Yang, S.F. (2022) A retrospective cohort study on outcome and interactions among prognostic factors of endodontic microsurgery. *Journal of Formosan Medical Association*, 121, 2220–2226. Available from: <https://doi.org/10.1016/j.jfma.2022.04.005>
- Li, H., Zhai, F., Zhang, R. & Hou, B. (2014) Evaluation of microsurgery with SuperEBA as root-end filling material for treating post-treatment endodontic disease: a 2-year retrospective study. *Journal of Endodontics*, 40, 345–350.
- Li, J. & Jin, X.Q. (2010) Management of a dens in dente by apical surgery: a case report. *Shanghai Journal of Stomatology*, 19, 558–560.
- Lindeboom, J.A., Frenken, J.W., Kroon, F.H. & Akker, H.P. (2005) A comparative prospective randomized clinical study of MTA and IRM as root-end filling materials in single-rooted teeth in endodontic surgery. *Oral Surgery, Oral Medicine, Oral Pathology, Oral Radiology, and Endodontics*, 100, 495–500.
- Lustmann, J., Friedman, S. & Shaharabany, V. (1991) Relation of pre- and intraoperative factors to prognosis of posterior apical surgery. *Journal of Endodontics*, 17, 239–241.
- Mehta D, Gulabivala K, Ng Y-L (2014) A systematic review and prospective study investigating the clinical outcomes and prognostic factors of root-end surgery in teeth with persistent periapical disease following non-surgical root canal treatment. University College London (unpublished work).
- Molven, O., Halse, A. & Grung, B. (1987) Observer strategy and the radiographic classification of healing after endodontic surgery. *International Journal of Oral and Maxillofacial Surgery*, 16, 432–439.
- Ng, T.K., Huang, L., Cao, D., Yip, Y.W.Y., Tsang, W.M., Yam, G.H.F. et al. (2015) Cigarette smoking hinders human periodontal

- ligament-derived stem cell proliferation, migration and differentiation potentials. *Scientific Reports*, 5, 7828.
- Ng, Y.L., Mann, V. & Gulabivala, K. (2011) A prospective study of the factors affecting outcomes of nonsurgical root canal treatment: part 1: periapical health. *International Endodontic Journal*, 44, 583–609.
- Ng, Y.L., Mann, V., Rahbaran, S., Lewsey, J. & Gulabivala, K. (2007) Outcome of primary root canal treatment: systematic review of the literature—part 1. Effects of study characteristics on probability of success. *International Endodontic Journal*, 40, 921–939.
- Ng, Y.L., Mann, V., Rahbaran, S., Lewsey, J. & Gulabivala, K. (2008) Outcome of primary root canal treatment: systematic review of the literature—part 2. Influence of clinical factors. *International Endodontic Journal*, 41, 6–31.
- Niederman, R. & Theodosopoulou, J.N. (2003) A systematic review of in vivo retrograde obturation materials. *International Endodontic Journal*, 36, 577–585.
- Niemczyk, S.P., Barnett, F., Johnson, J.D., Ordinola-Zapata, R., Glinianska, A., Julianna Bair, J.H. et al. (2022) PRESS and piezo microsurgery (bony lid): a 7-year evolution in a residency program part 1: surgeon-defined site location. *Journal of Endodontics*, 48, 787–796.
- Niemczyk, S.P., Barnett, F., Johnson, J.D., Ordinola-Zapata, R., Glinianska, A., Julianna Bair, J.H. et al. (2022) PRESS and piezo microsurgery (bony lid): a 7-year evolution in a residency program—part 2: PRESS-defined site location. *Journal of Endodontics*, 48, 797–806.
- Nordenram, A. (1970) Biobond for retrograde root filling in apicoectomy. *Scandinavian Journal of Dental Research*, 78, 251–255.
- Oberli, K., Bornstein, M.M. & von Arx, T. (2007) Periapical surgery and the maxillary sinus: radiographic parameters for clinical outcome. *Oral Surgery, Oral Medicine, Oral Pathology, Oral Radiology, and Endodontics*, 103, 848–853.
- Pallarés-Serrano, A., Glera-Suarez, P., Tarazona-Alvarez, B., Peñarrocha-Diago, M., Peñarrocha-Diago, M. & Peñarrocha-Oltra, D. (2021) Prognostic factors after endodontic microsurgery: a retrospective study of 111 cases with 5 to 9 years of follow-up. *Journal of Endodontics*, 47, 397–403.
- Pantschev, A., Carlsson, A.P. & Andersson, L. (1994) Retrograde root filling with EBA cement or amalgam. A comparative clinical study. *Oral Surgery, Oral Medicine, and Oral Pathology*, 78, 101–104.
- Pecora, G., De Leonardi, D., Ibrahim, N., Bovi, M. & Cornelini, R. (2001) The use of calcium sulphate in the surgical treatment of a 'through and through' periradicular lesion. *International Endodontic Journal*, 34, 189–197.
- Peñarrocha, M., Carrillo, C., Peñarrocha, M., Peñarrocha, D., von Arx, T. & Vera, F. (2011) Symptoms before periapical surgery related to histologic diagnosis and postoperative healing at 12 months for 178 periapical lesions. *Journal Oral and Maxillofacial Surgery*, 69, e31–e37.
- Peñarrocha-Diago, M., Maestre-Ferrín, L., Peñarrocha-Oltra, D., von Arx, T. & Peñarrocha-Diago, M. (2013) Influence of hemostatic agents upon the outcome of periapical surgery: dressings with anesthetic and vasoconstrictor or aluminum chloride. *Medicina Oral Patología Oral Cirugía Bucal*, 18, e272–e278.
- Peñarrocha-Diago, M., Menendez-Nieto, I., Cervera-Ballester, J., Maestre-Ferrín, L., Blaya-Tárraga, J.A. & Peñarrocha-Oltra, D. (2018) Influence of hemostatic agents in the prognosis of periapical surgery: a randomized study of epinephrine versus aluminum chloride. *Journal of Endodontics*, 44, 1205–1209.
- Peterson, J. & Gutmann, J.L. (2001) The outcome of endodontic re-surgery: a systematic review. *International Endodontic Journal*, 34, 169–175.
- Qualtrough, A., Alani, A., Bandheri, S., Mehta, D., Ng, Y., Saksena, A. et al. (2020) *Guidelines for periradicular surgery*. London: The Royal College of Surgeons of England, pp. 1–23.
- Rahbaran, S., Gilthorpe, M.S., Harrison, S.D. & Gulabivala, K. (2001) Comparison of clinical outcome of periapical surgery in endodontic and oral surgery units of a teaching dental hospital: a retrospective study. *Oral Surgery, Oral Medicine, Oral Pathology, Oral Radiology, and Endodontics*, 91, 700–709.
- Rapp, E.L., Brown, C.E., Jr. & Newton, C.W. (1991) An analysis of success and failure of apicoectomies. *Journal of Endodontics*, 17, 508–512.
- Reit, C. & Hirsch, J. (1986) Surgical endodontic retreatment. *International Endodontic Journal*, 19, 107–112.
- Roda R, Gettleman B, Johnson SC (2021) Non-surgical retreatment. In: Berman L, Hargreaves K, Rotstein I (Eds.) *Cohen's Pathways of the Pulp*. 12th edition. St Louis: Elsevier; 343–410.
- Rosenfeld, A.L., Mandelaris, G.A. & Tardieu, P.B. (2006a) Prosthetically directed implant placement using computer software to ensure precise placement and predictable prosthetic outcomes. Part 1: diagnostics, imaging, and collaborative accountability. *International Journal of Periodontics & Restorative Dentistry*, 26, 215–221.
- Rosenfeld, A.L., Mandelaris, G.A. & Tardieu, P.B. (2006b) Prosthetically directed implant placement using computer software to ensure precise placement and predictable prosthetic outcomes. Part 2: rapid-prototype medical modeling and stereolithographic drilling guides requiring bone exposure. *International Journal of Periodontics & Restorative Dentistry*, 26, 347–353.
- Rosenfeld, A.L., Mandelaris, G.A. & Tardieu, P.B. (2006c) Prosthetically directed implant placement using computer software to ensure precise placement and predictable prosthetic outcomes. Part 3: stereolithographic drilling guides that do not require bone exposure and the immediate delivery of teeth. *International Journal of Periodontics & Restorative Dentistry*, 26, 493–499.
- Rud, J. & Andreasen, J.O. (1972) A study of failures after endodontic surgery by radiographic, histologic and stereomicroscopic methods. *International Journal of Oral Surgery*, 1, 311–328.
- Rud, J., Andreasen, J.O. & Jensen, J.E. (1972a) Radiographic criteria for the assessment of healing after endodontic surgery. *International Journal of Oral Surgery*, 1, 195–214.
- Rud, J., Andreasen, J.O. & Jensen, J.F. (1972b) A multivariate analysis of the influence of various factors upon healing after endodontic surgery. *International Journal of Oral Surgery*, 1, 258–271.
- Rud, J., Munksgaard, E.C., Andreasen, J.O. & Rud, V. (1991) Retrograde root filling with composite and a dentin-bonding agent. 2. *Endodontics & Dental Traumatology*, 7, 126–131.
- Rud, J., Rud, V. & Munksgaard, E.C. (1996) Retrograde root filling with dentin-bonded modified resin composite. *Journal of Endodontics*, 22, 477–480.
- Safi, C., Kohli, M.R., Kratchman, S.I., Setzer, F.C. & Karabucak, B. (2019) Outcome of endodontic microsurgery using mineral trioxide aggregate or root repair material as root-end filling material: a randomized controlled trial with cone-beam computed tomographic evaluation. *Journal of Endodontics*, 45, 831–839.



- Schloss, T., Sonntag, D., Kohli, M.R. & Setzer, F.C. (2017) A comparison of 2- and 3-dimensional healing assessment after endodontic surgery using cone-beam computed tomographic volumes or periapical radiographs. *Journal of Endodontics*, 43, 1072–1079.
- Setzer, F.C., Kohli, M.R., Shah, S.B., Karabucak, B. & Kim, S. (2012) Outcome of endodontic surgery: a meta-analysis of the literature—part 2: comparison of endodontic microsurgical techniques with and without the use of higher magnification. *Journal of Endodontics*, 38, 1–10.
- Setzer, F.C. & Kratchman, S.I. (2022) Present status and future directions: surgical endodontics. *International Endodontic Journal*, 55, 1020–1058.
- Setzer, F.C., Shah, S.B., Kohli, M.R., Karabucak, B. & Kim, S. (2010) Outcome of endodontic surgery: a meta-analysis of the literature—part 1: comparison of traditional root-end surgery and endodontic microsurgery. *Journal of Endodontics*, 36, 1757–1765.
- Shah, P.K., El Karim, I.A., Duncan, H.F., Nagendrababu, V. & Chong, B.S. (2022) Outcomes reporting in systematic reviews on surgical endodontics: a scoping review for the development of a core outcome set. *International Endodontic Journal*, 55, 811–832.
- Shinbori, N., Grama, A.M., Patel, Y., Woodmansey, K. & He, J. (2015) Clinical outcome of endodontic microsurgery that uses EndoSequence BC root repair material as the root-end filling material. *Journal of Endodontics*, 41, 607–612.
- Song, M., Chung, W., Lee, S.J. & Kim, E. (2012) Long-term outcome of the cases classified as successes based on short-term follow-up in endodontic microsurgery. *Journal of Endodontics*, 38, 1192–1196.
- Song, M., Jung, I.Y., Lee, S.J., Lee, C.Y. & Kim, E. (2011) Prognostic factors for clinical outcomes in endodontic microsurgery: a retrospective study. *Journal of Endodontics*, 37, 927–933.
- Song, M., Kang, M., Kang, D.R., Jung, H.I. & Kim, E. (2018) Comparison of the effect of endodontic-periodontal combined lesion on the outcome of endodontic microsurgery with that of isolated endodontic lesion: survival analysis using propensity score analysis. *Clinical Oral Investigations*, 22, 1717–1724.
- Song, M. & Kim, E. (2012) A prospective randomized controlled study of mineral trioxide aggregate and super ethoxy-benzoic acid as root-end filling materials in endodontic microsurgery. *Journal of Endodontics*, 38, 875–879.
- Song, M., Kim, S.G., Lee, S.J., Kim, B. & Kim, E. (2013) Prognostic factors of clinical outcomes in endodontic microsurgery: a prospective study. *Journal of Endodontics*, 39, 1491–1497.
- Song, M., Kim, S.G., Shin, S.J., Kim, H.C. & Kim, E. (2013) The influence of bone tissue deficiency on the outcome of endodontic microsurgery: a prospective study. *Journal of Endodontics*, 39, 1341–1345.
- Song, M., Nam, T., Shin, S.J. & Kim, E. (2014) Comparison of clinical outcomes of endodontic microsurgery: 1 year versus long-term follow-up. *Journal of Endodontics*, 40, 490–494.
- Song, M., Shin, S.J. & Kim, E. (2011) Outcomes of endodontic microsurgery: a prospective clinical study. *Journal of Endodontics*, 37, 316–320.
- Sumi, Y., Hattori, H., Hayashi, K. & Ueda, M. (1996) Ultrasonic root-end preparation: clinical and radiographic evaluation of results. *Journal of Oral and Maxillofacial Surgery*, 54, 590–593.
- Susin, C., Fiorini, T., Lee, J., De Stefano, J.A., Dickinson, D.P. & Wikesjo, U.M. (2015) Wound healing following surgical and regenerative periodontal therapy. *Periodontology* 2000, 68, 83–98.
- Sutter, E., Valdec, S., Bichsel, D., Wiedemeier, D., Rucker, M. & Stadlinger, B. (2020) Success rate 1 year after apical surgery: a retrospective analysis. *Oral and Maxillofacial Surgery*, 24, 45–49.
- Taha, N.A., Aboyounes, F.B. & Tamimi, Z.Z. (2021) Root-end microsurgery using a premixed tricalcium silicate putty as root-end filling material: a prospective study. *Clinical Oral Investigations*, 25, 311–317.
- Tan, W.C., Krishnaswamy, G., Ong, M.M. & Lang, N.P. (2014) Patient-reported outcome measures after routine periodontal and implant surgical procedures. *Journal of Clinical Periodontology*, 41, 618–624.
- Taschieri, S., Corbella, S. & Del Fabbro, M. (2014) Do gingival soft tissues benefit from the application of a papilla preservation flap technique in endodontic surgery? *Journal of Oral and Maxillofacial Surgery*, 72, 1898–1908.
- Taschieri, S., Del Fabbro, M., Francetti, L., Perondi, I. & Corbella, S. (2016) Does the papilla preservation flap technique induce soft tissue modifications over time in endodontic surgery procedures? *Journal of Endodontics*, 42, 1191–1195.
- Taschieri, S., Del Fabbro, M., Testori, T., Francetti, L. & Weinstein, R. (2006) Endodontic surgery using 2 different magnification devices: preliminary results of a randomized controlled study. *Journal of Oral and Maxillofacial Surgery*, 64, 235–242.
- Taschieri, S., Del Fabbro, M., Testori, T., Saita, M. & Weinstein, R. (2008) Efficacy of guided tissue regeneration in the management of through-and-through lesions following surgical endodontics: a preliminary study. *International Journal of Periodontics and Restorative Dentistry*, 28, 265–271.
- Taschieri, S., Del Fabbro, M., Testori, T. & Weinstein, R. (2007) Efficacy of xenogeneic bone grafting with guided tissue regeneration in the management of bone defects after surgical endodontics. *Journal of Oral and Maxillofacial Surgery*, 65, 1121–1127.
- Taschieri, S., Del Fabbro, M., Testori, T. & Weinstein, R. (2008) Microscope versus endoscope in root-end management: a randomized controlled study. *International Journal of Oral and Maxillofacial Surgery*, 37, 1022–1026.
- Taschieri, S., Morandi, B., Giovarruscio, M., Francetti, L., Russillo, A. & Corbella, S. (2021) Microsurgical endodontic treatment of the upper molar teeth and their relationship with the maxillary sinus: a retrospective multicentric clinical study. *BMC Oral Health*, 21, 252.
- Testori, T., Capelli, M., Milani, S. & Weinstein, R.L. (1999) Success and failure in periradicular surgery: a longitudinal retrospective analysis. *Oral Surgery, Oral Medicine, Oral Pathology, Oral Radiology, and Endodontics*, 87, 493–498.
- Tobón, S.I., Arismendi, J.A., Marín, M.L., Mesa, A.L. & Valencia, J.A. (2002) Comparison between a conventional technique and two bone regeneration techniques in periradicular surgery. *International Endodontic Journal*, 35, 635–641.
- Truschnegg, A., Rugani, P., Kirnbauer, B., Kqiku, L., Jakse, N. & Kirmeier, R. (2020) Long-term follow-up for apical microsurgery of teeth with Core and post restorations. *Journal of Endodontics*, 46, 178–183.
- Tsesis, I., Rosen, E., Schwartz-Arad, D. & Fuss, Z. (2006) Retrospective evaluation of surgical endodontic treatment:

- traditional versus modern technique. *Journal of Endodontics*, 32, 412–416.
- Tsesis, I., Rosen, E., Tamse, A., Taschieri, S. & Del Fabbro, M. (2011) Effect of guided tissue regeneration on the outcome of surgical endodontic treatment: a systematic review and meta-analysis. *Journal of Endodontics*, 37, 1039–1045.
- Tsesis, I., Rosen, E., Taschieri, S., Telishevsky Strauss, Y., Ceresoli, V. & Del Fabbro, M. (2013) Outcomes of surgical endodontic treatment performed by a modern technique: an updated meta-analysis of the literature. *Journal of Endodontics*, 39, 332–339.
- Tsesis, I., Shoshani, Y., Givol, N., Yahalom, R., Fuss, Z. & Taicher, S. (2005) Comparison of quality of life after surgical endodontic treatment using two techniques: a prospective study. *Oral Surgery, Oral Medicine, Oral Pathology, Oral Radiology, and Endodontics*, 99, 367–371.
- Tsesis, I., Taivishvsky, V., Kfir, A. & Rosen, E. (2009) Outcome of surgical endodontic treatment performed by a modern technique: a meta-analysis of literature. *Journal of Endodontics*, 35, 1505–1511.
- Velentgas, P., Dreyer, N.A. & Wu, A.W. (2013) Outcome definition and measurement. In: Velentgas, P., Dreyer, N.A., Nourjah, P. et al. (Eds.) *Developing a protocol for observational comparative effectiveness research: a user's guide*. Rockville: Agency for Healthcare Research and Quality (US); Jan. Chapter 6.
- Velvart, P. (2002) Papilla base incision: a new approach to recession-free healing of the interdental papilla after endodontic surgery. *International Endodontic Journal*, 35, 453–460.
- Velvart, P., Ebner-Zimmermann, U. & Ebner, J.P. (2003) Comparison of papilla healing following sulcular full-thickness flap and papilla base flap in endodontic surgery. *International Endodontic Journal*, 36, 653–659.
- Velvart, P., Ebner-Zimmermann, U. & Ebner, J.P. (2004) Comparison of long-term papilla healing following sulcular full thickness flap and papilla base flap in endodontic surgery. *International Endodontic Journal*, 37, 687–693.
- Villa-Machado, P.A., Botero-Ramírez, X. & Tobón-Arroyave, S.I. (2013) Retrospective follow-up assessment of prognostic variables associated with the outcome of periradicular surgery. *International Endodontic Journal*, 46, 1063–1076.
- von Arx, T., Antonini, L., Salvi, G.E. & Bornstein, M.M. (2017) Changes of periodontal parameters after apical surgery: correlation of clinical and cone-beam computed tomographic data. *Journal of Endodontics*, 43, 876–884.
- von Arx, T. & Cochran, D.L. (2001) Rationale for the application of the GTR principle using a barrier membrane in endodontic surgery: a proposal of classification and literature review. *International Journal of Periodontics and Restorative Dentistry*, 21, 127–139.
- von Arx, T., Frei, C. & Bornstein, M.M. (2003) Periradicular surgery with and without endoscopy: a prospective clinical comparative study. *Schweizer Monatsschrift für Zahnmedizin*, 113, 860–865.
- von Arx, T., Janner, S.F., Hänni, S. & Bornstein, M.M. (2016) Evaluation of new cone-beam computed tomographic criteria for radiographic healing evaluation after apical surgery: assessment of repeatability and reproducibility. *Journal of Endodontics*, 42, 236–242.
- von Arx, T., Janner, S.F.M., Haenni, S. & Bornstein, M.M. (2020) Bioceramic root repair material (BCRRM) for root-end obturation in apical surgery. An analysis of 174 teeth after 1 year. *Swiss Dental Journal*, 130, 390–396.
- von Arx, T., Jensen, S.S. & Hänni, S. (2007) Clinical and radiographic assessment of various predictors for healing outcome 1 year after periapical surgery. *Journal of Endodontics*, 33, 123–128.
- von Arx, T., Jensen, S.S., Hänni, S. & Friedman, S. (2012) Five-year longitudinal assessment of the prognosis of apical microsurgery. *Journal of Endodontics*, 38, 570–579.
- von Arx, T., Jensen, S.S., Janner, S.F.M., Hänni, S. & Bornstein, M.M. (2019) A 10-year follow-up study of 119 teeth treated with apical surgery and root-end filling with mineral trioxide aggregate. *Journal of Endodontics*, 45, 394–401.
- von Arx, T., Kach, S., Suter, V.G.A. & Bornstein, M.M. (2020) Perforation of the maxillary sinus floor during apical surgery of maxillary molars: a retrospective analysis using cone beam computed tomography. *Australian Endodontic Journal*, 46, 176–183.
- von Arx, T. & Kurt, B. (1999) Root-end cavity preparation after apicoectomy using a new type of sonic and diamond-surfaced retrotip: a 1-year follow-up study. *Journal of Oral and Maxillofacial Surgery*, 57, 656–661.
- Von Arx, T., Marwik, E. & Bornstein, M.M. (2019) Effects of dimensions of root-end fillings and peripheral root dentine on the healing outcome of apical surgery. *European Endodontic Journal*, 4, 49–56.
- Von Arx, T., Peñarrocha, M. & Jensen, S. (2010) Prognostic factors in apical surgery with root-end filling: a meta-analysis. *Journal of Endodontics*, 36, 957–973.
- von Arx, T., Vinzens-Majaniemi, T., Burgin, W. & Jensen, S.S. (2007) Changes of periodontal parameters following apical surgery: a prospective clinical study of three incision techniques. *International Endodontic Journal*, 40, 959–969.
- Wada, M., Takase, T., Nakanuma, K., Arisue, K., Nagahama, F. & Yamazaki, M. (1998) Clinical study of refractory apical periodontitis treated by apicoectomy. Part 1. Root canal morphology of resected apex. *International Endodontic Journal*, 31, 53–56.
- Wälivaara, D., Abrahamsson, P., Fogelin, M. & Isaksson, S. (2011) Super-EBA and IRM as root-end fillings in periapical surgery with ultrasonic preparation: a prospective randomized clinical study of 206 consecutive teeth. *Oral Surgery, Oral Medicine, Oral Pathology, Oral Radiology, and Endodontics*, 112, 258–263.
- Wälivaara, D.Å., Abrahamsson, P., Sämfors, K.A. & Isaksson, S. (2009) Periapical surgery using ultrasonic preparation and thermoplasticized gutta-percha with AH plus sealer or IRM as retrograde root-end fillings in 160 consecutive teeth: a prospective randomized clinical study. *Oral Surgery, Oral Medicine, Oral Pathology, Oral Radiology, and Endodontology*, 108, 784–789.
- Wang, N., Knight, K., Dao, T. & Friedman, S. (2004) Treatment outcome in endodontics—the Toronto study. Phases I and II: apical surgery. *Journal of Endodontics*, 30, 751–761.
- Wang, Q., Cheung, G.S. & Ng, R.P. (2004) Survival of surgical endodontic treatment performed in a dental teaching hospital: a cohort study. *International Endodontic Journal*, 37, 764–775.
- Wang, Z.H., Zhang, M.M., Wang, J., Jiang, L. & Liang, Y.H. (2017) Outcomes of endodontic microsurgery using a microscope and mineral trioxide aggregate: a prospective cohort study. *Journal of Endodontics*, 43, 694–698.
- Yoo, Y.J., Kim, D.W., Perinpanayagam, H., Baek, S.H., Zhu, Q., Safavi, K. et al. (2020) Prognostic factors of long-term outcomes in



- endodontic microsurgery: a retrospective cohort study over five years. *Journal of Clinical Medicine*, 9, 2210.
- Zhou, W., Zheng, Q., Tan, X., Song, D., Zhang, L. & Huang, D. (2017) Comparison of mineral trioxide aggregate and iRoot BP plus root repair material as root-end filling materials in endodontic microsurgery: a prospective randomized controlled study. *Journal of Endodontics*, 43, 1–6.
- Zuolo, M.L., Ferreira, M.O. & Gutmann, J.L. (2000) Prognosis in periradicular surgery: a clinical prospective study. *International Endodontic Journal*, 33, 91–98.

**How to cite this article:** Ng, Y.-L. & Gulabivala, K. (2023) Factors that influence the outcomes of surgical endodontic treatment. *International Endodontic Journal*, 56(Suppl. 2), 116–139. Available from: <https://doi.org/10.1111/iej.13896>