




ELSEVIER

Contents lists available at ScienceDirect

JPRAS Open

journal homepage: [www.elsevier.com/locate/jpra](http://www.elsevier.com/locate/jpra)

## Management of Fibro-adipose Vascular Anomalies (FAVA) in Paediatric Practice ☆☆☆

C Lipede<sup>1,\*</sup>, D Nikkhah<sup>1</sup>, R Ashton<sup>1</sup>, G Murphy<sup>1</sup>, AM Barnacle<sup>2</sup>, PA Patel<sup>2</sup>, GD Smith<sup>1</sup>, DM Eastwood<sup>3,4</sup>, B Sivakumar<sup>2</sup>

<sup>1</sup> Department of Plastic Surgery, Great Ormond Street Hospital for Children, London UK

<sup>2</sup> Department of Radiology, Great Ormond Street Hospital for Children, London UK

<sup>3</sup> Department of Orthopaedics, Great Ormond Street Hospital for Children, London UK

<sup>4</sup> Division of Surgery & Interventional Sciences, Faculty of Medical Sciences, University College London

### ARTICLE INFO

#### Article history:

Received 16 April 2021

Accepted 7 May 2021

Available online 19 May 2021

#### Keywords:

FAVA

fibroadipose vascular anomaly

treatment

outcomes

paediatric

### ABSTRACT

Fibro-adipose vascular anomaly (FAVA) is a discrete type of vascular anomaly. We describe our experience managing FAVA at a tertiary level paediatric hospital and offer a treatment algorithm.

**Methods:** A retrospective review of 27 patients with proven FAVA was undertaken. All patients had undergone MRI and USS evaluation. Patient demographics, presenting concerns, treatment methods, and outcomes were recorded and evaluation with the paediatric outcomes data collection instrument (PODCI) completed a minimum of 12 months after definitive treatment.

**Results:** Mean age at presentation was 8.9 years (range: 9 m–17.4 y) and mean post-treatment follow-up was 7.4 y (range: 2 y–11.6 y). Twenty of 27 lesions affected the lower limb. Severe neurogenic-type pain was present in 23 cases and contractures across joints in 11 cases. Sclerotherapy with sodium tetradecyl sulphate was used in 11 cases, with no improvement in symptoms. Cryoablation

☆ LoE IV Case Series

☆☆ Work presented in part: EFORT (European Federation of Orthopaedics and Trauma) Meeting Lisbon, 2019 EPOS (European Paediatric Orthopaedic Society) Meeting Oslo, 2018 World Symposium in Congenital Malformations of the Hand and Upper Limb, Hong Kong, 2018

\* Corresponding author.

E-mail address: [clipede@doctors.org.uk](mailto:clipede@doctors.org.uk) (C. Lipede).

provided pain relief in 3/4 cases, but contracture subsequently increased in one patient and pain recurred in another.

Fourteen cases underwent surgery (four surgical excisions alone, 10 in combination with other procedures). Three patients required four further surgical procedures that include one amputation for intractable pain and poor function.

PODCI evaluations suggest overall good function, with surgical management and interventional radiology that provide comparable results. Surgery did correct deformity.

*Conclusion:* If conservative measures or cryoablation fail to achieve symptomatic control, surgical excision should be considered, combined with adjunctive procedures, to correct contractures and balance muscle forces.

Relief of pain may compensate for the loss of muscle mass and overall improves function. Multidisciplinary team working is essential.

Crown Copyright © 2021 Published by Elsevier Ltd on behalf of British Association of Plastic, Reconstructive and Aesthetic Surgeons.

This is an open access article under the CC BY-NC-ND license (<http://creativecommons.org/licenses/by-nc-nd/4.0/>)

---

## Introduction

Alomari and colleagues first described the clinical, radiological and pathological features of fibrovascular adipose anomaly (FAVA) in 2014<sup>1</sup>. They defined a rare but distinctive vascular anomaly. Prior to this description, these lesions were frequently labelled as either intramuscular haemangiomas, complex venous malformations or other vascular malformation variants. There is little information in the literature relating to the diagnosis, assessment or management of the FAVA lesion due perhaps to its recent description, its rarity and potentially its underdiagnosis.<sup>2–5</sup>

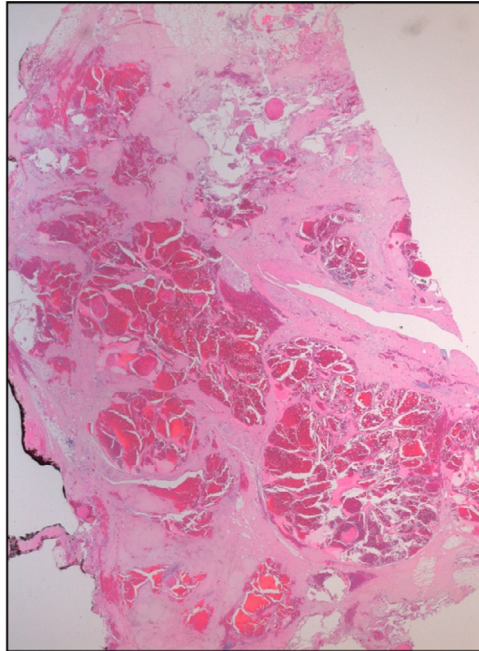
FAVA is diagnosed by specific features in both its clinical and radiological presentation and confirmed on histopathology, which demonstrates fibrofatty accumulation, with diffuse fibrotic infiltration of muscle and extension along fascial planes (Figure 1). The abnormal veins are often thin walled and dysplastic, and the fibrotic tissue may encase the neurovascular structures that cause compressive symptoms. These features differentiate FAVA from intramuscular vascular malformations.

Progressive, severe limb pain is common in FAVA, and it is typically disproportionate to the clinical findings<sup>1</sup> in contrast to the relatively minor symptoms associated with other vascular malformations<sup>6</sup>. Progressive muscle contractures that result in the loss of joint range of motion are often seen in patients with severe disease. On MRI, FAVA lesions have a more solid appearance than most venous malformations and lack both phleboliths and the fluid-fluid levels often seen with the stagnant blood within a venous malformation (Figure 2a and 2b). Treatment options include cryoablation, medical management and/or surgical debulking or excision<sup>7</sup>. Sclerotherapy is increasingly recognised to have little benefit for these patients.

We describe our experience and interventional treatment outcomes for cases of FAVA treated at our tertiary level referral centre for paediatric vascular anomalies.

## Methods

A retrospective, IRB approved (ref no. 1932) review of patients under 18 years of age treated for a FAVA at our Institution was performed. Cases were identified from our database of vascular malformations and included in the study if a FAVA had been confirmed histologically on core biopsy or on



**Figure 1.** An H&E-stained histological section of a FAVA excised from a gastrocnemius muscle showing abundant mixed fibro-adipose tissue, features specific to this diagnosis. In some fibro-fatty tissue predominates, whereas in others, there are dense bands of fibro-collagenous tissue with diffuse fibrotic infiltration of muscle and extension along fascial planes. The abnormal veins are often thin walled and dysplastic, and the fibrotic tissue may encase the neurovascular structures.

examination of the surgical specimen. Patients with all other malformations were excluded from the study. All patients underwent both an ultrasound assessment, using a colour Doppler to assess flow, to judge the presence/extent of the vascular component and MRI where T1- and T2-weighted sequences demonstrated heterogeneous high-signal intensities in keeping with a fibrofatty component of the FAVA.

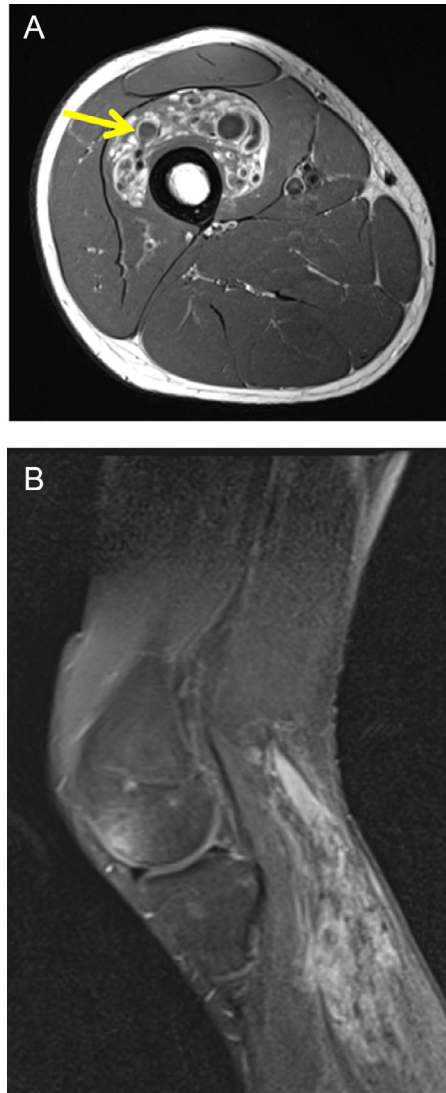
Patient demographics, symptomatology and clinical signs were documented and imaging modalities, treatment choices and complications noted.

In each case, treatment was determined following the discussion at our specialist vascular anomaly multidisciplinary team (MDT) meeting. All patients received input from the occupational therapy and physiotherapy teams that discussed the role of stretching regimes and night splints where appropriate. Pressure garments were trialled to see whether they worsened or improved symptoms and were used on an individual basis.

If the FAVA demonstrated a significant vascular component on Doppler ultrasound, sclerotherapy with either sodium tetradecyl sulphate (STS) or bleomycin was offered as first-line treatment to fibrose the vascular component of the lesion. Cryoablation was used in selected cases with a solid component and was offered more frequently as the teams' experience with this treatment modality grew<sup>7</sup>.

The indication for surgical treatment was intractable pain and/or contractures that lead to significant loss of function and reduced quality of life. The aim of surgery was to excise the lesion whilst preserving uninvolved muscle mass and critical structures, to correct fixed deformity by releasing tendon and joint contractures and to rebalance muscle/tendon forces as required.

Clinical outcomes were assessed objectively at a minimum of 12 months post-definitive treatment and patients/parents completed a Paediatric Outcomes Data Collection Instrument (PODCI).



**Figure 2.** a: Axial T1-weighted MR image through the thigh of a 5-year-old male demonstrating heterogeneous high-signal abnormality within vastus intermedius, in keeping with FAVA. The rounded low-signal areas within the lesion correspond to large dysplastic veins within the lesion, typical of this disease.

**Figure 2b:** Sagittal fat-saturated gadolinium-enhanced MR image of the lower limb of a 15-year-old male, demonstrating patchy enhancement of a FAVA lesion involving the gastrocnemius.

## Results

Since 2010, a total of 27 histologically proven FAVA cases have presented to our Paediatric Tertiary Referral Centre and have been included in this study. Patient demographics are shown in [Table 1](#). In our Institution, all referrals come to the Vascular Anomalies Team. Only one of 27 patients arrived with FAVA as a differential diagnosis.

The lower limb was involved in 20 cases, and the gastrocnemius-soleus muscle group was most commonly affected. Overall, eight patients had initially been prescribed orthotics to compensate for

**Table 1**  
Patient demographics

<b>Patient Demographics</b>	
Number of patients	27
Male: Female	15:12
Mean age at presentation	8.9 y (range: 9 m -17.4 y)
Mean follow-up	7.4y (range: 2-11.6 y)
Lower limb: Upper limb	20:7
<b>Symptoms/Signs</b>	
Pain/Exquisite tenderness	23
Joint contractures	11
<b>Imaging</b>	
Both MRI and USS	27
<b>Treatment Modalities</b>	
Sclerotherapy	11 patients
	3: Repeated injections 7: Proceeded to surgical intervention
Cryoablation	4 patients
	3: Symptomatic benefit, (transient in 1), <b>But</b> increased contracture in 1
Sirolimus	2 patients
Surgery	14 patients
	1: Symptomatic benefit

leg length inequality/joint position. In three patients, there was a significant leg length discrepancy at presentation. One patient had clawed toes due to muscle contractures.

All upper limb lesions were in the flexor compartment of the forearm with one patient who demonstrated extension into the carpal tunnel and proximal palm. Muscles affected ranged from the involvement of the entire flexor-pronator mass to more focal lesions of palmaris longus, flexor digitorum superficialis and profundus musculature. Four patients demonstrated resultant contractures of the wrist and digits. At wrist level: one patient had lost dorsiflexion and one had a flexion contracture of 10 degrees. At finger level, two patients required the release of muscle contractures. One patient required a median and ulnar nerve decompression.

Twenty-three of 27 patients presented with severe, neurogenic-type pain exacerbated by touch and by joint movement or muscle stretch. This was the most common presenting symptom and was the cause of significant dysfunction and poor mobility, which had contributed to the development of joint contractures in 11 patients. The joint contractures had usually worsened over time and with growth. Lesions were noted to be firm to clinical palpation and invariably tender to the touch.

## Interventional Radiology Management

### Sclerotherapy

Eleven patients, early in our experience of this condition, underwent sclerotherapy with little overall benefit (Tables 2, 3, and 4). In eight of these patients, sclerotherapy was the first treatment modality. Three of the 11 patients had multiple treatments with sclerotherapy. Foamed 3% STS was used as the sclerosant in 10 of the 11 patients. The other patient was treated with bleomycin with no symptomatic relief. This patient was subsequently treated with sirolimus and had decreased pain, bruising and swelling and improved function. No significant complications were noted after sclerotherapy.

### Cryoablation

All four patients who underwent cryoablation had lesions in the lower limb (Tables 2 and 4). Three patients achieved symptomatic relief and return to normal function after ablation and physiotherapy. One of these children, with an intra-articular lesion, developed recurrent pain 7 months post-ablation, requiring surgical debulking of the lesion. The fourth patient had ongoing pain and muscle contracture

**Table 2**  
Treatment of 7 Upper Limb Cases

Treatment options	Number of patients	Outcome
No treatment	1	
Sclerotherapy	3	2/3 failed • 1/2 failures progressed to surgery
Surgical Excision	4	
• Additional procedures	• 1 Nerve decompression • 2 Flexor tendon lengthening	

**Table 3**  
Treatment of 20 Lower Limb Cases

Treatment options	Number of patients	Outcome
No treatment	5	
Sclerotherapy	8	6/8 failures progressed to surgery
Cryoablation	4	1/4 proceeded to surgery
Surgical Excision	10	
Additional procedures	• 1: Nerve decompression • 8: Tendon lengthenings ◦ TA, FHL and Tib post • 2: Tendon transfers/augmentations ◦ FHL and FDL	

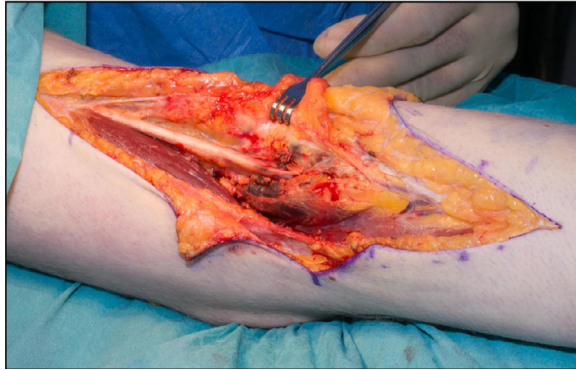**Table 4**  
Secondary Surgery: 5 procedures in 4 patients

Clinical Problem	Number of patients	Surgical Procedure
Significant leg length difference, affected side short	1	Contralateral distal femoral epiphysiodesis
Residual/recurrent disease	2	Re-excision and nerve decompression
Residual deformity	1	Calcaneal osteotomy
Persistent, severe, neurogenic pain and loss of function	1	Through-knee amputation

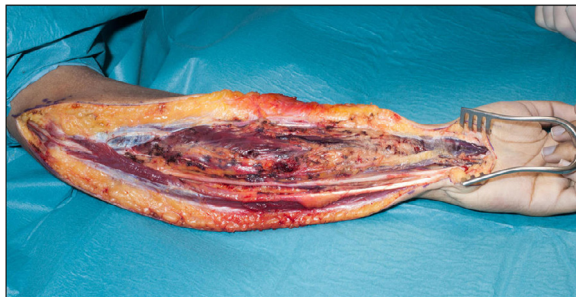post ablation; follow-up MRI demonstrated marked interval progression of disease, requiring surgical intervention.

## Surgical Intervention

Surgical intervention occurred in 14 cases (four upper limbs and 10 lower limbs) that included seven cases where sclerotherapy had failed to improve the clinical picture. (Tables 2,3 and 4). The indication for surgery was consistent pain/tenderness reported as at least 8/10 on a visual analogue scale in all cases and contracture in 11 patients. The mean age at surgery was 11.2 y (range: 4.2 y–18 y) and the mean follow-up is 3.75 y (range: 1–6 y). Surgical excision was performed in all cases with associated soft tissue releases and tendon lengthenings and/or transfers in 10 patients. No patient required a formal release of a joint. In two patients, formal decompression of the involved nerves took place (one sciatic, Figure 3 and in another both median and ulnar, Figure 4). The case that involves the sciatic nerve showed infiltration into epineurium itself in such a way that it prohibited the removal



**Figure 3.** Intraoperative image after the exploration of the flexor aspect of the thigh (posterior approach) demonstrating the involvement of the epineurium of the sciatic nerve.



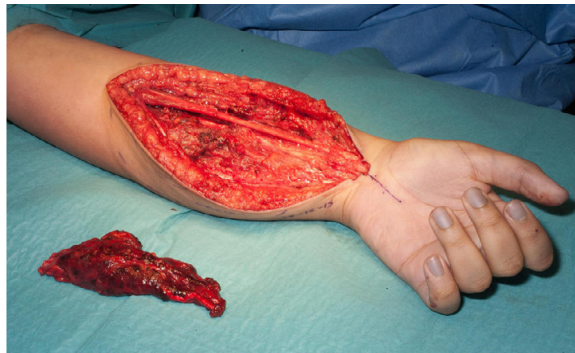
**Figure 4.** Intraoperative image after the extensive decompression of median and ulnar nerves in a case involving the majority of the flexor compartment of the forearm and demonstrating typical macroscopic appearance of the involved musculature.

of all of the involved tissue. After all but one of the surgical excisions, a drain was left in situ. All had initial post-operative splinting and those with a tendon release/reconstruction were in plaster casts for 6 weeks. In seven patients, an ankle foot orthosis (AFO) was used as part of the rehabilitation phase to protect tendon repairs/transfers and to guard against muscle imbalance that leads to further contracture. Contractures were corrected in all but one patient who was left with a neutral hind foot position but no eversion range.

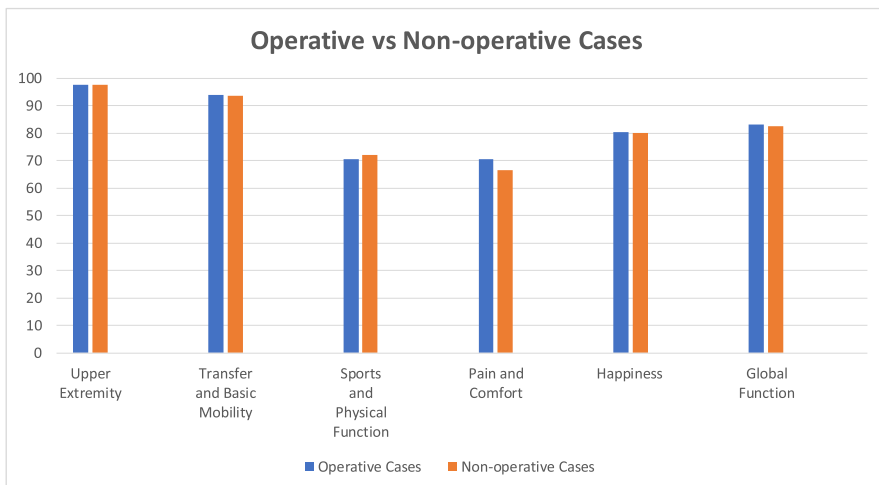
#### *Further Surgery*

After a mean follow-up of 7.4 years, further surgical procedures have been required in four patients (Table 4). One patient has undergone a contralateral epiphysiodesis for a leg length discrepancy (and one further patient is being monitored for a similar procedure). A second patient was left with residual disease and minor residual deformity, which worsened over time. Revision surgery was performed after 20 months when the residual disease was excised, the nerve decompressed and a calcaneal osteotomy performed to correct her deformity. She now uses an AFO for long distances due to the loss of calf muscle power.

Two further patients developed severe neurogenic pain and sensorimotor dysfunction. One patient developed pain after extensive dissection of the sciatic nerve and resection of a large FAVA within the hamstring muscles. As a result of the combination of intraneural involvement and nerve stretch secondary to the release of a longstanding contracture, the neurogenic pain worsened to the extent that, 2 years post initial treatment, a through-knee amputation was performed. The patient is now essentially pain free and mobile with a prosthetic limb. The other patient represented with median nerve



**Figure 5.** Intraoperative image of a forearm following debulking of involved palmaris longus and part of flexor digitorum superficialis.



**Figure 6.** PODCI (paediatric outcomes data collection instrument) scores for operative and nonoperatively treated FAVA cases.

dysfunction 2 years after a simple tendon release with limited excision of the FAVA. He underwent further excision and median nerve neurolysis but is still troubled by depressive symptoms, anxiety and pain.

### Functional Outcomes

At a most recent review, both the surgically and non-surgically treated groups demonstrated overall good functional outcomes as measured by the relief of pain and PODCI domain scores despite the loss of muscle bulk in the surgically treated group (Figure 5). This was noted particularly in the upper limb cases. Sixteen of 27 patients are entirely pain free at follow-up. Levels of function and pain post-surgical treatment were comparable to those patients whose symptoms had not warranted surgical intervention (Figure 6). Although the surgical and conservatively treated PODCI scores were similar, surgery was offered to those with most severe symptoms of pain and loss of function.



## Discussion

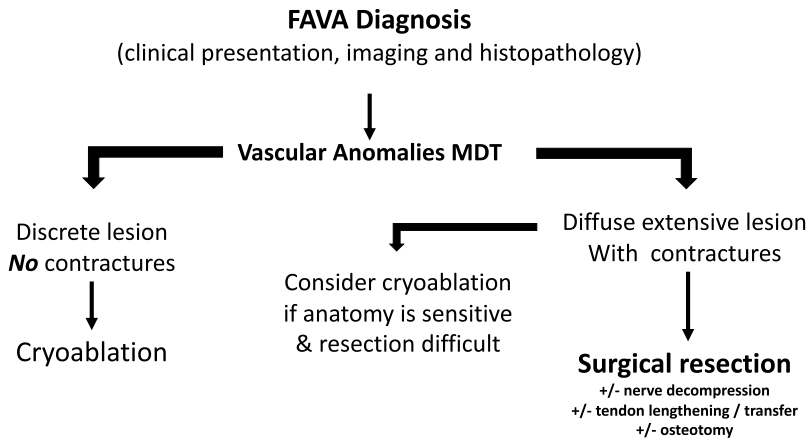
Vascular malformations vary in their clinical presentation. FAVA is characterized by a solid infiltrative lesion that typically invades muscle and neurovascular structures. In our series, as in others, there was a degree of diagnostic delay during which time the patients' symptoms and signs worsened, often with increase in contracture formation<sup>4,5</sup>. The delay caused significant distress to both patients and their families particularly as severe, intractable pain is a prominent feature of the clinical presentation. The pain limits mobility and ability to take part in normal daily activities. Tenderness on compression of the lesion is more evident than in other forms of vascular malformation, where compression is frequently therapeutic. Thus, we found the use of compression garments unhelpful. A combined clinical, radiological and histopathological analysis is essential to confirm a diagnosis of FAVA and MDT discussion, which is valuable to design a management plan<sup>8</sup>.

In this study, sclerotherapy did not result in symptomatic improvement despite repeated treatments. This was in part due to the late diagnosis of FAVA in some of these patients, some of whom were initially thought to have a venous malformation. Such diagnostic confusion is not uncommon in this patient group. In some lesions, a lack of response to sclerotherapy may suggest a FAVA diagnosis. Our team now recognises that sclerotherapy has no significant role to play in the management of this disease.

Cryoablation has been described as effective in the symptomatic management of FAVA. Shaikh et al used image-guided percutaneous cryoablation to control symptoms in their cohort of 20 paediatric and adult patients. All treatments were performed under a general anaesthetic and they identified a significant reduction in average pain experienced per 24 h and that pain interfered less with daily activities<sup>7</sup>. At 2-5 months follow up, 82% of patients were satisfied or very satisfied with the outcome of cryoablation. The long-term outcomes of cryoablation in FAVA remain unclear. Three patients in our cohort achieved pain relief and return to normal function post ablation; one of these patients required two ablation procedures to achieve complete pain relief. He developed transient Achilles tendonitis after the second cryoablation procedure that requires physiotherapy. One patient with an unusual intra-articular lesion developed symptomatic recurrence at 7 months post cryoablation requiring surgical debulking. One patient had no lasting benefit from cryoablation and required surgical intervention for severe progressive disease. Long-term studies and larger cohorts are required to determine the role of cryoablation for this disease, but it is clear that case selection is key, with cryoablation likely to have less of a role in patients with widespread disease or established contractures.

Surgical excision is indicated in patients with significant symptoms and signs who do not respond to conservative measures or cryoablation or where these techniques are inappropriate. FAVA is characterized by fibro-fatty infiltration of the muscles, with anomalous veins and the use of a tourniquet has been helpful during surgery. Often the optimal surgical plane for complete excision can be difficult to delineate and normal tissues may be compromised during the dissection. Fibrous tissue may also encircle the major peripheral nerves, and this neural scarring contributes to the characteristic neurogenic pain seen in this condition<sup>1</sup>. In line with findings from Wang et al., neural infiltration appears to be associated with a poorer long-term prognosis with a greater chance of intractable neuropathic symptoms,<sup>4</sup> and our two most disappointing results were associated with significant intraneural disease. Neurolysis and nerve decompression are surgical approaches that we have found helpful to remove the perineural fibrous tissue. Once the lesion has been excised, the deformity can be addressed by a variety of techniques that include lengthening of the muscle-tendon unit, release of joint contractures and/or osteotomy to ensure passive range of movement is restored. If, due to muscle excision, muscle imbalance is anticipated post-operatively, additional tendon transfers or augmentations can be performed. Care must be taken to address any actual or projected leg length difference of 2 cm or more with a well-timed epiphysiodesis.

Initially, there was a reluctance on the part of the surgeons to consider surgical excision as it was feared that the loss of muscle bulk would have a detrimental effect on function. However, this changed with the understanding that the pain limits function and subsequently causes contracture. We now have a lower threshold to offer surgical management; there is good correction of existing deformity and improvement in symptoms. Only 2/14 surgically treated cases have recurred. One further patient required amputation for intractable pain that was worsened by a surgical procedure: this



**Figure 7.** Suggested algorithm for the management of FAVA lesions in an MDT (multidisciplinary team) setting.

patient had undergone multiple previous procedures prior to referral, which may have compromised his final outcome.

There are few studies that have examined the management of this condition<sup>4,5,7</sup> and following this observational study, we have developed an algorithm of care based on the different treatment modalities available (Figure 7). The surgeon must consider factors that include how discrete/extensive the lesion is, the sensitivity of the anatomy and the difficulty of the resection.

Sirolimus, a mediator of the phosphoinositide 3-kinase signalling pathway, has been useful in the management of a range of vascular anomalies. We have used it in 2 cases with some benefit in one case with a very diffuse lesion. Overall, with the current level of evidence, any potential benefit would need to be balanced against the risks of systemic treatment.

This is a small retrospective study and discusses various treatment methods. Nevertheless, for a rare condition, this study does comprise a cohort of patients with a proven diagnosis who had all been managed by the same MDT and does provide some valuable information related to our treatment algorithm as a basis for further study. We believe that extensive disease, which involves an entire muscle compartment and/or intraneural extension and/or the presence of joint contractures are key features that influence management choices.

At the time this study was commenced, there was no core outcome set (COS) available for vascular anomalies. Horbach et al have now published their study that develops a COS for vascular anomalies as a whole<sup>9</sup> but this has not yet been used on this subgroup of FAVAs.

## Conclusion

FAVA is a rare but specific vascular malformation, with significant management challenges. MDT discussion and the use of a treatment algorithm help direct appropriate management. The loss of muscle bulk and function associated with surgery is counterbalanced by the improvement in pain and correction of deformity, which improves function.

## Declaration of Competing Interest

None.

## Funding

None.

**IRB approved:** ref 1932.

## References

- [1]. Alomari AI, Spencer SA, Arnold RW, et al. Fibro-adipose vascular anomaly: clinical-radiologic-pathologic features of a newly delineated disorder of the extremity. *J Pediatr Orthop.* 2014;34:109–117.
- [2]. Fernandez-Pineda ID, Marcilla D, Downey-Carmona FJ, Roldan S, Ortega-Laureano L, Bernabeu-Wittel L. Lower Extremity Fibro-Adipose Vascular Anomaly (FAVA): A New Case of a Newly Delineated Disorder. *Ann Vasc Dis.* 2014;7(3):316–319.
- [3]. Uller W, Fishman SJ, Alomari AI. Overgrowth syndromes with complex vascular anomalies. *Semin Pediatr Surg.* 2014;23(4):208–215.
- [4]. Wang KK, Glenn RL, Adams DM, et al. Surgical management of fibroadipose vascular anomaly of the lower extremities. *J Pediatr Orthop.* 2020;40:227–236.
- [5]. Cheung K, Taghnia AH, Sood RF, et al. Fibroadipose vascular anomaly in the upper extremity: a distinct entity with characteristic clinical, radiological and histopathological findings. *J Hand Surg Am.* 2020;45 68.e1-13.
- [6]. Guillet A, Connault J, Perrot P, et al. Early symptoms and long-term clinical outcomes of distal limb's cutaneous arterio-venous malformations: a retrospective multicentre study of 19 adult patients. *J Eur Acad Dermatol Venereol.* 2016;30:36–40.
- [7]. Shaikh R, Alomari AI, Kerr CL, Miller P, Spencer SA. Cryoablation in fibro-adipose vascular anomaly (FAVA): a minimally invasive treatment option. *Pediatr Radiol.* 2016;46:1179–1186.
- [8]. Markovic JN, Shortell CEK. Multidisciplinary treatment of extremity arteriovenous malformations. *J Vasc Surg Venous Lymphat Disord.* 2015;3:209–218.
- [9]. Horbach SER, van der Horst CMAM, Blei F, et al. OVAMA Consensus Group. Development of an international core outcome set for peripheral vascular malformations: the OVAMA project. *Br J Dermatol.* 2018;178(2):473–481 10.1111/bjd.16029Epub 2018 Jan 19.