



# Remote Ischaemic Pre-Conditioning Reduces Intestinal Ischaemia Reperfusion Injury in a Newborn Rat

Ian Howard Jones<sup>a, b, \*</sup>, Denise Tao<sup>c</sup>, Bhumita Vagdama<sup>c</sup>, Michael Orford<sup>d</sup>, Simon Eaton<sup>d</sup>, Jane Collins<sup>b</sup>, Nigel John Hall<sup>a, b</sup>

<sup>a</sup> Department of Paediatric Surgery and Urology, Southampton Children's Hospital, Southampton, UK

<sup>b</sup> University Surgery Unit, Faculty of Medicine, University of Southampton, Southampton, UK

<sup>c</sup> Department of Histopathology, University Hospitals Southampton NHS Foundation Trust, Southampton, UK

<sup>d</sup> Developmental Biology and Cancer Programme, UCL Great Ormond Street Institute of Child Health, London, UK

## ARTICLE INFO

### Article history:

Received 25 May 2022

Received in revised form

14 November 2022

Accepted 26 November 2022

### Keywords:

NEC

Necrotising enterocolitis

Intestinal ischaemia

RIC

Remote ischaemic conditioning

## ABSTRACT

**Objective:** Remote ischaemic conditioning (RIC) has been shown to reduce ischaemia-reperfusion injury (IRI) in multiple organ systems. IRI is seen in multiple bowel pathologies in the newborn, including NEC. We investigated the potential of RIC as a novel therapy for various intestinal pathologies in the newborn.

**Methods:** We used an established intestinal IRI model in rat pups which results in similar intestinal injury to necrotising enterocolitis (NEC). Animals were randomly allocated to IRI only (n = 14), IRI + RIC (n = 13) or sham laparotomy (n = 10). The macroscopic extent of intestinal injury is reported as a percentage of total small bowel. Injury severity was measured using Chiu-Park scoring. Neutrophil infiltration/activation was assayed by myeloperoxidase activity. Immunohistochemistry was used to assess the expression of hypoxia-inducible factor alpha (HIF-1 $\alpha$ ). Data are median (interquartile range). **Results:** Animals that underwent RIC showed a decreased extent of macroscopic injury from 100% (85–100%) in the IRI only group to 58% (15–84%, p = 0.003) in the IRI + RIC group. Microscopic injury score was significantly lower in animals that underwent RIC compared to IRI alone (3.5 [1.25–5] vs 5.5 [4–6], p = 0.014). Intestinal myeloperoxidase activity in animals exposed to IRI was 3.4 mU/mg of tissue (2.5–3.7) and 2.1 mU/mg (1.5–2.8) in the IRI + RIC group (p = 0.047). HIF-1 $\alpha$  expression showed a non-significant trend towards reduced expression in the IRI + RIC group.

**Conclusions:** RIC reduces the extent and severity of bowel injury in this animal model, supporting the hypothesis that RIC has therapeutic potential for intestinal diseases in the newborn.

© 2022 The Author(s). Published by Elsevier Inc. This is an open access article under the CC BY-NC-ND license (<http://creativecommons.org/licenses/by-nc-nd/4.0/>).

## 1. Introduction

The post-surfactant era has seen incredible improvements in outcomes for babies born prematurely. It is now the case, that the majority of babies born even at extremely low birth weight (<1000 g, ELBW) survive [1]. Moreover, they are surviving with much less neurodisability and other morbidities. However, premature infants, in particular ELBW infants are at risk of the

potentially devastating consequences of necrotising enterocolitis (NEC), which has a profound effect on both the mortality and morbidity of neonates. The overall incidence of NEC remains high, with a recent systematic review suggesting an incidence of between 2% and 7% in babies born before 32 weeks of gestation [2]. Based on a systematic review of recently published data, we estimate that overall mortality from NEC is 24%, rising to 35% in infants requiring surgery [3]. Similarly, NEC confers a high risk of severe neurodevelopmental disability – ranging from 25% to 60% of survivors [3]. Thus research efforts to reduce both morbidity and mortality from NEC remain extremely important.

The pathogenesis of NEC is complex and multifactorial but ischaemia-reperfusion injury (IRI) is part of this process [4]. This is supported by a number of observations. There is a synergistic association between systemic hypoxia and formula feeding which induces intestinal ischaemia and NEC [5]. In term infants, NEC is

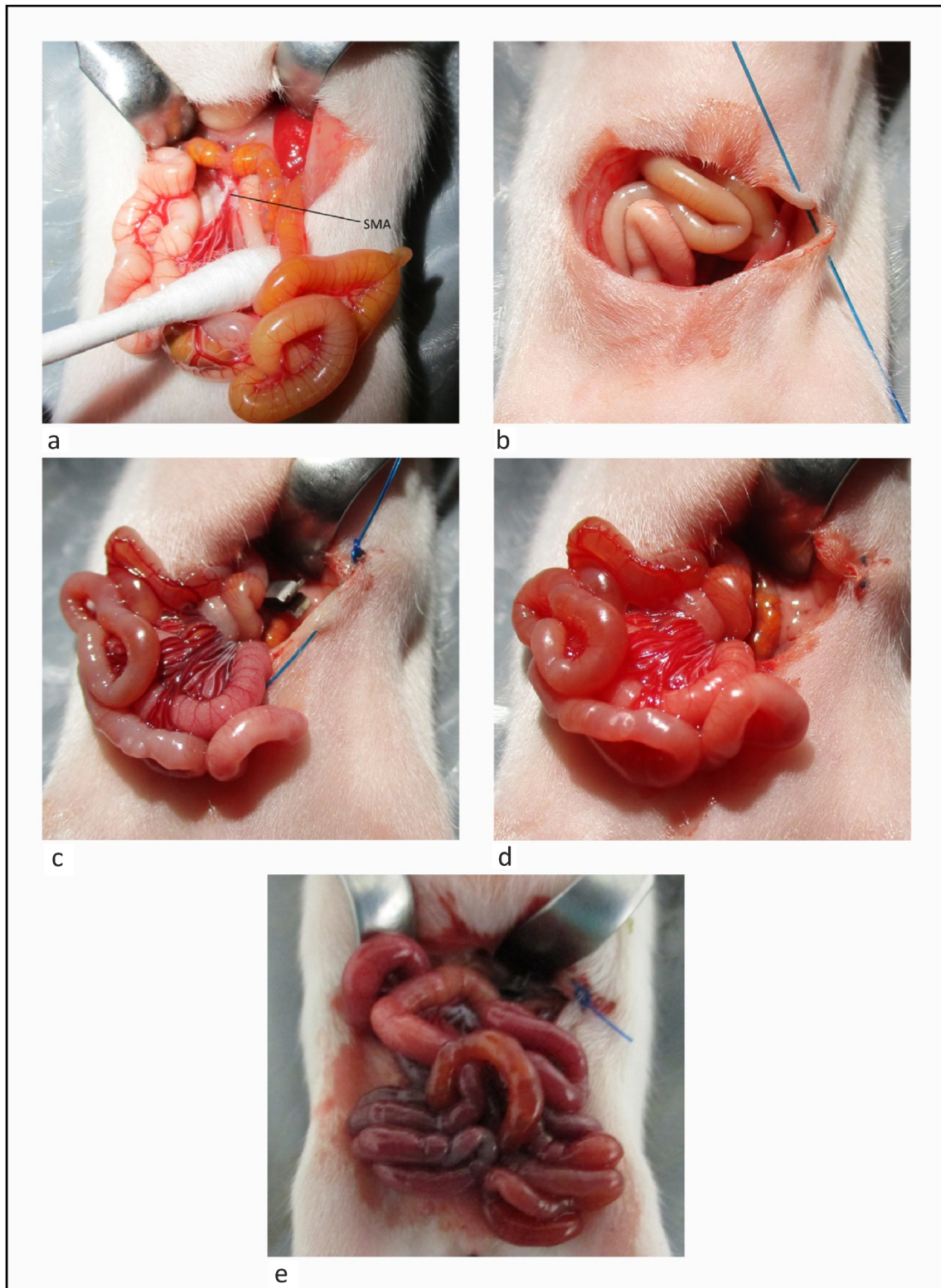
**Abbreviations:** RIC, Remote ischaemic conditioning; IRI, Ischaemia-reperfusion injury; NEC, Necrotising enterocolitis; HIF-1 $\alpha$ , Hypoxia-inducible factor 1 alpha; ELBW, Extremely low birth weight; SMA, Superior mesenteric artery; MPO, Myeloperoxidase; EDTA, Ethylenediaminetetraacetic acid; IQR, Inter-quartile range.

\* Corresponding author at: Department of Paediatric Surgery and Urology, Southampton Children's Hospital, Southampton, UK

E-mail address: [i.h.jones@soton.ac.uk](mailto:i.h.jones@soton.ac.uk) (I.H. Jones).

<https://doi.org/10.1016/j.jpedsurg.2022.11.014>

0022-3468/© 2022 The Author(s). Published by Elsevier Inc. This is an open access article under the CC BY-NC-ND license (<http://creativecommons.org/licenses/by-nc-nd/4.0/>).



**Fig. 1.** Ischaemia reperfusion of the small intestine in rat pups: 1 a shows superior mesenteric artery (SMA) exposed; 1 b hyperaemic appearance of the intestine immediately after occluding SMA; 1 c appearance after 40 min of ischaemia (SMA clamp visible in image); 1 d Hyperaemia appearance, immediately after release of SMA clamp and reperfusion; 1 e appearance of small intestine after 90 min of ischaemia with widespread necrosis.

most commonly seen in babies with congenital heart disease. There is a clear correlation between low-output states and the development of NEC. Moreover, high resistance in the superior mesenteric artery (SMA) demonstrated on ultrasonography predicts the

development of NEC. Similarly the association between the use of umbilical catheters and NEC is well established [6]. The histology of NEC specimens shows that the end-point is ischaemic necrosis [7]. HIF-1 $\alpha$  (Hypoxia-inducible factor 1-alpha), a marker of tissue

ischaemia, is increased in NEC resection specimens [8]. In pre-term infants mechanisms that regulate intestinal blood flow (involving nitric oxide and endothelin-1) do not function properly, meaning that the pre-term gut does not always adequately respond to increased metabolic demand and hence is much more susceptible to injury [9]. Animal studies also suggest that microvascular dysregulation is a key step in the pathogenesis of NEC [10].

In several clinical contexts, Remote Ischaemic Conditioning (RIC) has shown huge potential at reducing the injury to tissues and organs caused by IRI. Ischaemic conditioning was first described by Murry et al. in 1986 as an endogenous phenomenon whereby exposure to a minor, non-injurious ischaemic stimulus 'conditioned' the heart against an ischaemic insult and reduced the size of subsequent infarcts by 80% [11]. Since then it has been established that Ischaemic conditioning is also effective when used after the initiation of IRI (post-conditioning) and also can be given remotely [12]. Remote conditioning has huge potential for clinical use as it can be delivered effectively by means of blood pressure cuff inflated above systolic pressure for cycles of a few minutes. Given the observed benefit in other organ systems, we hypothesised RIC will reduce the bowel injury in an animal model of intestinal IRI in newborn rat pups. The rationale for this investigation is further supported by the recent work of Koike et al. (2020) which showed RIC to be effective using a gavage model of NEC [13]. We aimed to use a IRI model of NEC that has previous been used for translational work [14] and produces an intestinal injury by a simpler pathway than the gavage model. The experimental NEC that develops rat pups following intestinal IRI has a histological appearance is very close to that seen in human disease, as well as similar systemic effects. Moreover, this model produces the injury at a fixed time point which provides specific data about the temporal relationship between RIC at any putative protective effect.

## 2. Materials and methods

We assessed the effect of remote ischaemic pre-conditioning in an experimental animal model of intestinal IRI in suckling pup rats

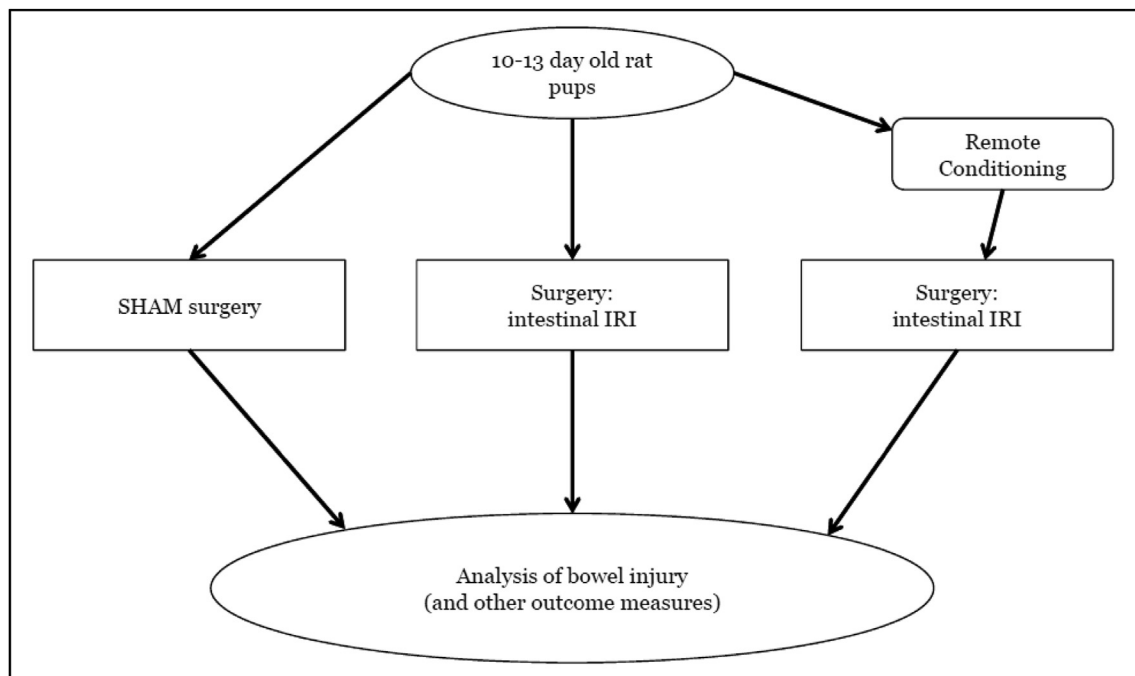
and evaluated a range of outcomes that are markers of intestinal damage.

Animal experiments were carried out with ethical approval from the local Animal Welfare and Ethical Review Body and according to the Animals in Scientific Procedures Act (APSA) 1986 and revisions (Project licence: PA813F125). This study is reported in accordance with the ARRIVE guidelines [15].

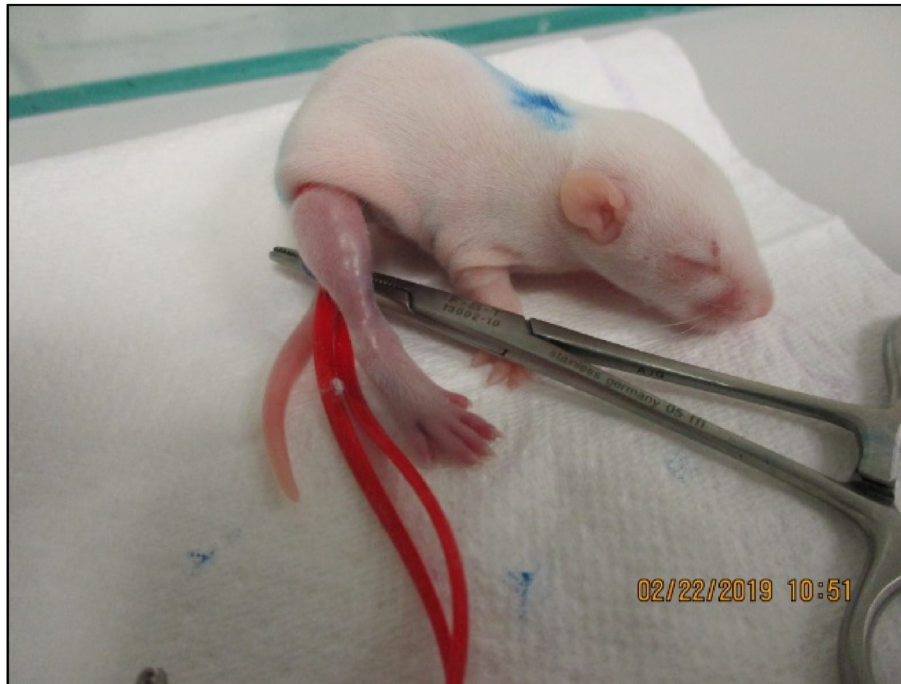### 2.1. Animal model of intestinal IRI [16]

Mixed sex suckling Sprague–Dawley rat pups were housed with their mother and allowed to suckle freely until the beginning of the experiment. Experimental procedures were performed on pups aged 10–13 days. Anaesthesia was induced and maintained with isoflurane, using oxygen as the carrier gas (1 l/min flow rate). Following induction of anaesthesia, each animal was given 0.2 ml (approx. 8–10 ml/kg) of 0.9% saline as a fluid bolus subcutaneously. Normothermia was maintained throughout the experiment using a closed-loop temperature control blanket system comprising a rectal temperature probe, augmented by a heatlamp, since it has been shown that hypothermia ameliorates the effects of intestinal IRI in this model [17,18]. Surgical procedures were conducted with 2.5× magnification by means of surgical loupes.

Experimental animals underwent laparotomy, the SMA was dissected and intestinal IRI induced by occlusion of the SMA with a microvascular clip (S&T, AG, Switzerland). Occlusion was confirmed by the loss of visible pulsation in the arterial arcades, and secondarily, by colour-change in the bowel (Fig. 1a). The abdomen was temporarily closed with a continuous suture. After 40 min of ischaemia time, the abdomen was re-opened, the clip was removed and reperfusion confirmed by the return of visible pulsation within the arterial arcades and hyperaemic colour change in the bowel (Fig. 1b and c). The abdomen was again temporarily closed with a continuous suture. After 90 min of reperfusion the animals were euthanized by exsanguination (cardiac puncture to obtain serum) whilst still under terminal general anaesthesia. Control animals underwent laparotomy and dissection of the SMA without application of the microvascular clip. Heart rate and oxygen saturation



**Fig. 2.** Experimental protocol. Pups randomly allocated to three groups; SHAM who underwent laparotomy without occlusion of SMA; intestinal IRI (positive controls) and RIC + IRI.



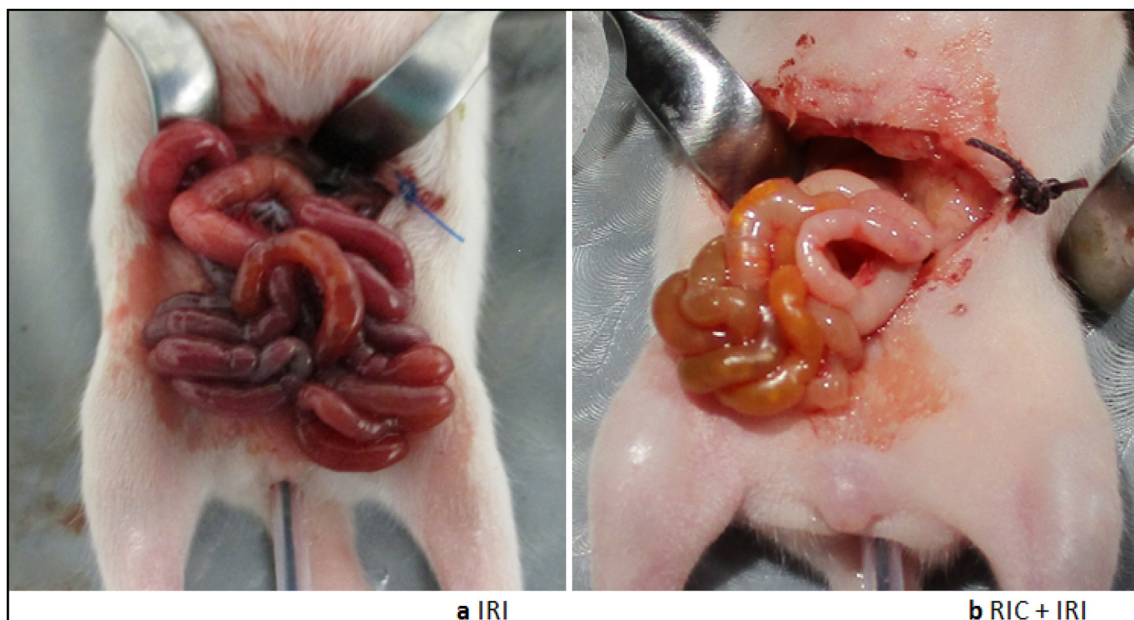
**Fig. 3.** Application of RIC with ligature to hind limb. Each animal that underwent RIC had 3 cycles of 5 min occlusion/5 min release.

was monitored by means of a pulse oximeter on the forelimb. This experimental protocol was based on that used by Stefanutti et al. and produces a significant, reproducible bowel injury that is ameliorable to intervention [16].

## 2.2. Application of RIC

In animals assigned to this experimental group (Fig. 2), RIC was induced immediately prior to anaesthesia by means of a ligature applied to the hind limb. Occlusion of arterial inflow was

demonstrated by a colour change in the limb. Further confirmation was attempted with a pulse oximeter but this proved to be unreliable in awake rat pups (Fig. 3). Each animal undergoing RIC received 3 cycles of 5 min of ischaemia with 5 min of reperfusion between the ischaemia episodes. RIC was applied prior to anaesthesia to minimise the risk of a confounding effect which is known to be a consideration with RIC [19]. The primary outcome for this study was microscopic assessment in intestinal injury. Secondary outcomes were macroscopic assessment of intestinal injury and intestinal myeloperoxidase activity.



**Fig. 4.** Bowel injury pattern at the end of reperfusion phase. 4 a: IRI only; 4 b underwent RIC prior to IRI.

### 2.3. Macroscopic assessment of bowel injury

In all animals, immediately after euthanasia, the entire small bowel was removed and laid out straight. The bowel was assessed visually and sections were categorised as 'normal,' with no bowel injury, 'severe injury' if the bowel was frankly necrotic and 'mild injury' for any bowel that was affected but not frankly necrotic. The sections of bowel in each of these three categories were measured in centimetres and the total small bowel length was measured. The results are expressed as length of bowel in each injury severity category as a percentage of total small bowel length. This model produces a variable pattern of intestinal injury with segments of frank necrosis, oedema and normal bowel seen side-by-side. This macroscopic appearance correlates well with microscopic changes and hence measuring the proportion of bowel affected is a reasonable measure of the extent of bowel injury [20]. Following this a 4 cm length of the most severely affected small intestine was removed for further analysis as detailed below.

### 2.4. Microscopic assessment of bowel injury

A 2 cm section of the most severely injured bowel was removed, flushed with phosphate buffered saline (with calcium chloride and magnesium chloride (Gibco/Therma Fisher Scientific, USA)), cut into three pieces and then immediately fixed in 10% neutral buffered formalin. These three pieces were embedded in paraffin. 5 µm sections were cut and stained with haematoxylin and eosin. Each slide contained a section from each of the three pieces and thus was representative of the whole 2 cm sample. The samples were labelled with a randomly generated 3-digit code unique to the animal to allow blinded assessment by three assessors. The same three-digit code was used for all samples from each animal. As recommended by Quaedackers et al. [21] and Oltean et al. [22], the severity of bowel injury was assessed using the Chiu-Park scoring system [23] which gives a score of 0–8 based on specific features that indicate gradations of ischaemic bowel injury from no injury (score 0) to complete loss of villi and transmural infarction (score 8). The median score of the three blinded assessors was used for analysis. Spearman r was used to assess the level of agreement between the assessors.

### 2.5. Myeloperoxidase assay

Neutrophil activity was quantified by measurement of myeloperoxidase (MPO) activity using an established technique [18]. A 2 cm section of bowel from the area of maximal injury was flushed with Phosphate Buffered Saline (with calcium chloride and magnesium chloride (Gibco/Therma Fisher Scientific USA)) and flash-frozen in liquid nitrogen before storage at  $-180^{\circ}\text{C}$  prior to batch processing and analysis. Thawed samples were weighed and then homogenised in 2 ml of 50 mM potassium phosphate buffer, pH 6.0, containing 0.5% (w/v) hexadecyltrimethylammonium bromide. 100 µl of the homogenate was extracted for protein estimation by the method of Peterson [24] and the remainder centrifuged at 21,000 g for 30 min 10 µl of the supernatant was added to 200 µl of buffer containing 0.53 mmol/l *O*-dianisidine hydrochloride and 0.0005% hydrogen peroxide. MPO activity was followed spectrophotometrically at  $30^{\circ}\text{C}$  at a wavelength of 450 nm and expressed as units (U) per mg of sample and also per mg of protein.

### 2.6. Immunohistochemistry staining for the presence of hypoxic-inducible factor alpha (HIF-1α)

In order to assess the accumulation of HIF-1α, we performed immunohistochemical staining with a HIF-1α (C-terminus)

polyclonal antibody raised in rabbit (Cayman Chemical Company, USA). 5 µm sections were cut and dewaxed with Tissue clear. Antigen retrieval was done with microwave heating in a 1 mM EDTA buffer (pH 8). The Primary antibody (HIF-1α) was applied at a concentration of 1:25 Biotinylated secondary antibody (Goat-anti-rabbit, Vector Laboratories, USA) was used at a concentration of 1 in 1000 with a 3,3'-Diaminobenzidine (DAB) substrate then applied for chromagen staining and counterstaining with haematoxylin for 1 min was performed. The slides were then scanned with an Olympus VS110 high throughput Virtual Microscopy System (Olympus, Germany). Based on the methodology described by Prasad et al. [25], the immunohistochemistry was quantified by counting the number of cells showing stain in randomly selected fields. For each sample, five randomly selected fields containing apical surface epithelium were examined and the left-most twenty

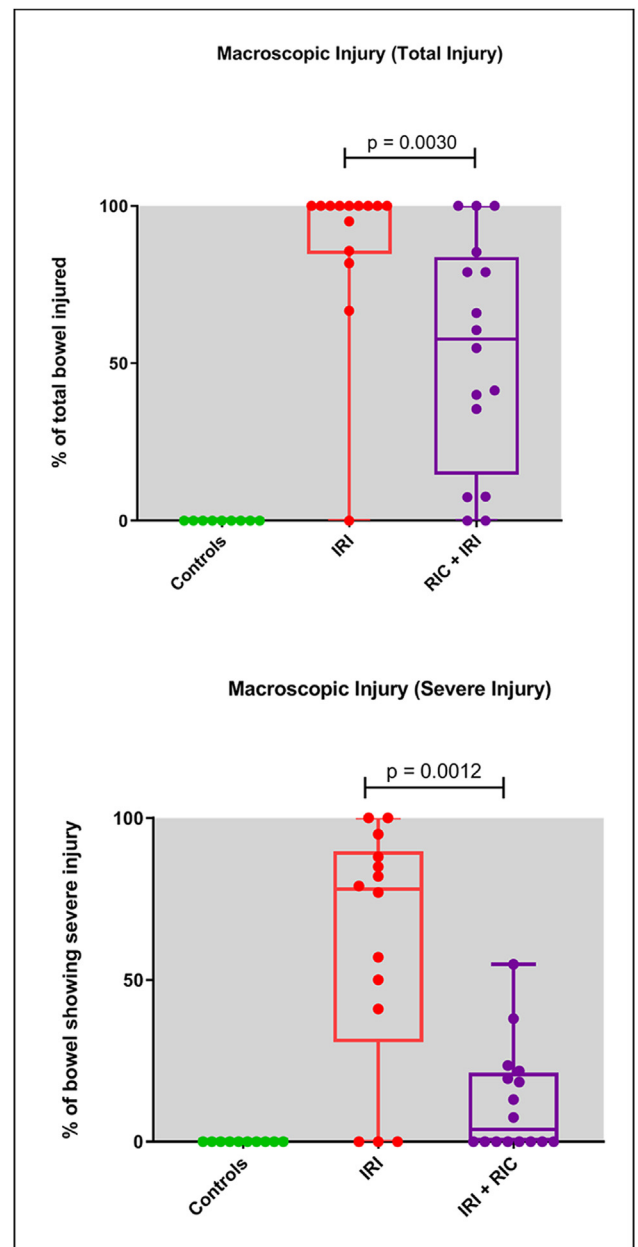


Fig. 5. Macroscopic bowel injury. Graphs show total bowel injury (as a % of total bowel resected) and severe bowel injury. All data points, median, interquartile range and range shown for each group.

cells examined. The number staining positive was counted. Summation of the numbers from all five fields thus yielded a count of cells staining positive.

### 2.7. Statistical analysis

There were 10 animals in the control group, 14 in the IRI group and 13 who underwent RIC prior to IRI. The Initial power calculation suggested groups sizes of 12–14 would be required. All statistical analyses were carried out with GraphPad Prism 8.2.1 (GraphPad Software, USA). Continuous data are presented as median and IQR. Mann–Whitney tests were used for comparison between the RIC and injury (RIC + IRI) group and the injury alone group (IRI). Spearman rank correlation analysis was used to determine the association between outcome measures.

## 3. Results

### 3.1. Macroscopic bowel injury

Fig. 4 shows the macroscopic injury seen in this model. Control animals ( $n = 10$ ) showed no macroscopic bowel injury. In animals exposed to intestinal reperfusion injury (IRI,  $n = 14$ ), the median length of intestine affected was 100% of total length (IQR 85–100%), with a median length of 78% showing severe injury (IQR 30–90%). Animals who underwent RIC prior to injury ( $n = 13$ , RIC + IRI) showed a significantly reduced injury with a median of 58% (IQR 15–84%) of the intestinal length showing any injury ( $p = 0.003$ ) and a median of 0% (IQR 0–21%) of the intestine showing severe injury ( $p = 0.0012$ ) (Fig. 5).

### 3.2. Microscopic bowel injury

Control animals had a median Chiu-Park score of 1 (IQR 0–1). Animals exposed to IRI had a median score of 5.5 (IQR 4–6) and animals who underwent RIC prior to IRI had significantly less microscopic injury, with a median score of 3.5 (IQR 1.25–5)  $p = 0.002$  (Mann–Whitney) (Fig. 6). Regression analysis showed high agreement between the blinded scorers, with Spearman's Rank coefficients of  $r_s = 0.72$ , 0.76 and 0.78.  $P < 0.0001$ .

### 3.3. Intestinal myeloperoxidase activity

MPO activity is reported both by weight of sample and by protein content. Controls showed a median MPO activity by weight of sample was 1.2 mU/mg of sample (IQR 0.9–1.5) for the controls, 3.4 (2.5–3.7) for IRI only and 2.1 (1.5–2.8) for RIC + IRI ( $p = 0.012$ ). MPO activity by protein content was 12.9 mU/mg of protein (IQR 9.6–15.7) for controls; IRI alone had a median of 24.2 mU (IQR 18.4–33.7) and RIC + IRI had a median of 20.6 (17.2–28.5)  $p = 0.60$  (Fig. 7).

Both measures of MPO activity show a correlation with the Chiu-Park scores,  $r_s = 0.39$  for the protein quantification method and  $r_s = 0.55$  weight of sample ( $p = 0.018$  and  $p = 0.0034$ , respectively).

### 3.4. Hypoxia-inducible factor one alpha

Staining was seen on apical epithelial cells and not within the crypts (Fig. 8). The median cell count for controls was 0 (IQR 0–13). Samples from animals exposed to IRI alone has a median count of 34 (19–58) and those that underwent RIC prior to IRI, 21 (5–54). Kruskal–Wallis testing showed a  $p$ -value of 0.023, with post-hoc testing showing non-significant trends when RIC were compared

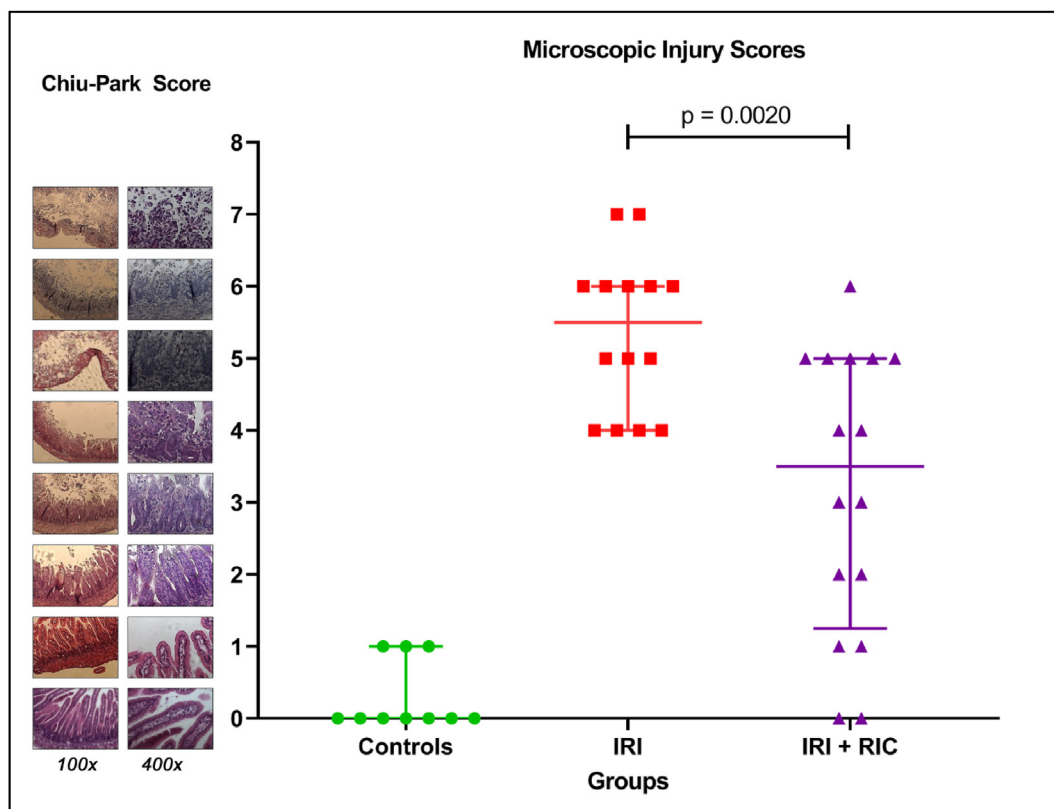


Fig. 6. Microscopic injury as quantified with Chiu-Park Scoring system. Graph shows all data points, median and interquartile range. Sample images for each score shown on y-axis.

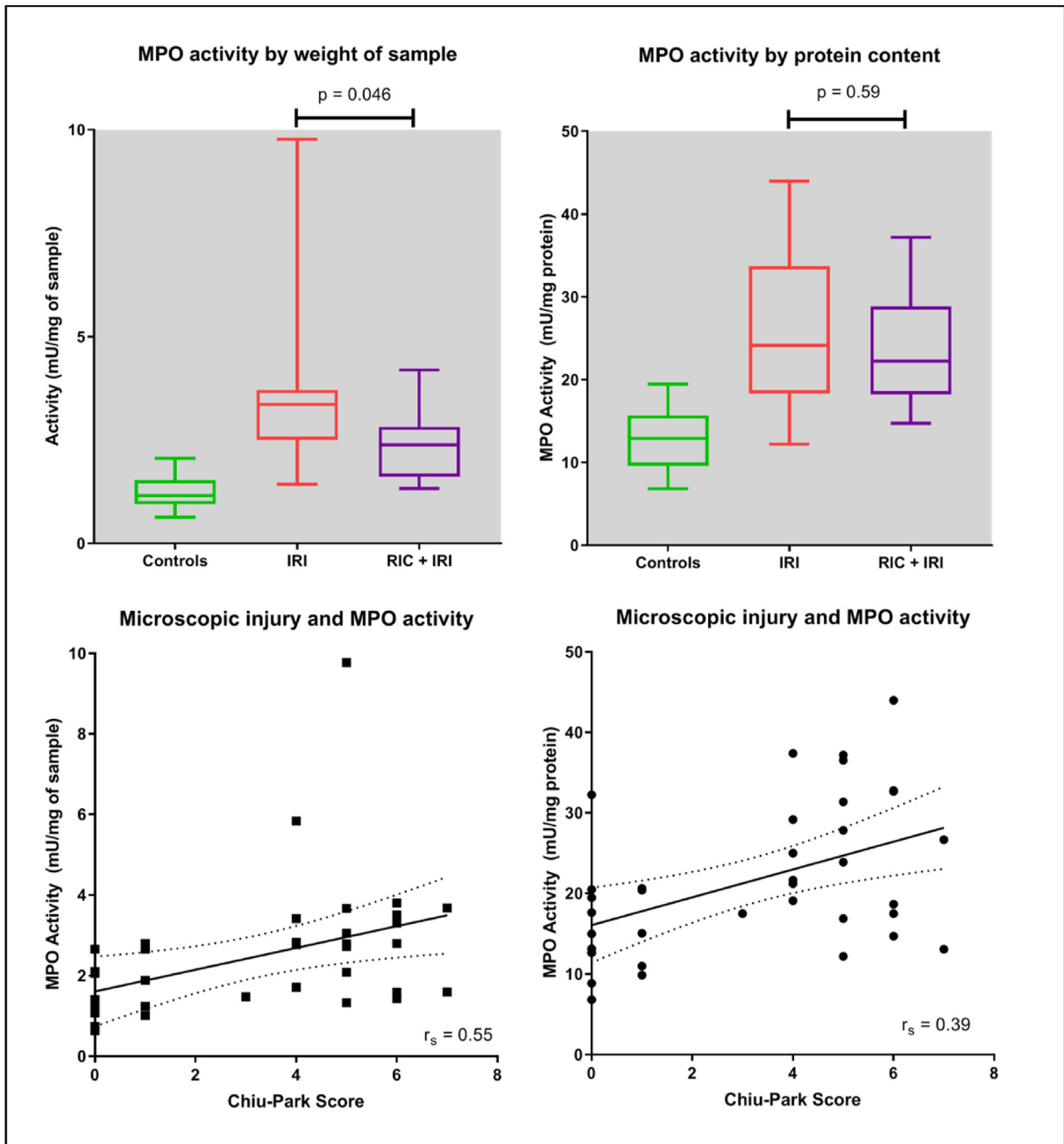


Fig. 7. Myeloperoxidase activity by sample weight and protein content. Graphs show all data points, median and interquartile range. Correlations with Chiu-Park scores shown.

with controls ( $p = 0.09$ ) and the RIC + RIC compared with IRI alone (Fig. 9)

#### 4. Discussion

We have shown, in an infant rat model that closely resembles the bowel injury observed in NEC [26], that RIC reduces the extent and severity of bowel injury. The IRI model used produced a consistent injury to the bowel mucosa and this injury was significantly mitigated by application of RIC prior to injury, indicating that RIC has a protective effect. Furthermore, the macroscopic analysis shows a significant reduction in the extent of intestinal injury when RIC is applied before IRI with both the length of intestine severely affected and the total length of injury significantly reduced in

animals who underwent RIC. Petrat et al. (2010) have demonstrated the validity of macroscopic assessment in this context [20].

Blinded scoring of the severity of bowel samples using the Chiu-Park scoring system was chosen as our primary outcome measure. This established system is sensitive enough to show progressive injury and is validated [22].

Whilst there is some variation in the magnitude of the reduction in (micro and macro-scopic) intestinal injury conferred by RIC in this IRI model, we believe that any reduction is likely to be of benefit when considering clinical translation. As mucosal disruption with consequent loss of intestinal barrier function causes leakage of pro-inflammatory factors such as endotoxin, and allows microbial translocation, decreasing the severity of injury even at a microscopic level may also decrease systemic effects. As intestinal





with a longer ischaemia time. Miyake et al. (2020) again, using a similar model in older rat pups and showed that both pre- and post- RIC reduced bowel injury [33].

The ischaemia-reperfusion injury model of NEC has important limitations. Whilst it produces an intestinal injury that is similar to that seen in human disease it does so by a much simpler pathway [26]. We acknowledge therefore that the other factors implicated in the pathogenesis of NEC are lacking in this model yet it does mimic the more severe features of NEC and importantly has been used as a basis for clinical translation previously [14,16]. The model is arguably most representative of the sub-group of term infants with congenital cardiac disease who develop NEC, as this is thought to be related primarily to poor gut perfusion [34]. However, arterial flow in the SMA of premature neonates who do not have cardiac conditions has also been shown to be an independent risk-factor for NEC [35]. Importantly, the IRI model involves arterial occlusion only, whilst venous outflow is unaffected and hence the model produces ischaemia without venous congestion. Corroboration of these results in different NEC models that include other factors known to be involved in the pathogenesis of NEC, such as formula feeding, and microbial dysbiosis, is important to confirm our findings. Koike et al. using a mouse gavage model of NEC showed that RIC reduces the severity of the disease by improving the intestinal microcirculation [13]. One particular advantage of the IRI model is that it gives a fixed time point for the initiation of bowel injury. In future work we intend to explore how long before the injury RIC can be applied and still give a protective effect. The relevance of this is that it may then be possible to provide RIC to high risk infants as a preventative measure. Since NEC occurs in premature babies from around two weeks of age onwards, it would be potentially practical to use RIC prophylactically before this time. By using this model we aim to establish the length of time that the protective effect lasts and thus use these data to design a protocol with appropriate time intervals for delivery of RIC. Similarly, we intend to investigate the mechanisms by which RIC is providing this protective effect through analysis of systemic inflammatory response and differential gene pathway expression.

Overall, these data support the use of RIC as a potential intervention for human NEC, especially in addition to the similar results seen with other animal models. In the context of other human diseases characterised by IRI most notably myocardial ischaemia, the translation to use for human disease has often not lived up to the potential seen in animal models. McCafferty et al. (2014) drew together detailed evidence on the effect of various factors that may confound the protective effect of ischaemic conditioning including hypertension, high cholesterol and cell aging [30]. None of these factors are likely to be relevant in the context of NEC as they do not apply to newborn humans. Thus we believe there is higher potential for this intervention to be translated successfully than has been observed in conditions that affect adult patients. However, a recent meta-analysis of clinical trials of RIC for non-cardiac surgery showed there is a reduction in cardiovascular events in patients exposed to RIC prior to their surgery. Moreover three trials showed consistent reduction in bowel injury biomarkers in patients who had RIC prior to vascular surgery [36].

We believe therefore that there is a potential role for RIC in the prevention of NEC. It should be noted that a recent paper did suggest that postRIC may have a detrimental effect on anastomosis healing [37]. Such an effect may limit the clinical usefulness of RIC. However, as Ballance et al. [7] demonstrated, NEC is an evolving process and not a one-time ischaemic insult. Thus, RIC delivered to infants with early NEC is not a truly post-hoc intervention. We will report separately our data on the protective effect of postRIC in this model.

## 5. Conclusion

Remote ischaemic conditioning reduces both the extent and severity of bowel injury in an animal model of ischaemia-reperfusion injury. This offers the prospect of a truly novel therapeutic intervention for several diseases, including NEC. Given the ease of administration if RIC, this further supports the proposed phase-II clinical trial protocol, recently published [38]. As with all novel therapies, this requires careful evaluation, especially in view of the potential downside of postRIC. This model also provides the basis for further work on the mechanism of RIC in the intestine.

## Previous Communication

None

## Disclosures

The authors report no proprietary or commercial interest in any product mentioned or concept discussed in this article.

## Funding sources

This work was supported by a Fellowship from the Royal College of Surgeons of England.

## Acknowledgments

University of Southampton Immunohistochemistry Unit, University of Southampton Biomedical Research Facility.

## References

- [1] Fullerton BS, Hong CR, Velazco CS, et al. Severe neurodevelopmental disability and healthcare needs among survivors of medical and surgical necrotizing enterocolitis: a prospective cohort study. *J Pediatr Surg* 2017.
- [2] Battersby C, Santhalingam T, Costeloe K, et al. Incidence of neonatal necrotizing enterocolitis in high-income countries: a systematic review. *Arch Dis Child Fetal Neonatal Ed* 2018.
- [3] Jones IH, Hall NJ. Contemporary outcomes for infants with necrotizing enterocolitis-A systematic review. *J Pediatr* 2020.
- [4] Granger CL, Bowker G, Powls A. G198(P) Express yourself: a quality improvement project aimed at early breast milk expression. *Arch Dis Child* March 2018;103: A81.
- [5] Chen Y, Koike Y, Miyake H, et al. Formula feeding and systemic hypoxia synergistically induce intestinal hypoxia in experimental necrotizing enterocolitis. *Pediatr Surg Int* 2016;32(12):1115–9.
- [6] Sulemanji M, Vakili K, Zurakowski D, et al. Umbilical venous catheter malposition is associated with necrotizing enterocolitis in premature infants. *Neonatology* 2017;111(4):337–43.
- [7] Ballance WA, Dahms BB, Shenker N, et al. Pathology of neonatal necrotizing enterocolitis: a ten-year experience. *J Pediatr* 1990;117(1 Pt 2):S6–13.
- [8] Chen Y, Chang KT, Lian DW, et al. The role of ischemia in necrotizing enterocolitis. *J Pediatr Surg* 2016;51(8):1255–61.
- [9] Nankervis CA, Giannone PJ, Reber KM. The neonatal intestinal vasculature: contributing factors to necrotizing enterocolitis. *Semin Perinatol* 2008;32(2): 83–91.
- [10] Downard CD, Grant SN, Matheson PJ, et al. Altered intestinal microcirculation is the critical event in the development of necrotizing enterocolitis. *J Pediatr Surg* 2011;46(6):1023–8.
- [11] Murry CE, Jennings RB, Reimer KA. Preconditioning with ischemia: a delay of lethal cell injury in ischemic myocardium. *Circulation* 1986;74(5):1124–36.
- [12] Kristiansen SB, Henning O, Kharbanda RK, et al. Remote preconditioning reduces ischemic injury in the explanted heart by a KATP channel-dependent mechanism. *Am J Physiol Heart Circ Physiol* 2005;288(3):H1252–6.
- [13] Koike Y, Bo L, Ganji N, et al. Remote ischemic conditioning counteracts the intestinal damage of necrotizing enterocolitis by improving intestinal microcirculation. *Nat Commun* 2020;11(1).
- [14] Hall NJ, Eaton S, Peters MJ, et al. Mild controlled hypothermia in preterm neonates with advanced necrotizing enterocolitis. *Pediatrics* 2010;125(2): e300–8.
- [15] Kilkenny C, Browne WJ, Cuthill IC, et al. Improving bioscience research reporting: the ARRIVE guidelines for reporting animal research. *PLoS Biol* 2010;8(6):e1000412.

- [16] Stefanutti G, Pierro A, Smith VV, et al. Peroxynitrite decomposition catalyst FeTMPyP provides partial protection against intestinal ischemia and reperfusion injury in infant rats. *Pediatr Res* 2007;62(1):43–8.
- [17] Vejchapipat P, Proctor E, Ramsay A, et al. Intestinal energy metabolism after ischemia–reperfusion: effects of moderate hypothermia and perfluorocarbons. *J Pediatr Surg* 2002;37(5):786–90.
- [18] Vinardi S, Pierro A, Parkinson EJ, et al. Hypothermia throughout intestinal ischaemia–reperfusion injury attenuates lung neutrophil infiltration. *J Pediatr Surg* 2003;38(1):88–91.
- [19] Kottenberg E, Thielmann M, Bergmann L, et al. Protection by remote ischemic preconditioning during coronary artery bypass graft surgery with isoflurane but not propofol - a clinical trial. *Acta Anaesthesiol Scand* 2012;56(1):30–8.
- [20] Petrat F, Swoboda S, de Groot H, et al. Quantification of ischemia–reperfusion injury to the small intestine using a macroscopic score. *J Invest Surg* 2010;23(4):208–17.
- [21] Quaedackers JS, Beuk RJ, Bennet L, et al. An evaluation of methods for grading histologic injury following ischemia/reperfusion of the small bowel. *Transplant Proc* 2000;32(6):1307–10.
- [22] Oltean M, Olausson M. The Chiu/Park scale for grading intestinal ischemia–reperfusion: if it ain't broke don't fix it. *Intensive Care Med* 2010;36(6):1095.
- [23] Park PO, Haglund U, Bulkley GB, et al. The sequence of development of intestinal tissue injury after strangulation ischemia and reperfusion. *Surgery* 1990;107(5):574–80.
- [24] Peterson GL. A simplification of the protein assay method of Lowry et al. which is more generally applicable. *Anal Biochem* 1977;83(2):346–56.
- [25] Prasad S, Mingrino R, Kaukinen K, et al. Inflammatory processes have differential effects on claudins 2, 3 and 4 in colonic epithelial cells. *Lab investigation; J Tech method and Pathol* 2005;85(9).
- [26] Tanner SM, Berryhill TF, Ellenburg JL, et al. Pathogenesis of necrotizing enterocolitis: modeling the innate immune response. *Am J Pathol* 2015;185(1):4–16.
- [27] Bowker RM, Yan X, De Plaen IG. Intestinal microcirculation and necrotizing enterocolitis: the vascular endothelial growth factor system. *Semin Fetal Neonatal Med* 2018;23(6):411–5.
- [28] Rosales C. Neutrophil: a cell with many roles in inflammation or several cell types? *Front Physiol* 2018;9:113.
- [29] De Plaen IG. Inflammatory signaling in necrotizing enterocolitis. *Clin Perinatol* 2013;40(1):109–24.
- [30] McCafferty K, Forbes S, Thiemeermann C, et al. The challenge of translating ischemic conditioning from animal models to humans: the role of comorbidities. *Dis Model Mech* 2014;7(12):1321–33.
- [31] Ceylan H, Yüncü M, Gürel A, et al. Effects of whole-body hypoxic preconditioning on hypoxia/reoxygenation-induced intestinal injury in newborn rats. *Eur J Pediatr Surg* 2005;15(5).
- [32] Hummitzsch L, Zitta K, Berndt R, et al. Remote ischemic preconditioning attenuates intestinal mucosal damage: insight from a rat model of ischemia–reperfusion injury. *J Transl Med* 2019;17(1):136.
- [33] Miyake H, Koike Y, Seo S, et al. The effect of pre- and post-remote ischemic conditioning reduces the injury associated with intestinal ischemia/reperfusion. *Pediatr Surg Int* 2020;36(12).
- [34] Polin RA, Pollack PF, Barlow B, et al. Necrotizing enterocolitis in term infants. *J Pediatr* 1976;89(3):460–2.
- [35] Murdoch EM, Sinha AK, Shanmugalingam ST, et al. Doppler flow velocimetry in the superior mesenteric artery on the first day of life in preterm infants and the risk of neonatal necrotizing enterocolitis. *Pediatrics* 2006;118(5):1999–2003.
- [36] Wahlstrøm K, Bjerrum E, Gögenur I, et al. Effect of remote ischaemic preconditioning on mortality and morbidity after non-cardiac surgery: meta-analysis. *BJS open* 2021;5(2).
- [37] Nygaard M, Mie Strandby J, Debrabant B, et al. Remote ischemic post-conditioning has a detrimental effect and remote ischemic preconditioning seems to have no effect on small intestinal anastomotic strength. *Scand J Gastroenterol* 2022;57(7).
- [38] Ganji N, Li B, Ahmad I, et al. Remote ischemic conditioning in necrotizing enterocolitis: study protocol of a multi-center phase II feasibility randomized controlled trial. *Pediatr Surg Int* 2022;38(5).