

# Transmissible human proteopathies: an expanding field

Zane Jaunmuktane<sup>1,2</sup> and Sebastian Brandner<sup>1,3</sup>

<sup>1</sup> Division of Neuropathology, the National Hospital for Neurology and Neurosurgery, UCL Hospitals NHS Foundation Trust, London, WC1N 3BG

<sup>2</sup> Department of Clinical and Movement Neurosciences and Queen Square Brain Bank, UCL Queen Square Institute of Neurology, London, WC1N 3BG

<sup>3</sup> Department of Neurodegenerative Disease, UCL Queen Square Institute of Neurology, London, WC1N 3BG

## Abstract

Prions are considered the prototype of transmissible proteopathies, and this property has for many decades been considered unique. More recently the transmissibility of other misfolded proteins, notably A $\beta$ , tau and synuclein, has been recognised. Initially, the transmission of these proteins was shown experimentally but the relevance for humans was debated. The co-transmission of A $\beta$  with prions through medical procedures involving preparations derived from cadaveric human tissues, such as human growth hormone treatment, dura mater transplants or the use of neurosurgical instruments carrying traces of A $\beta$  protein has fundamentally changed the opinion in the field. In this article, we will summarise the key features of the most common neurodegenerative diseases involving protein misfolding and their established or potential role in disease transmission.

## Glossary:

**Amyloid:** Aggregation of proteins forming a  $\beta$ -sheet structure. Most, but not all, show Congo red birefringence.

**PrP<sup>Sc</sup>:** Misfolded (abnormally shaped) normal cellular prion protein (PrP<sup>C</sup>).

**Prions:** Operational term to designate an infectious particle, containing a protein as an essential component.

**Isoforms:** Proteins that have a similar, but not an identical amino acid sequence; for tau, all isoforms are produced by the same gene *MAPT*.

**Misfolding:** Change in the shape of normal cellular proteins.

**Proteopathies:** Diseases characterised by the deposition of misfolded protein. Many neurodegenerative diseases are associated with pathological deposition and aggregation of misfolded proteins.

## Introduction

The majority of adult-onset neurodegenerative diseases, such as the most prevalent dementia Alzheimer's disease (AD) and the most common movement disorder Parkinson's disease (PD), develop through pathological aggregation of proteins or peptides. They are part of a large spectrum of more than 50 diseases, all caused by misfolding and dysfunction of soluble host proteins [25]. These abnormal proteins have the ability to self-assemble and many of them display amyloid characteristics.

Neurodegenerative diseases are leading causes for disability accompanied by a significant emotional and economic burden to the immediate family, community and society as a whole. The majority of neurodegenerative diseases are sporadic, i.e. are not associated with specific gene mutations. The strongest risk factor for the development of all sporadic neurodegenerative diseases is age. As a result of an increasing life expectancy in the years to come, there will be growing numbers of people with neurodegenerative diseases. Apart from genetic (familial, inherited) forms of neurodegenerative diseases, the underlying biological mechanisms of sporadic neurodegenerative diseases are complex and not fully understood. This complexity contributes to the difficulty to develop effective disease-modifying treatments, and currently, neurodegenerative diseases are incurable and invariably fatal.

After the discovery of the transmissible nature of prion diseases in the 1960's, it was long thought that such properties are unique to prions, and have led to the establishment of precautionary measures when handling infected tissue [5, 36, 37, 40]. Transmission of other neurodegenerative diseases, although hypothesised years ago, has been much less in the spotlight until recently. Following early studies demonstrating experimental transmission of amyloid- $\beta$  (A $\beta$ ), there was a steady growth of publications which increasingly underpinned the hypothesis of its transmissibility in experimental settings. Only the recent discovery of a possible link between human transmissions of A $\beta$  through medical procedures (human cadaveric pituitary-derived growth hormone (c-hGH), dura mater transplantations and other neurosurgical interventions), suggested that transmission of proteopathic seeds in humans was possible beyond prions.

Here, we will give a succinct overview of neurodegenerative diseases caused by misfolded proteins, review evidence of human transmission of neurodegenerative disease-associated misfolded proteins and discuss how to identify potential at-risk-cases, as well as practical health and safety aspects for pathologists.

## Overview of protein misfolding diseases associated with neurodegeneration

Most proteopathies are associated with distinct and variably overlapping clinical phenotypes and neuropathological alterations. A clinical neurodegenerative phenotype caused by misfolded protein accumulation can be broadly grouped into disorders dominated by dementia or by movement impairment. Whilst for some of the diseases additional clinical, imaging or biochemical alterations allow the distinction on clinical grounds, often an accurate diagnosis can only be established by neuropathological examination of the brain. The main proteins or peptides associated with neurodegenerative diseases are A $\beta$ , hyperphosphorylated tau protein (p-tau),  $\alpha$ -synuclein and TDP43.

**Alzheimer's disease (AD)** is by far the most common neurodegenerative disorder and it is characterised by the deposition of misfolded A $\beta$  peptide and p-tau. During disease progression, both A $\beta$  and p-tau show a distinct but stereotypical anatomical progression across different brain regions, defining the pathological disease stages [29]. However, A $\beta$  and tau spread does not equally correlate

with the clinical progression, in that p-tau load much better corresponds to clinical symptoms than A $\beta$  load. In some ways, this is not surprising, firstly, because p-tau pathology early on affects the medial temporal lobe, a region important for memory formation, and secondly, p-tau forms predominantly intracellular aggregates within neurones, whilst A $\beta$  is deposited mainly extracellularly in the surrounding neuropil. Genetic forms of AD develop only due to mutations in genes involved in A $\beta$  peptide generation from transmembrane APP protein. This discovery was followed by the widely accepted amyloid-cascade hypothesis, postulating that A $\beta$  is required for the initiation, and p-tau for the progression of AD pathology. This hypothesis, which dominated the neurodegeneration field over the last two decades, has recently been challenged, proposing that impaired APP metabolism in general (and not specifically its proteolytic fragment A $\beta$ ) may have a much wider role in AD development [24].

**Tauopathies.** There are a number of other neurodegenerative diseases in which p-tau is the sole disease-associated protein. These disorders are referred to as tauopathies. They can broadly be categorised into two groups, based on the dominant p-tau isoform. Under normal conditions, adult human neurones express 6 tau isoforms: three of these isoforms comprise three exons 9, 11 and 12, and are referred to as 3 repeat tau (3R). The other three isoforms express an additional exon 10 and are referred to as 4 repeat tau (4R). In Alzheimer's disease, p-tau is composed of 3R and 4R tau isoforms. Instead, certain tauopathies, such as progressive supranuclear palsy (PSP), corticobasal degeneration (CBD), globular glial tauopathy (GGT) and argyrophilic grain disease (AGD) are characterised by a strong predominance of 4R tau, whilst another tauopathy - Pick's disease - is characterised by a dominance of pathologically aggregated 3R tau (Figure 1). The clinical phenotypes of these tauopathies range from frontotemporal dementias to parkinsonian-type movement disorders. The majority of these primary tauopathies occur sporadically. Genetic forms of tauopathies are caused by mutations in the tau encoding *MAPT* gene, but their histopathological appearance is similar or identical to sporadic forms. An acquired, recently described tauopathy is caused by mild, repetitive head trauma (e.g. in boxers) or even by a single severe head trauma [28]. Like other neurodegenerative diseases, chronic traumatic encephalopathy (CTE) can only be definitively diagnosed by post-mortem examination of brain tissue.

**Alpha-synucleinopathies.** Pathological aggregation of  $\alpha$ -synuclein is a hallmark feature of three clinically defined neurodegenerative diseases (Figure 1). In two of them, the misshaped protein is deposited in the cytoplasm of neurones as small globules, called Lewy bodies or within neuronal processes, referred to as Lewy neurites. Lewy bodies and neurites are named after the neurologist Friedrich Heinrich Lewy, who first described them in 1912 (at the age of 27) [34]. Lewy bodies and neurites are diagnostic features of Parkinson's disease (PD) and dementia with Lewy bodies (DLB). PD initially presents with a characteristic movement impairment which may in some patients be followed by cognitive decline several years later. Instead, DLB initially presents with cognitive impairment and may be followed by movement disorder during disease progression. Of note, Lewy bodies in the amygdala region are occasionally also seen in patients with an advanced AD. Whilst the majority of PD and DLB are sporadic forms, a small proportion of Parkinson's diseases are familial, associated with mutations in a number of different genes. The third  $\alpha$ -synucleinopathy is multiple system atrophy (MSA). In contrast to PD and DLB, the dominant pathology in MSA is in oligodendrocytes rather than neurones. MSA is considered sporadic as no pathogenic mutations have been found to date.

**TDP43 proteopathies.** Displacement of TDP43 from the nucleus to the cytoplasm or into cell processes underlies a majority of motor neurone diseases (MND, also called amyotrophic lateral

sclerosis or ALS) and a proportion of frontotemporal dementias (referred to as FTL-D-TDP) (Figure 1). Both MND and FTL-D-TDP can be either sporadic or genetic due to mutations in various genes.

**Prion diseases** are caused by misfolding of the host-encoded prion protein (PrP<sup>C</sup>) into a pathological isoform (PrP<sup>Sc</sup>). The most common clinical prion disease phenotype, Creutzfeldt-Jakob disease (CJD), is characterised by typically rapidly progressive dementia. The majority of prion diseases are sporadic, with much rarer inherited and transmitted forms. Sporadic CJD (sCJD) develops as a result of a spontaneous alteration of PrP<sup>C</sup>, and its conversion into PrP<sup>Sc</sup>. Familial prion diseases are inherited in an autosomal dominant manner, caused by mutations in the *PRNP* gene. Acquired (transmitted) forms include iatrogenic exposure to prions through medical procedures such as neurosurgical repair with cadaveric dura mater, corneal transplants, use of surgical instruments, treatment c-hGH, or dietary exposure. The latter includes ritual endocannibalism in a population in the Eastern Highlands of Papua New Guinea with its peak in the 1950's. The disease presented as progressive cerebellar ataxia, "kuru" (translating to "trembling" or "shivering"). In the 1980's the human exposure to BSE (bovine spongiform encephalopathy) prions led to the development of a new strain of prion disease. Clinically, it presents as variant CJD (vCJD) with a distinct neuropathological phenotype and a unique involvement of the lymphoreticular system. vCJD secondary transmission through blood transfusion has been documented in rare instances.

#### **Prion disease transmission – a brief overview**

Prion diseases are regarded as the prototype of transmissible proteopathies and were for many decades considered unique. Initially thought to be a slow virus, the unconventional properties of prions have successively been uncovered and characterised over the last five decades. The term "prion" refers to "proteinaceous infectious agent" and was introduced by Nobel Prize winner Stanley Prusiner. The responsible protein, thought to be the sole agent of the infectious particle (the prion), was termed PrP<sup>Sc</sup> (scrapie agent). Following the description and experimental proof of the transmissible nature of prions, the corresponding gene was cloned in 1985 and termed accordingly *PRNP*, encoding for the gene product PrP<sup>C</sup> (cellular PrP). In 1966, human prions were transmitted for the first time to non-human primates, by inoculating chimpanzees with preparations from human kuru brains. This was followed in 1968 by experimental transmission of sCJD, again into primates. Since then, experimental transmission of inherited prion diseases has been attempted with varied success. A comprehensive overview of these research studies is given in [6].

The first observation suggesting transmission of prions in humans was documented in 1974 in a patient who had died of prion disease after receiving a cadaver-derived corneal graft less than 2 years earlier. Subsequently, it was found out that the corneal graft came from a patient who had died of autopsy-confirmed CJD [11]. 3 years later transmission through contaminated EEG electrodes was reported [2]. This was followed by further reports of prion disease in patients who received treatments with cadaver-derived tissue (such as extracts of growth hormone or gonadotrophin derived from pooled pituitary glands or dura mater transplants, all obtained during autopsies), or who underwent invasive surgical procedures. These reports triggered the ban of treatment with cadaver-derived hormones in the UK in 1985 and their replacement with genetically engineered peptides. The withdrawal of Lyodura (human cadaver-sourced dural grafts) from the market took place much later, in 1996.

The incubation period of iatrogenic prion diseases varies considerably. Whilst earlier reports [2, 11], documented cases with incubation periods as short as one year, much longer incubation times in the range of four decades have been described more recently in kuru [7] and in iatrogenic CJD (iCJD)

[35]. Interestingly, even in patients with long incubation periods once the first symptoms develop the disease typically is of comparably short duration.

### **Disease versus disease-associated misfolded protein transmission**

Increasing evidence from experimental studies supports the concept that misfolded proteins or peptides associated with neurodegenerative diseases can act as a seed or template by inducing conformational changes in native proteins, leading to their continuous corruption and misfolding, trans-cellular propagation throughout the nervous system, and progression of clinical symptoms. Given that ageing is the strongest risk factor for neurodegenerative diseases, it is not surprising that incidental Alzheimer's type A $\beta$  and tau pathology, Lewy body pathology or TDP43 pathology can be observed within vulnerable (susceptible) brain regions even in clinically healthy individuals. Thus, histopathological identification of these aggregates does not equate to neurodegenerative disease carrier status and it remains speculative that these patients would have progressed to develop a disease phenotype, had they lived longer.

A notable exception is the A $\beta$  cerebral amyloid angiopathy (CAA). CAA is seen in a majority of patients with AD and occurs also sporadically with increasing age with no associated AD. CAA can be found either in leptomeninges overlying the brain, within brain parenchyma or both. The A $\beta$  deposition in the blood vessel walls makes them fragile and prone to rupture, causing intracerebral haemorrhages.

Unlike in prion diseases, there is no epidemiological evidence that advanced AD or PD has been transmitted between humans through blood transfusions and other medical procedures [1]. However, the challenge of epidemiological studies to assess potential transmissibility of neurodegenerative diseases such as AD and PD lies in the comparably high prevalence of these diseases in the general population and in the long incubation periods, overlapping with the onset and the slowly progressive clinical symptoms of the sporadic presentation of AD or PD.

### **Transmissible proteopathies - animal models and human disease**

#### *A $\beta$ (one of the hallmark proteins in AD)*

Experimental transmission of A $\beta$  has been demonstrated through intracerebral injections in primates [32] and rodents and nearly all routes of transmission have been successful in mice [8, 14].

In 2015 we provided the first evidence that A $\beta$  may also be transmissible in humans, through medical procedures [22]. Here, we observed a high load of A $\beta$  in parenchyma and vasculature of a proportion of patients who had died from iCJD decades after receiving cadaver-derived human GH (c-hGH) treatment. Until 1985, when the use of c-hGH preparations was banned in the UK, more than 400,000 pituitary glands had been collected, and pools of glands homogenised for the preparation of GH injections. These GH extracts were repeatedly injected intramuscularly over a variable period of time. The contamination of the pool with a single or several glands derived from carriers of sporadic CJD caused the transmission of prions and the development of GH-related iCJD in the recipients. However, the concomitant contamination with A $\beta$  seeds had thus far been undiscovered, until we analysed a cohort of young adults with gh-iCJD, and noted striking parenchymal and vascular A $\beta$  pathology. After we published this mode of transmission, brains of patients who died of dural transplant related iCJD (d-iCJD) were also confirmed to contain A $\beta$  in parenchyma and blood vessels [17]. Similar findings have been published in further cohorts from different countries (Figure 2 and 3). An important corollary to our study [22] is the finding of A $\beta$  pathology in patients who were treated with c-hGH, but did not develop prion disease [33],

reinforcing our hypothesis that the two pathologies (A $\beta$  and prions) developed independently rather than through a co-dependent seeding process (Figure 2) [9, 12, 18].

None of the patients described in the above studies demonstrated signs of AD and none had any significant p-tau or any other protein aggregate. Therefore, it remains uncertain, if any of these patients would have developed AD had they lived longer. None of the above patients were also documented to have any signs of CAA-related haemorrhages.

An additional mode of transmission of prion diseases is through contaminated neurosurgical instruments. By reviewing past medical histories of young adults who had undergone brain biopsies or had died of intracerebral haemorrhages, we have recently identified four young adults who had developed intracerebral bleeds caused by CAA [23]. All patients had in common one or several neurosurgical interventions in their childhood or teenage years for various reasons, such as head trauma, intracranial tumour or malformations. Through a review of the literature, we identified four more case studies of patients who presented with intracerebral CAA-related haemorrhage and had evidence of childhood neurosurgery. A further recent case report documents a fatal CAA-related intracerebral haemorrhage in a young patient who had received a human cadaver-derived dural graft as a child [19].

We and others have shown that A $\beta$  may be contained in pituitary glands [20, 22] or in dura mater [27] and this implies a possible source for transmission. Moreover, A $\beta$  and tau have been found in the c-hGH batches used for GH injection preparations [12]. These studies demonstrate that the cadaver-derived material used for medical procedures and contaminated surgical instruments were indeed the source of A $\beta$  seeds and that iatrogenic CAA may lead to devastating intracerebral haemorrhages.

#### *Tau, $\alpha$ -synuclein and TDP43*

*In vitro* and/or *in vivo* transmission of tau,  $\alpha$ -synuclein and TDP43 aggregates derived from brains from patients with associated neurodegenerative diseases has been demonstrated [38], but at present, human transmission of these proteins has not been described.

#### **How to identify potential iatrogenic transmission of A $\beta$**

As discussed above, there is a growing number of *in vitro* studies and animal experiments demonstrating the transmissibility of misfolded proteins implicated in neurodegenerative diseases. There is now strong support for A $\beta$  seed transmission in humans through contaminated human cadaver-derived tissues, and this should prompt consideration of iatrogenic A $\beta$  transmission in all patients with a history of treatment with human cadaver-derived tissues, such as GH or gonadotrophin injections, implantation or administration of any product containing dura mater, or corneal transplants. In analogy to prion diseases, A $\beta$  seed transmission may also occur through contaminated neurosurgical instruments. Hence, potentially in all patients the past medical history of invasive surgical, and notably neurosurgical manipulations may be of relevance in terms of possible proteopathic seed transmission [23].

However, there are two important caveats. First, neurodegenerative proteopathies are highly prevalent in the ageing population, and such high prevalence confounds discrimination from transmitted seeds through prior invasive surgical procedures or administration of human-derived treatments and sporadic cases. Second, all previous observational studies indicate long latencies (more than 2 decades) between the causative intervention and A $\beta$  pathology development. This

implies that an absence of pathology in patients with shorter incubation times does not equate to the absence of transmission.

CAA is a characteristic feature of human A $\beta$  transmission, and CAA is highly unusual in patients under 55 years of age. These two circumstances should prompt further investigation into the cause of CAA in younger people. Once pathogenic mutations in *APP*, *PSEN1* and *PSEN2* (genes associated with early-onset A $\beta$  pathology) have been excluded, a critical review and scrutiny of the past medical history, in particular for any evidence of surgical interventions or past medical treatments, is recommended. So far no association of blood transfusions and AD have been observed [3, 10, 26, 30]. Nevertheless, as discussed above, transmission of the misfolded protein or peptide does not necessarily equate to transmission of the associated disease. The limited numbers of epidemiological studies have looked only for evidence of an advanced neurodegenerative disease based on clinical criteria and these studies have only reviewed medical records but did not correlate with the neuropathological post-mortem findings. Therefore, further studies would be necessary to assess risks of transmission of misfolded proteins associated with neurodegenerative disease.

### **The risks of transmission - health and safety aspects**

The experimental transmission and the circumstantial evidence of human transmission of proteopathic seeds through medical procedures raise questions about safety in relation to handling human tissue and research with transgenic animals.

The safety and transmission aspects of prion diseases have been extensively covered elsewhere and guidelines of best practice have been widely published by official bodies, such as the UK Department of Health and Public Health England (<https://www.gov.uk/government/collections/creutzfeldt-jakob-disease-cjd-guidance-data-and-analysis>, accessed in September 2018) and this resource is continuously updated. Model systems of the transmission of prions have recently been published in a comprehensive review [6].

For all other transmissible proteopathies, very limited or no guidance is currently available. The human transmission of A $\beta$  occurred more than three decades ago, in the context of administration of c-hGH, and the use of such cadaver-derived GH ceased in 1985 once identified as a source of CJD transmission. Dura mater, another established source of CJD transmission and recently identified source for A $\beta$  transmission, was withdrawn from the market in the 1990's, but it cannot be excluded that batches of Lyodura stocked in hospitals may have been used for many more years after without adequate documentation, making identification of at-risk patients difficult.

The risk of A $\beta$  transmission through surgical procedures needs to be assessed appropriately. Again, the methods of instrument decontamination and sterilisation have changed over time. It is not possible to reconstruct the procedures used for neurosurgical instrument decontamination 2-3 decades ago, and, therefore, it is currently not possible to draw any conclusions about the safety of current procedures.

For experimental studies involving human tissue in laboratory settings, adherence to good laboratory practice, and observing general health and safety guidelines relevant to handling of human tissue has been considered as appropriate in a recent workshop and expert consultation at the National Institute of Health, (Bethesda, MD USA) May 2, 2018 (Neurodegenerative Disease Transmissibility: Current Science and Recommendations for Future Research, SB personal communication).

It is well established that formaldehyde and standard decontamination and sterilization procedures are insufficient to completely remove infectivity from prion-contaminated instruments and protocols for appropriate decontamination are widely published [5, 13, 21, 36, 40]. There is evidence that A $\beta$  (similar to prions) is resistant to heat and formaldehyde treatment [16] and adheres to stainless steel surfaces [14]. The effectiveness of different commercially available reagents to disassemble A $\beta$ , tau or  $\alpha$ -synuclein seeds, adsorbed on non-disposable materials, such as plastic, glass, aluminium or stainless steel surfaces have been recently published [4, 15, 31, 39]. A recent study [15] describes cleaning procedures with commercially available detergents, SDS, TFD4 and Hellmanex (1% in MilliQ water) that are effective in removing  $\alpha$ -synuclein, tau and A $\beta$  from non-disposable laboratory tools. However, the detergents TFD4 and Hellmanex corrode aluminium surfaces highlighting the need of taking into account the compatibility between the detergent and the surface when choosing the most appropriate decontamination method. Details of the compatibility and efficacy between different cleaning procedures and laboratory tools in relation to the removal of  $\alpha$ -synuclein, tau and A $\beta$ , are published in [15].

## **Conclusion**

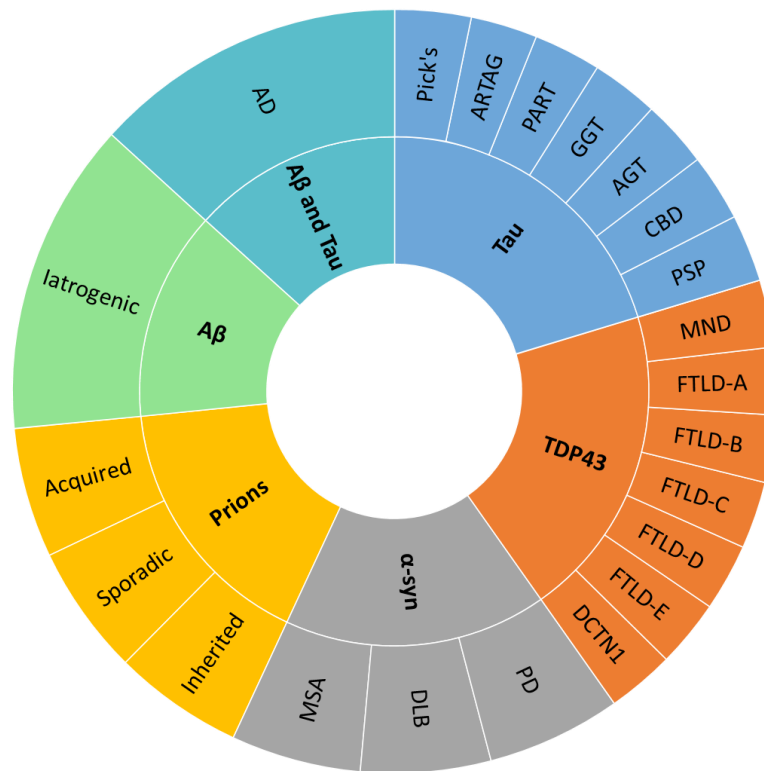In conclusion, there is significant experimental evidence that misfolded proteins implicated in neurodegenerative diseases are potentially transmissible. Apart from the established human transmission of prions, there is also growing evidence that A $\beta$  can be transmitted in humans.

Currently, there is no epidemiological evidence that advanced neurodegenerative diseases could have been iatrogenically transmitted. However, there is strong evidence from observational studies that intracerebral, often fatal, haemorrhages develop as a consequence of iatrogenic transmission of vascular A $\beta$  [19, 23]. Further detailed studies are now required to ascertain the transmission risk of all proteins implicated in neurodegenerative diseases, so that appropriate risk assessments for procedures involving human tissues are carried out and correct, standardised decontamination approaches are used for equipment in clinical and research practice.

## **Acknowledgements:**

This study was funded by the National Institute for Health Research Biomedical Research Centre's funding scheme to University College London Hospitals. ZJ and SB declare no conflict of interest.



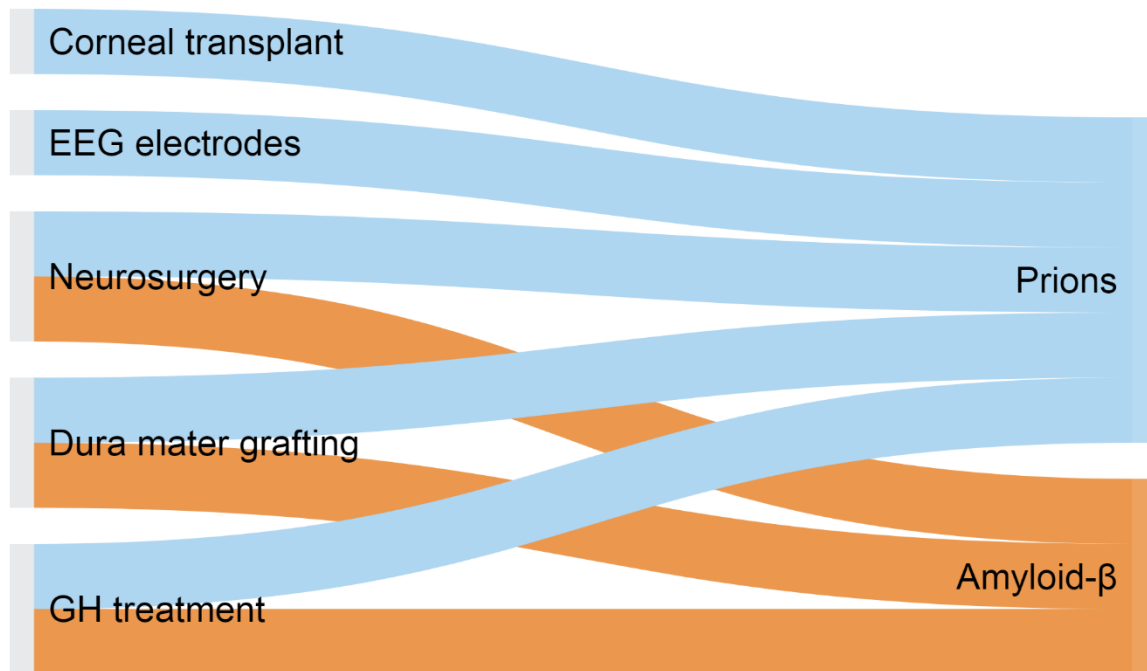


**Figure 1: Overview of neurodegenerative diseases associated with misfolded protein aggregation.**

The inner circle shows the misfolded protein and the outer circle indicates the disease associated with it. Clockwise from top: Tau (blue): associated with Pick's disease, ARTAG – ageing related tau astrogliopathy, PART – primary ageing related tauopathy, GGT – globular glial tauopathy, AGT – argyrophilic grain disease, CBD – corticobasal degeneration, PSP – progressive supranuclear palsy. TDP43 (orange): MND – motor neurone disease, FTLD-TDP, type A to FTLD-TDP, type E – types of frontotemporal lobar degeneration, DCTN1 – a neurodegenerative disease associated with mutations in the *DCTN1* gene. α-synuclein (grey): PD – Parkinson's disease, DLB – dementia with Lewy bodies, MSA – multiple system atrophy. Prion diseases (yellow): aetiologically subdivided into inherited, sporadic and acquired forms. Aβ (green) with no concomitant pathology can be seen in transmitted forms, whilst in combination with tau (cyan) is characteristic of AD – Alzheimer's disease.

Year	GH treatment and CJD	GH treatment, no CJD	Dural grafting and CJD	Dura grafting, no CJD	Neurosurgery, no CJD
1996			Simpson et al. Australia		
2006			Preusser et al. Austria		
2015	Jaunmuktane et al. UK				
2016			Frontzek et al. Switzerland Kovacs et al. Austria Hamaguchi et al. Japan		
2017	Ritchie et al. UK	Ritchie et al. UK			
2018	Cali et al. USA Duyckaerts et al. France		Cali et al. USA, Australia, France, Italy	Herve et al. France	Jaunmuktane et al. UK, Belgium, Portugal

**Figure 2: Timeline of published studies on A $\beta$  transmission in humans.** The left column indicates the publication year. The subsequent columns to the right show publications of case series of transmitted proteopathies. Column 2 (dark brown), patients with human cadaver-derived growth hormone (c-hGH) related iatrogenic Creutzfeldt-Jakob disease (iCJD) and A $\beta$  pathology; Column 3 (light brown), patients treated with c-hGH who died of causes other than prion disease but developed A $\beta$  pathology. Column 4 (green), patients who died of iCJD due to dural grafting and had additional A $\beta$  pathology (first two studies from 1996 and 2006 documented A $\beta$  pathology but did not suggest the possibility of iatrogenic A $\beta$  transmission); Column 5 (cyan), patients who received human cadaver-derived dura mater grafts and developed A $\beta$  pathology but did not develop prion disease. Column 6 (blue), patients with past medical history of neurosurgery, who had parenchymal and vascular A $\beta$  but not CJD.



**Figure 3: Treatments associated with prion and A $\beta$  transmission in humans.** Medical treatments and surgical procedures associated with A $\beta$  and/or prion transmission are shown on the left. The lines in blue demonstrate the treatments or surgical procedures which have resulted in prion transmission and the orange lines denote treatments and procedures resulting in A $\beta$  transmission. Human cadaver-derived corneal grafting, shown on the top left, was the first documented procedure resulting in prion disease transmission, whilst a group of patients who had received human cadaver-derived GH treatment, shown on the bottom left, was the first cohort in which evidence of A $\beta$  transmission was demonstrated.

## References:

1. Beekes M, Thomzig A, Schulz-Schaeffer WJ and Burger R (2014) Is there a risk of prion-like disease transmission by Alzheimer- or Parkinson-associated protein particles? *Acta neuropathologica* 128:463-476
2. Bernoulli C, Siegfried J, Baumgartner G, Regli F, Rabinowicz T, Gajdusek DC and Gibbs CJ, Jr. (1977) Danger of accidental person-to-person transmission of Creutzfeldt-Jakob disease by surgery. *Lancet* 1:478-479
3. Bohnen NI, Warner MA, Kokmen E, Beard CM and Kurland LT (1994) Prior blood transfusions and Alzheimer's disease. *Neurology* 44:1159-1160
4. Bousset L, Brundin P, Bockmann A, Meier B and Melki R (2016) An Efficient Procedure for Removal and Inactivation of Alpha-Synuclein Assemblies from Laboratory Materials. *Journal of Parkinson's disease* 6:143-151
5. Bradford BM, Piccardo P, Ironside JW and Mabbott NA (2014) Human prion diseases and the risk of their transmission during anatomical dissection. *Clinical anatomy (New York, N.Y.)* 27:821-832
6. Brandner S and Jaunmuktane Z (2017) Prion disease: experimental models and reality. *Acta neuropathologica* 133:197-222
7. Brandner S, Whitfield J, Boone K, Puwa A, O'Malley C, Linehan JM, Joiner S, Scaravilli F, Calder I, M PA, Wadsworth JD and Collinge J (2008) Central and peripheral pathology of kuru: pathological analysis of a recent case and comparison with other forms of human prion disease. *Philosophical transactions of the Royal Society of London. Series B, Biological sciences* 363:3755-3763
8. Burwinkel M, Lutzenberger M, Heppner FL, Schulz-Schaeffer W and Baier M (2018) Intravenous injection of beta-amyloid seeds promotes cerebral amyloid angiopathy (CAA). *Acta neuropathologica communications* 6:23
9. Cali I, Cohen ML, Hasmall yi US, Parchi P, Giaccone G, Collins SJ, Kofskey D, Wang H, McLean CA, Brandel JP, Privat N, Sazdovitch V, Duyckaerts C, Kitamoto T, Belay ED, Maddox RA, Tagliavini F, Pocchiari M, Leschek E, Appleby BS, Safar JG, Schonberger LB and Gambetti P (2018) Iatrogenic Creutzfeldt-Jakob disease with Amyloid-beta pathology: an international study. *Acta neuropathologica communications* 6:5
10. Darby SC, Kan SW, Spooner RJ, Giangrande PL, Hill FG, Hay CR, Lee CA, Ludlam CA and Williams M (2007) Mortality rates, life expectancy, and causes of death in people with hemophilia A or B in the United Kingdom who were not infected with HIV. *Blood* 110:815-825

11. Duffy P, Wolf J, Collins G, DeVoe AG, Streeten B and Cowen D (1974) Letter: Possible person-to-person transmission of Creutzfeldt-Jakob disease. *The New England journal of medicine* 290:692-693
12. Duyckaerts C, Sazdovitch V, Ando K, Seilhean D, Privat N, Yilmaz Z, Peckeu L, Amar E, Comoy E, Maceski A, Lehmann S, Brion JP, Brandel JP and Haik S (2018) Neuropathology of iatrogenic Creutzfeldt-Jakob disease and immunoassay of French cadaver-sourced growth hormone batches suggest possible transmission of tauopathy and long incubation periods for the transmission of Abeta pathology. *Acta neuropathologica* 135:201-212
13. Edgeworth JA, Sicilia A, Linehan J, Brandner S, Jackson GS and Collinge J (2011) A standardized comparison of commercially available prion decontamination reagents using the Standard Steel-Binding Assay. *The Journal of general virology* 92:718-726
14. Eisele YS, Bolmont T, Heikenwalder M, Langer F, Jacobson LH, Yan ZX, Roth K, Aguzzi A, Staufienbiel M, Walker LC and Jucker M (2009) Induction of cerebral beta-amyloidosis: intracerebral versus systemic Abeta inoculation. *Proceedings of the National Academy of Sciences of the United States of America* 106:12926-12931
15. Fenyi A, Coens A, Bellande T, Melki R and Bousset L (2018) Assessment of the efficacy of different procedures that remove and disassemble alpha-synuclein, tau and A-beta fibrils from laboratory material and surfaces. *Scientific reports* 8:10788
16. Fritschi SK, Cintron A, Ye L, Mahler J, Buhler A, Baumann F, Neumann M, Nilsson KP, Hammarstrom P, Walker LC and Jucker M (2014) Abeta seeds resist inactivation by formaldehyde. *Acta neuropathologica* 128:477-484
17. Frontzek K, Lutz MI, Aguzzi A, Kovacs GG and Budka H (2016) Amyloid-beta pathology and cerebral amyloid angiopathy are frequent in iatrogenic Creutzfeldt-Jakob disease after dural grafting. *Swiss medical weekly* 146:w14287
18. Hamaguchi T, Taniguchi Y, Sakai K, Kitamoto T, Takao M, Murayama S, Iwasaki Y, Yoshida M, Shimizu H, Kakita A, Takahashi H, Suzuki H, Naiki H, Sanjo N, Mizusawa H and Yamada M (2016) Significant association of cadaveric dura mater grafting with subpial Abeta deposition and meningeal amyloid angiopathy. *Acta neuropathologica* 132:313-315
19. Herve D, Porche M, Cabrejo L, Guidoux C, Tournier-Lasserre E, Nicolas G, Adle-Biassette H, Plu I, Chabriat H and Duyckaerts C (2018) Fatal Abeta cerebral amyloid angiopathy 4 decades after a dural graft at the age of 2 years. *Acta neuropathologica* 135:801-803
20. Irwin DJ, Abrams JY, Schonberger LB, Leschek EW, Mills JL, Lee VM and Trojanowski JQ (2013) Evaluation of potential infectivity of Alzheimer and Parkinson disease proteins in recipients of cadaver-derived human growth hormone. *JAMA neurology* 70:462-468

21. Jackson GS, McKintosh E, Flechsig E, Prodromidou K, Hirsch P, Linehan J, Brandner S, Clarke AR, Weissmann C and Collinge J (2005) An enzyme-detergent method for effective prion decontamination of surgical steel. *The Journal of general virology* 86:869-878
22. Jaunmuktane Z, Mead S, Ellis M, Wadsworth JD, Nicoll AJ, Kenny J, Launchbury F, Linehan J, Richard-Loendt A, Walker AS, Rudge P, Collinge J and Brandner S (2015) Evidence for human transmission of amyloid-beta pathology and cerebral amyloid angiopathy. *Nature* 525:247-250
23. Jaunmuktane Z, Quaegebeur A, Taipa R, Viana-Baptista M, Barbosa R, Koriath C, Sciot R, Mead S and Brandner S (2018) Evidence of amyloid-beta cerebral amyloid angiopathy transmission through neurosurgery. *Acta neuropathologica* 15:018-1822
24. Kametani F and Hasegawa M (2018) Reconsideration of Amyloid Hypothesis and Tau Hypothesis in Alzheimer's Disease. *Frontiers in neuroscience* 12:25
25. Knowles TP, Vendruscolo M and Dobson CM (2014) The amyloid state and its association with protein misfolding diseases. *Nature reviews. Molecular cell biology* 15:384-396
26. Kokmen E, Beard CM, O'Brien PC and Kurland LT (1996) Epidemiology of dementia in Rochester, Minnesota. *Mayo Clin Proc* 71:275-282
27. Kovacs GG, Lutz MI, Ricken G, Strobel T, Hoftberger R, Preusser M, Regelsberger G, Honigschnabl S, Reiner A, Fischer P, Budka H and Hainfellner JA (2016) Dura mater is a potential source of Aβ seeds. *Acta neuropathologica* 131:911-923
28. McKee AC, Cairns NJ, Dickson DW, Folkerth RD, Keene CD, Litvan I, Perl DP, Stein TD, Vonsattel JP, Stewart W, Tripodis Y, Crary JF, Bieniek KF, Dams-O'Connor K, Alvarez VE and Gordon WA (2016) The first NINDS/NIBIB consensus meeting to define neuropathological criteria for the diagnosis of chronic traumatic encephalopathy. *Acta neuropathologica* 131:75-86
29. Montine TJ, Phelps CH, Beach TG, Bigio EH, Cairns NJ, Dickson DW, Duyckaerts C, Frosch MP, Masliah E, Mirra SS, Nelson PT, Schneider JA, Thal DR, Trojanowski JQ, Vinters HV, Hyman BT, National Institute on Aging-Alzheimer's Association (2012) National Institute on Aging-Alzheimer's Association guidelines for the neuropathologic assessment of Alzheimer's disease: a practical approach. *Acta neuropathologica* 123:1-11
30. O'Meara ES, Kukull WA, Schellenberg GD, Bowen JD, McCormick WC, Teri L, Pfanschmidt M, Thompson JD and Larson EB (1997) Alzheimer's disease and history of blood transfusion by apolipoprotein-E genotype. *Neuroepidemiology* 16:86-93
31. Phan HTM, Bartz JC, Ayers J, Giasson BI, Schubert M, Rodenhausen KB, Kananizadeh N, Li Y and Bartelt-Hunt SL (2018) Adsorption and decontamination of alpha-synuclein from medically and environmentally-relevant surfaces. *Colloids and surfaces. B, Biointerfaces* 166:98-107

32. Ridley RM, Baker HF, Windle CP and Cummings RM (2006) Very long term studies of the seeding of beta-amyloidosis in primates. *J Neural Transm (Vienna)* 113:1243-1251
33. Ritchie DL, Adlard P, Peden AH, Lowrie S, Le Grice M, Burns K, Jackson RJ, Yull H, Keogh MJ, Wei W, Chinnery PF, Head MW and Ironside JW (2017) Amyloid-beta accumulation in the CNS in human growth hormone recipients in the UK. *Acta Neuropathol* 134:221-240
34. Rodrigues e Silva AM, Geldsetzer F, Holdorff B, Kielhorn FW, Balzer-Geldsetzer M, Oertel WH, Hurtig H and Dodel R (2010) Who was the man who discovered the "Lewy bodies"? *Movement disorders : official journal of the Movement Disorder Society* 25:1765-1773
35. Rudge P, Jaunmuktane Z, Adlard P, Bjurstrom N, Caine D, Lowe J, Norsworthy P, Hummerich H, Drueyeh R, Wadsworth JD, Brandner S, Hyare H, Mead S and Collinge J (2015) Iatrogenic CJD due to pituitary-derived growth hormone with genetically determined incubation times of up to 40 years. *Brain : a journal of neurology* 138:3386-3399
36. Rutala WA and Weber DJ (2001) Creutzfeldt-Jakob disease: recommendations for disinfection and sterilization. *Clinical infectious diseases : an official publication of the Infectious Diseases Society of America* 32:1348-1356
37. Rutala WA and Weber DJ (2010) Guideline for disinfection and sterilization of prion-contaminated medical instruments. *Infection control and hospital epidemiology* 31:107-117
38. Smethurst P, Newcombe J, Troakes C, Simone R, Chen YR, Patani R and Sidle K (2016) In vitro prion-like behaviour of TDP-43 in ALS. *Neurobiology of disease* 96:236-247
39. Thomzig A, Wagenfuhr K, Daus ML, Joncic M, Schulz-Schaeffer WJ, Thanheiser M, Mielke M and Beekes M (2014) Decontamination of medical devices from pathological amyloid-beta-, tau- and alpha-synuclein aggregates. *Acta Neuropathol Commun* 2:151
40. Weber DJ and Rutala WA (2002) Managing the risk of nosocomial transmission of prion diseases. *Current opinion in infectious diseases* 15:421-425