

## CONVENTIONAL DRILLS *VERSUS* PIEZOELECTRIC SURGERY PREPARATION FOR PLACEMENT OF FOUR IMMEDIATELY LOADED ZYGOMATIC ONCOLOGY IMPLANTS IN EDENTULOUS MAXILLAE: 3-YEAR RESULTS OF A WITHIN-PERSON RANDOMISED CONTROLLED TRIAL



### ROBERTO PISTILLI, MD

Resident, Oral and Maxillofacial Unit, San Camillo Hospital, Rome, Italy

### MARCO ESPOSITO, DDS, PhD

Freelance researcher and Associate Professor, Department of Biomaterials, The Sahlgrenska Academy at Göteborg University, Sweden

### CARLO BARAUSSE, DDS, PhD

Research Fellow, Unit of Odontostomatologic Surgery, Department of Biomedical and Neuromotor Sciences, University of Bologna, Italy

### ANDREA BALERCIA, DDS

Resident in Maxillofacial Surgery, Azienda ospedaliera ospedali riuniti di Ancona, Italy

### LORENZO BONIFAZI

Dentistry student, Unit of Odontostomatologic Surgery, Department of Biomedical and Neuromotor Sciences, University of Bologna, Italy

### JACOPO BUTI, DDS, PhD, MPerio RCSEd

Associate Professor, Unit of Periodontology, UCL Eastman Dental Institute, London, UK

### PIETRO FELICE, MD, DDS, PhD

Associate Professor, Unit of Odontostomatologic Surgery, Department of Biomedical and Neuromotor Sciences, University of Bologna, Italy

Correspondence to:

Marco Esposito

Casella Postale 34, 20862 Arcore (MB), Italy  
E-mail: espositomarco@hotmail.com

**PURPOSE.** A within-person randomised controlled trial to compare the outcome of site preparation for two zygomatic oncology implants per zygoma using conventional preparation with rotary drills or piezoelectric surgery with dedicated inserts.

**MATERIALS AND METHODS.** Twenty edentulous patients with severely atrophic maxillae and insufficient bone volumes for placing dental implants with less than 4 mm of bone height subantrally had their hemi-maxillae randomised according to a within-patient study design into implant site preparation with either conventional rotational drills or piezoelectric surgery. Two zygomatic oncology implants (unthreaded coronal portion) were placed in each hemi-maxilla. Implants that achieved an insertion torque of greater than 40 Ncm were immediately loaded with provisional screw-retained metal-reinforced acrylic prostheses. Outcome measures were: prosthesis and implant failures, any complications, time to place the implants, presence of post-operative haematoma, and patient preference, as assessed by blinded assessors when possible. All patients were followed up for 3 years after loading.

**RESULTS.** In two patients, drills had to be used in the piezoelectric surgery arm in order to prepare implant sites properly. One implant from the conventional drill group did not achieve an insertion torque of greater than 40 Ncm since the zygoma fractured. Three patients dropped out. Two distal oncology implants failed in the same patient (one per group), who was not prosthetically rehabilitated. Six patients experienced at least one complication at drilled sites and five at piezoelectric surgery sites (three patients had bilateral complications), the difference not being statistically significant (odds ratio = 1.5;  $P$  [McNemar's test] = 1.0; 95% CI of odds ratio: 0.25 to 8.98). Implant placement with conventional drills took on average 14.35±1.76 minutes vs. 23.50±2.26 minutes with piezoelectric surgery, the implant placement time being significantly shorter with conventional drilling (difference = 9.15±1.69 minutes; 95%CI: 8.36 to 9.94 minutes;  $P$  = 0.000). Post-operative haematomas were larger at drilled sites in 11 patients and similar at both sides in nine patients (chi-square = 20.4;  $df$  = 3;  $P$  = 0.0001), and 16 patients found both techniques equally acceptable while four preferred piezoelectric surgery (chi-square = 34.4;  $df$  = 3;  $P$  < 0.0001).

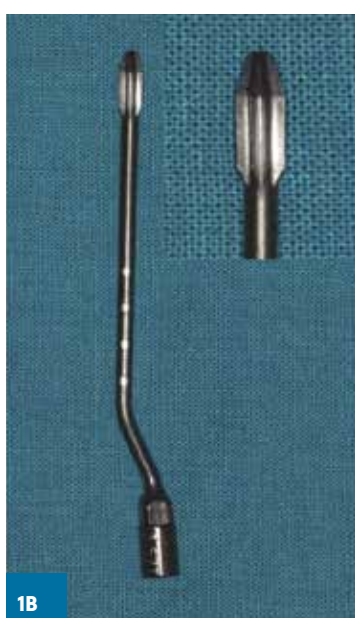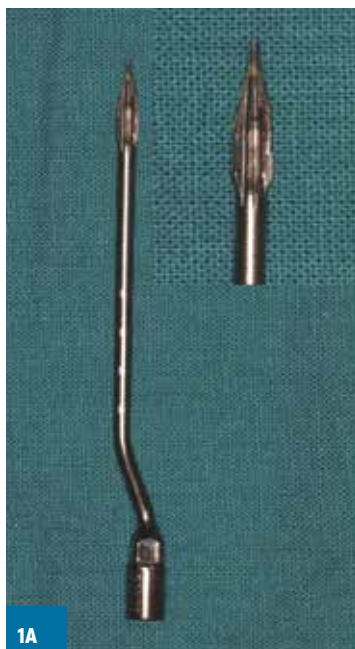**CONCLUSIONS.** Although these results may be system-dependent, and therefore cannot be generalised to other zygomatic systems with confidence, both drilling techniques achieved similar clinical outcomes. However, conventional drilling required 9 minutes less and could be used in all instances, though it was more aggressive.

**CONFLICT OF INTEREST STATEMENT.** This study was partially supported by Southern Implants (Irene, South Africa), the manufacturer of the zygomatic implants and the conventional drills evaluated in this study. However, all data is the property of the authors and by no means did the manufacturer interfere with the conduct of the trial or the publication of its results. Dr. Felice and Dr. Pistilli developed the piezoelectric surgery zygomatic insert used in the present study.

## INTRODUCTION

Zygomatic implants are an alternative to conventional bone augmentation and implant rehabilitation in severely atrophic maxillae<sup>1</sup>. Zygomatic implants are long implants which are placed in the zygomatic bone, passing through the maxillary sinus depending on the individual local anatomical conditions<sup>2</sup>. Oncology implants are a variation of zygomatic implants characterised by an unthreaded coronal portion of various lengths to be used in various maxillofacial reconstructions procedures. Two zygomatic implants can be placed each zygoma, and can be successfully immediately loaded if inserted with a sufficient torque<sup>3</sup>. This is a major potential advantage over conventional bone augmentation procedures used to rehabilitate severely atrophic maxillae, since patients can be functionally rehabilitated in a single day instead of undergoing two to three surgical procedures over the course of several months<sup>4,5</sup>. However, despite zygomatic implants having been in use for more than 20 years<sup>1,6-9</sup>, only one comparative trial evaluating the actual efficacy and potential risks in comparisons to conventional augmentation procedures has thus far been published<sup>10-12</sup>. While running that trial, which compared four immediately loaded zygomatic implants with conventional implants placed in bone augmented with bone substitutes<sup>10,11</sup>, it became apparent that one of the problems with the drilling procedures for zygomatic implants was the difficulty in controlling such long drills, which were prone to wobbling. The authors felt that drilling precision could be improved, however, and, as suggested in a previous study<sup>13</sup>, developed for this purpose two specific tips to be used with a piezoelectric surgery device (**FIGS. 1A, B**). Two different piezoelectric inserts (Zygoma kit, Esacrom, Imola, Italy) with double internal irrigation were designed; each featured an angled part and a straight part, and could be manufactured at total lengths of 74 or 94 mm, but had different shaped tips: conical (2.9 mm diameter; **FIG. 1A**) with micro-sharp blades, or diamond-shape (3.5 mm diameter; **FIG. 1B**) with blades. These zygomatic inserts are manufactured from medical stainless steel with T-black finishing. They are given a double-coated nanostructure surface treatment to reduce tissue heating and provide greater resistance to wear and corrosion. Both inserts have depth indicators at 30, 35, 40, 45, and 50 mm from the tip.

We present here the 3-year results of a study designed to test the performance of these implants. Specifically, this randomised controlled trial (RCT) of within-patient design was implemented to compare the respective clinical outcomes of the new purpose-designed piezoelectric surgery inserts vs. conventional rotary drilling (**FIG. 2**) in site preparation for placing two zygomatic oncology implants per zygoma. This report presents clinical outcomes up to 3 years after loading, following the previous publication of the preliminary results 1 year after loading<sup>14</sup>. It is planned to report data up to 5 years after loading when they become available. The present article is reported according to the CONSORT statement for improving the quality of reports (<http://www.consort-statement.org/>), and its extension checklist for reporting within-person randomised trials (<http://www.consort-statement.org/extensions/overview/withinperson>).



**FIGS. 1A, B:** Inserts for piezoelectric surgery used in this study: the conical insert with micro-sharp blades (A); the diamond-shaped insert (B).

## MATERIALS AND METHODS

### Trial design

This was a single-centre RCT of within-patient design with balanced randomisation and blind assessment. Two different operators treated an equal number of patients each. The hemi-maxilla of each patient was randomly allocated to have two adjacent zygomatic oncology implant sites prepared either with two piezoelectric surgery inserts (piezo group; **FIGS. 1A, B**), or conventional drills (drill group; **FIGS. 2A-D**) provided by the zygomatic implant manufacturer (Southern Implants, Irene, South Africa) (**FIGS. 3A-E**). The other procedure was to be used for implant site preparation on the opposite side.

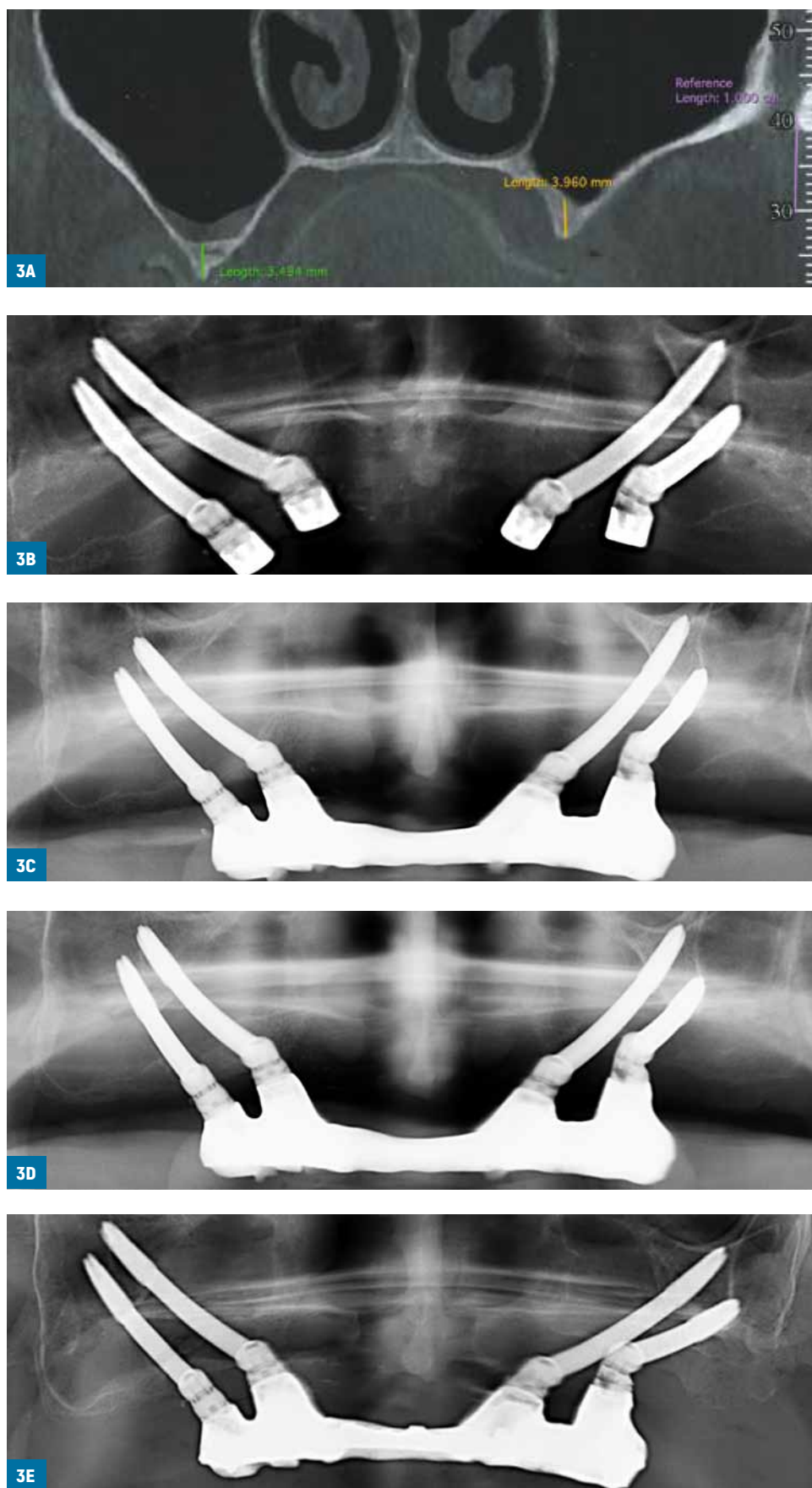
### Eligibility criteria for participants

Any patient with a severely atrophic edentulous maxilla not allowing the placement of dental implants and having a residual bone height under the maxillary sinus of less than 4 mm as measured on cone-beam computed tomography (CBCT) or conventional computed tomography (CT) scans requesting a fixed prosthesis who was 18 or older and able to understand and sign an informed consent form was eligible for inclusion in this trial. Coronal slices were added to conventional CBCT/CT scans to allow assessment of the status of the osteomeatal complex and sinus epithelium. Only patients with healthy sinuses were asked to join the trial. Patients were not admitted to the study if any of the following exclusion criteria applied:

- General contraindications to implant surgery;
- Irradiation to the head and neck region greater than 70 Gray;
- Immunosuppression or immunocompromised state;
- Previous or ongoing treatment with intravenous aminobisphosphonates;
- Untreated periodontal disease;
- Poor oral hygiene and motivation;
- Uncontrolled diabetes;
- Pregnancy or lactation;
- Substance abuse;



**FIGS. 2A-D:** Set of drills used in this study in order of sequence of use: zygomatic round ball for initial preparation (A); 2.9 mm diameter pilot drill (B); 3.4 mm diameter countersink drill (C); 3.4 mm diameter drill (D).



**FIGS. 3A-E:** Preoperative CBCT scan of one of the patients included in the study showing the submental bone height at right and left sides, respectively lower than 4 mm (A); immediate post-operative panoramic radiograph (the right side was randomly allocated to the drilling implant site preparation and the left to the piezo-surgery) (B); panoramic radiographs just after immediate loading (C), at 1 year (D) and 3 years (E) post-loading.



- Psychiatric problems;
- Lack of opposing occluding dentition/prosthesis;
- Restricted mouth opening (less than 3.5 cm inter-arch anteriorly);
- Acute or chronic infection/inflammation in the area intended for implant placement;
- Inability to commit to a 5-year follow-up;
- Participation in other studies, if the present protocol could not be properly adhered to;
- Referral for implant placement alone.

Patients were categorised into three groups according to their declaration: non-smokers, moderate smokers (up to 10 cigarettes per day) or heavy smokers (more than 10 cigarettes per day).

### Setting and locations

Patients were treated in the Ancona University Hospital, Italy, by two different operators (Dr. Pietro Felice and Dr. Roberto Pistilli, who treated 10 patients each following similar procedures.

### Surgical procedures

All patients received thorough explanation, understood the nature of the study, and signed an informed written consent form prior enrolment in the trial. Stereolithographic models of their maxillae were created from CBCT/CT scans to better plan the implant insertion angles. Anatomical landmarks to be avoided, such as the infraorbital foramina, and the correct implant insertion axes were marked with a pencil. Diagnostic wax-ups and surgical guides were prepared to help clinicians select the most appropriate position and angle of each implant. Efforts were made to plan implant exits at the crestal level rather than palatally.

Patients rinsed with 0.2% chlorhexidine mouthwash for one minute prior to implant placement, which was carried out under general anaesthesia and prophylactic intravenous antibiotics (1 g of amoxicillin plus clavulanic acid, or, if allergic to penicillin, clindamycin 300 mg). Articaine with epinephrine 1:100,000 was injected locally to reduce bleeding and increasing visibility. The right side of the patient was treated first. After crestal and release incisions, a mucoperiosteal flap was raised, exposing the maxilla in order to allow identification of the infraorbital foramen and the incisura between the zygomatic arch and the lateral and medial surfaces of the frontal process of the zygomatic bone. If necessary, a 10 x 5 mm or wider window, extending from the sinus floor to the base of the zygomatic bone, was opened in the lateral wall of the maxillary sinus, close to the infra-zygomatic crest. The sinus lining was carefully lifted and an absorbable haemostatic gelatine sponge (Spongostan Special, Ethicon, Johnson & Johnson, New Brunswick, NJ, USA) was used to protect the sinus epithelium after its displacement. This sponge, of porcine origin, is off-white and porous in appearance; it is sterile, water-insoluble, malleable, and intended for application to a bleeding surface. After its application, the sequentially numbered envelope corresponding to the recruitment number of the patient was opened, thereby randomly allocating the right side of the patient to either conventional rotary drill or piezoelectric surgery preparation. The other procedure was used for implant site preparation in the left side. Each patient received four zygomatic oncology implants only, two per side. Those sites randomised to rotary drills were prepared following the instructions provided by the zygomatic implant manufacturer (Southern Implants). Specifically, the zygomatic round ball was used for the initial preparation, followed by the 2.9 mm diameter pilot drill to full depth (penetrating the outer cortical layer of the zygomatic bone at the zygomatic malar face). The length of the implant used was determined using a depth in-

dicator. Next, the 3.4 mm diameter countersink drill was used, followed by a 3.4 mm diameter bit to full depth (**FIG. 2**).

The two sites randomly allocated to piezoelectric surgery preparation were initially prepared with the conical-shape tip insert (**FIG. 1A**), which was inserted, when possible, in the residual alveolar bone, exiting at the base of the sinus window; in this way, implants had an intraosseous path at the level of the atrophic crest to provide better primary stability. Subsequently, the tip of this insert, due to its length, was passed through the maxillary sinus, entering the midportion of the zygomatic body and exiting from the zygomatic malar face. The diamond-shape tip insert (**FIG. 1B**) was then used to widen the implant site to the desired diameter (3.5 mm) in relation to the implant diameter (4.3 mm). A depth indicator was inserted into the site to determine the correct length of the zygomatic implants.

The zygomatic implants used were of the oncology type, characterised by lack of threads in the coronal portion of 7.5, 12.5, 17.5, 22.5, 27.5, 30.0, 32.5 and 35.0 mm, depending on the implant length, and 55° angled neck with external hexagonal connection. The following implant lengths were used: 27.5, 32.5, 37.5, 42.5, 47.5, 50.0, 52.5 and 55.0 mm, all having a diameter of 4.3 mm.

It was attempted to place the largest portion of the implants outside the sinus. Surgical templates were used to position the implant exit into the oral cavity at a crestal level and not on the palate. A retractor was placed at the incisura between the zygomatic arch and the lateral and medial surfaces of the frontal process of the zygomatic bone to facilitate correct three-dimensional orientation of the implant. Abundant irrigation was provided during preparation of the implant sites. After the first implant was placed, the same procedure was repeated for placement of the second implant. It was attempted to position the implant apices at least 3 mm apart, and to place implants with an insertion torque of greater than 40 Ncm in order to be able to load them immediately. Implants inserted with less than 40 Ncm were submerged for 5 months. Bicortical engagement was always obtained, meaning that the tip of the implant protruded for 1 to 2 mm on the other side of the zygoma. The Bichat fat pads were exposed, and gently shifted medially to cover the exposed implant portions. Flaps were then sutured around the impression copings with simple interrupted 4-0 resorbable sutures (Vicryl, Ethicon FS-2, Johnson & Johnson, New Brunswick, NJ, USA).

### Prosthetic procedures

Prosthetic procedures were initiated immediately after flap suturing. Panoramic radiographs were taken to verify proper seating of all the impression copings. Self-curing acrylic resin (Pattern Resin, GC, Alsip, IL, USA) was positioned on a brass wire to further stabilise the impression copings in position. A pick-up impression was taken using a polyether material (Impregum, 3M ESPE, Milan, Italy), and when possible, the patient's denture, with holes in the resin palate, was used as a customised tray. Healing caps were positioned. A provisional screw-retained metal-reinforced acrylic cross-arch prosthesis was fitted within 1 week.

The following post-surgical instructions were given:

- Augmentin 1 g (or clindamycin 300 mg) to be taken three times a day for one week;
- Ibuprofen 600 mg prescribed to be taken four times a day during meals for one week, but patients were instructed not to take it in the absence of pain;
- Xylometazolin ehydrochloride (nasal decongestant) 1 mg five drops to be taken three times a day for two weeks;
- A soft diet recommended for two weeks;
- Gentle 0.2% chlorhexidine rinses twice a day for two weeks.

Patients were recalled and checked after 3 days (when haematoma and patient preference outcomes were also assessed), 10 days (suture removal and prosthesis check-up), and one month.

Five months after delivery, the provisional prostheses were to be removed, and implant stability checked by tightening the abutment screws with 15 Ncm torque using a manual torque wrench; a definitive impression was also to be taken at abutment level using a rigid impression material and impression copings with an open tray. Within one month, definitive screw-retained metal-resin/composite cross-arch prostheses were to be fitted. However, due to financial issues not even one definitive prosthesis was delivered before the second year in function.

Patients were enrolled in an oral hygiene programme with recall visits every 6 months. Operators were free to increase maintenance frequency (every 3-4 months) based on individual needs. Dental occlusion was evaluated at each maintenance visit. Follow-ups were conducted by an independent blind outcome assessor (initially by Dr. Tuci, then replaced by Dr. Barausse up to 1 year after loading, and thereafter by Dr. Balercia and Dr. Cassoni).

### Outcome measures

Outcome measures were the following.

- Prosthesis failure: defined as no prosthesis delivery or prosthesis replacement due to implant failure or any other reason.
- Implant failure: defined as an implant displaying rotational mobility, any infection dictating implant removal, and/or any mechanical complication rendering the implant unusable (e.g., implant fracture or deformation of the connecting platform). Implant stability assessments were to be performed, with the prostheses removed, at delivery of the definitive prosthesis (this procedure actually did not take place as originally planned, since no definitive prosthesis was delivered) and at 1 and 3 years after loading by tightening the abutment screws with 15 Ncm torque. Rotating implants were considered failures and were to be removed. It was possible that a few zygomatic implants displayed a slight horizontal mobility due to their lengths, and possible lack of alveolar bone at their exits, this was recorded, but implants were considered successful if they did not rotate.
- Any biological or prosthetic complications: these were divided into those likely caused by the implant site preparation and those likely independent of implant site preparation.
- Time for site preparation: the time necessary to prepare and fully insert both implants at each site was recorded, starting from the first drill to complete implant insertion.
- Presence of haematoma: assessed at day 3 post-surgery on frontal pictures of the patient's face by the blind outcome assessor. The presence and extension of the haematoma at each site of the face was evaluated to see if one of the two sites had a larger haematoma. Haematomas were scored in the following manner: 1) larger haematoma at the rotary drill treated side; 2) larger haematoma at the piezoelectric surgery treated side; 3) no haematoma at either side; 4) both haematomas looking similar in extension.
- Patient preference: evaluated at day 3 post-surgery by the blind outcome assessor, who asked patients if they preferred one of the two sides and for what reason. The following question was asked: "Which side of the maxilla did you prefer?" Patients pointed at the preferred site and the outcome assessor recorded the patient's choice, which could have been: 1) the side prepared with piezoelectric surgery; 2) the side prepared with traditional drills; 3) none, both treatments were equally good; 4) none, both treatments were equally bad. Patients' explanations/comments on the procedures were recorded.

### **Sample size, random sequence, allocation concealment and blinding**

No sample size was calculated. A blocked randomisation was applied to include 10 hemi-maxilla for each operator in each treatment group, and two computer-generated restricted randomisation lists were created. Only one of the investigators (Dr. Esposito), not involved in the selection and treatment of the patients, was aware of the randomisation sequence and could have access to the randomisation lists, which were stored on his password-protected laptop. The randomisation codes were enclosed in sequentially numbered, identical, opaque, sealed envelopes. Envelopes were opened sequentially after the bony window at the right maxillary sinus, thereby concealing treatment allocation from the investigators in charge of enrolling and treating the patients.

One blinded dentist (Dr. Tuci, replaced at the end of the treatment phase by Dr. Barausse), measured implantation time, implant stability and patient preference up to 1 year after loading. Thereafter, Dr. Andrea Balercia and Roberto Cassoni evaluated the stability of single implants and complications in blinded mode. Dr. Barausse made all haematoma assessments on photographs, without knowing group allocation.

### **Statistical methods**

All data analysis was carried out according to a pre-established analysis plan. A dentist with expertise in statistics (Dr. Buti) analysed the data without knowing the group codes. The patient was the statistical unit of the analyses. An intention-to-treat analysis was carried out, but an as-treated analysis (carried out removing the data of the two patients who had both sites treated with conventional drills) was also done for site preparation time, haematoma presence, and patient preference. McNemar's test and Fisher's exact test were used to investigate the differences in the proportions of patients with prosthesis failures, implant failures and complications (dichotomous outcomes), respectively, between the implant site preparation methods and between clinicians. Differences in the time taken to prepare the implant site (continuous outcome) were investigated at the patient level through Wilcoxon signed-rank tests (comparisons between implant site preparation methods) and Mann-Whitney U tests (comparisons between the clinicians). Chi-squared goodness-of-fit testing was used to investigate the distribution of patients' implant preparation site preference and haematoma (hypothesising the expected proportion of cases in each group to be equal). All statistical comparisons were conducted at the 0.05 level of significance.

## **RESULTS**

Twenty-five patients were screened for eligibility, but five patients were not enrolled in the trial, as three patients had more than 4 mm of bone subantrally and two had maxillary sinus pathologies. Twenty patients were considered eligible and were consecutively enrolled and treated in the trial. All patients were treated according to the allocated interventions, with the exception of two patients who had both sites prepared using conventional drills because the first piezosurgery insert was unable to penetrate the bone (in one case the preparation was only completed with drills while in the second case it was completed with piezoelectric surgery).

Three patients dropped out:

- One stopped attending recalls and is no longer reachable; last seen at 1 year after loading;
- One died of prostate carcinoma; last seen at 1 year and 3 months after loading;
- One stopped attending recalls and is no longer reachable; last seen at 1 year and 6 months after loading.



Data pertaining to all remaining patients was evaluated in the statistical analyses. The following additional protocol deviations occurred:

- no patient received the definitive prosthesis during the first year in function because of financial problems. However, three patients were rehabilitated with definitive metal-composite screw-retained prostheses between 2 years to 2 years and 5 months after loading;
- two patients had both sites prepared with conventional drills since the piezoelectric surgery insert was unable to perforate the bone;
- one of the 47.5 mm long implants from the piezo group was too long, so 2.5 mm was cut from its apex using a laboratory disk saw at surgery.

Patients received zygomatic implants from May to December 2015. The follow-up of all patients was 3 years after prosthetic loading.

There were 11 females and nine males. The mean age at implantation was 68 years (range 62 to 75). Fourteen patients were non-smokers and six were moderate smokers. The main baseline patient characteristics are presented in **TABLE 1**. There were no apparent systematic baseline imbalances between the two groups. Only one implant from the conventional drill group did not achieve an insertion torque greater than 40 Ncm, because it fractured the zygoma and was left unloaded.

### **Prosthesis failures**

One provisional prosthesis was lost because both distal zygomatic implants failed 15 days after their placement; two 6x4 mm implants were placed at the lateral incisor position but no new implant-supported prosthesis was delivered since the patient was diagnosed with prostate cancer in the meantime, and unfortunately died a few months later.

### **Implant failures**

Two distal zygomatic implants (one per group) failed in the same patient 2 weeks after their placement. The patient had swelling, pain and signs of infection at both implant sites and both

**TABLE 1** INTERVENTION CHARACTERISTICS (20 PATIENTS)

	Rotary drill group	Piezoelectric surgery group
Total number of inserted implants	40	40*
Number of 27.5 mm-long implants	1	0
Number of 32.5 mm-long implants	3	2
Number of 37.5 mm-long implants	6	7
Number of 42.5 mm-long implants	7	8
Number of 47.5 mm-long implants	16	12
Number of 50.0 mm-long implants	4	7
Number of 52.5 mm-long implants	3	1
Number of 55.0 mm-long implants	0	3
Implants inserted with a torque of greater than 40 Ncm	39	40
Implants inserted with a torque of less than 40 Ncm	1	0

\*Four implants in two patients were inserted after drill preparation since the piezoelectric surgery insert was unable to perforate the bone.

implants were mobile and were therefore removed. Two 6x4 mm Southern implants were placed in positions 12 and 22. The patient also complained of discomfort at the two mesial zygomatic implants, which were, however, stable. Antibiotic therapy (amoxicillin plus clavulanic acid 1 g three times a day for 10 days) was prescribed. During the healing period, the patient was diagnosed with prostate carcinoma; the oral rehabilitative procedures were suspended, and the patient unfortunately died a few months later.

### **Complications**

Six patients were affected by eight complications at drilled sites and five patients at piezoelectric surgery sites (three patients had bilateral complications), the difference being not statistically significant (odds ratio = 1.5; P [McNemar's test = 1.0]; 95% CI of odds ratio: 0.25 to 8.98).

The complications at the drilled sites were the following.

- Two patients had burns to the lower lip caused by the drills; both healed spontaneously. One of these patients complained about discomfort below the right eye, spreading toward the maxillary sinus, one year and 4 months after loading. CBCT showed radiopacity of the right sinus (sinusitis). Moxifloxacin 400 mg was prescribed once a day for 7 days, and a nebuliser (2 cc physiological solution, 1 bottle of beclomethasone, half a bottle of lincomycin 600 mg, and 4 drops of Argotone, a nasal decongestant) twice a day for 20 days; 3 squeezes of Nasonex (a steroid) 50 mcg nasal spray were prescribed for the right naris once a day for 20 days. After 20 days, the symptoms were reduced, and the last cycle of aerosol and Nasonex was prescribed with the same posology for a further 20 days until the issue resolved. Two years and 7 months after loading, resin tooth #15 was damaged and repaired at the dental chair, and it was noticed that its prosthetic screw was fractured. This was removed with the help of ultrasound and replaced.
- One patient had a fracture line at the zygoma at placement of implant in position 15. The desired torque could not be achieved, and the implant was submerged and was still unloaded at the 1-year follow-up, thereafter the patient dropped-out.
- One patient had signs of infection (pain and swelling) at both distal implants, which were mobile 15 days after their placement. Both implants were removed as previously described.
- Two patients had a burning sensation and discomfort at implants in position 26 at 6 months after loading, and the mucosa was inflamed and bleeding (mucositis). The prostheses were removed and cleaned, together with the implant abutments. Patients were instructed to use chlorhexidine gel instead of toothpaste three times a day for 3 weeks, during which the issue resolved.

Complications at the piezoelectric surgery sites were the following.

- One patient had signs of infection (pain and swelling) at both distal implants, which were mobile 15 days after their placement. Both implants were removed as previously described.
- One patient showed an implant fenestration at an implant in position 25 one month after its placement. The fenestration is still present, stable and inflammation-free. No treatment was attempted.
- One patient reported discomfort and feeling the implant tip, extraorally, at the left zygoma level 1 month and half after loading. She also complained that she could not sleep on that side and that a solution had to be found to this problem. The tip of implant 25 could be felt extraorally, but all implants were stable and symptom-free. It was decided to cut off the implant tip by opening a flap under the lower eyelid, as a blepharoplasty, to examine the area of interest. The implant apex extruded outside the zygoma by four threads. The protruding portion of the implant was removed with a diamond ball bur, and the area

was then cleaned with hydroxide peroxide to remove the residual titanium powder. The patient healed fine and experienced no more discomfort.

- One patient showed peri-implant mucositis around #25 at the check-up 2 years after loading. The prosthesis was removed and accurately cleaned, and the patient was prescribed chlorhexidine gel as a toothpaste substitute three times per day for 3 weeks. After 21 days the problem had resolved.
- One patient presented with a fractured prosthesis screw in position #25 at 2-year check-up. The screw was removed with the aid of ultrasound and replaced. Occlusal contacts were balanced because they were concentrated in the anterior portion of the prosthesis. The same patient had also had, as previously described, a lip burn on the other side of the mouth.

### **Mean implant insertion time**

On average it took  $23.50 \pm 2.26$  minutes to prepare and place implants at piezosurgical sites and  $14.35 \pm 1.76$  minutes at conventionally drilled sites, the difference being statistically significant (difference =  $9.15 \pm 1.69$  minutes; 95%CI: 8.36 to 9.94 minutes;  $P < 0.0001$ ). After removing the two patients who had both sites treated or partially treated with drills from the analysis, the difference was still significant (difference =  $9.11 \pm 1.78$  minutes; 95%CI: 8.23 to 10.00 minutes;  $P < 0.0001$ ).

### **Haematoma at day 3**

Post-operative haematomas were larger at drilled sites in 11 patients and similar on both sides in nine patients. Significantly more haematomas occurred at conventionally drilled sites (chi-square = 20.4; df = 3;  $P = 0.0001$ ). After removing the two patients who had both sites treated or partially treated with drills from the analysis, the difference was still significant (chi-square = 19.78; df = 3;  $P = 0.0002$ ).

### **Patient preference at day 3**

Sixteen patients found both techniques equally acceptable while four patients preferred piezoelectric surgery, a difference that was statistically different (chi-square = 34.4; df = 3;  $P < 0.0001$ ), even after removing the two patients who had both sites treated or partially treated with drills from the analysis (chi-square = 39.78; df = 3;  $P < 0.0001$ ).

A comparison between the two clinicians' clinical outcomes is presented in **TABLE 2**. There were no apparent differences between the two operators.

## **DISCUSSION**

This trial was designed to determine whether it would be more convenient to use piezoelectric surgery or conventional rotary drills to prepare sites for zygomatic implants. A split-mouth design was preferred to minimise anatomical variations and other patient-related factors that could potentially influence the results. Both procedures yielded similar outcomes at 3 years post-loading, but, despite the limited sample size, some differences were noted. In particular, the time necessary to place both implants was 9 minutes shorter using conventional drills, and in two patients drills also had to be used on the piezoelectric surgery side, since the piezoelectric surgery inserts were unable to penetrate the maxillary bone, even at maximum power. On the other hand, larger haematomas were seen at the drilled side, suggesting that conventional drills are more aggressive. Anecdotally speaking, the operators also felt that it was easier to initiate the preparation of the sites with piezosurgery, because it was easier to keep the insert tip in the exact position they wanted; in contrast, drill tips tended to slip away from the planned drilling point, rendering some adjustment necessary during the first phase of the site preparation.

**TABLE 2** COMPARISON OF THE CLINICAL OUTCOMES OF THE TWO OPERATORS. EACH OPERATOR TREATED 10 PATIENTS

	Dr. Felice	Dr. Pistilli	P = value
Patients with failed prostheses	0	1	1.000 <sup>§</sup>
Patients with failed implants	0	1	1.000 <sup>§</sup>
Patients with complications	6	2	0.0698 <sup>§</sup>
Implant insertion time in minutes (mean±SD)	19.45±2.39	18.40±0.91	0.248 <sup>†</sup>
Patients with implants not loaded immediately	0	1	1.000 <sup>§</sup>
Patients with more haematoma at drilled sites	5	6	1.000 <sup>§</sup>
Patients preferring piezoelectric surgery	3	1	0.582 <sup>§</sup>

SD: standard deviation; <sup>†</sup> Two-tailed Fisher's exact test; <sup>‡</sup> Mann-Whitney U Test

It was decided to use oncology implants rather than conventional fully threaded zygomatic implants in this study during the design phase; it was felt that having an unthreaded coronal portion in the area more likely to be exposed to bacterial plaque in the oral cavity over time would facilitate oral hygiene procedures over the exposed implant surface in the event of complications, such as tissue fenestrations, around the implants. In fact, one case of implant exposure occurred, but the area remained free of plaque and inflammation, suggesting that it was a sound decision to use implants with an unthreaded coronal portion.

Having to express a preference, the authors would prefer to use rotary drills; however, this pilot trial has yielded suggestions for modifications and improvements to the equipment we used, which may be of interest the manufacturers. In the opinion of the authors, the rotary drills would benefit from either an additional bit with a diameter greater than 3.4 mm or a tapping drill for placing 4.3 mm diameter implants; these would minimise the risk of zygoma fracture, especially in very dense bone. While we agree that implant sites should be under-prepared to achieve high insertion torques in order to allow immediate loading, at the same time it is essential to minimise the risk of zygoma fracture when delivering high torques at implant insertion. To facilitate the placement of pairs of implants in small zygomas, we also suggest that zygomatic oncology implants with smaller diameters be manufactured (if the implant resistance at fracture is not be compromised). Interestingly, after the publication of the first report<sup>14</sup> from this trial, the implant manufacturer took into consideration our suggestions and produced variants of zygomatic implants with apical diameters of 3.4 mm to facilitate their placement in small zygomas, and allowing the use of the 3.4 mm diameter bit in the presence of hard bone to minimise the risk of accidental zygoma fractures. Regarding the piezoelectric surgery options, both speed and penetrating capacity into the bone are an issue which need to be improved to make piezoelectric surgery a really competitive alternative to rotary drills. Finally, as one of our cases illustrates, it may be uncomfortable to have the implant tip protruding a few mm outside the zygoma, so a wide range of zygomatic implants of varying lengths is a necessity to prevent interventions to shorten implants, as we had to resort to in another patient.

It is interesting to observe that not one single patient had been rehabilitated with a definitive prosthesis at two years after loading, while at protocol stage it was planned and agreed to deliver definitive prostheses at 6 months after loading. The explanation is that while patients received free implants and provisional prostheses, they had to pay for their own definitive prostheses. It is likely that the patients were pleased with their provisional prostheses or had financial issues and so decided to postpone fitting of their definitive prosthesis. Indeed, the

provisional prostheses they received were of good quality and metal reinforced. At the time of writing this paper, only three patients had had their permanent prosthesis fitted; however, no major prosthetic complications have occurred.

It is not possible to compare the present results with those of similar RCTs, since none have been published.

The main limitation of the present investigation was the small number of patients enrolled. Nonetheless, the sample size was sufficient to provide some useful indications, and generate hypotheses for future investigations.

Both implant preparation techniques were tested under real clinical conditions, and patient inclusion criteria were broad, meaning that the results of the present trial can be generalised to a larger population with similar characteristics, bearing in mind, however, that the placement of zygomatic implants is a complex procedure requiring skilled and experienced operators, since potentially severe complication may occur.

## CONCLUSIONS

Although our results may be system-dependent, and cannot, therefore, be generalised to other zygomatic systems with confidence, both drilling techniques achieved similar clinical outcomes. However, conventional drilling required 9 minutes less and could be used in all instances, even though it was more aggressive.

## REFERENCES

1. Brånemark PI, Gröndahl K, Öhrnell LO, Nilsson P, Petruson B, Svensson B, Engstrand P, Nannmark U. Zygoma fixture in the management of advanced atrophy of the maxilla: technique and long-term results. *Scandinavian Journal of Plastic and Reconstructive Surgery* 2004;38:70-85.
2. Aparício C. A proposed classification for zygomatic implant patient based on the zygoma anatomy guided approach (ZAGA): a cross-sectional survey. *European Journal of Oral Implantology* 2011;4:269-75.
3. Davó R, Pons O. Prostheses supported by four immediately loaded zygomatic implants: a 3-year prospective study. *European Journal of Oral Implantology* 2013;6:263-9.
4. Esposito M, Felice P, Worthington HV. Interventions for replacing missing teeth: augmentation procedures of the maxillary sinus. *Cochrane Database of Systematic Reviews* 2014 May 13;(5) CD008397.
5. Esposito M, Barausse C, Pistilli R, Sammartino G, Grandi G, Felice P. Short implants versus bone augmentation for placing longer implants in atrophic maxillae: one-year post-loading results of a pilot randomised controlled trial. *European Journal of Oral Implantology* 2015;8:257-68.
6. Stevenson AR, Austin BW. Zygomatic fixtures - The Sydney experience. *Annales of the Royal Australasian College of Dental Surgeons* 2000;15:337-9.
7. Triplett RG, Schow SR, Laskin DM. Oral and maxillofacial surgery advances in implant dentistry. *The International Journal of Oral and Maxillofacial Implants* 2000;15:47-55.
8. Malevez C, Abarca M, Durdu F, Daelemans P. Clinical outcome of 103 consecutive zygomatic implants: a 6-48 months follow-up study. *Clinical Oral Implants Research* 2004;15:18-22.
9. Hirsch JM, Öhrnell LO, Henry PJ, Andreasson L, Brånemark PI, Chiapasco M, Gynther G, Finne K, Higuchi KW, Isaksson S, Kahnberg KE, Malevez C, Neukam FW, Sevetz E, Urgell JP, Widmark G, Bolind P. A clinical evaluation of the Zygoma fixture: one year of follow-up at 16 clinics. *Journal of Oral and Maxillofacial Surgery* 2004;62:22-9.
10. Davó R, Felice P, Pistilli R, Barausse C, Marti-Pages C, Ferrer-Fuertes A, Ippolito DR, Esposito M. Immediately loaded zygomatic implants vs conventional dental implants in augmented atrophic maxillae: 1-year post-loading results from a multicentre randomised controlled trial. *European Journal of Oral Implantology* 2018;11:145-61.
11. Esposito M, Davó R, Marti-Pages C, Ferrer-Fuertes A, Barausse C, Pistilli R, Ippolito DR, Felice P. Immediately loaded zygomatic implants vs conventional dental implants in augmented atrophic maxillae: 4 months post-loading results from a multicentre randomised controlled trial. *European Journal of Oral Implantology* 2018;11:11-28.
12. Esposito M, Worthington HV. Interventions for replacing missing teeth: dental implants in zygomatic bone for the rehabilitation of the severely deficient edentulous maxilla. *Cochrane Database of Systematic Reviews* 2013 Sept.
13. Mozzati M, Mortellaro C, Arata V, Gallesio G, Prevgliano V. Rehabilitation with 4 zygomatic implants with a new surgical protocol using ultrasonic technique. *The Journal of Craniofacial Surgery* 2015;26:722-8.
14. Esposito M, Barausse C, Balercia A, Pistilli R, Ippolito DR, Felice P. Conventional drills vs piezoelectric surgery preparation for placement of four immediately loaded zygomatic oncology implants in edentulous maxillae: results from 1-year split-mouth randomised controlled trial. *European Journal of Oral Implantology* 2017;10:147-58.