

*MiniDSAEK for Macroperforation*

Formatted: Font: Italic

**Mini-DSAEK for Macro Corneal Perforations,**

Formatted: Font: Bold

Alfonso Vasquez-Perez, MD, FRCOphth, FEBOS-CR,\* Nizar Din, MBBS, BSc,  
FRCOphth,\* Maria Phylactou, MD, MSc, FEBO,\* Jaime Kriman Nunez, MD,\* and  
Bruce Allan, MD, FRSC, FRCOphth\*† **Mini-DSAEK for macro corneal**

Formatted: Font: (Default) Arial, 12 pt, Bold

Formatted: Font: Bold

Formatted: Space Before: Auto, After: Auto, Line spacing: single

Formatted: Font: (Default) Arial

**perforations.**

\*Cornea & External Diseases Department, Moorfields Eye Hospital,  
NHS Foundation Trust, London, United Kingdom; †Department of  
Health's NIHR Biomedical Research Centre for Ophthalmology,  
Moorfields Eye Hospital and UCL Institute of Ophthalmology,  
London, United Kingdom.

Formatted: Font: (Default) Arial, 12 pt, Not Italic

Formatted: Line spacing: Double

Formatted: Font: Not Italic

The authors have no conflicts of interest to disclose.

Formatted: Font: (Default) Arial, 12 pt, Not Italic

Formatted: Line spacing: Double

Formatted: Font: Not Italic

Bruce Allan receives partial salary support for research from the Department of  
Health's NIHR Biomedical Research Centre for Ophthalmology at Moorfields Eye  
Hospital and UCL Institute of Ophthalmology. The views expressed in the  
publication are those of the authors and not necessarily those of the Department of  
Health.

Formatted: Font: Not Italic

Formatted: Adjust space between Latin and Asian text, Adjust space between Asian text and numbers

Formatted: Font: (Default) Arial, 12 pt, Not Italic

Formatted: Line spacing: Double

Formatted: Font: Not Italic

Formatted: Font: (Default) Arial, 12 pt, Not Italic

Formatted: Font: Not Italic

Formatted: Font: (Default) Arial, 12 pt, Not Italic

Formatted: Font: Not Italic

Formatted: Font: (Default) Arial, 12 pt, Not Italic

Formatted: Line spacing: Double

Formatted: Right: 0.63 cm

Formatted: Position: Horizontal: Right, Relative to: Margin, Vertical: 0 cm, Relative to: Paragraph, Wrap Around

Supplemental digital content is available for this article ([www.corneajrnl.com](http://www.corneajrnl.com)).

Correspondence: Alfonso Vasquez-Perez, MD, FRCOphth, FEBOS-CR, Cornea

*MiniDSAEK for Macroporation*

Formatted: Font: Italic

& External Diseases Service, Moorfields Eye Hospital, 162 City Rd, London

EC1V 2PD, United Kingdom (e-mail: Alfonso.perez1@nhs.net).

Formatted: Font: 12 pt, Not Bold

Formatted: Space Before: Auto, After: Auto, Line spacing: Double

Formatted: Line spacing: Double

**Alfonso Vasquez-Perez**

**Nizar Din**

**Jaime Kriman-Nunez**

**Maria Phylactou**

**Bruce D Allan MD FRCOphth**

**Bruce Allan receives partial salary support for research from the Department of Health's NIHR Biomedical Research Centre for Ophthalmology at Moorfields Eye Hospital and UCL Institute of Ophthalmology. The views expressed in the publication are those of the authors and not necessarily those of the Department of Health.**

Formatted: Font: 12 pt, Bold

Formatted: Right: 0.63 cm

Formatted: Position: Horizontal: Right, Relative to: Margin, Vertical: 0 cm, Relative to: Paragraph, Wrap Around

*MiniDSAEK for Macroperforation*

Formatted: Font: Italic

**Purpose:** We present a technique that preserves good vision in paracentral macroperforations and avoids challenges of tectonic lamellar or penetrating keratoplasty in eyes with poor visual potential.

Formatted: Font: 12 pt, Bold

Formatted: Font: 12 pt

Formatted: Space Before: 0 pt, After: 10 pt

**Method:** A wet laboratory was implemented for mini-Descemet stripping endothelial keratoplasty to seal macroperforations ab interno. This included a suture support technique designed to prevent graft herniation. We also present 3 cases who were treated successfully with this technique.

Formatted: Font: 12 pt, Bold

Formatted: Font: 12 pt

**Results:** The laboratory test confirmed that mini-Descemet stripping endothelial keratoplasty can successfully seal macroperforations without the need of large incisions. The minidisc is introduced through the perforation, and a double mattress suture prevents graft herniation. The technique allowed us to preserve 20/15 unaided vision in a case with paracentral macroperforation. It also restored eye globe integrity and achieved long-term stability in 2 cases with limbal stem- cell deficiency.

Formatted: Font: 12 pt, Bold

Formatted: Font: 12 pt

**Conclusions:** Mini-Descemet stripping-automated endothelial keratoplasty technique can be an alternative approach to avoid poor visual outcomes of tectonic keratoplasty in paracentral perforations. It also offers host tissue preservation in eyes with high risk of rejection for tectonic grafts.

Formatted: Font: 12 pt, Bold

Formatted: Font: 12 pt

**Key Words:** corneal perforations, DSAEK, DSEK, mini-DSAEK, tectonic keratoplasty

Formatted: Right: 0.63 cm

Formatted: Position: Horizontal: Right, Relative to: Margin, Vertical: 0 cm, Relative to: Paragraph, Wrap Around

*MiniDSAEK for Macroperforation*

Formatted: Font: Italic

Corneal perforation is a sight-threatening problem that requires urgent intervention.

Formatted: Font: (Default) Arial, 12 pt, Not Italic

Delay in treatment can result in enucleation or evisceration because of persistent

Formatted

aqueous leak and hypotony, leading to endophthalmitis, suprachoroidal hemorrhage,

Formatted: Line spacing: Double

or phthisis bulbi.<sup>1-3</sup> Corneal perforations can be traumatic or nontraumatic.

Formatted

Nontraumatic perforations result from progressive corneal stromal melting secondary

Formatted

to infective keratitis, autoimmune keratitis, chemical injury, drug toxicity, and

persistent corneal epithelial defects.<sup>3-5</sup> Nontraumatic corneal perforations are often

accompanied by significant tissue loss.<sup>3,4,6</sup>

There are a variety of approaches for surgical repair, and the choice of technique is

Formatted

primarily dependent on the size and location of the perforation.<sup>2,3,6</sup> In small traumatic

perforations with no tissue loss, aqueous tamponade using a soft contact lens can

be effective. More commonly, cyanoacrylate glue or sutured closure is required.<sup>2,6</sup>

For perforations up to 2 mm diameter, layered closure with amniotic membrane and

cyanoacrylate glue patching can be effective.<sup>4,7-9</sup> However, for larger perforations

("macroperforations"), tectonic lamellar keratoplasty or penetrating keratoplasty (PK)

Formatted

is almost always necessary.<sup>10,11</sup>

Oversized PKs have a high risk of rejection and failure.<sup>12</sup> Custom-shaped or small

Formatted: Font: (Default) Arial, 12 pt, Not Italic

diameter circular tectonic keratoplasty is therefore often the best repair option for

Formatted

macroperforations outside the visual axis.<sup>13,14</sup> Although tectonic keratoplasty

Formatted: Line spacing: Double

procedures can restore eye globe integrity, they often fail to restore clear vision.<sup>1,3,10-</sup>

Formatted

<sup>12</sup> Corneal sutures may cause deformation, irregular astigmatism, and scarring in the

visual axis when tectonic keratoplasty is performed for eccentric perforations.<sup>10-15</sup>

Tectonic keratoplasty can also be time consuming and technically challenging and

Formatted: Right: 0.63 cm

Formatted: Position: Horizontal: Right, Relative to: Margin, Vertical: 0 cm, Relative to: Paragraph, Wrap Around

*MiniDSAEK for Macroperforation*

Formatted: Font: Italic

may result in corneal neovascularization, increasing the risk of rejection and failure in any subsequent central PK performed to restore vision.<sup>10,12,16</sup>

Formatted

Formatted

Because of the complexity, cost, and poor visual results from tectonic keratoplasty, we set out to develop an alternate treatment suitable for use in eyes with good visual potential and peripheral or paracentral macroperforations, and cases of central macroperforation in eyes with poor visual potential.

Formatted: Font: (Default) Arial, 12 pt, Not Italic

Formatted: Line spacing: Double

Formatted

Formatted

Formatted

Here, we describe the use of a small Descemet stripping endothelial keratoplasty (DSEK)/Descemet stripping-automated endothelial keratoplasty (DSAEK) lenticule (mini-DSAEK) to seal macroperforations ab interno and laboratory testing of a suture support technique designed to prevent mini-DSAEK herniation through larger macroperforations. This builds on our previous in vitro studies of ab interno patching<sup>17</sup> and earlier case reports describing the use of normal diameter DSAEK donor lenticules in impending or actual perforation.<sup>18-20</sup>

Formatted: Font: (Default) Arial, 12 pt, Not Italic

Formatted

Formatted: Line spacing: Double

Formatted

Formatted

Formatted

**Materials and methods**

Formatted: Font: Bold

Formatted: Line spacing: Double

Formatted

Ethical approval for the use of human corneal tissue designated for research was obtained from the Moorfields Biobank Ethics Committee. Our review of case notes was approved as a clinical audit project by the Moorfields Eye Hospital Clinical Audit and Effectiveness Committee. The tenets of the Declaration of Helsinki were followed with informed consent for surgery as part of routine clinical care. In particular, patients were counseled that conventional tectonic keratoplasty may be necessary in the event of treatment failure.

Formatted: Font: (Default) Arial, 12 pt, Not Italic

Formatted: Right: 0.63 cm

Formatted: Position: Horizontal: Right, Relative to: Margin, Vertical: 0 cm, Relative to: Paragraph, Wrap Around

*MiniDSAEK for Macroporation*

Formatted: Font: Italic

*In Vitro Testing*

Formatted: Font: (Default) Arial, 12 pt

We mounted test corneoscleral discs on a Barron Artificial Anterior Chamber (Katena Inc, Denville, NJ) infused with balanced salt solution (BSS), using a blood pressure cuff to increase infusion pressure until bursting. We monitored infusion pressure continuously using an Infiniti 540 intraarterial pressure sensor (Draeger GmbH, Lubeck, Germany) to record the bursting pressure.

Formatted: Font: (Default) Arial, 12 pt, Not Italic  
Formatted: Font: (Default) Arial, 12 pt, Not Italic  
Formatted: Font: (Default) Arial, 12 pt, Not Italic  
Formatted: Font: (Default) Arial, 12 pt, Not Italic  
Formatted: Font: (Default) Arial, 12 pt, Not Italic  
Formatted: Font: (Default) Arial, 12 pt, Not Italic  
Formatted: Font: (Default) Arial, 12 pt, Not Italic  
Formatted: Font: (Default) Arial, 12 pt, Not Italic

We obtained 3 test mini-DSEK corneal patches from a single-corneoscleral disc mounted on a Barron Artificial Anterior Chamber (Katena Inc) with BSS infusion at physiological pressure. We initiated full-width manual lamellar dissection at 300 mm depth using a guarded blade to make a 7-mm limbal groove. We then lifted the anterior lamella and marked the stromal surface of the posterior lamella with 3 "S" letters using a gentian violet pen. We confirmed posterior lamellar thickness (172–193 mm) using a handheld ultrasound pachymeter (Pachmate2; DGH technology, Inc) measuring over each mark (172, 184, and 193 mm). We then punched out a 3-, 4-, and 5-mm diameter test mini-DSEK patch using disposable punch skin biopsy trephines (Stiefel, Schuco, United Kingdom) (Fig. 1).

Formatted: Font: (Default) Arial, 12 pt, Not Italic  
Formatted: Font: (Default) Arial, 12 pt, Not Italic  
Formatted: Font: (Default) Arial, 12 pt, Not Italic  
Formatted: Font: (Default) Arial, 12 pt, Not Italic  
Formatted: Font: (Default) Arial, 12 pt, Not Italic  
Formatted: Font: (Default) Arial, 12 pt, Not Italic  
Formatted: Font: (Default) Arial, 12 pt, Not Italic  
Formatted: Font: (Default) Arial, 12 pt, Not Italic  
Formatted: Font: (Default) Arial, 12 pt, Not Italic  
Formatted: Font: (Default) Arial, 12 pt, Not Italic  
Formatted: Font: (Default) Arial, 12 pt, Not Italic

We mounted a test corneoscleral disc with a peripheral macroporation created using a disposable punch skin trephine on a Barron Artificial Anterior Chamber infused with BSS. We then used air tamponade to compress test mini-DSEK patches evenly over the internal aspect of the test macroporation. We introduced the mini-DSEK patches into the anterior chamber through the test corneal perforation using 27-gauge blunt tying forceps. We used air and a small volume of cohesive ocular viscosurgical device (Provisc; Alcon, Fort Worth, TX), introduced through a separate

Formatted: Font: (Default) Arial, 12 pt, Not Italic  
Formatted: Font: (Default) Arial, 12 pt, Not Italic  
Formatted: Font: (Default) Arial, 12 pt, Not Italic  
Formatted: Font: (Default) Arial, 12 pt, Not Italic  
Formatted: Font: (Default) Arial, 12 pt, Not Italic  
Formatted: Font: (Default) Arial, 12 pt, Not Italic  
Formatted: Font: (Default) Arial, 12 pt, Not Italic  
Formatted: Font: (Default) Arial, 12 pt, Not Italic  
Formatted: Font: (Default) Arial, 12 pt, Not Italic  
Formatted: Font: (Default) Arial, 12 pt, Not Italic  
Formatted: Font: (Default) Arial, 12 pt, Not Italic  
Formatted: Font: (Default) Arial, 12 pt, Not Italic  
Formatted: Font: (Default) Arial, 12 pt, Not Italic  
Formatted: Font: (Default) Arial, 12 pt, Not Italic  
Formatted: Right: 0.63 cm  
Formatted: Position: Horizontal: Right, Relative to: Margin, Vertical: 0 cm, Relative to: Paragraph, Wrap Around

*MiniDSAEK for Macroperforation*

20-gauge paracentesis, to support the mini-DSEK patch beneath the test perforation.

We ensured that the mini-DSEK patch overlapped the internal aspect of the test perforation evenly by mobilizing it across the posterior corneal surface with a reverse Sinsky hook and then using a 20-gauge needle to engage the stromal side of the mini-DSEK patch and fine-tune its position. We then injected air through the paracentesis to initiate internal tamponade. After an internal sealing was confirmed, we used a blood pressure cuff to increase BSS infusion pressure until bursting. We monitored infusion pressure continuously using an Infiniti 540 intraarterial pressure sensor (Draeger GmbH) to record the bursting pressure.

Test perforations were 2 or 3 mm in diameter. For each test perforation, we used a 1- or 2-mm oversized mini-DSEK patch to test bursting pressure, measuring bursting pressure n = 4 times in each condition. Finally, we tested the effect of placing a mattress suture (Fig. 1) across the 3-mm perforation to prevent herniation of the mini-DSEK patch as intraocular pressure was raised.

*Mini-DSEK Surgical Technique*

All clinical cases were cases of corneal perforations after up to 3 failed attempts at sealing the anterior chamber with a conventional cyanoacrylate glue and polyethylene patch technique. Two cases were treated with mini-DSEK discs and 1 case with a mini-DSAEK disc. We prepared all minidiscs oversized by 2 mm versus the largest diameter of the corneal perforation measured at a slit lamp, using punch trephination as described above from either manually dissected (DSEK) or pre-cut (DSAEK) donor corneas with a target thickness in the range 100 to 200  $\mu$ m. Surgery was performed using either a sub-Tenon block or general anesthesia. After cleaning

Formatted: Font: Italic

Formatted: Font: (Default) Arial, 12 pt, Not Italic

Formatted: Font: (Default) Arial, 12 pt, Not Italic

Formatted: Font: (Default) Arial, 12 pt, Not Italic

Formatted: Font: (Default) Arial, 12 pt, Not Italic

Formatted: Font: (Default) Arial, 12 pt, Not Italic

Formatted: Font: (Default) Arial, 12 pt, Not Italic

Formatted: Font: (Default) Arial, 12 pt, Not Italic

Formatted: Font: (Default) Arial, 12 pt, Not Italic

Formatted: Font: (Default) Arial, 12 pt, Not Italic

Formatted: Font: (Default) Arial, 12 pt, Not Italic

Formatted: Font: (Default) Arial, 12 pt, Not Italic

Formatted: Font: (Default) Arial, 12 pt, Not Italic

Formatted: Font: (Default) Arial, 12 pt, Not Italic

Formatted: Font: (Default) Arial, 12 pt, Not Italic

Formatted: Font: (Default) Arial, 12 pt, Not Italic

Formatted: Font: (Default) Arial, 12 pt, Not Italic

Formatted: Font: (Default) Arial, 12 pt, Not Italic

Formatted: Font: (Default) Arial, 12 pt, Not Italic

Formatted: Line spacing: Double

Formatted: Font: (Default) Arial, 12 pt, Not Italic

Formatted: Font: (Default) Arial, 12 pt, Not Italic

Formatted: Font: (Default) Arial, 12 pt, Not Italic

Formatted: Font: (Default) Arial, 12 pt, Not Italic

Formatted: Font: (Default) Arial, 12 pt, Not Italic

Formatted: Font: (Default) Arial, 12 pt, Not Italic

Formatted: Font: (Default) Arial, 12 pt, Not Italic

Formatted: Font: (Default) Arial, 12 pt

Formatted: Line spacing: Double

Formatted: Font: (Default) Arial, 12 pt, Not Italic

Formatted: Font: (Default) Arial, 12 pt, Not Italic

Formatted: Font: (Default) Arial, 12 pt, Not Italic

Formatted: Font: (Default) Arial, 12 pt, Not Italic

Formatted: Font: (Default) Arial, 12 pt, Not Italic

Formatted: Font: (Default) Arial, 12 pt, Not Italic

Formatted: Font: (Default) Arial, 12 pt, Not Italic

Formatted: Font: (Default) Arial, 12 pt, Not Italic

Formatted: Font: (Default) Arial, 12 pt, Not Italic

Formatted: Font: (Default) Arial, 12 pt, Not Italic

Formatted: Font: (Default) Arial, 12 pt, Not Italic

Formatted: Font: (Default) Arial, 12 pt, Not Italic

Formatted: Font: (Default) Arial, 12 pt, Not Italic

Formatted: Font: (Default) Arial, 12 pt, Not Italic

Formatted: Right: 0.63 cm

Formatted

*MiniDSAEK for Macroperforation*

necrotic tissue, glue remnants, and corneal epithelium from around the perforation, we repositioned the iris using a small amount of cohesive ocular viscosurgical device to deepen the anterior chamber beneath the perforation. We then created a 1.5-mm cut-down paracentesis at the superior limbus. We introduced a mini-DSEK or mini DSAEK donor disc through the perforation, and then, a reverse Sinsky hook and a 20-gauge needle were used for centering of the donor disc beneath the perforation, as described before. For larger perforations (case 3), we placed a 10/0 nylon mattress suture to help prevent donor disc herniation. We sealed the anterior chamber with air injected through the paracentesis incision to tamponade the mini DSEK against the posterior aspect of the perforation at a physiological intraocular pressure as judged by gentle palpation. After drying the corneal stromal defect anterior to the mini-DSEK, we applied fibrin sealant (Tisseel; Baxter, Newbury, United Kingdom) and then filled the stromal defect with donor corneal stromal tissue followed by 3 layers of amniotic membrane, each secured with further applications of fibrin sealant. We then removed the air and Provisc from the anterior chamber with manual irrigation/aspiration through the paracentesis incision and completed surgery with an injection of intracameral cefuroxime 1 mg/0.1 mL (see Video, Supplemental Digital Content, <http://links.lww.com/ICO/B192>).

**Results**

Bursting pressures for each test condition are detailed in Table 1. Oversizing by 2 mm resulted in a higher bursting pressure than oversizing by 1 mm (unpaired t test;  $P = 0.001$ ). Reinforcement with a mattress suture resulted in further increases in burst strength (unpaired t test;  $P = 0.001$ ).

Formatted: Font: Italic

Formatted: Font: (Default) Arial, 12 pt, Not Italic

Formatted: Font: (Default) Arial, 12 pt, Not Italic

Formatted: Font: (Default) Arial, 12 pt, Not Italic

Formatted: Font: (Default) Arial, 12 pt, Not Italic

Formatted: Font: (Default) Arial, 12 pt, Not Italic

Formatted: Font: (Default) Arial, 12 pt, Not Italic

Formatted: Font: (Default) Arial, 12 pt, Not Italic

Formatted: Font: (Default) Arial, 12 pt, Not Italic

Formatted: Font: (Default) Arial, 12 pt, Not Italic

Formatted: Font: (Default) Arial, 12 pt, Not Italic

Formatted: Font: (Default) Arial, 12 pt, Not Italic

Formatted: Font: (Default) Arial, 12 pt, Not Italic

Formatted: Font: (Default) Arial, 12 pt, Not Italic

Formatted: Font: (Default) Arial, 12 pt, Not Italic

Formatted: Font: (Default) Arial, 12 pt, Not Italic

Formatted: Font: (Default) Arial, 12 pt, Not Italic

Formatted: Font: (Default) Arial, 12 pt, Not Italic

Formatted: Font: (Default) Arial, 12 pt, Not Italic

Formatted: Font: (Default) Arial, 12 pt, Not Italic

Formatted: Font: (Default) Arial, 12 pt, Not Italic

Formatted: Font: (Default) Arial, 12 pt, Not Italic

Formatted: Font: (Default) Arial, 12 pt, Not Italic

Formatted: Font: (Default) Arial, 12 pt, Not Italic

Formatted: Font: (Default) Arial, 12 pt, Not Italic

Formatted: Font: (Default) Arial, 12 pt, Not Italic

Formatted: Font: (Default) Arial, 12 pt, Not Italic

Formatted: Font: (Default) Arial, 12 pt, Not Italic

Formatted: Font: (Default) Arial, 12 pt, Not Italic

Formatted: Font: (Default) Arial, 12 pt, Not Italic

Formatted: Font: (Default) Arial, 12 pt, Not Italic

Formatted: Font: (Default) Arial, 12 pt, Not Italic

Formatted: Font: (Default) Arial, 12 pt, Not Italic

Formatted: Font: Bold

Formatted: Font: (Default) Arial, 12 pt, Bold, Not Italic

Formatted: Line spacing: Double

Formatted: Font: (Default) Arial, 12 pt, Not Italic

Formatted: Font: (Default) Arial, 12 pt, Not Italic

Formatted: Font: (Default) Arial, 12 pt, Not Italic

Formatted: Font: (Default) Arial, 12 pt, Not Italic

Formatted: Font: (Default) Arial, 12 pt, Not Italic

Formatted: Font: (Default) Arial, 12 pt, Not Italic

Formatted: Font: (Default) Arial, 12 pt, Not Italic

Formatted: Right: 0.63 cm

Formatted



Formatted: Font: Italic

**Clinical Cases**

Formatted: Font: (Default) Arial, 12 pt, Bold, Not Italic

**Case 1**

Formatted: Line spacing: Double

Formatted: Font: (Default) Arial, 12 pt

A 29-year-old man with a history of staphylococcal blepharitis and keratitis since childhood presented with a 4-day history of redness and pain. Examination revealed a collapsed anterior chamber and a 2.0-mm paracentral perforation with partial iris prolapse. We performed corneal scrapes from the margin of the perforation with samples sent for microbiological testing.

Formatted: Font: (Default) Arial, 12 pt, Not Italic

Formatted: Font: (Default) Arial, 12 pt, Not Italic

Formatted: Font: (Default) Arial, 12 pt, Not Italic

Formatted: Font: (Default) Arial, 12 pt, Not Italic

Formatted: Font: (Default) Arial, 12 pt, Not Italic

Formatted: Font: (Default) Arial, 12 pt, Not Italic

Formatted: Font: (Default) Arial, 12 pt, Not Italic

Formatted: Font: (Default) Arial, 12 pt, Not Italic

Formatted: Font: (Default) Arial, 12 pt, Not Italic

Formatted: Font: (Default) Arial, 12 pt, Not Italic

Formatted: Font: (Default) Arial, 12 pt, Not Italic

Formatted: Font: (Default) Arial, 12 pt, Not Italic

Formatted: Font: (Default) Arial, 12 pt, Not Italic

Formatted: Font: (Default) Arial, 12 pt, Not Italic

Formatted: Font: (Default) Arial, 12 pt, Not Italic

Formatted: Font: (Default) Arial, 12 pt, Not Italic

Formatted: Font: (Default) Arial, 12 pt, Not Italic

Formatted: Font: (Default) Arial, 12 pt, Not Italic

Formatted: Font: (Default) Arial, 12 pt, Not Italic

Formatted: Font: (Default) Arial, 12 pt, Not Italic

Formatted: Font: (Default) Arial, 12 pt, Not Italic

Formatted: Line spacing: Double

After failure of glue patching, we performed a 4-mm diameter mini-DSEK under local anesthesia aiming to tamponade the corneal perforation ab interno without inducing irregular astigmatism. Postoperatively, we treated the patient with moxifloxacin (0.5%) eye drops and preservative free dexamethasone (0.1%) eye drops both 4 times daily for 1 month, together with doxycycline 100 mg once daily orally for 2 months after surgery.

Formatted: Font: (Default) Arial, 12 pt, Not Italic

Formatted: Font: (Default) Arial, 12 pt, Not Italic

Formatted: Font: (Default) Arial, 12 pt, Not Italic

Formatted: Font: (Default) Arial, 12 pt, Not Italic

Formatted: Font: (Default) Arial, 12 pt, Not Italic

Formatted: Font: (Default) Arial, 12 pt, Not Italic

Formatted: Font: (Default) Arial, 12 pt, Not Italic

Formatted: Font: (Default) Arial, 12 pt, Not Italic

Formatted: Font: (Default) Arial, 12 pt, Not Italic

Formatted: Font: (Default) Arial, 12 pt

Formatted: Line spacing: Double

Staphylococcus epidermidis was isolated from microbiological cultures, but there was no recurrence of inflammation or leakage. Corneal epithelial regeneration was complete at 1 week, with stromal regeneration and partial clearing of the cornea in the subsequent months. The mini-DSEK disc remained in place, and the uncorrected distance visual acuity was 20/15 at a 2-year review (Fig. 2).

Formatted: Font: (Default) Arial, 12 pt, Not Italic

Formatted: Font: (Default) Arial, 12 pt, Not Italic

Formatted: Font: (Default) Arial, 12 pt, Not Italic

Formatted: Font: (Default) Arial, 12 pt, Not Italic

Formatted: Font: (Default) Arial, 12 pt, Not Italic

Formatted: Font: (Default) Arial, 12 pt, Not Italic

Formatted: Right: 0.63 cm

Formatted: Position: Horizontal: Right, Relative to: Margin, Vertical: 0 cm, Relative to: Paragraph, Wrap Around

**Case 2**

A 32-year-old woman developed a 2.5-mm diameter corneal perforation in the periphery of PK at the site of a persistent epithelial defect. She had had a uniocular alkaline injury 5 years previously, treated with amniotic membrane grafting in the



*MiniDSAEK for Macroperforation*

Formatted: Font: Italic

corneal scrapes, subsequently confirmed by microbiological culture results. She was treated with hourly amphotericin 0.15% and moxifloxacin 0.5% eye drops.

Formatted

Three days later, after failed cyanoacrylate glue and polyethylene disc patching, we performed a 6-mm diameter mini-DSEK under general anesthesia with placement of two 10/0 nylon mattress sutures (Fig. 4). In this case, a smaller customized stromal lamellar disc was allocated over the mini-DSEK covering the area of the perforation.

Formatted: Font: (Default) Arial, 12 pt, Not Italic

Formatted

Formatted: Line spacing: Double

Formatted

A multilayered amniotic membrane technique similar to case 2 was also performed. We injected intracameral amphotericin B (10 micrograms/0.1 mL) at the end of the procedure. We continued treatment with moxifloxacin 0.5% and amphotericin 0.15% hourly in the early postoperative period and started with preservative free dexamethasone 0.1% eye drops 4 times daily 1 week later.

Formatted

The infection resolved after 2 months of treatment. At the 6-month postoperative stage, there was no recurrence of the perforation, but the corneal epithelium remained unstable with incomplete healing. Accordingly, we removed the mattress sutures and performed a bridge conjunctival flap together with a lateral tarsorrhaphy. At the latest review, 9 months after surgery, the epithelium remains stable, and the eye is comfortable and uninflamed with a visual acuity of hand movements.

Formatted: Font: (Default) Arial, 12 pt, Not Italic

Formatted

Formatted: Line spacing: Double

**Discussion**

Formatted: Font: Bold

DSAEK as a treatment for corneal perforations has been previously reported by Graue-Hernandez et al,<sup>18</sup> Nahum et al,<sup>19</sup> and Tourkmani et al,<sup>20</sup> These authors described a standard DSAEK technique using a large corneal incision (4–5 mm), an anterior chamber maintainer, and a glide to insert an 8- to 9-mm graft,<sup>18,19</sup> Here, we

Formatted: Font: (Default) Arial, 12 pt, Bold, Not Italic

Formatted: Line spacing: Double

Formatted

Formatted

Formatted

Formatted: Right: 0.63 cm

Formatted: Position: Horizontal: Right, Relative to: Margin, Vertical: 0 cm, Relative to: Paragraph, Wrap Around

*MiniDSAEK for Macroperforation*

Formatted: Font: Italic

present a simplified technique in which smaller DSEK or DSAEK donors can be introduced directly through the corneal perforation after debridement or through a small, cut-down paracentesis. It is not necessary to seal the anterior chamber with glue at the time of surgery to create the incisions at a normal intraocular pressure, and the host corneal endothelium outside the donor disc is left intact.

Formatted

Relative preservation of the host endothelium is particularly important in eyes with good visual potential (case 1). The risk of corneal endothelial rejection after transplantation in inflamed eyes is high. This risk is unquantified for DSAEK. Over 90% of tectonic grafts are full thickness, and the 5-year survival rate is .50%.<sup>10,12,16,21</sup> We would recommend using a 2-mm oversized donor and a mattress suture (Fig. 1) for perforations larger than 3 mm to prevent donor herniation during air tamponade. A 1-mm oversized donor in combination with a mattress suture can be used to keep the visual axis clear for paracentral perforations. Bursting pressures in our laboratory experimentation were relatively low—approximately 2x the upper limit of the physiological range for a 2-mm oversized donor or 3x where a mattress suture was used (Table 1). We would therefore recommend the use of a Cartella shield to protect the eye during sleep in the early postoperative period and avoidance of eye rubbing.

Formatted

Formatted

These bursting pressures do not take into account any additional wound strength added by bioglues in rebuilding the corneal stroma. Here, we used fibrin glue, corneal donor stromal in-filling, and amniotic membrane layering.<sup>22</sup> Bursting pressures in similar laboratory tests for newer bioglues currently in development, which are designed to promote stromal tissue regeneration, are up to 10x the upper

Formatted: Font: (Default) Arial, 12 pt, Not Italic

Formatted

Formatted

Formatted

Formatted: Right: 0.63 cm

Formatted: Position: Horizontal: Right, Relative to: Margin, Vertical: 0 cm, Relative to: Paragraph, Wrap Around

*MiniDSAEK for Macroperforation*

end of the physiological range.<sup>23,24</sup> These bioglues may develop for clinical use either in combination with an ab interno patching technique, such as mini-DSEK, or in isolation as an effective therapy for corneal perforation.<sup>17</sup>

Corneal perforation remains a common, sight-threatening problem worldwide. Here, we present a simplified endothelial keratoplasty technique, with advantages for host tissue preservation and, for peripheral or paracentral perforations in sighted eyes, less induced irregular astigmatism versus techniques that have previously been described.

**References**

1. Portnoy SL, Insler MS, Kaufman HE. Surgical management of corneal ulceration and perforation. *Surv Ophthalmol.* 1989;34:47–58.
2. Vora GK, Haddadin R, Chodosh J. Management of corneal lacerations and perforations. *Int Ophthalmol Clin.* 2013;53:1–10.
3. Jhanji V, Young AL, Mehta JS, et al. Management of corneal perforation. *Surv Ophthalmol.* 2011;56:522–538.
4. Loya-Garcia D, Serna-Ojeda JC, Pedro-Aguilar L, et al. Non-traumatic corneal perforations: aetiology, treatment and outcomes. *Br J Ophthalmol.* 2017;101:634–639.
5. Xie L, Zhai H, Dong X, et al. Primary diseases of corneal perforation in Shandong Province, China: a 10-year retrospective study. *Am J Ophthalmol.* 2008;145:662–666.

Formatted: Font: Italic

Formatted: Font: (Default) Arial, 12 pt, Not Italic

Formatted: Font: (Default) Arial, 12 pt, Not Italic

Formatted: Font: (Default) Arial, 12 pt, Not Italic, Superscript

Formatted: Font: (Default) Arial, 12 pt, Not Italic

Formatted: Font: (Default) Arial, 12 pt, Not Italic

Formatted: Font: (Default) Arial, 12 pt, Not Italic

Formatted: Font: (Default) Arial, 12 pt, Not Italic

Formatted: Font: (Default) Arial, 12 pt, Not Italic

Formatted: Font: (Default) Arial, 12 pt, Not Italic

Formatted: Font: (Default) Arial, 12 pt, Not Italic, Superscript

Formatted: Font: (Default) Arial, 12 pt, Not Italic

Formatted: Font: (Default) Arial, 12 pt, Not Italic

Formatted: Font: (Default) Arial, 12 pt, Not Italic

Formatted: Font: (Default) Arial, 12 pt, Not Italic

Formatted: Font: (Default) Arial, 12 pt, Not Italic

Formatted: Font: (Default) Arial, 12 pt, Not Italic

Formatted: Font: (Default) Arial, 12 pt, Not Italic

Formatted: Font: (Default) Arial, 12 pt, Not Italic

Formatted: Font: (Default) Arial, 12 pt, Not Italic

Formatted: Font: (Default) Arial, 12 pt, Not Italic

Formatted: Font: (Default) Arial, 12 pt, Bold, Not Italic

Formatted: Line spacing: Double

Formatted: Font: (Default) Arial, 12 pt, Not Italic

Formatted: Font: (Default) Arial, 12 pt, Not Italic

Formatted: Font: (Default) Arial, 12 pt, Not Italic

Formatted: Font: (Default) Arial, 12 pt, Not Italic

Formatted: Font: (Default) Arial, 12 pt, Not Italic

Formatted: Font: (Default) Arial, 12 pt, Not Italic

Formatted: Font: (Default) Arial, 12 pt, Not Italic

Formatted: Font: (Default) Arial, 12 pt, Not Italic

Formatted: Font: (Default) Arial, 12 pt, Not Italic

Formatted: Font: (Default) Arial, 12 pt, Not Italic

Formatted: Font: (Default) Arial, 12 pt, Not Italic

Formatted: Right: 0.63 cm

Formatted: Position: Horizontal: Right, Relative to: Margin, Vertical: 0 cm, Relative to: Paragraph, Wrap Around

*MiniDSAEK for Macroperforation*

Formatted: Font: Italic

6. Yokogawa H, Kobayashi A, Yamazaki N, et al. Surgical therapies for corneal perforations: 10 years of cases in a tertiary referral hospital. Clin Ophthalmol. 2014;8:2165–2170.

Formatted: Font: (Default) Arial, 12 pt, Not Italic

Formatted: Font: (Default) Arial, 12 pt, Not Italic

Formatted: Font: (Default) Arial, 12 pt, Not Italic

7. Leahey AB, Gottsch JD, Stark WJ. Clinical experience with N-butyl cyanoacrylate (Nexacryl) tissue adhesive. Ophthalmology. 1993;100:173–180.

Formatted: Font: (Default) Arial, 12 pt, Not Italic

Formatted: Font: (Default) Arial, 12 pt, Not Italic

8. Sharma A, Kaur R, Kumar S, et al. Fibrin glue versus N-butyl-2-cyanoacrylate in corneal perforations. Ophthalmology. 2003;110:291–298.

Formatted: Font: (Default) Arial, 12 pt, Not Italic

9. Moorthy S, Jhanji V, Constantinou M, et al. Clinical experience with N-butyl cyanoacrylate tissue adhesive in corneal perforations secondary to herpetic keratitis. Cornea. 2010;29:971–975.

Formatted: Font: (Default) Arial, 12 pt, Not Italic

Formatted: Font: (Default) Arial, 12 pt, Not Italic

Formatted: Font: (Default) Arial, 12 pt, Not Italic

10. Ang M, Mehta JS, Sng CC, et al. Indications, outcomes, and risk factors for failure in tectonic keratoplasty. Ophthalmology. 2012;119:1311–1319.

Formatted: Font: (Default) Arial, 12 pt, Not Italic

Formatted: Font: (Default) Arial, 12 pt, Not Italic

11. Bhatt PR, Lim LT, Ramaesh K. Therapeutic deep lamellar keratoplasty for corneal perforations. Eye (Lond). 2007;21:1168–1173.

12. Williams KA, Lowe M, Bartlett C, et al. Risk factors for human corneal graft failure within the Australian corneal graft registry. Transplantation. 2008;86:1720–1724.

13. Deshmukh R, Stevenson LJ, Vajpayee RB. Techniques of noncircular corneal transplantation. Curr Opin Ophthalmol. 2020;31:293–301.

14. Lohchab M, Prakash G, Arora T, et al. Surgical management of peripheral corneal thinning disorders. Surv Ophthalmol. 2019;64:67–78.

15. Vajpayee RB, Singhvi A, Sharma N, et al. Penetrating keratoplasty for perforated corneal ulcers: preservation of iris by corneal debulking. Cornea. 2006;25:44–46.

Formatted: Right: 0.63 cm

Formatted: Position: Horizontal: Right, Relative to: Margin, Vertical: 0 cm, Relative to: Paragraph, Wrap Around

*MiniDSAEK for Macroperforation*

16. Hossain P, Tourkmani AK, Kazakos D, et al. Emergency corneal grafting in the UK: a 6-year analysis of the UK Transplant Registry. *Br J Ophthalmol.* 2018;102:26–30.

17. Samarawickrama C, Samanta A, Liszka A, et al. Collagen-based fillers as alternatives to cyanoacrylate glue for the sealing of large corneal perforations. *Cornea.* 2018;37:609–616.

18. Graue-Hernandez EO, Zuñiga-Gonzalez I, Hernandez-Camarena JC, et al. Tectonic DSAEK for the management of impending corneal perforation. *Case Rep Ophthalmol Med.* 2012;2012:916528.

19. Nahum Y, Bahar I, Busin M. Tectonic Descemet stripping automated endothelial keratoplasty for the management of sterile corneal perforations in decompensated corneas. *Cornea.* 2016;35:1516–1519.

20. Tourkmani AK, Ansari AS, Hossain PN, et al. Tectonic Descemet stripping endothelial keratoplasty for the management of corneal perforation: a case series. *Cornea.* 2020;39:1571–1575.

21. Coster DJ, Williams KA. The impact of corneal allograft rejection on the long-term outcome of corneal transplantation. *Am J Ophthalmol.* 2005;140:1112–1122.

22. Fan J, Wang M, Zhong F. Improvement of amniotic membrane method for the treatment of corneal perforation. *Biomed Res Int.* 2016;2016:1693815.

23. McTiernan CD, Simpson FC, Haagdoorens M, et al. LiQD cornea: proregeneration collagen mimetics as patches and alternatives to corneal transplantation. *Sci Adv.* 2020;6:eaba2187.

24. Shirzaei Sani E, Kheirkhah A, Rana D, et al. Sutureless repair of corneal injuries using naturally derived bioadhesive hydrogels. *Sci Adv.* 2019;5:eaav1281.

Formatted: Font: Italic

Formatted: Font: (Default) Arial, 12 pt, Not Italic

Formatted: Font: (Default) Arial, 12 pt, Not Italic

Formatted: Font: (Default) Arial, 12 pt, Not Italic

Formatted: Font: (Default) Arial, 12 pt, Not Italic

Formatted: Font: (Default) Arial, 12 pt, Not Italic

Formatted: Font: (Default) Arial, 12 pt, Not Italic

Formatted: Font: (Default) Arial, 12 pt, Not Italic

Formatted: Font: (Default) Arial, 12 pt, Not Italic

Formatted: Font: (Default) Arial, 12 pt, Not Italic

Formatted: Font: (Default) Arial, 12 pt, Not Italic

Formatted: Font: (Default) Arial, 12 pt, Not Italic

Formatted: Font: (Default) Arial, 12 pt, Not Italic

Formatted: Font: (Default) Arial, 12 pt, Not Italic

Formatted: Font: (Default) Arial, 12 pt, Not Italic

Formatted: Font: (Default) Arial, 12 pt, Not Italic

Formatted: Font: (Default) Arial, 12 pt, Not Italic

Formatted: Font: (Default) Arial, 12 pt, Not Italic

Formatted: Font: (Default) Arial, 12 pt, Not Italic

Formatted: Font: (Default) Arial, 12 pt, Not Italic

Formatted: Font: (Default) Arial, 12 pt, Not Italic

Formatted: Font: (Default) Arial, 12 pt, Not Italic

Formatted: Font: (Default) Arial, 12 pt, Not Italic

Formatted: Font: (Default) Arial, 12 pt, Not Italic

Formatted: Font: (Default) Arial, 12 pt, Not Italic

Formatted: Right: 0.63 cm

Formatted: Position: Horizontal: Right, Relative to: Margin, Vertical: 0 cm, Relative to: Paragraph, Wrap Around

Formatted: Font: Italic

**Table 1.** Wet-lab bursting pressures (mmHg) for different perforations and mini-discs sizes

Formatted

<b>Case</b>	<b>2mm perforation</b>	<b>3mm perforation</b>	<b>Suture mattress (3mm perforation)</b>
<b>1mm oversized disc</b>	<u>29</u> (range 22-36) (3mm disc, 172 microns)	<u>26</u> (range 21-32) (4mm disc, 184 microns)	<u>44</u> (range 39-50) (4mm disc, 184 microns)
<b>2mm oversized disc</b>	<u>41</u> (range 35-51) (4mm disc, 184 microns)	<u>37</u> (range 31-44) (5mm disc, 193 microns)	<u>66</u> (range 61-75) (5mm disc, 193 microns)

**Figures legends**

Formatted

**Figure 1.** Mini-DSEK wet laboratory. A, "S" marks on the posterior lamella after manual dissection before trephination of minidisks. B, Second cornea on the artificial anterior chamber with a paracentral perforation. C, Tamponade with a 2-mm oversized mini-DSEK, the borders of the perforation are marked with white dots. D, Suture mattress technique preventing mini-DSEK herniation.

Formatted

Formatted

Formatted: Line spacing: Double

**Figure 2.** Case 1. A, Paracentral perforation with iris prolapse. B, Air tamponade with mini-DSEK sealing the perforation. C, One-week postop anterior segment optical coherence tomography showing attached posterior mini-DSEK. D, Slit-lamp photograph after 1 month showing visual axis-free, visual acuity was 20/20 uncorrected.

Formatted: Space After: 0 pt, Don't adjust space between Latin and Asian text, Don't adjust space between Asian text and numbers

Formatted: Font: Bold

Formatted: Font: (Default) Arial, 12 pt, Not Italic

Formatted

Formatted: Line spacing: Double

**Figure 3.** Case 2. A, Inferior perforation on the graft host junction. B, Minidisc prepared from a precut DSAEK tissue before it is introduced through the perforation. C, 1-month post-op anterior segment optical coherence tomography showing a thin

Formatted: Space After: 0 pt, Don't adjust space between Latin and Asian text, Don't adjust space between Asian text and numbers

Formatted: Font: Bold

Formatted

Formatted: Line spacing: Double

Formatted

Formatted: Right: 0.63 cm

Formatted: Position: Horizontal: Right, Relative to: Margin, Vertical: 0 cm, Relative to: Paragraph, Wrap Around



*MiniDSAEK for Macroporation*

posterior lamellar graft (arrow). D, Slit-lamp photograph after 3 months showing a stable ocular surface.

**Figure 4.** Case 3. A, End-stage Stevens-Johnson syndrome with a macroporation because of candida keratitis. B, Double suture mattress to prevent herniation of the mini-DSEK. C, A second lamellar disc is customized to fit in the anterior defect. D, Slit-lamp photograph after 1 month showing mini-DSEK and mattress sutures.

Formatted: Font: Italic

Formatted: Font: (Default) Arial, 12 pt, Not Italic

Formatted: Font: (Default) Arial, 12 pt, Not Italic

Formatted: Font: (Default) Arial, 12 pt, Not Italic

Formatted: Space After: 0 pt, Don't adjust space between Latin and Asian text, Don't adjust space between Asian text and numbers

Formatted: Font: Bold

Formatted: Font: (Default) Arial, 12 pt, Not Italic

Formatted: Font: (Default) Arial, 12 pt, Not Italic

Formatted: Font: (Default) Arial, 12 pt, Not Italic

Formatted: Font: (Default) Arial, 12 pt, Not Italic

Formatted: Font: (Default) Arial, 12 pt, Not Italic

Formatted: Font: (Default) Arial, 12 pt, Not Italic

Formatted: Font: (Default) Arial, 12 pt, Not Italic

Formatted: Font: (Default) Arial, 12 pt, Not Italic

Formatted: Font: (Default) Arial, 12 pt, Not Italic

Formatted: Font: (Default) Arial, 12 pt, Not Italic

Formatted: Font: (Default) Arial, 12 pt, Not Italic

Formatted: Font: (Default) Arial, 12 pt, Not Italic

Formatted: Font: (Default) Arial, 12 pt, Not Italic

Formatted: Font: (Default) Arial, 12 pt, Not Italic

Formatted: Font: (Default) Arial, 12 pt, Not Italic

Formatted: Font: (Default) Arial, 12 pt, Not Italic

Formatted: Font: (Default) Arial, 12 pt, Not Italic

Formatted: Font: (Default) Arial, 12 pt, Not Italic

Formatted: Font: (Default) Arial, 12 pt, Not Italic

Formatted: Font: (Default) Arial, 12 pt, Not Italic

Formatted: Font: (Default) Arial, 12 pt, Not Italic

Formatted: Font: (Default) Arial, 12 pt, Not Italic

Formatted: Font: (Default) Arial, 12 pt, Not Italic

Formatted: Font: (Default) Arial, 12 pt, Not Italic

Formatted: Font: (Default) Arial, 12 pt, Not Italic

Formatted: Font: (Default) Arial, 12 pt, Not Italic

Formatted: Font: (Default) Arial, 12 pt, Not Italic

Formatted: Font: (Default) Arial, 12 pt, Not Italic

Formatted: Font: (Default) Arial, 12 pt, Not Italic

Formatted: Font: (Default) Arial, 12 pt, Not Italic

Formatted: Font: (Default) Arial, 12 pt, Not Italic

Formatted: Font: (Default) Arial, 12 pt, Not Italic

Formatted: Font: (Default) Arial, 12 pt, Not Italic

Formatted: Font: (Default) Arial, 12 pt, Not Italic

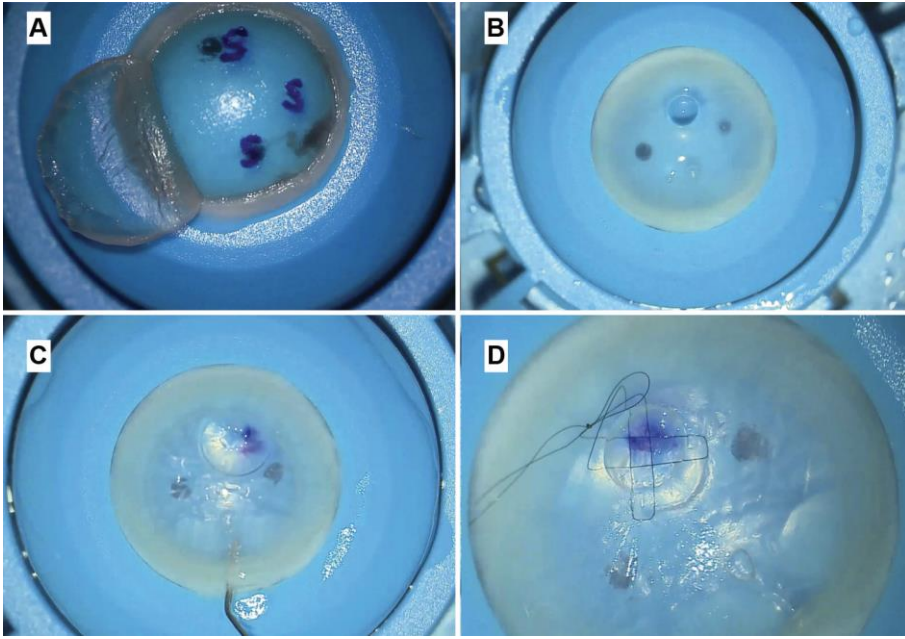
Formatted: Font: (Default) Arial, 12 pt, Not Italic

Formatted: Font: (Default) Arial, 12 pt, Not Italic

Formatted: Right: 0.63 cm

Formatted: Position: Horizontal: Right, Relative to: Margin, Vertical: 0 cm, Relative to: Paragraph, Wrap Around

**Fig.1**



Formatted: Font: Italic

Formatted: Font: Bold

Formatted: Font color: Auto

Formatted: Space After: 0 pt, Don't adjust space between Latin and Asian text, Don't adjust space between Asian text and numbers

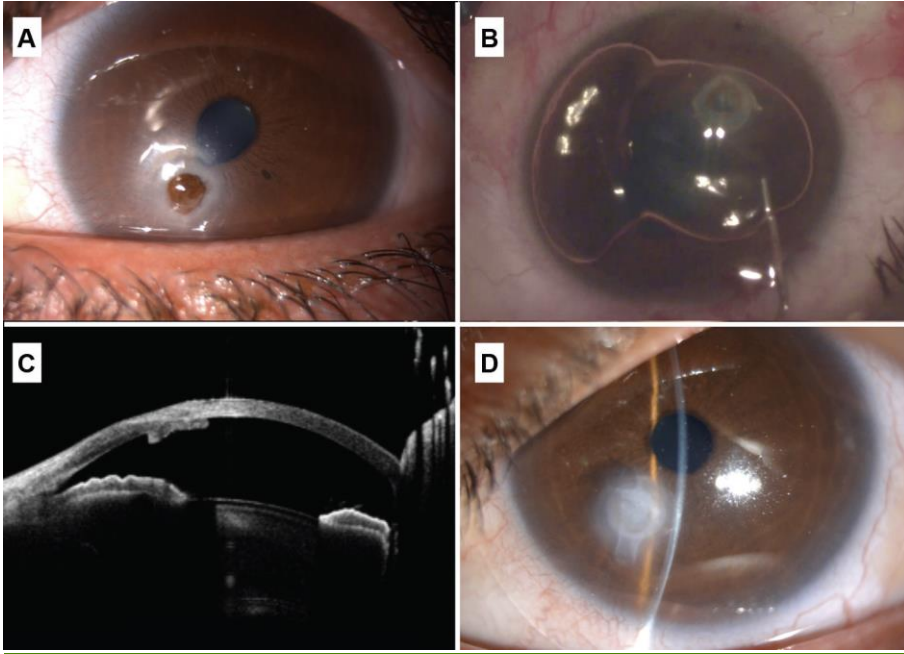
Formatted: Right: 0.63 cm

Formatted: Position: Horizontal: Right, Relative to: Margin, Vertical: 0 cm, Relative to: Paragraph, Wrap Around

Formatted: Font: Italic

**Fig. 2**

Formatted: Font: Bold



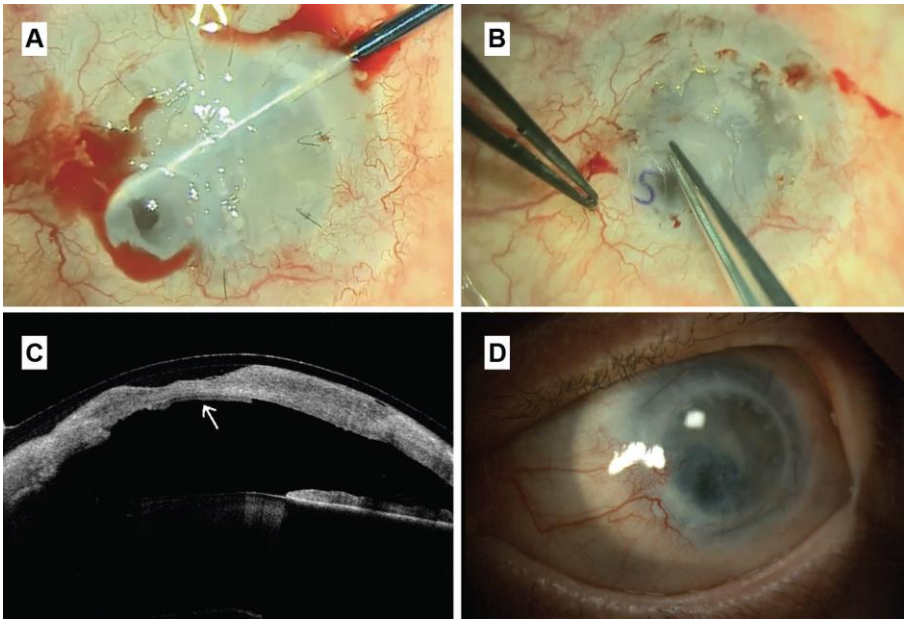
Formatted: Right: 0.63 cm

Formatted: Position: Horizontal: Right, Relative to: Margin,  
Vertical: 0 cm, Relative to: Paragraph, Wrap Around

Formatted: Font: Italic

**Fig. 3**

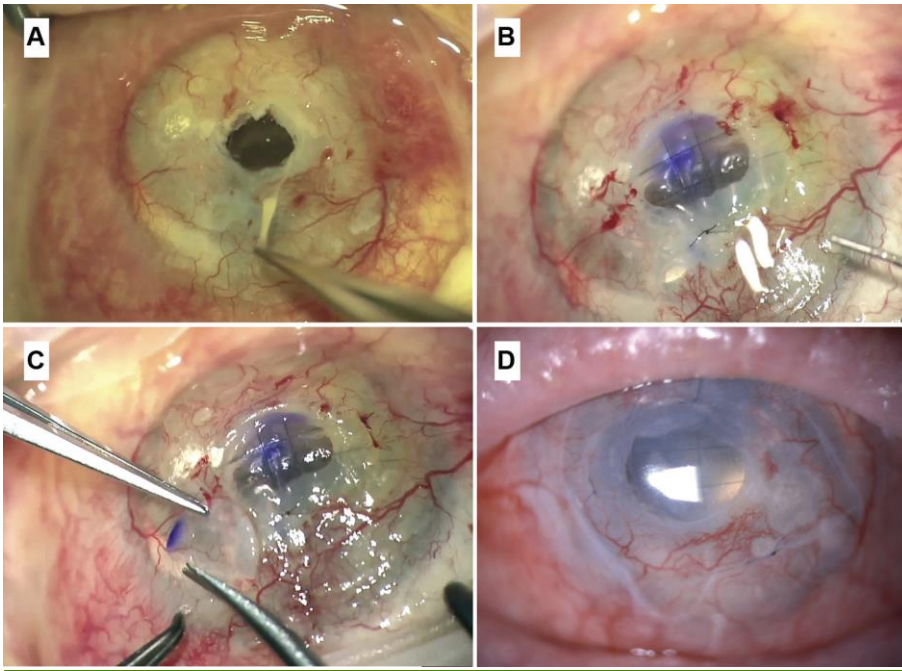
Formatted: Font: Bold



Formatted: Right: 0.63 cm

Formatted: Position: Horizontal: Right, Relative to: Margin, Vertical: 0 cm, Relative to: Paragraph, Wrap Around

**Fig. 4**



Corneal perforation is a sight-threatening problem that requires urgent intervention. Delay in treatment can result in enucleation or evisceration due to persistent aqueous leak and hypotony leading to endophthalmitis, suprachoroidal haemorrhage, or phthisis bulbi<sup>1-3</sup>. Corneal perforations can be traumatic or non-traumatic. Non-traumatic perforations result from progressive corneal stromal melting secondary to infective keratitis, autoimmune keratitis, chemical injury, drug toxicity, and persistent corneal epithelial defects<sup>3-5</sup>. Non-traumatic corneal perforations are often accompanied by significant tissue loss<sup>3,4,6</sup>.

There are a variety of approaches to surgical repair, and the choice of technique is primarily dependent on the size and location of the perforation<sup>2-3,6</sup>. In small traumatic perforations with no tissue loss, aqueous tamponade using a soft contact lens can be effective. More commonly, cyanoacrylate glue or sutured closure is required<sup>2,6</sup>. For perforations up to 2mm diameter, layered closure with amniotic membrane and cyanoacrylate glue patching can be effective<sup>4,7</sup>. But, for larger perforations ("macroperforations"), tectonic lamellar keratoplasty or penetrating keratoplasty (PK) is almost always necessary<sup>7-11</sup>.

Oversized PKs have a high risk of rejection and failure<sup>12</sup>. Custom shaped or small diameter circular tectonic keratoplasty is therefore often the best repair option for macroperforations outside the visual axis<sup>13,14</sup>. Although tectonic keratoplasty procedures can restore eye globe integrity, they often fail to restore clear vision<sup>1,3,10,11,12</sup>. Corneal sutures may cause deformation, irregular astigmatism and scarring in the visual axis when tectonic keratoplasty is performed for eccentric perforations<sup>10-15</sup>. Tectonic keratoplasty can also be time consuming and technically challenging, and may result in corneal neovascularization, increasing the risk of rejection and failure in any subsequent central PK performed to restore vision<sup>10,12,16</sup>.

Because of the complexity, cost, and poor visual results from tectonic keratoplasty, we set out to develop an alternate treatment suitable for use in eyes with good visual potential and peripheral or paracentral macroperforations; and cases of central macroperforation in eyes with poor visual potential.

Here we describe the use of a small DSEK/DSAEK lenticule (mini-DSAEK) to seal macroperforations ab interno, and laboratory testing of a suture support technique designed to prevent mini-DSAEK herniation through larger macroperforations. This builds on our previous in vitro studies of ab interno patching<sup>18</sup>, and earlier case reports describing the use of normal diameter DSAEK donor lenticules in impending or actual perforation<sup>19,20</sup>.

### **Material and methods**

Ethical approval for the use of human corneal tissue designated for research was obtained from the Moorfields Biobank Ethics Committee. Our review of case notes was approved as a clinical audit project by the Moorfields Eye Hospital Clinical Audit and Effectiveness Committee. The tenets of the declaration of Helsinki were followed with informed consent for surgery as part of routine clinical care. In particular, patients were counselled that conventional tectonic keratoplasty may be necessary in the event of treatment failure.

### **In vitro testing**

We mounted test corneoscleral discs on a Barron artificial anterior chamber (Katona Inc, Denville, NJ) infused with balanced salt solution (BSS), using a blood pressure cuff to increase infusion pressure until bursting. We monitored infusion pressure continuously using an Infiniti 540 intra-arterial pressure sensor (Draeger GmbH, Lubeck, Germany) to record the bursting pressure.

Formatted: Right: 0.63 cm

Formatted: Position: Horizontal: Right, Relative to: Margin, Vertical: 0 cm, Relative to: Paragraph, Wrap Around

We obtained 3 test mini-DSEK corneal patches from a single corneoscleral disc mounted on a Barron artificial anterior chamber (Katena Inc, Denville, NJ) with BSS infusion at physiological pressure. We initiated full-width manual lamellar dissection at 300µm depth using a guarded blade to make a 7mm limbal groove. We then lifted the anterior lamella and marked the stromal surface of the posterior lamella with three "S" letters using a gentian violet pen. We confirmed posterior lamellar thickness (172-193µm) using (Make, Model) ultrasound pachymetry (Manufacturer, City, State) measurements over each mark. (172,184 and 193 microns). We then punched out a 3, 4 and 5mm diameter test mini-DSEK patch using disposable (Make, Model) punch skin biopsy trephines (Manufacturer, City, State) (Figure 1).

We mounted a test corneoscleral disc with a peripheral macroperforation created using a disposable trephine on a Barron artificial anterior chamber infused with balanced salt solution (BSS). We then used air tamponade to compress test mini-DSEK patches evenly over the internal aspect of the test macroperforation. We introduced the mini-DSEK patches through the test corneal perforation using 27-gauge blunt tying forceps. We used air and a small volume of cohesive ocular viscosurgical device (OVD) (Provisc, Alcon, Fort Worth, TX), introduced through a separate 20-gauge paracentesis, to support the mini-DSEK patch beneath the test perforation. We then ensured that the mini-DSEK patch overlapped the internal aspect of the test perforation evenly using a 20-gauge needle to engage the stromal side of the mini-DSEK patch and fine tune its position. We then injected air through the paracentesis to initiate internal tamponade. After ab interno sealing was confirmed, we used a blood pressure cuff to increase BSS infusion pressure until bursting. We monitored infusion pressure continuously using an Infiniti 540 intra-

Formatted: Right: 0.63 cm

Formatted: Position: Horizontal: Right, Relative to: Margin, Vertical: 0 cm, Relative to: Paragraph, Wrap Around



arterial pressure sensor (Draeger GmbH, Lubeck, Germany) to record the bursting pressure.

Test perforations were 2mm or 3mm in diameter. For each test perforation, we used a 1mm or 2mm oversized mini-DSEK patch to test bursting pressure, measuring bursting pressure n=4 times in each condition. Finally, we tested the effect of placing a mattress suture (Figure 1) across the 3mm perforation to prevent herniation of the mini-DSEK patch as intraocular pressure was raised.

### **Mini-DSEK Surgical Technique**

All clinical cases were cases of corneal perforation treated with Mini-DSEK after up to 3 failed attempts at sealing the anterior chamber with a conventional cyanoacrylate glue and polyethylene patch technique. We prepared mini-DSEK donor discs, oversized by 2mm versus the largest diameter of the corneal perforation measured by OCT scanning, using punch trephination as described above from either manually dissected (DSEK) or pre-cut (DSAEK) donor corneas with a target thickness in the range 100-200µm. Surgery was performed using either a sub-Tenon block or general anaesthesia. After cleaning necrotic tissue, glue remnants, and corneal epithelium from around the perforation, we repositioned the iris using a small amount of cohesive OVD to deepen the anterior chamber beneath the perforation. For larger perforations (Case 3 below), we pre-placed a 10/0N mattress suture to help prevent donor disc herniation (Figure 1). We then created a 1.5mm cut-down paracentesis at the superior limbus. We introduced mini-DSEK donor discs either through the perforation or through the paracentesis, before centering the donor disc beneath the perforation using a Sinsky hook. We sealed the anterior chamber with

Formatted: Right: 0.63 cm

Formatted: Position: Horizontal: Right, Relative to: Margin, Vertical: 0 cm, Relative to: Paragraph, Wrap Around

air injected through the paracentesis incision to tamponade the mini-DSEK against the posterior aspect of the perforation at a physiological intraocular pressure as judged by gentle palpation. After drying the corneal stromal defect anterior to the mini-DSEK, we applied fibrin sealant (Tisseel, Baxter, Newbury, UK), then filled the stromal defect with donor corneal stromal tissue followed by 3 layers of amniotic membrane, each secured with further applications of fibrin sealant. We then removed the air and Provisc from the anterior chamber with manual irrigation/aspiration through the paracentesis incision, and completed surgery with an injection of intracameral Cefuroxime 1mg/0.1ml. **INSERT LINK TO VIDEO**

## Results

Bursting pressures for each test condition are detailed in table 1. Oversizing by 2mm, leaving a 1mm internal overlap 360°, resulted in a higher bursting pressure than oversizing by 1mm (unpaired t test; p=0.001). Reinforcement with a mattress suture resulted in further increases in burst strength (unpaired t test; p=0.001).

## Clinical Cases:

### Case 1

A 29-year-old male with history of staphylococcal blepharitis and keratitis since childhood presented with a 4-day history of redness, and pain. Examination revealed a collapsed anterior chamber and a 2.0mm paracentral perforation with partial iris prolapse. We performed corneal scrapes from the margin of the perforation with samples sent for microbiological testing.

Formatted: Right: 0.63 cm

Formatted: Position: Horizontal: Right, Relative to: Margin, Vertical: 0 cm, Relative to: Paragraph, Wrap Around

After failure of glue patching, we performed a 4mm diameter mini-DSEK under local anaesthesia aiming to tamponade the corneal perforation ab interno without inducing irregular astigmatism. Postoperatively, we treated the patient with Moxifloxacin (0.5%) eye drops and preservative free Dexamethasone (0.1%) eye drops both 4 times daily for 1 month, together with Doxycycline 100mg once daily orally for 2 months after surgery.

Staphylococcus Epidermidis was isolated from microbiological cultures, but there was no recurrence of inflammation or leakage. Corneal epithelial regeneration was complete at 1 week, with stromal regeneration and partial clearing of the cornea in the subsequent months. The mini-DSEK disc remained in place, and the uncorrected distance visual acuity was 20/15 at 2-year review. (Figure 2)

## **Case 2**

A 32-year-old female developed a 2.5mm diameter corneal perforation in the periphery of a penetrating keratoplasty at the site of a persistent epithelial defect. She had had a unioocular alkaline injury 5 years previously, treated with amniotic membrane grafting in the acute phase, and subsequent autologous simple limbal epithelial transplantation (SLET) for limbal stem cell failure. The eye was hypotonous with choroidal effusions after 3 failed attempts cyanoacrylate glue and polyethylene disc patching.

We performed 4.5mm diameter mini-DSEK under general anaesthesia, with a covering layer of amniotic membrane sutured basement membrane down limbus to limbus. Postoperatively, we treated the patient with Moxifloxacin (0.5%) eye drops and preservative free Dexamethasone (0.1%) eye drops both 4 times daily for 1

Formatted: Right: 0.63 cm

Formatted: Position: Horizontal: Right, Relative to: Margin, Vertical: 0 cm, Relative to: Paragraph, Wrap Around

month, together with Doxycycline 100mg once daily orally for 2 months after surgery. Preservative free Prednisolone (0.5%) eye drops were then continued once daily, together with preservative free topical lubricants.

The intraocular pressure normalised and the choroidal effusions resolved. After one month the covering layer of amniotic membrane had resorbed. The epithelium had healed over the amniotic membrane layers, and remained stable at the last review, one year after surgery, with a visual acuity of ~~X/X~~.

### Case 3:

A 57 year-old female with advanced Steven Johnson Syndrome (SJS) presented with a left corneal abscess and 4mm diameter central perforation. The patient had previously had multiple previous surgical procedures including penetrating keratoplasty, cataract surgery with intraocular lens implantation, and multiple superficial keratectomies for calcific band keratopathy. We diagnosed Candida keratitis based on the microscopy results from of corneal scrapes, subsequently confirmed by microbiological culture results. She was treated with hourly Amphotericin 0.15% and Moxifloxacin 0.5% eye drops.

3 days later, after failed cyanoacrylate glue and polyethylene disc patching, we performed a 6mm diameter mini-DSEK under general anaesthesia with pre-placement of 2 10/0 Nylon mattress sutures (Figure 1). We injected intracameral amphotericin B (10micrograms/0.1mL) at the end of the procedure. We continued treatment with Moxifloxacin 0.5% and Amphotericin 0.15% hourly in the early

Formatted: Right: 0.63 cm

Formatted: Position: Horizontal: Right, Relative to: Margin, Vertical: 0 cm, Relative to: Paragraph, Wrap Around

postoperative period, together with preservative free Dexamethasone 0.1% eye drops four times daily.

The infection resolved after 2 months treatment. At the 6-month postoperative stage, there was no recurrence of the perforation, but the corneal epithelium remained unstable with incomplete healing. Accordingly, we removed the mattress sutures and performed a bridge conjunctival flap together with a lateral tarsorrhaphy. At the latest review, 9 months after surgery, the epithelium remains stable, and the eye is comfortable and uninflamed with a visual acuity of **X/X**.

#### **DISCUSSION:**

DSAEK as a treatment for corneal perforations has been previously reported by Graue et al.<sup>18</sup> and Nahum et al.<sup>19</sup>. These authors describe a standard DSAEK technique using a large corneal incision (4-5mm), an AC maintainer and a glide to insert a 8-9 mm graft.<sup>18,19</sup>. Here, we present a simplified technique in which smaller DSEK donors can be introduced directly through the corneal perforation after debridement, or through a small, cut-down paracentesis. It is not necessary to seal the anterior chamber with glue at the time of the surgery in order to create the incisions at a normal intraocular pressure, and the host corneal endothelium outside the donor disc is left intact.

Relative preservation of the host endothelium is particularly important in eyes with good visual potential (Case 1 above). The risk of corneal endothelial rejection following transplantation in inflamed eyes is high. This risk is unquantified for

DSAEK. Over 90% of tectonic grafts are full-thickness, and 5-year survival is <50%  
40,46,24.

We would recommend using a 2mm oversized donor, and a mattress suture (figure 1) for perforations larger than 3mm to prevent donor herniation during air tamponade. A 1mm oversized donor in combination with a mattress suture can be used to keep the visual axis clear for paracentral perforations. Bursting pressures in our laboratory experimentation were relatively low—approximately 2x the upper limit of the physiological range for a 2mm oversized donor, or 3x where a mattress suture was used (Table 1). We would therefore recommend the use of a Cartella Shield to protect the eye during sleep in the early postoperative period, and avoidance of eye-rubbing.

These bursting pressures do not take account of any additional wound strength added by bioglues in rebuilding the corneal stroma. Here, we used fibrin glue, corneal donor stromal in-filling, and amniotic membrane layering. Bursting pressures in similar laboratory tests for newer bioglues currently in development, which are designed to promote stromal tissue regeneration, are up to 10x the upper end of the physiological range. These bioglues may develop for clinical use either in combination with an ab-interno patching technique such as mini-DSEK, or in isolation as an effective therapy for corneal perforation.

Corneal perforation remains a common, sight-threatening problem worldwide. Here, we present a simplified endothelial keratoplasty technique, with advantages for host tissue preservation and, for peripheral or paracentral perforations in sighted eyes,

Formatted: Right: 0.63 cm

Formatted: Position: Horizontal: Right, Relative to: Margin, Vertical: 0 cm, Relative to: Paragraph, Wrap Around

less induced irregular astigmatism versus techniques that have previously been described.

#### REFERENCES:

1. Portnoy SL, Inslor MS, Kaufman HE. Surgical management of corneal ulceration and perforation. *Surv Ophthalmol*. 1989;34: 47–58.
2. Vora GK, Haddadin R, Chodosh J. Management of corneal lacerations and perforations. *Int Ophthalmol Clin* 2013;53:1–10.
3. Jhanji V, Young AL, Mehta JS, et al. Management of corneal perforation. *Surv Ophthalmol* 2011;56:522–38.
4. Loya-Garcia D, Serna-Ojeda JC, Pedro-Aguilar L, et al. Non-traumatic corneal perforations: aetiology, treatment and outcomes. *British Journal of Ophthalmology*. 2017;101:634–639.
5. Xie L, Zhai H, Dong X, et al. Primary diseases of corneal perforation in Shandong Province, China: a 10-year retrospective study. *Am J Ophthalmol* 2008;145:662–6.
6. Yokogawa H, Kobayashi A, Yamazaki N, et al. Surgical therapies for corneal perforations: 10 years of cases in a tertiary referral hospital. *Clin Ophthalmol* 2014;8:2165–70.
7. Leahey AB, Gottsch JD, Stark WJ. Clinical experience with N-butyl cyanoacrylate (Nexacryl) tissue adhesive. *Ophthalmology* 1993;100:173–80.
8. Sharma A, Kaur R, Kumar S, et al. Fibrin glue versus N-butyl-2-cyanoacrylate in corneal perforations. *Ophthalmology* 2003;110:291–8.
9. Moorthy S, Jhanji V, Constantinou M, et al. Clinical experience with N-butyl cyanoacrylate tissue adhesive in corneal perforations secondary to herpetic keratitis. *Cornea* 2010;29:971–5.
10. Ang M, Mehta JS, Sng CC, et al. Indications, outcomes, and risk factors for failure in tectonic keratoplasty. *Ophthalmology* 2012;119:1311–9.

Formatted: Right: 0.63 cm

Formatted: Position: Horizontal: Right, Relative to: Margin, Vertical: 0 cm, Relative to: Paragraph, Wrap Around

11. Bhatt PR, Lim LT, Ramaesh K. Therapeutic deep lamellar keratoplasty for corneal perforations
12. Williams KA, Lowe M, Bartlett C, Kelly TL, Coster DJ; All Contributors. Risk factors for human corneal graft failure within the Australian corneal graft registry. *Transplantation*. 2008 Dec 27;86(12):1720-4. doi: 10.1097/TP.0b013e3181903b0a. PMID: 19104411.
13. Deshmukh R, Stevenson LJ, Vajpayee RB. Techniques of noncircular corneal transplantation. *Curr Opin Ophthalmol*. 2020 Jul;31(4):293-301. doi: 10.1097/ICU.0000000000000672. PMID: 32412959.
14. Lohchab M, Prakash G, Arora T, Maharana P, Jhanji V, Sharma N, Vajpayee RB. Surgical management of peripheral corneal thinning disorders. *Surv Ophthalmol*. 2019 Jan-Feb;64(1):67-78. doi: 10.1016/j.survophthal.2018.06.002. Epub 2018 Jun 8. PMID: 29886126.
15. Vajpayee RB, Singhvi A, Sharma N, et al. Penetrating keratoplasty for perforated corneal ulcers. Preservation of iris by corneal debulking. *Cornea*. 2006;25:44-46.
16. Hossain P, Tourkmani AK, Kazakos D, et al. Emergency corneal grafting in the UK: a 6-year analysis of the UK Transplant Registry. *British Journal of Ophthalmology*. 2018;102:26-30.
17. Samarawickrama C, Samanta A, Liszka A, Fagerholm P, Buznyk O, Griffith M, Allan B. Collagen-Based Fillers as Alternatives to Cyanoacrylate Glue for the Sealing of Large Corneal Perforations. *Cornea*. 2018 May;37(5):609-616. doi: 10.1097/ICO.0000000000001459. PMID: 29176452.
18. Graue-Hernandez EO, Zuñiga-Gonzalez I, Hernandez-Camarena JC, et al. Tectonic DSAEK for the Management of Impending Corneal Perforation. *Case Rep Ophthalmol Med*. 2012;2012:916528. doi:10.1155/2012/916528.
19. Nahum Y, Bahar I, Busin M. Tectonic Descemet Stripping Automated Endothelial Keratoplasty for the Management of Sterile Corneal Perforations in Decompensated Corneas. *Cornea*. 2016;35(12):1516-1519. doi:10.1097/ICO.0000000000001037.
20. Okada A, Sano I, Ikeda Y, Fujihara E, Tanito M. Patch Grafting Using a Cryopreserved Descemet Stripping Automated Endothelial Keratoplasty Flap for Treating Corneal Perforation. *Case Rep Ophthalmol*. 2016;7(1):202-207. Published 2016 Apr 29. doi:10.1159/000445796.

Formatted: Right: 0.63 cm

Formatted: Position: Horizontal: Right, Relative to: Margin, Vertical: 0 cm, Relative to: Paragraph, Wrap Around



21. Williams KA, Keane MC, Galettis RA, Jones VJ, Mills RAD, Coster DJ. The Australian Corneal Graft Registry 2015 Report. Adelaide, Australia: Flinders University; 2015.
22. Anterior lamellar keratoplasty over penetrating keratoplasty for optical, therapeutic, and tectonic indications: a case series. Ang M, Mehta JS, Arundhati A, Tan DT. *Am J Ophthalmol*. 2009 Apr;147(4):697-702
23. Jhanji V, Young AL, Mehta JS, Sharma N, Agarwal T, Vajpayee RB. Management of corneal perforation. *Surv Ophthalmol*. 2011;56(6):522-538. doi:10.1016/j.survophthal.2011.06.003.
24. Tugal-Tutkun I, Akova YA, Foster CS. Penetrating keratoplasty in cicatrizing conjunctival diseases. *Ophthalmology*. 1995;102(4):576-585. doi:10.1016/s0161-6420(95)30980-3.
25. Wang F, Li S, Wang T, Gao H, Shi W. Modified tectonic keratoplasty with minimal corneal graft for corneal perforation in severe Stevens-Johnson syndrome: a case series study. *BMC Ophthalmol*. 2014;14:97.
26. Zarei-Ghanavati M, Avadhanam V, Vasquez-Perez A, Liu C. The osteo-odonto-keratoprosthesis. *Curr Opin Ophthalmol*. 2017;28(4):397-402.

Formatted: Right: 0.63 cm

Formatted: Position: Horizontal: Right, Relative to: Margin, Vertical: 0 cm, Relative to: Paragraph, Wrap Around