




Childhood-Onset Choreo-Dystonia Due to a Recurrent Novel Homozygous Nonsense *HPCA* Variant: Case Series and Literature Review

Francesca Magrinelli, MD, PhD,^{1,*}  Kailash P. Bhatia, MD, DM, FRCP,¹  Mehran Beiraghi Toosi, MD,^{2,3} Fatemeh Arab, PhD,⁴ Ehsan Ghayoor Karimiani, MD, PhD,^{5,6} Sahar Sedighzadeh, PhD,^{7,8} Behnaz Ansari, MD,⁹ Maedeh Neshatdoust, BSc,¹⁰ Clarissa Rocca, MSc,¹¹ Henry Houlden, MD, PhD,¹¹  and Reza Maroofian, PhD¹¹

Abstract: Background: Biallelic variants in *HPCA* were linked to isolated dystonia (formerly DYT2) in 2015. Since then, the clinical spectrum of *HPCA*-related disorder has expanded up to including a complex syndrome encompassing neurodevelopmental delay, generalized dystonia with bulbar involvement, and infantile seizures. Cases: We report four individuals with a new phenotype of childhood-onset choreo-dystonia belonging to two unrelated Iranian pedigrees and harboring a novel homozygous nonsense pathogenic variant NM_002143.3: c.49C>T p.(Arg17*) in *HPCA*. Although the families are both Iranian, haplotype analysis of the exome data did not reveal a founder effect of the variant.

Literature Review: A systematic review of articles on *HPCA* and dystonia published since the disease gene discovery (PubMed; search on July 09, 2022; search strategy “*HPCA* AND dystonia”, “*HPCA* AND movement disorder”, “hippocalcin AND dystonia”, and “hippocalcin AND movement disorder”; no language restriction) resulted in 18 references reporting 10 cases from six families. *HPCA*-related dystonia was isolated or in various combinations with neurodevelopmental delay, intellectual disability, seizures, cognitive decline, and psychiatric comorbidity. Onset of dystonia ranged from infancy to early adulthood. Dystonia started in the limbs or neck and became generalized in most cases. Brain MRI was unremarkable in nearly all cases where performed. There was poor or no response to common antidystonic medications in most cases.

Conclusions: Our case series expands the pheno-genotypic spectrum of *HPCA*-related disorder by describing childhood-onset choreo-dystonia as a new phenotype, reporting on a recurrent novel pathogenic nonsense variant in *HPCA*, and suggesting that exon 2 of *HPCA* might be a mutational hotspot.

Biallelic *HPCA* variants were first linked to isolated dystonia (formerly DYT2) in 2015.¹ Thenceforth, despite large dystonia cohorts being screened,^{2,3} only 10 cases from six pedigrees have been reported, with clinical features ranging from isolated dystonia to a

syndrome featuring neurodevelopmental delay, generalized dystonia with bulbar involvement, and infantile seizures.^{1,4–7}

HPCA encodes hippocalcin, a neuron-specific calcium-binding protein highly expressed in the human striatum and

¹Department of Clinical and Movement Neurosciences, UCL Queen Square Institute of Neurology, University College London, London, United Kingdom; ²Department of Pediatrics, School of Medicine, Mashhad University of Medical Sciences, Mashhad, Iran; ³Neuroscience Research Center, Mashhad University of Medical Sciences, Mashhad, Iran; ⁴Department of Medical Genetics, Faculty of Medicine, Tehran University of Medical Sciences, Tehran, Iran; ⁵Molecular and Clinical Sciences Institute, St. George's University of London, London, United Kingdom; ⁶Department of Medical Genetics, Next Generation Genetic Polyclinic, Mashhad, Iran; ⁷Department of Biological Sciences, Faculty of Science, Shahid Chamran University of Ahwaz, Ahwaz, Iran; ⁸KaryoGen Medical Genetics Laboratory, Isfahan, Iran; ⁹Department of Neurology, School of Medicine, Neurosciences Research Centre, Al-Zahra Hospital, Isfahan University of Medical Sciences, Isfahan, Iran; ¹⁰Department of Cell and Molecular Biology and Microbiology, Faculty of Biological Science and Technology, University of Isfahan, Isfahan, Iran; ¹¹Department of Neuromuscular Diseases, UCL Queen Square Institute of Neurology, London, United Kingdom

*Correspondence to: Dr. Francesca Magrinelli, Department of Clinical and Movement Neurosciences, UCL Queen Square Institute of Neurology, University College London, Queen Square, London WC1N 3BG, UK; E-mail: f.magrinelli@ucl.ac.uk

Keywords: chorea, dystonia, genetics, hippocalcin, *HPCA*.

This is an open access article under the terms of the [Creative Commons Attribution License](https://creativecommons.org/licenses/by/4.0/), which permits use, distribution and reproduction in any medium, provided the original work is properly cited.

Received 10 April 2022; revised 10 July 2022; accepted 15 July 2022.

Published online 23 August 2022 in Wiley Online Library (wileyonlinelibrary.com). DOI: 10.1002/mdc3.13529

hippocampus.¹ Hippocampal modulates the activity of voltage-dependent calcium and potassium channels.^{1,8}

We report four individuals with choreo-dystonia belonging to two unrelated Iranian families and carrying a novel homozygous nonsense *HPCA* variant, perform haplotype analysis of the exome data from two probands, retrieve our genetic databases looking for additional *HPCA* cases, and systematically review previously published *HPCA* cases (Table 1). In the two probands herein reported, whole-exome sequencing (WES) was performed with Illumina NovaSeq (50× mappable, 6–8 Gb) after DNA sample preparation and exome enrichment using Agilent SureSelect Human All Exon V6 kit.

Cases Series

Pedigree A

Case A-II-1: A 14-year-old right-handed Iranian male (Fig. 1A), first child of consanguineous parents, had a history of intrauterine growth retardation. He was born at 39 gestational weeks and manifested mild jaundice at birth. He had delayed gross motor milestones, with acquisition of sitting position at age 1.5 and independent walking at age 2, whereas his speech and language development was unremarkable. He showed abnormal posturing of his fingers and feet since early childhood, with slow progression to generalized dystonia. He had two younger brothers, of whom one (Case A-II-2) was similarly affected and the other died of a bowel defect in early childhood. There was no family history of neurological, muscular, cardiac, gastrointestinal disorders or dysmorphic features in the extended pedigree. On examination (Video 1), he had mild dysmorphic features, including everted lower lip, large ears, and S-shaped scoliosis. He had dysarthria, generalized mobile dystonia with facial grimacing and prominent involvement of his distal limbs with acral choreiform movements of his fingers and feet. His gait was characterized by mild dystonic posturing of his toes. Despite formal neuropsychometry not being performed, cognitive functions were reported to be intact. Brain MRI at age 11 and EEG were unremarkable. Echocardiography showed small muscular ventricular septal defect. Trials of levodopa, tetrabenazine, and trihexyphenidyl were unsuccessful.

Case A-II-2: His 10-year-old brother (Fig. 1A) was born at 39 gestational weeks. He showed delayed gross motor milestones, including acquisition of sitting position at the age 1 year and independent walking at age 2 years. He also presented with slowly progressive abnormal posturing of his fingers and feet since early childhood. He suffered from social anxiety not requiring specific treatment. Examination (Video 1) revealed everted lower lip and large ears, dysarthria, generalized mobile dystonia with prominent facial grimacing and choreiform movements of

his distal limbs. He showed dystonic posturing of his left foot when walking. There were no concerns about his cognitive functions in view of his school performances. EEG and echocardiography were normal. Dystonia did not respond to trihexyphenidyl.

On WES, the proband was found to carry a novel homozygous nonsense variant NM_002143.3:c.49C>T p.(Arg17*) in *HPCA* residing within a 21 Mbp region of homozygosity (ROH; Fig. 1B). No pathogenic or likely pathogenic variants were found in other genes associated with neurological disorders. Segregation analysis revealed that his affected brother was homozygote, and their parents were heterozygotes for the same variant (Fig. 1A).

Pedigree B

Case B-II-1: A 35-year-old right-handed Iranian male (Fig. 1C) was born full term to a consanguineous couple. Pre- and perinatal history were uneventful. He had delayed motor milestones. At the age of 18 months, he started experiencing involuntary jerky head movements. Over few years, he developed dysarthria and generalized dystonia affecting his limbs and trunk. He had one younger brother in good health and one younger sister with a milder phenotype of choreo-dystonia. On examination (Video 2), he showed mild dysmorphic features (everted lower lip) and had dysarthria and generalized dystonia with choreiform movements mostly affecting the perioral region, upper limbs, and feet. His gait was mainly characterized by worsening of dystonic posturing of his trunk and upper limbs. Brain MRI and EEG were unremarkable. He had partial response to trihexyphenidyl and tetrabenazine.

Case B-II-3: His 21-year-old sister (Fig. 1C) was born full term after uncomplicated pregnancy and vaginal delivery. She had delayed motor milestones. She started manifesting involuntary jerky head movements at the age of 18 months with progression to choreo-dystonia affecting her upper body over few years. Her brain MRI and EEG were normal. She refused any pharmacological treatment.

WES revealed that the proband was homozygote for the nonsense variant NM_002143.3:c.49C>T p.(Arg17*) in *HPCA* within 44 Mbp region of homozygosity (Fig. 1D). No pathogenic or likely pathogenic variants were found in other genes associated with neurological disorders. Segregation analysis confirmed that his parents were heterozygotes, and his affected sister was homozygote for the same variant (Fig. 1C).

The *HPCA* variant hitherto reported has one heterozygous and no homozygous entries in GnomAD_v2/v3 (accessed on 09/July/2022), is absent from Iranome GME Variome and Queen Square Genomics database, is predicted pathogenic by in silico prediction tools, including a CADD score of 35.0, and is pathogenic according to the ACMG/AMP variant classification.¹¹ Haplotype analysis of the two probands (Fig. 1E) revealed only a narrow ROH of 200 Kbp with the same pattern of

TABLE 1 Phenotypic and genotypic features of cases of HPCA-related dystonia hitherto reported

References	Charlesworth et al., ¹ Khan et al., ⁴ and Bahint et al. ⁹		Charlesworth et al., ¹ Khan et al., ⁴ and Bahint et al. ⁹		Atasu et al. ⁵		Atasu et al. ⁵		Siegert et al. ⁶		Li et al. ⁷		This article		This article			
	Pedigree I	Pedigree II	Pedigree III	Pedigree IV	Pedigree V	Pedigree VI	Pedigree VII	Pedigree VIII	Pedigree IX	Pedigree X	Pedigree XI	Pedigree XII	Pedigree XIII	Pedigree XIV	Pedigree XV	Pedigree XVI		
Case	Case 1	Case 2	Case 3	Case 4	Case 5	Case 6	Case 7	Case 8	Case 9	Case 10	Case 11	Case 12	Case 13	Case 14	Case 15	Case 16		
Gender	F	M	F	F	M	M	M	M	F	F	M	M	M	M	M	F		
Age at onset dystonia	1 year	8 years	5 years	Late teens-Early 20s	8 months	17 years	N.A.	N.A.	11 years	N.A.	N.A.	N.A.	18 months	18 months	18 months	21 years		
Age last assessment	68 years	65 years	59 years	69 years	32 years	20 years	N.A.	N.A.	N.A.	N.A.	14 years	10 years	35 years	35 years	35 years	21 years		
Ethnicity	Sephardic Jewish	Sephardic Jewish	Sephardic Jewish	Sri Lankan	Turkish	Turkish	Turkish	Turkish	Turkish	N.A.	Iranian	Iranian	Iranian	Iranian	Iranian	Iranian		
Consanguinity	Yes	Yes	Yes	No	Yes	Yes	N.A.	N.A.	No	No	Yes	Yes	Yes	Yes	Yes	Yes		
Family history	Yes, Two siblings affected (Cases 2-3).	Yes, Two siblings affected (Cases 1-2).	Yes, Two siblings affected (Cases 1-2).	No	No	No	Yes, One brother and one niece affected (Cases 8-9).	Yes, One brother and one daughter affected (Cases 7-9).	Yes, Father and one paternal uncle affected (Cases 7-8).	Yes, One sibling affected (Case 11).	Yes, One sibling affected (Case 10).	Yes, One sibling affected (Case 14).	Yes, One sibling affected (Case 13).	Yes, One sibling affected (Case 13).	Yes, One sibling affected (Case 13).	Yes, One sibling affected (Case 13).	Yes, One sibling affected (Case 13).	
Perinatal history	N.A.	N.A.	N.A.	N.A.	N.A.	N.A.	N.A.	N.A.	IUGR, fetal distress	N.A.	IUGR, mild jaundice at birth	N.A.	N.A.	N.A.	N.A.	N.A.	N.A.	
Dysmorphic features	N.A.	N.A.	N.A.	N.A.	N.A.	N.A.	N.A.	N.A.	N.A.	N.A.	Everted lower lip, large ears, and S-shaped scoliosis	Everted lower lip and large ears	Everted lower lip	Everted lower lip	Everted lower lip	N.A.	N.A.	
Neurodevelopmental disorder	No	No	No	No	N.A.	Delayed motor and cognitive milestones	N.A.	N.A.	Delayed motor and speech milestones	Yes	Delayed gross motor milestones.	Delayed gross motor milestones.	Delayed gross motor milestones.	Delayed gross motor milestones.	Delayed gross motor milestones.	Delayed gross motor milestones.	Delayed gross motor milestones.	
Dystonia distribution at onset	Legs	Legs	Legs, face	Hands	Neck	Legs	N.A.	N.A.	Limbs	N.A.	Limbs	Limbs	Neck	Neck	Neck	Neck	Neck	
Neurological manifestations	Infantile seizures; generalized dystonia (mainly upper body)	Infantile seizures; generalized dystonia (mainly upper body)	Generalized dystonia (mainly upper body); cognitive dysfunction (anterior-subcortical areas)	Segmental dystonia; cognitive dysfunction	Generalized dystonia; dysphagia; cognitive dysfunction	Infantile seizures; generalized dystonia; learning disability	Intellectual disability; neck dystonia; dysarthria, jerky movements of the limbs	Intellectual disability; neck dystonia; dysarthria; hypomimia; neck dystonia; choreatic movements	Generalized dystonia; hypomimia; dysarthria; hypersalivation; cognitive dysfunction	Dyskinesia (not further specified)	Generalized choreo-dystonia	Generalized choreo-dystonia	Generalized choreo-dystonia	Generalized choreo-dystonia	Generalized choreo-dystonia	Choreo-dystonia with prominent involvement of the upper body	Choreo-dystonia with prominent involvement of the upper body	Choreo-dystonia with prominent involvement of the upper body
Other clinical manifestations	Anxiety Depression Pain	Anxiety Depression Pain	Anxiety Pain	Anxiety Depression Pain	N.A.	N.A.	N.A.	N.A.	N.A.	N.A.	Myopia Constipation	Anxiety Constipation	Pain	Pain	Pain	Pain	Pain	Pain
Brain MRI	Normal	Normal	Normal	Normal	Normal (except for sequelae of right pallidotomy)	Normal	N.A.	N.A.	Normal	Abnormal (not specified)	Normal	N.A.	Normal	Normal	Normal	Normal	Normal	Normal

(Continues)

TABLE 1 Continued

References	Charlesworth et al., ¹ Khan et al., ⁴ and Balint et al. ⁹	Charlesworth et al., ¹ Khan et al., ⁴ and Balint et al. ⁹	Charlesworth et al., ¹ Khan et al., ⁴ and Balint et al. ⁹	Atasu et al. ⁵	Atasu et al. ⁵	Siogert et al. ⁶	Li et al. ⁷	This article	This article
Other investigations	EEG: normal; NCS: reduced nerve conduction velocities; reduced levels of ARSA in fibroblasts and leucocytes; brown metachromatic granules in sural nerve biopsy (ARSA pseudodeficiency)	EEG: normal; NCS: reduced nerve conduction velocities; reduced levels of ARSA in fibroblasts and leucocytes; brown metachromatic granules in sural nerve biopsy (ARSA pseudodeficiency)	EEG: normal; NCS: reduced nerve conduction velocities; reduced levels of ARSA in fibroblasts and leucocytes; brown metachromatic granules in sural nerve biopsy (ARSA pseudodeficiency)	CSF analysis: normal; EEG: normal; neuropsychometry: normal at age 20; impaired verbal fluency and visuospatial abilities at age 26	CSF analysis: normal; EEG: normal; neuropsychometry: normal at age 20; impaired verbal fluency and visuospatial abilities at age 26	CSF analysis: normal; EEG: normal; neuropsychometry: normal at age 4; impaired verbal comprehension, working memory, reaction times, verbal fluency, and high amount of repetition errors at age 17.5	Neuropsychometry: N.A.; normal at age 4; impaired verbal comprehension, working memory, reaction times, verbal fluency, and high amount of repetition errors at age 17.5	EEG: normal; Echocardiography: small VSD (muscular)	EEG: normal; Echocardiography: normal
Response to treatment	No response to levodopa	No response to levodopa	No response to valproate, clonazepam, levodopa; partial transient response to right pallidotomy	No response to improvement with biperiden 12 mg/day	No response to improvement with biperiden 12 mg/day	No response to dopaminergic and anticholinergic treatment	Poor response to levodopa, tetraabenazine, trihexyphenidyl	Poor response to trihexyphenidyl	Partial response to tetraabenazine, trihexyphenidyl
Variants HPCA [NM_002143.3]	HOM c.225C>A p.(Asn75Lys)	HOM c.225C>A p.(Asn75Lys)	HOM c.208G>A p.(Trp103*)	HOM c.284delC p.(Gln11AspG*70) ^Δ	HOM c.182C>T p.(Ala61Val)	HOM c.182C>T p.(Ala61Val)	HOM c.209G>C p.(Arg70Pro)	HOM c.49C>T p.(Arg17*)	HOM c.49C>T p.(Arg17*)
			C-HET c.212C>A p.(Thr71Asn) c.568G>C p.(Ala190Thr)						HOM c.49C>T p.(Arg17*)

Abbreviations: ARSA, arylsulfatase A; CSF, cerebrospinal fluid; EEG, electroencephalography; EMG, electromyography; HET, heterozygote; HOM, homozygote; IUGR, intrauterine growth retardation; N.A., not available; NCS, nerve conduction studies; Nil, nothing; VSD, ventricular septal defect. ^Δ Reannotation of NM_002143.3(HPCA):c.G284del-C [p.P10PKTer80].⁵

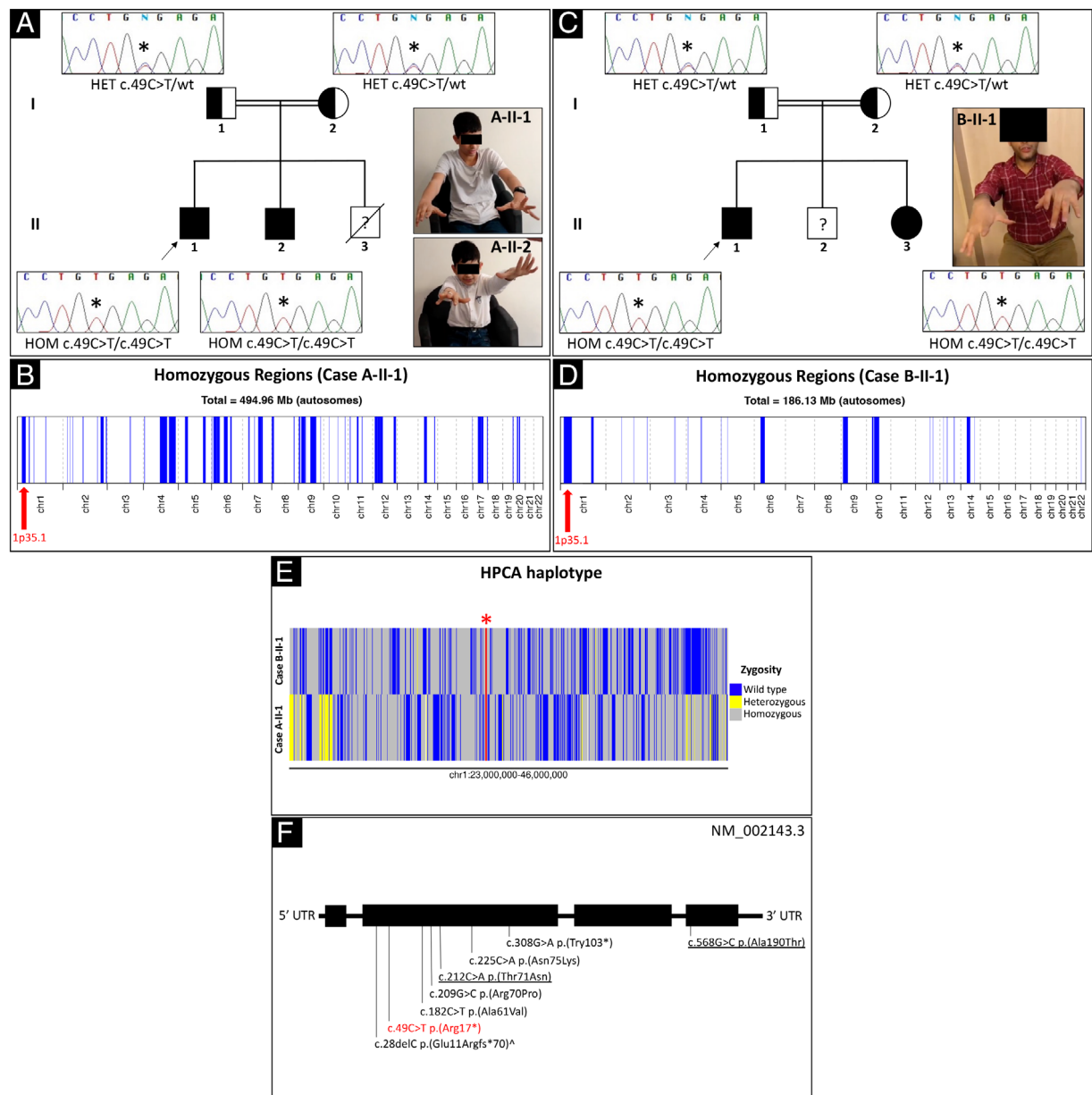
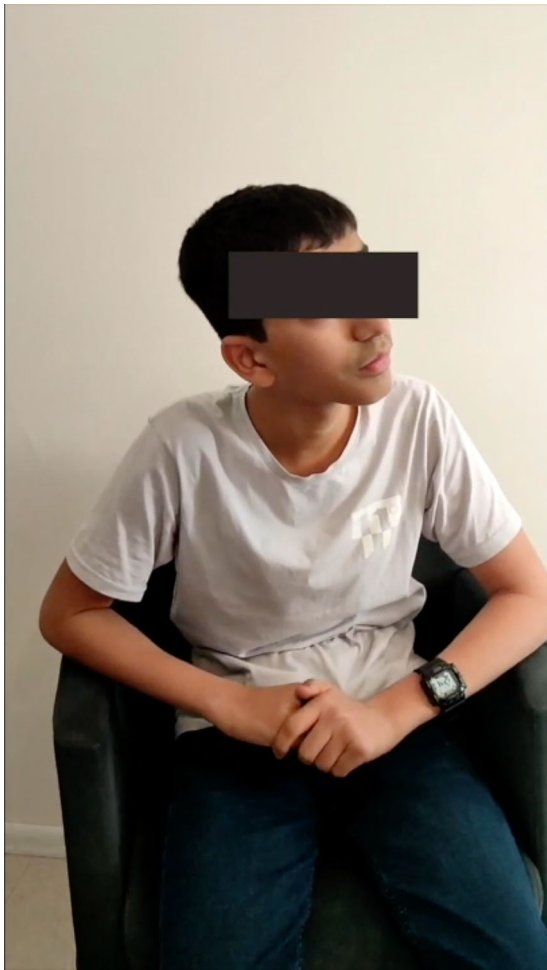

FIG. 1. (A) Family tree of pedigree a, segregation analysis of the *HPCA* variant NM_002143.3:C.49C>T p.(Arg17*), and video frames showing the proband (A-II-1) and his affected brother (A-II-2) with prominent upper limb dystonia. The DNA region of interest was amplified bidirectionally using the following primers (5' → 3'): F-caacaagaggcagggatgg and R-ggggtaagggccaatgttc, with an amplicon size of 821 base pairs (bp). Chromatograms were analyzed using the Sequencher software package. (B) Regions of homozygosity (ROH) encompassing the *HPCA* variant identified by processing the VCF file from Case A-II-1's exome sequencing data through AutoMap (<https://automap.iob.ch/>).¹⁰ *HPCA* lies in a 21 Mbp ROH (GCh38 genomic coordinates chr1:24095460–45,206,294) on chromosome 1p35.1 (red arrow). (C) Family tree of pedigree B, segregation analysis of the *HPCA* variant NM_002143.3:C.49C>T p.(Arg17*), and video frame showing the proband (B-II-1) with prominent oromandibular and upper limb dystonia. Sanger sequencing was performed and visualized as reported above. (D) ROH encompassing the *HPCA* variant identified by processing the VCF file from Case B-II-1's exome sequencing data as reported above.¹⁰ *HPCA* lies in a 44 Mbp ROH (GCh38 genomic coordinates: chr1:18377050–62,263,112) on chromosome 1p35.1 (red arrow). (E) Haplotyping revealed different haplotypes around the *HPCA* variant (GCh38 genomic coordinates: chr1:32,800,000–33,000,000). (F) Schematic of the *HPCA* gene with variants hitherto reported, including the novel one reported in the present article (highlighted in red); all variants were reported in the homozygous state except for the underlined variants, which were reported in compound heterozygosity.¹ ^ Reannotation of NM_002143(*HPCA*):C.G28del-C [p.P10PfsTer80].⁵ Arrow, proband; HET, heterozygote; HOM, homozygote; wt, wild type; ?, unknown genotype.



Video 1. Pedigree A. *First segment.* The proband (Case A-II-1, age 14) showing generalized choreo-dystonia with prominent acral involvement and mobile facial grimacing. When walking, he presented with mild dystonic trunk tilt and mild dystonic posturing of the feet. During writing, there was dystonic posturing of the right hand with motor overflow to the left hand. *Second segment.* The proband's younger brother (Case A-II-2, age 10) showing generalized choreo-dystonia with prominent acral involvement and mobile facial grimacing, the latter being mainly present on action. He also presented with mild dystonic trunk tilt and dystonic posturing of the feet (right > left) when walking. He had dystonic posturing of the right hand with minimal motor overflow to the left hand when writing.



Video 2. Pedigree B. The proband (Case B-II-1, age 35) showing mild dysmorphic features (everted lower lip) and generalized dystonia with choreiform movements mostly affecting the perioral region, upper limbs, and feet. His gait was mainly characterized by worsening of dystonic posturing of his trunk and upper limbs. During writing, there was dystonic posturing of the right hand with motor overflow to the left hand.

variants in the probands of the two families. Shared variants within this region all have high frequency in both gnomAD and our genetic datasets, suggesting that this *HPCA* variant is not a founder mutation in these cases.

By screening our dataset of 23,741 exomes (522 subjects with diagnostic category “dystonia”) and the 100,000 Genomes Project repository (1116 participants enrolled using the *Human Phenotype Ontology* term “dystonia”), we identified only two additional *HPCA* cases from one pedigree previously published.¹

Literature Review

Articles published since 2015 (disease gene discovery) were identified by systematically searching PubMed on July 09 2022. There was no language restriction. The search strategy was “HPCA AND dystonia” (14 results), “HPCA AND movement disorder” (10 results), “hippocalcin AND dystonia” (13 results) and “hippocalcin AND movement disorder” (10 results), with deduplication resulting in 18 references. Reference list of relevant articles and online first publications were also reviewed.

Along with new *HPCA* cases herein described, 14 subjects (eight males, six females) from eight pedigrees of Sephardic Jewish, Sri Lankan, Turkish and Iranian origin outline *HPCA*-related

dystonia as being isolated or variously combined with neurodevelopmental delay, intellectual disability, infantile seizures, chorea, mild dysmorphic features, cognitive decline, pain, and psychiatric comorbidity (Table 1). Neurodevelopmental milestones, in particular gross motor achievements, were delayed in seven cases. Age of dystonia onset ranges from infancy to early adulthood. Dystonia starts in the limbs or neck and mainly affects the perioral, cervical, and upper limb regions, becoming generalized in most cases. Brain MRI was unremarkable in 10 out of 11 cases where performed. Dystonia shows poor or no response to oral antidystonic drugs. Eight *HPCA* variants, including five missense and three loss-of-function (LOF) variants, have been linked to dystonia, all but one located in exon 2 of the gene (Fig. 1E).

Discussion

Our case series expand the pheno-genotypic spectrum of *HPCA*-related disorder. First, these new cases document the novel association of biallelic *HPCA* variants and choreo-dystonia. Occurrence of choreatic movements along with dystonia is consistent with evidence of striatal dysfunction in *HPCA*-related disorder.¹² Functional studies recently proved that the dystonia-linked *HPCA* variant p.Asn75Lys¹ prevents suppression of neuronal activity via slow afterhyperpolarization, which results in increased neuronal excitability of striatal neurons and altered synaptic plasticity likely through a LOF mechanism.¹² Interestingly, hippocampin expression is reduced in mouse models of Huntington disease (HD) at clinical onset and in human HD brain.^{13,14} Long-term follow-up and neuropathology may establish if *HPCA* LOF variants cause neurocognitive decline/neurodegeneration directly or by influencing *HPCA* downstream effectors. Overall, our case series with *HPCA*-related childhood-onset choreo-dystonia support the inclusion of *HPCA* in the diagnostic workup of genetically unexplained early-onset chorea associated with dystonic features, with this phenotype having previously been associated with autosomal dominant disorders due to variants in *NKX2-1*, *ADCY5* (where facial/perioral twitching is a common manifestation as observed in *HPCA*-related disorder),^{15,16} *PDE10A*,¹⁷ *DRD2*^{18,19} as well as autosomal recessive *PDE2A*-related disorder.²⁰ Second, we report a novel pathogenic *HPCA* variant which recurs in two families without evidence of being a founder variant. Although the limited number of *HPCA* cases reported so far hampers genotype-phenotype correlations, our cases suggest that truncating variants in *HPCA* might invariably be associated with neurodevelopmental delay preceding the onset of dystonia in early childhood. Third, we suggest that exon 2 of *HPCA* can represent a mutational hotspot. Finally, we confirmed that biallelic *HPCA* variants represents a very rare dystonia etiology.

Acknowledgment

The authors would like to thank the patients and their families for participating in this study.

Author Roles

(1) Research Project: A. Conception, B. Organization, C. Execution. (2) Data Analysis: A. Design, B. Execution, C. Review and Critique. (3) Manuscript Preparation: A. Writing of the first draft, B. Review and Critique.

F.M.: 1A, 1B, 1C, 2A, 2B, 3A

K.P.B.: 1C, 2C, 3B

M.B.T.: 1C, 2C, 3B

F.A.: 1C, 2C, 3B

E.G.K.: 1C, 2C, 3B

S.S.: 1C, 2C, 3B

B.A.: 1C, 2C, 3B

M.N.: 1C, 2C, 3B

C.R.: 1C, 2C, 3B

H.H.: 1C, 2C, 3B

R.M.: 1A, 1B, 1C, 2C, 3B.

Disclosures

Ethical Compliance Statement: We confirm that we have read the Journal's position on issues involved in ethical publication and affirm that this work is consistent with those guidelines. The authors confirm that the approval of an institutional review board was not required for this work. We confirm that the patients' parents of pedigree A and the patients of pedigree B provided consent for genetic testing on a research basis. The patients' parents of pedigree A and the proband of pedigree B also provided consent for video acquisition and publication.

Funding Sources and Conflicts of Interest: Biological samples of pedigree A were collected as part of the SYNAPS Study Group collaboration funded by The Wellcome Trust and strategic award (Synaptopathies) funding (WT093205MA and WT104033AIA) and research was conducted as part of the Queen Square Genomics group at University College London, supported by the National Institute for Health Research University College London Hospitals Biomedical Research Centre. The authors declare that there are no conflicts of interest relevant to this work.

Financial Disclosures for the Previous 12 Months: Francesca Magrinelli is supported by the Michael J. Fox Foundation and Edmond J. Safra Foundation. Kailash P. Bhatia has received grant support from Wellcome/MRC, NIHR, Parkinson's UK and EU Horizon 2020. He receives royalties from publication of the Oxford Specialist Handbook Parkinson's Disease and Other Movement Disorders (Oxford University Press, 2008), of Marsden's Book of Movement Disorders (Oxford University Press, 2012), and of Case Studies in Movement Disorders—Common and uncommon presentations (Cambridge University Press, 2017). He has received honoraria/personal compensation for participating as consultant/scientific board member from Ipsen, Allergan, Merz and honoraria for speaking at meetings and from Allergan, Ipsen, Merz, Sun Pharma, Teva, UCB Pharmaceuticals

and from the American Academy of Neurology and the International Parkinson's Disease and Movement Disorders Society. Henry Houlden is funded by The MRC (MR/S01165X/1, MR/S005021/1, G0601943), The National Institute for Health Research University College London Hospitals Biomedical Research Centre, Rosetree Trust, Ataxia UK, MSA Trust, Brain Research UK, Sparks GOSH Charity, Muscular Dystrophy UK (MDUK), Muscular Dystrophy Association (MDA USA), Mehran Beiraghi Toosi, Fatemeh Arab, Ehsan Ghayoor Karimiani, Sahar Sedighzadeh, Behnaz Ansari, Maedeh Neshatdoust, Clarissa Rocca, and Reza Maroofian have no disclosures to declare. ■

References

- Charlesworth G, Angelova PR, Bartolome-Robledo F, et al. Mutations in HPCA cause autosomal-recessive primary isolated dystonia. *Am J Hum Genet* 2015;96(4):657–665.
- Dobricic V, Kresojevic N, Marjanovic A, et al. HPCA-related dystonia: too rare to be found? *Mov Disord* 2016;31(7):1071.
- Carecchio M, Reale C, Invernizzi F, et al. DYT2 screening in early-onset isolated dystonia. *Eur J Paediatr Neurol* 2017;21(2):269–271.
- Khan NL, Wood NW, Bhatia KP. Autosomal recessive, DYT2-like primary torsion dystonia: a new family. *Neurology* 2003;61(12):1801–1803.
- Atasu B, Hanagasi H, Bilgic B, et al. HPCA confirmed as a genetic cause of DYT2-like dystonia phenotype. *Mov Disord* 2018;33(8):1354–1358.
- Siegert S, Schmidt WM, Pletschko T, Bittner RE, Gobara S, Freilinger M. Specific cognitive changes due to Hippocalcin alterations? A novel familial homozygous Hippocalcin variant associated with inherited dystonia and altered cognition. *Neuropediatrics* 2021;52(5):377–382.
- Li N, Zhou P, Tang H, et al. In-depth analysis reveals complex molecular aetiology in a cohort of idiopathic cerebral palsy. *Brain* 2022;145(1):119–141.
- Helassa N, Antonyuk SV, Lian LY, Haynes LP, Burgoyne RD. Biophysical and functional characterization of hippocalcin mutants responsible for human dystonia. *Hum Mol Genet* 2017;26(13):2426–2435.
- Balint B, Charlesworth G, Erro R, Wood NW, Bhatia KP. Delineating the phenotype of autosomal-recessive HPCA mutations: not only isolated dystonia! *Mov Disord* 2019;34(4):589–592.
- Quinodoz M, Peter VG, Bedoni N, et al. AutoMap is a high performance homozygosity mapping tool using next-generation sequencing data. *Nat Commun* 2021;12(1):518.
- Richards S, Aziz N, Bale S, et al. Standards and guidelines for the interpretation of sequence variants: a joint consensus recommendation of the American College of Medical Genetics and Genomics and the Association for Molecular Pathology. *Genet Med* 2015;17(5):405–424.
- Osyenko DS, Dovgan AV, Kononenko NI, et al. Perturbed Ca²⁺-dependent signaling of DYT2 hippocalcin mutant as mechanism of autosomal recessive dystonia. *Neurobiol Dis* 2019;132:104529.
- Rudinskiy N, Kaneko YA, Beesen AA, Gokce O, Régulier E, Déglon N, Luthi-Carter R. Diminished hippocalcin expression in Huntington's disease brain does not account for increased striatal neuron vulnerability as assessed in primary neurons. *J Neurochem* 2009;111(2):460–472.
- Luthi-Carter R, Hanson SA, Strand AD, et al. Dysregulation of gene expression in the R6/2 model of polyglutamine disease: parallel changes in muscle and brain. *Hum Mol Genet* 2002;11(17):1911–1926.
- Chen YZ, Matsushita MM, Robertson P, et al. Autosomal dominant familial dyskinesia and facial myokymia: single exome sequencing identifies a mutation in adenylyl cyclase 5. *Arch Neurol* 2012;69(5):630–635.
- Carapito R, Paul N, Untrau M, et al. A de novo ADCY5 mutation causes early-onset autosomal dominant chorea and dystonia. *Mov Disord* 2015;30(3):423–427.
- Mencacci NE, Kamsteeg EJ, Nakashima K, et al. De novo mutations in PDE10A cause childhood-onset chorea with bilateral striatal lesions. *Am J Hum Genet* 2016;98(4):763–771.
- van der Weijden MCM, Rodriguez-Contreras D, Delnooz CCS, et al. A gain-of-function variant in dopamine D2 receptor and progressive chorea and dystonia phenotype. *Mov Disord* 2021;36(3):729–739.
- Mencacci NE, Steel D, Magrinelli F, et al. Childhood-onset chorea caused by a recurrent de novo DRD2 variant. *Mov Disord* 2021;36(6):1472–1473.
- Salpietro V, Perez-Duenas B, Nakashima K, et al. A homozygous loss-of-function mutation in PDE2A associated to early-onset hereditary chorea. *Mov Disord* 2018;33(3):482–488.