

BMJ Case Reports

Scurvy presenting primarily as gingival manifestation in a young child:A diagnostic dilemma

Journal:	<i>BMJ Case Reports</i>
Manuscript ID	bcr-2022-249113.R1
Manuscript Type:	Case report
Date Submitted by the Author:	13-Apr-2022
Complete List of Authors:	Chaluvaraj, Rashmi; CNWL, Buckinghamshire Priority Dental Service; Buckinghamshire Priority Dental Service Ashley, Paul; UCL Eastman Dental Institute, Paediatric Dentistry Parekh, Susan; UCL Eastman Dental Institute, Paediatric Dentistry
Keywords:	Mouth, Vitamins and supplements < Nutrition and metabolism, Dentistry and oral medicine, Diet < Nutrition and metabolism

SCHOLARONE™
Manuscripts

BMJ Case Reports

BMJ Case Reports

TITLE OF CASE

Scurvy presenting primarily as gingival manifestation in a young child: A diagnostic dilemma

SUMMARY

Vitamin C deficiency, historically known as Scurvy was associated with sailors in the Victorian times, however, a global review in 2020 suggests it still exists in certain at-risk groups.

A case is presented of a young non-verbal child with learning difficulties and on a restricted diet, in which the primary symptom was gingival inflammation. It posed a diagnostic dilemma due to the non-specific symptoms, until vitamin C deficiency was confirmed.

Gingival inflammation is one of the common findings in vitamin C deficiency and dental professionals may be the first point of contact. The importance of dietary evaluation, identifying and looking for other signs and liaising with the medical colleagues are discussed.

Conclusion: This case highlights the role of the dentist in identifying latent cases of vitamin C deficiency and to consider this as a differential diagnosis especially in certain at-risk groups.

BACKGROUND

Vitamin C deficiency has been historic, however a 2008 UK survey revealed that 25% men and 14% of women from low-income populations had vitamin C deficiency ($<11\mu\text{mol/L}$) and a further 20% of the population being vitamin C deplete ($11\text{--}28\mu\text{mol/L}$).^[1] A recent review of global vitamin C status indicated a high prevalence of Vitamin C deficiency in individuals with lower socioeconomic status or higher deprivation particularly in low- and middle-income countries.² The National Diet and Nutrition Surveys (2008–2017) have shown a significant 6% increase in vitamin C deficiency over the nine-year period in women aged 19–64. [2]

Certain risk groups are associated with dietary insufficiency of Vitamin C, such as alcoholics with poor diets, babies purely fed on cow's milk, individuals with eating disorders or restrictive diets, food allergies, children with autistic spectrum disorders with a limited food repertoire and individuals in nursing homes or care homes over the age of 65.[3,4,5,6] Vitamin C deficiency can be due to an underlying primary disease such as inflammatory bowel disease, individuals with iron overload which leads to wasting of vitamin C by kidneys, Type 1 diabetes who have higher vitamin C requirements and not necessarily due to lack of vitamin C in their diet. [7]

CASE PRESENTATION

A young Asian boy with severe learning difficulties, non-verbal and a wheel chair user, presented to the clinic with his mother and father. His mother was the main carer with limited understanding of English, and father gave the history. Their main concern was their son's swollen, bleeding gums, which had been present for two to three weeks. As tooth brushing was generally difficult, his parents assumed the bleeding gums was related to that and would resolve, but his condition had worsened and his mother stated that his behaviour had changed and he was more lethargic. They reported that his appetite was reduced. The patient showed signs of discomfort and his mother recognised that he was in pain and gave him analgesics regularly. They did not feel that his gums had been swollen before. The medical history included Cerebral Palsy with mixed tone pattern and truncal hypotonia, global developmental delay; non-verbal, central visual impairment well controlled Epilepsy, Beta Thalassemia trait. Medication included Levetiracetam 100mg twice daily and allergy to chicken and egg products. The diet was mainly pureed due to swallowing difficulties including supplements like pediasure and a cooked lentil diet. Toothbrushing was carried out by his mother twice daily using fluoridated toothpaste.

The patient had been seen by the Community Dental Service pre-covid. There were deposits of calculus, which were removed by hand scaling of his teeth due to limited co-operation, and appropriate oral hygiene instructions were advised. The follow up recall appointment did not take place due to Covid 19. The child lived with his mother and father and had two other siblings and attended a special needs school but was cared for at home due to covid restrictions at that time. The patient was examined in his wheelchair assisted by his mum. Extra-oral lymph nodes were not palpable and no other abnormalities were evident. However, he appeared very weak. Intra-orally, examination was limited. Clinical examination revealed generalised erythematous swollen marginal gingiva involving the interdental papilla and extending to mucogingival junction. The consistency was spongy but palatally appeared like large gingival finger-like swellings with spontaneous bleeding. It was extremely tender to touch. Some calculus deposits were visible and the gingiva appeared to be detached. The vestibule and the tongue were not affected. No obvious ulceration evident upon examination (figure 1).

Fig 1A and Fig 1B: A clinical photograph at the time of presentation showing erythematous gingival enlargement and picture on the left showing palatal gingival enlargement appearing like finger like projections.

Treatment on that day was limited to the anterior teeth only due to limited co-operation. The gingiva was gently wiped using gauze soaked with chlorhexidine -0.2% mouthwash. This simple treatment involved lot of bleeding and had to use four extraction packs to stop the bleeding. Parents were given oral hygiene instructions, to use a soft toothbrush and prescribed 0.2% chlorhexidine mouthwash. The child could not rinse and parents were advised to use a gauze. They were advised to hydrate with fluids and to use analgesic prior to feeding the child to minimise discomfort. They were also advised to seek A & E assistance if child becomes very unwell. The patient was referred to his General medical practitioner and Oral Medicine department urgently for haematological investigations.

INVESTIGATIONS

Table 1: Results of haematological investigations

Investigation	Result	Reference range
Red blood cell count	3.90 x10 ¹² /L	4.0-5.2/10 ¹² L
Total white blood count	6.3x10 ⁹ /L	3.7-13 x10⁹/L
Platelets	413 x10 ⁹ /L	180.0-450.0 x10 ⁹ /L
Haemoglobin concentration	69.0 g/L Below low reference unit	115.0-155.0g/L
Vit C level	<2.4 µmol	26.1-84 µmol
Serum 25-Hydroxy Vitamin D3 level	21.7nmol/L	Less than 25nmol/L; Vit D deficiency

DIFFERENTIAL DIAGNOSIS

The differential diagnosis included Necrotising ulcerative gingivitis, acute herpetic gingivostomatitis due to the severity of the inflammation, leukaemia, desquamative gingivitis seen in immune-mediated and autoinflammatory gingival lesions, and gingival hyperplasia due to anti-epileptic medication [8] presenting as reactive hyperplastic tissue, bleeding disorders. Following immediate referral to Oral Medicine colleagues and his General Medical Practitioner, he was admitted to hospital for further investigations. The initial blood tests revealed very low haemoglobin levels, so an initial diagnosis of iron deficiency anaemia was made. Leukaemia was ruled out as white blood cell count and platelet count was in the normal range. His condition did show some improvement with antibiotics but the gingival inflammation persisted. Later, testing of vitamin C levels revealed severe Vitamin C deficiency; less than 2.4 µmol. He was admitted for a total of 10 days.

TREATMENT

The patient received ascorbic acid tablets (250 mg) for a week and showed remarkable gingival improvement with in few days of treatment. There was a concomitant vitamin D deficiency as well. He was also prescribed Colecalciferol liquid (Vitamin D deficiency) 6000 units once a day and Sodium feredetate (Iron deficiency anaemia) 190mg/5mLoral solution sugar free for four months.

OUTCOME AND FOLLOW-UP

Review four weeks later in dental clinic, showed spontaneous resolution of the gingival tissues (figure 2).Follow-up two months later in clinic did not show any recurrence.He had regular follow-up appointments with his Paediatrician and Dietician to improve his diet.

Fig.2 Clinical photograph four weeks from the time of diagnosis, after scaling of teeth

DISCUSSION

This case demonstrated Vitamin C deficiency presenting with gingival manifestations due to restricted dietary intake. Other symptoms such as pain in the limbs and difficulty in walking were not possible to assess as the child was non-verbal and non-mobile. Vitamin C deficiency manifestations are mainly associated with defective collagen synthesis and hence increased vascular fragility leads to a bleeding tendency which produces petechiae and ecchymosis.

In hindsight, a thorough dietary history would have given more information. His mother reported that he was mostly bottle-fed until the age of five due to difficulties with swallowing. A 5 day diet sheet showed severely restricted food intake, with allergy to egg products and chicken limiting his diet. He was fed cereals for breakfast and although his meals included cooked rice and lentils, there was no mention of fruits or juices in his diet. Liaison with the dietician revealed that his mother was boiling the lentils with vegetables at a high temperature to suit a pureed diet due to his swallowing difficulties; Vitamin C being thermo-labile was destroyed at high temperature, which lowered the nutritive value. His siblings did not have any reported problems as they had a more varied diet and no underlying medical problems.

Page 5 of 10 Studies have investigated oral manifestations of scurvy in children with neuro-developmental disorders, suggesting that in those with medical or developmental conditions like autistic spectrum disorders[9,10,11,12] maybe a presentation due to a restricted diet or food selectivity. They identified gingival swelling,pain,and bleeding as the classic oral features of scurvy.Limp, leg pain and refusal to walk, anaemia were some of the other common findings in these studies. A Canadian study cited that Scurvy should be a 'never event' in a healthy society and that a confident diagnosis of scurvy was only made in 12 cases out of a total of 58 admissions. [13] In a more recent systematic review of literature by Gicchino et al in 2021 showed that 51% of patients presenting with scurvy were affected by neurodevelopmental disorders and 83% of these patients, presented with oral manifestations. The most common oral manifestation cited in their review were gingival bleeding, swelling, and hypertrophy. [14]

As oral manifestation is a common presenting feature in scurvy, we would like to highlight that dentists are in a unique position to identify nutritional deficiencies in children especially in children with learning difficulties on a limited food repertoire and in those described as picky or fussy eaters. It is important to be vigilant and look for signs and symptoms of nutritional deficiencies through dietary evaluation.

We would also like to remind medical professionals to consider Scurvy as a potential diagnosis whilst evaluating patients with both musculo-skeletal and cutaneous manifestations, to enquire for the common oral manifestations; to aid prompt diagnosis of Vitamin C deficiency. Vitamin C deficiency still exists and as clinicians we should be aware of the early oral, cutaneous and musculo-skeletal manifestations, especially in children with autism and developmental disorders and liaise with medical professionals to avoid the delay in diagnosis.Nonaccidental injuries should be considered in any case of bony pain and unexplained bleeding, and rule out physical injuries due to child abuse.

Hence this case presentation is to promote awareness among dentists and medical teams regarding nutritional deficiencies such as vitamin C presenting with non-specific symptoms and to consider this in our differential diagnosis.

LEARNING POINTS/TAKE HOME MESSAGES

- Scurvy is still prevalent in certain risk groups
- Presents a clinical case in a young child with non-specific symptoms and the importance to identify similar cases in their own practice
- To include vitamin C deficiencies as a differential diagnosis in cases of gingival enlargement
- Highlights the importance of dentist in recognising this deficiency using dietary evaluation
- Early recognition to aid simple treatment preventing time-consuming tests and procedures

REFERENCES

1. Mosdol A, Erens B, Brunner EJ. Estimated prevalence and predictors of vitamin C deficiency within UK's low-income population, *Journal of Public Health*, 2008; **30**, (4):456–460, <https://doi.org/10.1093/pubmed/fdn076>.
2. Carr AC, Rowe S. Factors Affecting Vitamin C Status and Prevalence of Deficiency: A Global Health Perspective. *Nutrients*. 2020 Jul 1; **12**(7):1963. doi: 10.3390/nu12071963. PMID: 32630245; PMCID: PMC7400679.
3. Griffiths JK. Vitamin deficiencies. In: Magill AJ, Hill DR, Solomon T, Ryan ET. *Hunters Tropical Medicine and Emerging Infectious Disease*. 2013 (Ninth Edition). Amsterdam: Elsevier BV. 997-1002. <https://doi.org/10.1016/B978-1-4160-4390-4.00139-9>.
4. Bates CJ, Prentice A, Cole TJ, van der Pols JC, Doyle W, Finch S, et al. Micronutrients: highlights and research challenges from the 1994-5 National Diet and Nutrition Survey of people aged 65 years and over. *Br J Nutr*. 1999 Jul; **82**(1):7-15. doi: 10.1017/s0007114599001063. PMID: 10655951.
5. Bailey AL, Maisey S, Southon Wright AJA, Finglas PM, Fulcher RA. Relationships between micronutrient intake and biochemical indicators of nutrient adequacy in a 'free-living' elderly UK population. *British Journal of Nutrition* 1997; **77**(2):225-42.
6. Bandini LG, Anderson SE, Curtin C et al. Food selectivity in children with autism spectrum disorders and typically developing children. *J Pediatr*. 2010 Aug; **157**(2):259-64. doi: 10.1016/j.jpeds.2010.02.013. Epub 2010 Apr 1. PMID: 20362301; PMCID: PMC2936505.
7. Maxfield L, Crane JS. Vitamin C Deficiency. 2020; Jul 2. In: *Stat Pearls* [Internet]. Treasure Island (FL): StatPearls Publishing; 2021 Jan–. PMID: 29630239.
8. Aruna H, Abe J, Hane Y et al .Drug-induced gingival hyperplasia: a retrospective study using spontaneous reporting system databases. *Journal of Pharmaceutical Health Care and Sciences*. 2017; **3** : (**19**). DOI 10.1186/s40780-017-0088-5.19. Ma NS, Thompson C, Weston S. Brief Report: Scurvy as a Manifestation of Food Selectivity in Children with Autism. *J Autism Dev Disord*. 2016 Apr; **46**(4):1464-70. doi: 10.1007/s10803-015-2660-x. PMID: 26590972.

9. Tanoue K, Takamasu T, Matsui K. Food repertoire history in children with autism spectrum disorder in Japan. *Pediatrics International* 2016.<https://doi-org.libproxy.ucl.ac.uk/10.1111/ped.13160>.

10. Kothari P, Tate A, Adewumi A, Kinlin LM, Ritwik P. The risk of scurvy in children with neurodevelopmental disorders. *Spec Care Dentist*.2020; **40**:251-259.

11. Madaan P, Krishnappa A, Yadav J, Saini L. Selective Eating: A common Fuss in Neurodevelopmental Disorders *Pediatr Neurol*. 2019; 95:90.

12. Demartini B, Nisticò V, Bertino V et al Eating disturbances in adults with autistic spectrum disorder without intellectual abilities. *Autism research*. March 2021.<https://doi-org.libproxy.ucl.ac.uk/10.1002/aur.2500>.

13. Dadgar, K., Neary, J. Clinical Profile of Scurvy in Hamilton Since 2009: a Cohort Study. *J Gen Intern Med* **36**, 230–231 (2021). <https://doi.org/10.1007/s11606-020-05636-1>

14.Gicchino MF, Romano A, Cioffi S, Fiori F, Miraglia del Giudice E, Lucchese A, Olivieri AN, Serpico R. Oral Manifestations in Scurvy Pediatric Patients: A Systematic Review and a Case Report. *Applied Sciences*. 2021; 11(18):8323. <https://doi.org/10.3390/app11188323>

FIGURE/VIDEO CAPTIONS

Fig 1A and Figure 1B: A clinical photograph at the time of presentation showing erythematous gingival enlargement and picture on the left showing palatal gingival enlargement appearing like finger like projections.


Fig 2: Clinical photograph four weeks from the time of diagnosis, after scaling of teeth

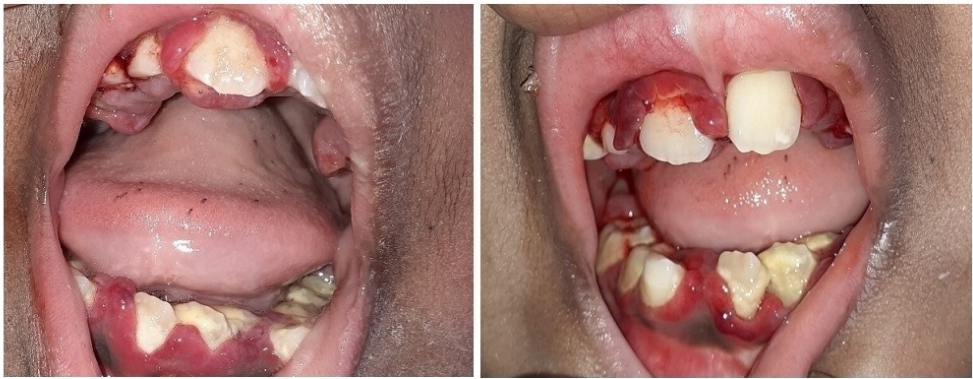PATIENT’S PERSPECTIVE

n/a

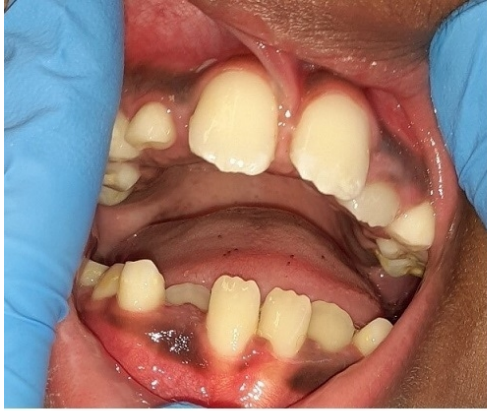I, **[Rashmi Chaluvraj]**, the Author has the right to grant and does grant on behalf of all authors, an exclusive licence and/or a non-exclusive licence for contributions from authors who are: i) UK Crown employees; ii) where BMJ has agreed a CC-BY licence shall apply, and/or iii) in accordance with the relevant stated licence terms for US Federal Government Employees acting in the course of the their employment, on a worldwide basis to the BMJ Publishing Group Ltd (“BMJ”) and its licensees, to permit this Work (as defined in the below licence), if accepted, to be published in BMJ Case Reports and any other BMJ products and to exploit all rights, as set out in our licence [author licence](#).

Date:27/01/2022





86x64mm (300 x 300 DPI)



86x64mm (300 x 300 DPI)