




Treatment Strategies for Central Nervous System Effects in Primary and Secondary Haemophagocytic Lymphohistiocytosis in Children

Samantha Cooray, MB BS, PhD¹
Saraswathy Sabanathan, MB BS, PhD²
Yael Hacohen, MB BS, PhD^{1,2,3}
Austen Worth, MB BS, PhD⁴
Despina Eleftheriou, MB BS, PhD¹
Cheryl Hemingway, MB ChB, PhD^{1,2,*} 

Address

^{1,1}Infection, Immunity, and Inflammation Department, University College London
Great Ormond Street Institute of Child Health, 30 Guilford Street, London WC1N1EH,
UK

Email: Cheryl.Hemingway@gosh.nhs.uk

²Department of Paediatric Neurology, Great Ormond Street Hospital for Children,
London, UK

³Department of Neuroinflammation, Queen Square Multiple Sclerosis Centre, UCL
Institute of Neurology, London, UK

⁴Department of Paediatric Immunology, Great Ormond Street Hospital for Children,
NHS Foundation Trust, London, UK

© The Author(s) 2022

This article is part of the Topical Collection on *Multiple Sclerosis and Related Disorders*

Samantha Cooray and Saraswathy Sabanathan shared first authorship

Keywords Hemophagocytic lymphohistiocytosis (HLH) · Central nervous system (CNS) · Biologics

Abstract

Purpose of Review This review presents an appraisal of current therapeutic options for the treatment of central nervous system haemophagocytic lymphohistiocytosis (CNS-HLH)

in the context of systemic disease, as well as when CNS features occur in isolation. We present the reader with a diagnostic approach to CNS-HLH and commonly used treatment protocols. We discuss and evaluate newer treatments on the horizon.

Recent Findings Mortality is high in patients who do not undergo HSCT, and while larger studies are required to establish benefit in many treatments, a number of new treatments are currently being evaluated. Alemtuzumab is being used as a first-line treatment for CNS-HLH in a phase I/II multicentre prospective clinical trial as an alternative to traditional HLH-1994 and 2004 protocols. It has also been used successfully as a second-line agent for the treatment of isolated CNS-HLH that is refractory to standard treatment. Ruxolitinib and emapalumab are new immunotherapies that block the Janus kinase—Signal Transducer and Activator of Transcription (JAK-STAT) pathway that have shown efficacy in refractory HLH, including for CNS-HLH disease.

Summary Treatment of CNS-HLH often requires HLH-94 or 2004 protocols followed by haematopoietic stem cell transplantation (HSCT) to maintain remission, although relapse can occur, particularly with reduced intensity conditioning if donor chimerism falls. CNS features have been shown to improve or stabilise following HSCT in CNS-HLH in the context of systemic disease and in isolated CNS-HLH. Encouraging reports of early cohort studies suggest alemtuzumab and the Janus kinase (JAK) inhibitor ruxolitinib offer potential salvage therapy for relapsed and refractory CNS-HLH. Newer immunotherapies such as tocilizumab and natalizumab have been shown to be beneficial in sporadic cases. CNS-HLH due to primary gene defects may be amenable to gene therapy in the future.

Introduction

Haemophagocytic lymphohistiocytosis (HLH) represents a type of cytokine storm syndrome, characterised by uncontrolled inflammation and immune dysregulation, which can be fatal [1–4]. Clinical features include unremitting fever, hepatosplenomegaly, and cytopenias as well as central nervous system sequelae [3, 5, 6]. HLH may be classified as either primary (inherited) or secondary (acquired). Familial HLH (fHLH) is a form of primary HLH that normally presents in early childhood and is caused by inherited autosomal recessive bi-allelic mutations in genes encoding proteins that regulate granule-dependent cytotoxicity of cytotoxic T lymphocytes (CTLs) and natural killer (NK) cells (types 2–5, Table 1) [2, 5, 7]. In these conditions, HLH is usually the predominant or only clinical abnormality, and patients with these genetic mutations have a very high risk of developing HLH. Heterozygous defects in two or more of these genes may also cause synergistic deleterious effects which can also lead to HLH, although the onset is commonly later in childhood [8]. Primary HLH can

also be seen in primary immunodeficiency disorders (PID) where the susceptibility to HLH is more variable, and is usually associated with other immunological defects (susceptibility to chronic infection, autoimmunity). Some of these disorders also affect cytotoxic cell function, such as Chediak-Higashi syndrome, Griscelli syndrome subtype 2, and Hermansky Pudlack type 2. Other PIDs associated with HLH have an impaired immune response to Epstein-Barr Virus (EBV) or other viral infections, such as deficiencies in X-linked lymphoproliferative disorder type 1 (XLP1)/SLAM-associated protein (SAP), X-inhibitor of apoptosis protein (XIAP), CD27, MAGT1, and IL-2 inducible kinase deficiency (ITK) (Table 1). HLH can also be an unusual complication of other more common PIDs such as chronic granulomatous disease, DiGeorge syndrome, severe combined immunodeficiency (SCID), and Wiskott-Aldrich Syndrome [9]. Untreated full blown primary HLH is usually fatal [4].

Secondary causes of HLH are numerous and include infection (e.g. viruses—particularly EBV, bacteria,

Table 1 Subtypes of primary HLH

Primary HLH subtype	Gene	Protein	Functional defect	Clinical features	Diagnostic results by flow cytometry
Familial HLH:					
Type 1 fHLH	Unknown	Unknown	Unknown	Early onset HLH	Unknown
Type 2 fHLH	<i>PRF1</i>	Perforin	Pore formation and apoptosis	Early onset HLH	Low/absent perforin expression
Type 3 fHLH	<i>UNC13D</i>	Munc13-4	Vesicle priming	Increased incidence of CNS-HLH	Decreased CD107a expression
Type 4 fHLH	<i>STX11</i>	Syntaxin-11	Vesicle transport	Mild recurrent HLH, colitis, Turkish descent	Decreased CD107a expression
Type 5 fHLH	<i>STXBP2</i>	Munc18-2	Vesicle trafficking and release	Late onset, colitis, hypogammaglobulinaemia, platelet adhesion defects	Decreased CD107a expression
Immunodeficiency syndromes:					
Griscelli syndrome type II	<i>RAB27A</i>	RAS associated protein	Signal transduction	Partial albinism, silvery grey hair, late onset HLH with CNS involvement	Decreased CD107a expression
Chediak-Higashi syndrome	<i>LYST</i>	Lysosomal trafficking regulator	Vesicle docking	Partial albinism, bleeding tendency, impaired phagocytosis, recurrent pyogenic infections	Decreased CD107a expression
Hemansky-Pudlak syndrome type II	<i>APB31</i>	Beta-3A subunit of the AP3 complex	Vesicle trafficking	Partial albinism, bleeding tendency, immunodeficiency	Decreased CD107a expression
X-linked lymphoproliferative disease type I (XLP1)	<i>SH2D1A/SAP</i>	SH2 domain containing protein 1A/SLAM associated protein (SAP)	T, NK and NKT cell signalling and apoptosis	Hypogammaglobulinaemia, lymphoma, EBV infection associated HLH	Decreased/absent SAP Low NKT cells
X-inhibitor of apoptosis protein (XIAP) deficiency	<i>BIRC4</i>	X-linked inhibitor of apoptosis (XIAP)	NFκB signalling and apoptosis	HLH and colitis, variable immunodeficiency	Decreased/absent XIAP expression, impaired NOD2 signalling, raised IL-18 levels
IL-2 inducible kinase (ITK) deficiency	<i>ITK</i>	IL-2 inducible kinase (ITK)	T, NKT lymphocyte activation	EBV associated HLH and Hodgkin's lymphoma	Reduced T cell receptor (TCR)-mediated calcium flux Absent NKT cells

Table 1 (continued)

Primary HLH subtype	Gene	Protein	Functional defect	Clinical features	Diagnostic results by flow cytometry
CD27 deficiency	<i>CD27</i>	CD27	B lymphocyte activation	Combined immunodeficiency, EBV driven HLH & lymphoma	Reduced/absent CD27 on B and T cells
X-linked immunodeficiency with magnesium defect, EBV infection, and neoplasia (XIMEN)	<i>MAGT1</i>	MagT1	T cell receptor function N-linked glycosylation	Combined immunodeficiency, chronic EBV infections and EBV driven lymphoma	Reduced T cell receptor (TCR)-mediated Mg2+ influx Decreased CD69 expression in stimulated CD4+ T cells
NLR4 gain of function mutations	<i>NLR4</i>	NLR Family, CARD Domain-Containing Protein 4 (NLR4)	Constitutively active inflammasome	Autoinflammatory disease	Raised IL1 β and IL-18 levels

*This list is not exhaustive and HLH has been recognised in a large number of rare primary immunodeficiencies

protozoa and fungi), malignancy, metabolic disorders, autoimmune diseases, and autoinflammatory disorders [2, 3].

Central nervous system involvement in all forms of HLH (CNS-HLH) is common, with a reported incidence of between 18 and 73% and up to 75% in fHLH [10–18]. CNS-HLH may occur at disease onset, during the course of the disease or at a relapse, and results in increased morbidity and mortality and poor neurological outcome [19]. Although clinical features of CNS-HLH have been more commonly reported in patients with primary causes of HLH, they are increasingly recognised in secondary HLH, particularly when associated with chronic EBV infection.

Less commonly, both primary and secondary HLH may present with isolated CNS features in the absence

of systemic disease, or occurring several weeks or months prior to the onset of systemic signs and symptoms [20, 21]. Isolated CNS-HLH is becoming increasingly recognised as a separate clinical entity, although it presents a diagnostic challenge, as, in the absence of systemic inflammation, neurological symptoms, and neuroradiological manifestations can mimic a number of other neuroinflammatory and neurovascular conditions. In addition, there is very little evidence for the specific treatment of isolated CNS-HLH.

In this review, we summarise our current understanding of pathogenic mechanisms, present common clinical features of CNS-HLH and methods of investigation and diagnosis, and review current treatment approaches with particular focus on newer immunotherapeutics.

Pathophysiology of CNS-HLH

The neuropathological features of CNS-HLH vary greatly both in the context of primary and secondary HLH [19, 21, 22]. In a recent literature review of 7 biopsies and 39 autopsies (9 studies) carried out in children with primary HLH, neuropathological changes included vascular, parenchymal, and leptomeningeal lymphohistiocytic infiltration, small vessel lymphocytic vasculitis, and parenchymal white matter and leptomeningeal inflammation that could be accompanied by necrosis and haemorrhage [19]. The occurrence of CNS haemophagocytosis is variable and has been most commonly observed in the leptomeninges. In those who had had biopsies as part of a diagnostic work up for fHLH, with confirmed genetic changes, the findings were less severe and usually involved lymphocytic infiltration and CNS haemophagocytosis without gross haemorrhage or necrosis. In autopsies, findings varied considerably from mild leptomeningeal infiltration to haemorrhage with gross oedema and tissue destruction [14, 19]. Immunostaining of perivascular infiltrates has demonstrated the majority of cells are CD3 + lymphocytes [23]. Biopsy findings of 5 children with secondary HLH (2 EBV, 2 malignancy, 1 unknown) showed similar findings to those found in primary HLH [19].

Another literature review of biopsy findings in 28 cases of isolated CNS-HLH demonstrated that lymphocytic infiltrate was the most common finding in just over 15% of cases, whereas necrosis, haemorrhage, and ischaemia occurred in <5%. Half of these patients went on to develop systemic features [21].

A three stage neuropathological system has been devised for CNS-HLH based on autopsy findings in cases of primary HLH [14]. Stage I involves leptomeningeal inflammation; stage II extended to perivascular inflammation; in stage III, lymphohistiocyte tissue infiltration, tissue necrosis, and blood vessel destruction are apparent. In secondary HLH, the pathology of CNS-HLH has

been less well studied, although reports from autopsy and biopsy findings are similar to those with primary HLH. The pathological mechanisms of HLH in the CNS remain poorly characterised but likely relate to the hyperinflammation and dysregulated immune response observed systemically [24, 25].

The cellular mechanisms of CNS-HLH are poorly understood. Gene mutations identified in fHLH and other forms of primary HLH are predominantly involved in perforin-granzyme B-mediated apoptotic signalling in CTLs and NK cells (Table 1) [26]. These mutations impair perforin formation as well as trafficking, docking, or fusion of perforin and granzyme-containing cytotoxic granules to the plasma membrane [26]. Other described gene mutations affect B, T, NK, and NKT cell activation (Table 1) [25, 26]. These mutations effectively impair the cytotoxic killing potential of CTLs and NK cells, preventing the removal of infected, unwanted, or defective cells, which is thought to result in excessive activation and proliferation of both antigen-presenting cells (APC) and effector cells [25]. The normal regulatory mechanisms that eliminate activated immune cells are also impaired resulting in an excess production of pro-inflammatory cytokines resulting in sustained hyperinflammation [4].

The lymphohistiocytic infiltration, haemophagocytosis, and subsequent tissue damage observed in CNS disease in the context of systemic HLH and isolated CNS-HLH are similar to that seen in other end organs. The reason for a predilection for the CNS or CNS infiltration prior to systemic infiltration is unclear and further research on pathological mechanisms is required to elucidate this.

Diagnosis of CNS-HLH

There is no agreed definition of CNS-HLH, but HLH-2004 diagnostic criteria list neurological symptoms and cerebrospinal fluid pleocytosis as supportive evidence of disease [27]. In general, CNS-HLH should be considered in any patient presenting with one or more of the following neurological symptoms or signs: irritability, seizures, ataxia, dystonia, hemi- or diplegias, cranial nerve palsies, visual disturbance, dysarthria, dysphagia, mental status change, or meningoencephalitis and pleocytosis or high levels of protein in the CSF and abnormalities on MRI brain imaging in the context of HLH.

A recent global cohort study of isolated CNS-HLH demonstrated the mean time to diagnosis of 28.3 months, highlighting the diagnostic difficulties [21]. Diagnostic delay may result in inappropriate management and CNS-HLH may be only considered in cases that are refractory to treatment. An initial response to systemic immunosuppression given for suspected alternative neuroinflammatory conditions may further delay diagnosis, with neurological disease progression.

Neurological Features

In systemic HLH, seizures are observed in 30–40% of young patients with CNS involvement [17, 28], with ataxia being more frequent in older children [13]. In a global study of 38 cases of isolated CNS-HLH, the most frequent neurological presentations were ataxia and gait disturbances (up to 74%) [21]. Seizures were the next most frequent manifestation (50%), followed by headache (47%), visual disturbances (45%), and motor difficulties (42%). Diverse, neurological manifestations such as cranial nerve palsies, dysmetria, dysarthria, papilloedema, intermittent sensory deficits, and behavioural changes were also reported in this cohort [21].

A smaller series of four patients with isolated CNS-HLH also reported ataxia, seizures, motor weakness, and cognitive decline [20]. There are case reports of CNS-HLH presenting with peripheral nervous system involvement, e.g. motor and sensory neuropathy in a patient with confirmed compound heterozygous mutations in *UNC13D*, and diffuse polyradiculoneuropathy in an 11-year-old with parental consanguinity but without genetic testing of fHLH genes [29, 30].

The clinical features described in these studies demonstrate the extent of brain involvement in CNS-HLH—cerebellar, brainstem, and cortical.

CSF Investigations

In a study of 116 children with systemic HLH, the prevalence of CSF abnormalities (defined as a leukocyte number above $19 \times 10^9/L$ or total protein concentration above 500 mg/L) was reported to be up to 15%, and was more prevalent in primary HLH (58%; 7/19 cases) than secondary HLH (6%; 10/160 cases) [28].

In 29 cases of isolated CNS-HLH, the median CSF cell count was $10.0 \times 10^6/L$ (range 0– $84 \times 10^6/L$) with elevated CSF protein (>45 mg/dL; range 4–874 mg/dL) in 52% (15/29) [21]. Oligoclonal bands (OCB) in the CSF have varied with both positive (type 2, suggesting intrathecal synthesis) or matched (type 4, suggesting blood brain barrier (BBB) damage) being reported [30, 31]. The neurotransmitter, CSF purine nucleotide neopterin, is synthesised by microglia following interferon- γ (IFN- γ) stimulation. Levels were elevated in 2 of 4 cases with isolated CNS-HLH [20] but its utility needs validation in larger studies.

Blinco et al. identified normal CSF parameters (white cell count $<5 \times 10^6/L$ and protein <45 g/dl) in 38% of cases (12/32) of isolated CNS-HLH, suggesting disease may exist within brain parenchyma without leptomeningeal involvement [21]. However, this appears contrary to post-mortem histopathology classification in primary HLH, where early disease is characterised by leptomeningeal inflammation [14].

The limited literature in isolated CNS-HLH does not support a correlation between CSF abnormalities and prognosis, although resolution of CSF abnormalities can be used to monitor response to therapy in CNS-HLH.

It is recommended that all patients with HLH have a lumbar puncture (LP), irrespective of the presence of clinical neurological features, provided there are no contraindications [32] (Fig. 1). Repeated lumbar puncture is required if there is clinical suspicion of CNS disease as CSF abnormalities may develop over time. CSF changes can occur in isolation and are considered a poor prognostic indicator in systemic HLH [15, 17].

Neuroimaging

MRI is the modality of choice for neuroimaging in CNS-HLH. In CNS-HLH in the context of systemic disease, the prevalence of MRI abnormalities was reported to be as high as 50% in a study of 179 children with HLH [28]. The highest proportion of MRI abnormalities was observed in those with primary

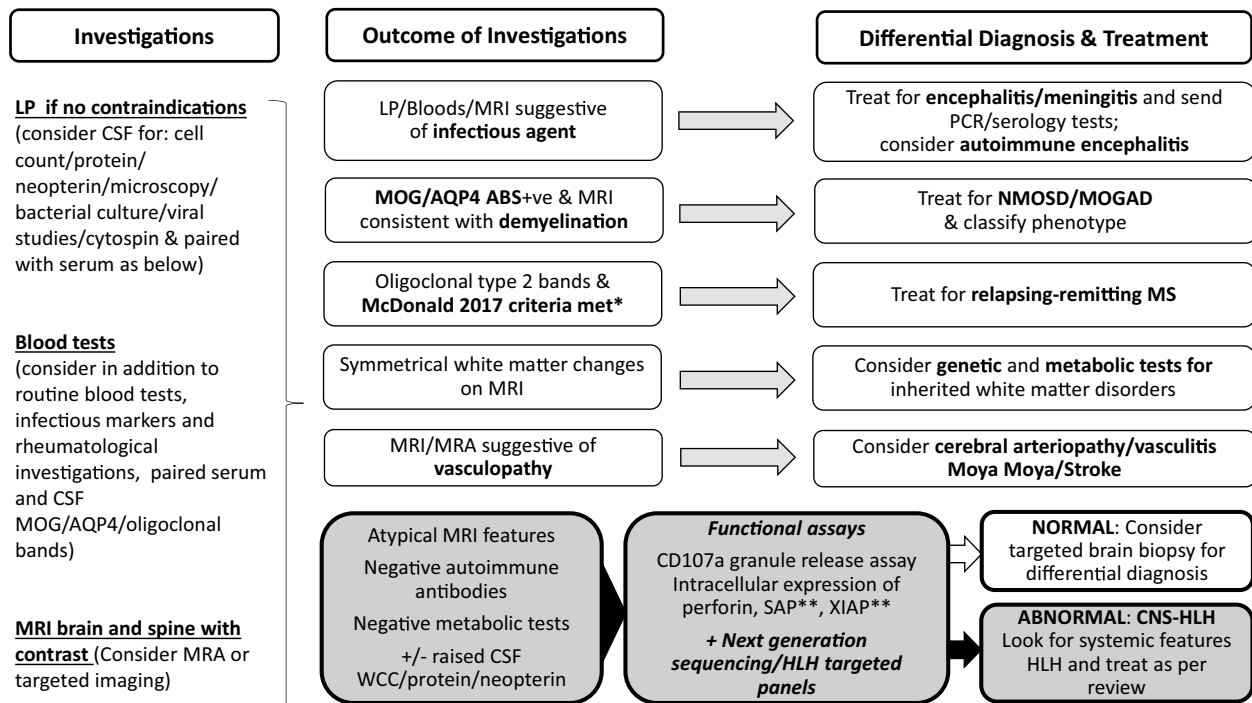


Fig. 1 Flow chart for the investigation and differential diagnosis of CNS-HLH and related conditions. Diagnostic algorithm for the evaluation of patients with possible neuroinflammatory conditions including CNS-HLH (suggested by history and examination). Further diagnostic evaluation is dependent on the initial results of LP, neuroimaging, and blood tests, which can be stratified according to differential diagnosis and treated accordingly. Features suggestive of CNS-HLH together with further diagnostic evaluation and treatment are shown in the grey boxes. Abbreviations: LP, lumbar puncture; CSF, cerebrospinal fluid; MRI, magnetic resonance imaging; MRA, magnetic resonance angiography; PCR, polymerase chain reaction; MOG, myelin oligodendrocyte glycoprotein; AQP4, aquaporin 4 antibodies; ABS, antibodies; NMOSD, neuromyelitis optica spectrum disorder; MOGAD, MOG antibody disease; MS, multiple sclerosis; SAP, SLAM-associated protein; XIAP, X-inhibitor of apoptosis protein; HLH, hemophagocytic lymphohistiocytosis; CNS-HLH, central nervous system hemophagocytic lymphohistiocytosis. *McDonald 2017 criteria for MS [39], **Test only if male.

HLH (13/18 cases); 67/142 were observed in secondary HLH. In comparison to MRI abnormalities, neurological symptoms were only observed in 21.2% (38/179) of children. Lesions that have been reported in CNS-HLH in the context of systemic HLH included nodular or ring-enhancing parenchymal lesions with periventricular changes, lesions at the junction of grey and white matter, and haemorrhagic transformation (of parenchymal lesions) [33–35]. Subdural collection, diffuse leptomeningeal enhancement, and atrophy have also been reported, and even within the same patient, there is variability of imaging findings over time [34]. Neuroimaging has also shown brainstem and spinal cord involvement in fHLH [13, 35–37].

In isolated CNS-HLH, all patients have positive imaging findings along with neurological symptoms as the presentation of such features leads to the diagnosis (Fig. 1). The largest worldwide cohort of isolated CNS-HLH to date identified cerebellar abnormalities in 61% of patients [21]. In common with CNS disease in systemic HLH, reported findings included diffuse and multifocal white matter changes, oedema, haemorrhage, and atrophy. Within the spine, isolated CNS-HLH has been described with short segment punctate enhancing lesions [38]. Progression of MRI changes prompted further investigations since isolated CNS-HLH was not the initial diagnosis in any of the 38 patients reported in the cohort. Initial diagnoses in isolated CNS-HLH included demyelinating conditions such as acute disseminated encephalomyelitis (ADEM) and multiple sclerosis (MS) [39], as well as vasculitis, stroke, and the descriptive entity “chronic lymphocytic inflammation with pontine perivascular enhancement responsive to steroids (CLIPPERS)” [21]. The characteristic MRI findings of which include punctate and curvilinear perivascular peppercorn-like gadolinium enhancement (suggesting BBB damage) of the pons and cerebellum [40]. Two children who presented with an atypical chronic demyelinating illness were initially diagnosed as CLIPPERS. Next generation sequencing (gene panels conducted on a research basis) identified a compound heterozygote variant in RAB27A (Griscelli syndrome type 2) in one child, and a heterozygote variant in STXBP2 gene (fHLH V) in the second, consistent with primary HLH [41]. This demonstrates that all children with suspected CLIPPERS should have primary HLH excluded. As deep grey matter and cerebellar involvement is also seen in myelin oligodendrocyte glycoprotein (MOG) antibody positive as well as antibody negative demyelinating conditions, these conditions should also be considered (Fig. 1) [38].

Histopathology

The presence of CNS-HLH may only be diagnosed, or the extent appreciated, on brain biopsy (Fig. 1) [20]. Brain biopsies have played a role in isolated CNS-HLH diagnostic process where imaging, neurological features, and CSF findings have been non-specific. In 28 cases of isolated CNS-HLH disease, 6 cases (21%) pursued investigations for fHLH genes following a brain biopsy [21]. As previously mentioned, the most prevalent finding was T cell-dominated lymphohistiocytic infiltration (15/20 biopsies), with more severe features such as necrosis and haemorrhage being present in smaller

numbers (3/20 and 1/20, respectively) [21]. However, timing of the biopsies was varied with one case identified after autopsy and another case was only found to have lymphohistiocytic infiltration on a repeat second biopsy. In the era of genetic, molecular, and immunological studies, highlighting isolated CNS-HLH as a clinical entity may reduce the need for brain biopsies which carry inherent risks.

Functional Assays for Primary HLH

NK cells and cytotoxic T lymphocytes mediate cell death of target cells through the release, or degranulation, of cytolytic granules containing granzyme B and perforin. This process requires fusion of the granule membrane with the cytoplasmic membrane resulting in surface exposure of proteins such as CD107a. Membrane expression of CD107a represents a surrogate marker of effective cytotoxicity in NK or cytotoxic T cells. Flow cytometric analysis of CD107a expression on cytotoxic cells following activation can therefore be used to identify patients with inherent defects of cytotoxic granule release (including fHLH 3–5, Chediak Higashi syndrome, Griscelli syndrome type 2, Hermansky Pudlack type 2) [42].

A prospective study of degranulation assays in 494 HLH or suspected HLH patients identified resting NK-cell degranulation below 5%, with 96% sensitivity and 88% specificity for primary HLH disorders caused by impaired cytotoxic granule release [43]. NK or cytotoxic T cell function can be further investigated using cellular killing assays. Flow cytometry-based assays can also quantify perforin, SLAM-associated protein (SAP), and X-linked inhibitor of apoptosis (XIAP), to further aid the diagnosis of other specific forms of primary HLH. Although these functional and protein expression assays are invaluable tools in the rapid diagnostics of primary HLH, it is important to recognise that not all causes of primary HLH will be identified by these assays. In some patients with primary HLH, pathogenic gene mutations can result in non-functional proteins which are still expressed, resulting in a normal protein expression as identified by flow cytometry, but impaired protein function. The proportion of patients with protein expression in the cohort of 38 patients with isolated CNS-HLH cohort is higher than that reported for patients with systemic HLH and perforin deficiency, suggesting a hypothesis that isolated CNS HLH may be associated with hypomorphic rather than null mutations [21].

Genetic Testing

Urgent genetic investigation of any patients with suspected CNS-HLH is essential. Immunological functional abnormalities with negative exome sequencing of fHLH genes have been reported [44]. In 5 such cases, whole genome sequencing identified mutations in the non-coding region of RAB27A. The cases lacked the typical hypopigmentation associated with Griscelli syndrome

type 2. Three of these cases presented with recurrent neuroinflammation and two were initially diagnosed as ADEM [44].

Summary of the Recommendations for Investigation of CNS-HLH (Fig. 1)

1. Lumbar puncture for CSF analysis is indicated provided there are no contraindications. We recommend CSF microscopy and culture, protein, paired serum and CSF glucose, paired serum and CSF oligoclonal bands, and neopterin (if available).
2. An extended MRI protocol of brain and spine of T1, T2-weighted, fluid-attenuated inversion recovery (FLAIR), for detection of juxtacortical lesions, diffusion weighted imaging (DWI), which is sensitive to white matter changes, and post-contrast imaging along with susceptibility-weighted imaging (SWI) looking for blood components is recommended.
3. Functional assays for primary HLH have an important role in CNS-HLH diagnosis. These investigations are limited by the need for specialist laboratory experience; however, the reliability of these assays is not compromised by a 48-h delay between blood draw and testing, allowing samples to be couriered to specialist laboratories. Not all causes of primary HLH will be identified by these assays so if clinical suspicion is high, genetic investigations should be pursued.
4. Genetic diagnosis is needed for confirmation of a diagnosis of primary HLH. Usually this is clinically urgent and guides ongoing treatment; the mode of genetic investigation must be governed by the turnaround time of results. Where a specific diagnosis is suggested by functional immunology assays, conventional Sanger sequencing targeting likely causative genes may be most efficient. Otherwise next generation sequencing, using targeted gene enrichment panels or whole exome/genome sequencing is appropriate. We would recommend an extensive genetic investigation as soon as practicably possible in any case of suspected CNS-HLH, as the genetic diagnosis may have implications for siblings of the index case.
5. Targeted brain biopsy can aid determination of differential diagnoses.

Treatment of CNS-HLH in the Context of Systemic Disease

The HLH treatment guidelines developed by the Histiocyte Society in 1994 and 2004 (HLH-94 and HLH-2004) include specific recommendations for the management of CNS disease presenting in the context of systemic HLH, or isolated CNS-HLH, once identified [22, 27]. There is no consensus on salvage treatments for individuals with CNS-HLH who are refractory to HLH-1994 and 2004 protocols, or in whom disease relapses. Here we summarise current approaches and review newer immunotherapies that are beginning to come into use.

The initial treatment of CNS disease in systemic HLH is based on control of systemic hyperinflammation and immune dysregulation, with a presumed beneficial effect to CNS infiltration and haemophagocytosis in the brain. The 1994 and 2004 protocols use a combination of etoposide, dexamethasone, and cyclosporine A (CsA) with the aim of reducing systemic hyperinflammation and controlling the immune response to induce a state of remission. In

primary causes of HLH, particularly fHLH, once in remission, continuation therapy acts as a bridge prior to more definitive treatment with allogeneic HSCT [45]. In the revised HLH-2004 protocol, CsA was used at the start of induction rather than later on in treatment, with the aim of reducing pre-HSCT morbidity and mortality. However although this improved remission, there was no overall improvement in long-term survival compared to the HLH-94 protocol, due to infectious complications [46]. In secondary HLH with CNS features, induction therapy may be curative. However, continuation therapy should be initiated if the disease is still active. Refractory cases may need second-line therapy and even HSCT if recurrent or persistent. Both HLH-94 and HLH-2004 protocols also include specific intrathecal treatment (methotrexate and hydrocortisone) for CNS disease in the context of systemic HLH [22, 27]. EBV is a common infectious trigger in both primary and secondary HLH, and where detected rituximab should be used to reduce the viral load [47].

In the HLH-94 trial, 81/122 (66%) of patients with CNS involvement were alive after starting treatment, with CNS features persisting in 22% post-HSCT after a median follow-up of 3.1 years [22]. With the revised protocol, CNS features post-HSCT persisted in 17% [27].

An alternative approach to the HLH-94 and 2004 protocols has been the use of lymphocyte serotherapy. Anti-thymocyte globulin (ATG) is an infusion of rabbit-derived antibodies against human T cells and in combination with methylprednisolone and CsA continuation therapy, has had comparable efficacy for CNS-HLH [48]. With this regimen, complete remission in patients with neurological involvement was seen in 11/19 patients (58%) within a median time of 1.3 months [32]. A hybrid immunotherapy trial for HLH (HIT-HLH) in children is currently underway in North America (clinicaltrials.gov NCT01104025) which combines the HLH-2004 and ATG regimens to see if combined therapies result in better remission rates. The evaluation of this trial is currently in progress.

Alemtuzumab is another treatment being explored as an alternative therapy for HLH. It is a humanised IgG1 kappa monoclonal antibody that selectively binds CD52, a small GPI-anchored protein expressed on lymphocytes, monocytes, macrophages, and dendritic cells, depleting these cells from the circulation. The use of alemtuzumab was first described in adult patients with refractory sHLH who had failed standard therapy [49, 50]. A small retrospective (26 patients) and prospective (29 patients) pilot study of alemtuzumab with steroids and CsA demonstrated a favourable safety profile with 92.3% and 91.6%, respectively, surviving to HSCT. CNS disease, however, was not specifically evaluated [23]. A prospective multicentre, phase I/II, non-randomised study (NCT02472054) is currently open assessing the use of alemtuzumab, with methylprednisolone and CsA as a first-line therapy in patients with primary HLH [45]. Alemtuzumab-based treatment is currently used as first line in certain specialist European centres and publications of outcome data are awaited.

The quality of disease remission prior to HSCT in HLH is important for long-term survival, with the HLH-2004 data demonstrating a significant survival benefit for patients undergoing HSCT in complete remission compared to those in partial remission (hazard ratio 2.12) [46]. Mortality prior to

transplant remains between 20 and 30% despite modifications to the standard HLH-94 and 2004 protocols [45]. Mortality with CNS-HLH has been reported to be worse on longer-term follow-up prior to HSCT (hazard ratio 1.3) using the 2004 protocol, although this was not statistically significant. The delay in the diagnosis and appropriate treatment of isolated CNS-HLH may contribute to worse outcomes although this has not been quantified.

In patients with CNS-HLH that is refractory to systemic and intrathecal treatment, high-dose pulsed corticosteroids and alemtuzumab have been recommended [21]. Alemtuzumab has been used as a salvage therapy in 22 paediatric and adult patients with HLH refractory to standard treatments (etoposide, dexamethasone, cyclosporine), with 67% of patients reported to achieve a partial response, and 77% going on to receive HSCT [51]. However, two patients with CNS-HLH who had failed systemic HLH treatment and intrathecal methotrexate showed no clinical improvement in CNS features, although CSF post-alemtuzumab could not be fully analysed. In a more recent comprehensive study, 38 patients with isolated CNS-HLH in fHLH, alemtuzumab was used in 3 patients, which was in addition to intrathecal therapy in two of the three [21]. Two patients showed neurological improvement, with one having residual subtle neurological features and the other, who only received systemic alemtuzumab and steroids, regaining the ability to walk after being previously wheelchair bound. The third child had moderate improvement with significant ongoing neurological impairment. In previous studies, CMV and adenovirus viraemias occurred in a quarter to a third of patients following alemtuzumab, which is a potential concern with this treatment [25]. In 2019, the European Medicines Agency (EMA) has launched an urgent safety review of alemtuzumab after a number of serious cardiovascular and immune-mediated adverse events were reported [52]. The UK Medicines and Healthcare products Regulatory Agency (MHRA) has increased restrictions on its use while this review is undertaken.

Treatment of Isolated CNS-HLH

A review of cases of isolated CNS-HLH in fHLH showed a wide variation in initial treatment including standard HLH-94 and 2004 protocols with intrathecal therapy, isolated use of intrathecal methotrexate and steroids, alemtuzumab, cyclosporine, cyclophosphamide, and MMF with or without steroids. This was primarily because the patients with isolated CNS-HLH are often treated for other conditions including ADEM, MS, and CNS vasculitis even up to the point of transplantation [21]. Horne et al. [32] has suggested that the standard of care for isolated CNS-HLH should be the same as that for CNS-HLH in systemic disease, namely standard HLH-94 or 2004 protocols, intrathecal therapy, and alemtuzumab for refractory or relapsed disease, followed by HSCT. However, problems with monitoring response to therapy run the risk of prolonged systemic therapy with greater toxicity. A therapeutic approach that targets CNS inflammation would be much more attractive.

HSCT

HSCT is currently used for the treatment of CNS-HLH in those with confirmed genetic mutations (Table 1) or in individuals with relapsed or refractory CNS features, whether isolated or in the context of systemic HLH [47]. Fully myeloablative conditioning regimens have been largely replaced by reduced intensity conditioning (RIC) or reduced toxicity regimens due to complications, particularly veno-occlusive disease [53–55]. Comparable or improved outcomes have been observed with RIC, although increased rates of mixed chimerism have been reported, with increased risk of engraftment failure and relapse [53, 56, 57]. Reported survival rates with RIC are extremely variable (44–100%) but individuals with CNS features generally have a worse prognosis [13, 16]. In the context of RIC conditioned HSCT, higher rates of mixed chimerism and rejection are seen with mismatched donors. Haploidentical (including parental) donors have the advantage of donor availability, and can avoid delays in transplant caused by an unrelated donor search; however, rates of rejection remain higher than with fully matched donors. Newer haploidentical transplant conditioning and graft manipulation strategies (post-transplant cyclophosphamide with a T replete graft, $\alpha\beta$ TCR/CD19 depleted graft manipulation) may improve results [58].

The minimum donor chimerism for HSCT in primary HLH has been determined to be 20–30%, as this level has been found to protect against late disease relapse (> 180 days post-transplant). In some individuals, a higher level of chimerism is required. Levels of donor chimerism < 20% inevitably result in disease relapse which often requires a second transplant [59]. Low lymphoid chimerism rather than myeloid chimerism appears to be a better predictor of relapse, although the threshold of chimerism which can prevent HLH is likely to be different for different genetic disorders [45]. Adequate chimerism and engraftment have been demonstrated to prevent neurological disease progression [60, 61].

A recent single-centre review of HSCT in 4 children with isolated CNS-HLH and confirmed *Prf1* or *UNC13D* gene mutations showed successful engraftment with long-term correction in all 4 patients. Three patients received RIC and matched unrelated donor (MUD) transplants and achieved 20–23% donor chimerism [62]. Two patients improved in terms of neurological features (ataxia, weakness, diplopia, reduced seizures) and the third patient remained stable. The fourth patient received a matched transplant from a sibling who was heterozygous for a *Prf1* mutation, and experienced a CNS-relapse. It was later demonstrated that the donor cells had lower than normal perforin expression despite adequate chimerism. The patient survived with long-term remission following a second MUD transplant. The impact of heterozygous mutations in donor siblings is unclear, particularly as monoallelic variants are also observed in the general population [63, 64].

In a recent literature review and international survey of isolated CNS-HLH (primary HLH) cases, 19/38 underwent HSCT following reduced intensity conditioning and 11 (59%) had long-term improvement in neurological sequelae, 4 remained stable (21%), 1 relapsed requiring a second transplant,

and 3 died (15%) [21]. In two patients, the improvement was significant with return to normal neurological baseline. Another 15/38 patients were not transplanted and of these 3 improved with systemic±intrathecal treatment (20%), 1 relapsed, 1 had unreported outcomes, and 10 died (67%). A further 4 patients were awaiting planned HSCT. The authors suggest that the poor outcomes in non-transplanted patients indicate that HSCT should be rapidly performed in isolated CNS-HLH. More robust follow-up studies are required to better understand the factors which lead to successful long term engraftment success in CNS-HLH with resolution of CNS features, prevention of neurological progression, and prevention of relapse.

Newer Therapies

With standard treatments for CNS-HLH, there remains concern in paediatric populations about the toxicity of chemotherapy drugs such as etoposide as well as side effects of long-term steroids. Early administration of CsA is now often omitted due to high rates of toxicity such as posterior reversible encephalopathy syndrome (PRES) and renal toxicity [25, 65], and lack of significant improvement in overall survival [65]. The rapid development of targeted immunotherapies against inflammatory mediators has led to a number of studies looking at the effectiveness of these molecules in primary and secondary HLH. We consider these in the sections below.

Inhibition of JAK-STAT Signalling

Perforin deficient mouse models of HLH have shown that interferon gamma (IFN- γ) is a key mediator of hyperinflammation in HLH [66, 67]. Signalling downstream of IFN- γ and a number of other cytokines is mediated via Janus Activated Kinase-Signal Transducer and Activator of Transcription (JAK-STAT) cascades (Fig. 2). Two JAK-STAT pathway inhibitors are currently under investigation for the treatment of HLH: ruxolitinib, a selective JAK1/JAK2 inhibitor, and emapalumab, a fully human IgG1 anti-IFN- γ monoclonal antibody that binds free and receptor-bound IFN- γ (Fig. 2) [68, 69].

Ruxolitinib has shown efficacy in mice and has been used in a number of case studies for the treatment of refractory HLH, to good effect [66, 67, 70–72]. In a case series of 34 paediatric patients with refractory HLH, ruxolitinib with or without glucocorticoid treatment 25/34 (73.4%) showed a partial (58.8%) or complete (14.7%) response to treatment [72]. The overall survival rate was 65.9%. Clinical trials investigating the efficacy of ruxolitinib in HLH including in effects on CNS-HLH are ongoing (NCT02400463 and NCT03533790).

Emapalumab has been tested in an open-label phase 2–3 study in 34 children with primary HLH (NCT01818492) with a response in 65% of patients (21% partial and 31% complete) [73]. A partial response was defined as improvement in three or more clinical parameters including CNS

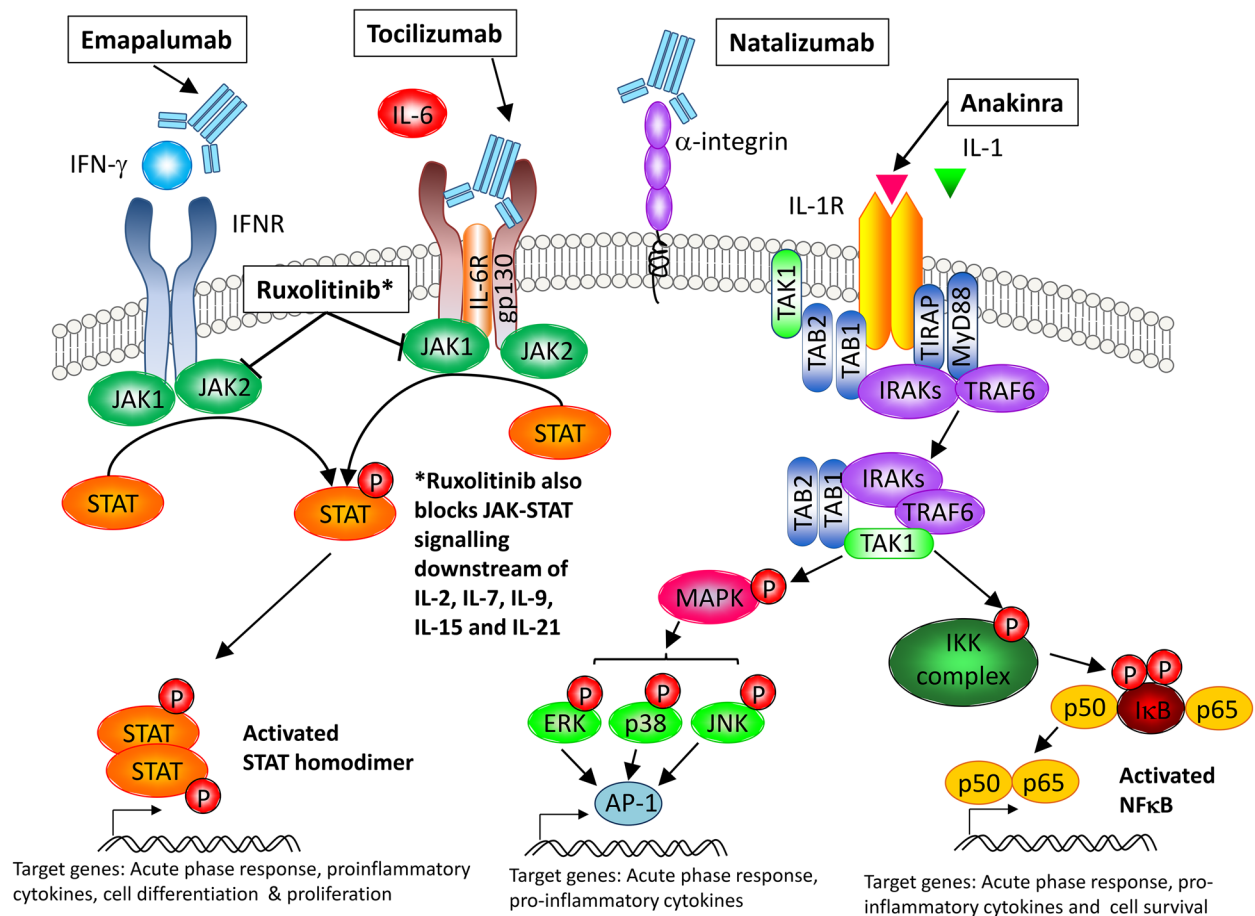


Fig. 2 Mechanism of action of new immunotherapeutics used in the treatment of HLH. JAK-STAT pathway inhibitors are being used to block downstream cytokine activation in HLH. The monoclonal antibody emapalumab binds to IFN- γ and blocks ligand-receptor interaction and downstream signalling. Ruxolitinib is a selective JAK1/JAK2 kinase inhibitor that blocks JAK-STAT signalling downstream of a number of inflammatory cytokines. Tocilizumab binds to the IL-6 receptor and prevents IL-6 binding and downstream activation of JAK-STAT signalling. Natalizumab is a monoclonal antibody that binds to alpha integrin on the surface of immune cells and prevents their adhesion to, and passage across, the blood-brain barrier. Anakinra is a competitive inhibitor of IL-1 and prevents downstream signalling via mitogen activated kinases (MAPK) and nuclear factor kappa NF- κ B and subsequent upregulation of a number of pro-inflammatory cytokines.

involvement. Twelve patients had CNS involvement, which normalised in 6, improved in 4, and could not be evaluated in 2 because of worsening systemic HLH. There was no organ toxicity but severe infections were observed in 10/34 patients and this remains a safety concern and although approved by the Food and Drug Administration (FDA) in the USA for refractory HLH, the European Medicines Agency (EMA) has refused market authorisation based on lack of evidence [74, 75]. Further studies are required to establish the safety and efficacy of these agents in systemic and isolated CNS-HLH.

Other Immunotherapies

A number of other new immunotherapeutics have been used for the treatment of HLH or are in clinical trials to establish efficacy for HLH, but not specifically for CNS-HLH. These include i) tocilizumab, a humanised monoclonal antibody directed against the human interleukin-6 receptor (anti-IL-6R) [76]; ii) natalizumab, a humanised monoclonal antibody that targets the cell adhesion molecule alpha-4 integrin believed to reduce the ability of inflammatory immune cells to pass through the BBB [77]; and iii) anakinra, a recombinant human IL-1 receptor antagonist protein [78–81] (Fig. 2).

- i) Tocilizumab has been successfully used to treat refractory HLH in adults with secondary HLH (88.9% remission) [82], and is currently being tested in a phase-2 open-label clinical trial in children who meet the clinical diagnostic criteria for HLH, as defined by the Histiocyte Society (either primary or secondary), with a primary completion date of January 2021 (NCT02007239). As with ruxolitinib, there are concerns over the use of tocilizumab for the treatment of secondary HLH due to infective complications.
- ii) Natalizumab has been used compassionately for the treatment of a 5-year-old girl with CNS-HLH, prior to diagnosis, who presented with headache, vomiting, mild ataxia with CSF pleocytosis, and multifocal cerebral and cerebellar lesions on MRI (CIS) [20]. Her condition clinically and radiographically improved and stabilised for 3 years, after which she relapsed, was diagnosed with fHLH and treated according to the HLH-2004 protocol. Natalizumab has also been used in another patient on compassionate grounds but standard treatment and HSCT were still required [62].
- iii) Anakinra has established efficacy in patients with systemic juvenile idiopathic arthritis and macrophage activation syndrome (MAS) [78–81]. A retrospective review of anakinra treatment in 44 children with various types of secondary HLH showed that early initiation resulted in a survival rate of 73% compared with 56% using etoposide-based protocols [83]. Anakinra is not myelosuppressive and can cross the BBB when given intravenously. Subcutaneous treatment has shown to be neuroprotective in rats, although high doses are required [84]. Further studies are required to establish whether these agents could be used in addition to, or as an alternative to, the standard HLH-94 and 2004 protocols.

Gene Therapy

The monogenic nature of defects associated with primary HLH means that, like other monogenic disorders that affect the immune system such as X-linked severe combined immunodeficiency syndrome (X-SCID), adenosine deaminase 1 associated SCID (ADA-SCID), Wiskott-Aldrich syndrome, and chronic granulomatous disease, gene therapy may offer a viable alternative to HSCT.

Pre-clinical gene therapy studies in murine models of HLH due to perforin deficiency have shown successful correction of cytotoxic T cell-mediated killing following with autologous CD8+T cells transduced with a gammaretroviral

vector carrying the *Prfl* gene [85]. Gammaretroviral mediated transfer of the *UNC13D* gene to cytotoxic T cells derived from patients with fHLH type 3 restored expression of functional Munc13-4 protein, as well as degranulation capacity and cell-mediated cytotoxicity in vitro [86]. Although this field is in its infancy, the use of autologous stem cells and RIC, with reduced toxicity and elimination of GvHD, offers a potentially curative treatment for primary HLH and associated CNS disease.

Conclusions

In patients with systemic HLH, CNS involvement should be actively looked for through CSF studies and regular neuroimaging. Isolated CNS-HLH presents a diagnostic challenge and should be considered early in cases of unclassified neuroinflammation, despite the lack of haematological or systemic features of HLH. Treatment approaches to CNS-HLH in the context of systemic HLH are improving but whether these can be extrapolated to isolated CNS disease remains to be established. The CNS penetration of newer therapies also needs to be determined. Optimisation of therapies for isolated CNS-HLH is required and needs to be tailored to this subgroup of patients. Uncertainty remains about the optimal time of HSCT with respect to CNS-HLH treatment and response, and also how CNS-HLH relapse post-HSCT should be treated. The recent advances in diagnostics and our understanding of the variability of clinical phenotype in CNS-HLH have now provided a foundation for addressing these important therapeutic questions.

Open Access This article is licensed under a Creative Commons Attribution 4.0 International License, which permits use, sharing, adaptation, distribution and reproduction in any medium or format, as long as you give appropriate credit to the original author(s) and the source, provide a link to the Creative Commons licence, and indicate if changes were made. The images or other third party material in this article are included in the article's Creative Commons licence, unless indicated otherwise in a credit line to the material. If material is not included in the article's Creative Commons licence and your intended use is not permitted by statutory regulation or exceeds the permitted use, you will need to obtain permission directly from the copyright holder. To view a copy of this licence, visit <http://creativecommons.org/licenses/by/4.0/>.

References and Recommended Reading

- Behrens EM, Koretzky GA. Review: Cytokine storm syndrome: looking toward the precision medicine era. *Arthritis Rheumatol*. 2017;69(6):1135–43. <https://doi.org/10.1002/art.40071>.
- Brisse E, Wouters CH, Matthys P. Hemophagocytic lymphohistiocytosis (HLH): a heterogeneous spectrum of cytokine-driven immune disorders. *Cytokine Growth Factor Rev*. 2015;26(3):263–80. <https://doi.org/10.1016/j.cytogfr.2014.10.001>.
- Chandrakasan S, Filipovich AH. Hemophagocytic lymphohistiocytosis: advances in pathophysiology, diagnosis, and treatment. *J Pediatr*. 2013;163(5):1253–9. <https://doi.org/10.1016/j.jpeds.2013.06.053>.
- Janka GE, Lehmborg K. Hemophagocytic syndromes—an update. *Blood Rev*. 2014;28(4):135–42. <https://doi.org/10.1016/j.blre.2014.03.002>.
- Esteban YM, de Jong JLO, Teshler MS. An overview of hemophagocytic lymphohistiocytosis. *Pediatr Ann*. 2017;46(8):e309–13. <https://doi.org/10.3928/19382359-20170717-01>.
- Janka GE. Hemophagocytic syndromes. *Blood Rev*. 2007;21(5):245–53. <https://doi.org/10.1016/j.blre.2007.05.001>.

7. Henter JI. Biology and treatment of familial hemophagocytic lymphohistiocytosis: importance of perforin in lymphocyte-mediated cytotoxicity and triggering of apoptosis. *Med Pediatr Oncol*. 2002;38(5):305–9. <https://doi.org/10.1002/mpo.1340>.
8. Zhang K, Chandrakasan S, Chapman H, Valencia CA, Husami A, Kissell D, et al. Synergistic defects of different molecules in the cytotoxic pathway lead to clinical familial hemophagocytic lymphohistiocytosis. *Blood*. 2014;124(8):1331–4. <https://doi.org/10.1182/blood-2014-05-573105>.
9. Bode SF, Ammann S, Al-Herz W, Bataneant M, Dvorak CC, Gehring S, et al. The syndrome of hemophagocytic lymphohistiocytosis in primary immunodeficiencies: implications for differential diagnosis and pathogenesis. *Haematologica*. 2015;100(7):978–88. <https://doi.org/10.3324/haematol.2014.121608>.
10. Akima M, Sumi SM. Neuropathology of familial erythrophagocytic lymphohistiocytosis: six cases and review of the literature. *Hum Pathol*. 1984;15(2):161–8. [https://doi.org/10.1016/s0046-8177\(84\)80057-x](https://doi.org/10.1016/s0046-8177(84)80057-x).
11. Deiva K, Mahlaoui N, Beaudonnet F, de Saint BG, Caridade G, Moshous D, et al. CNS involvement at the onset of primary hemophagocytic lymphohistiocytosis. *Neurology*. 2012;78(15):1150–6. <https://doi.org/10.1212/WNL.0b013e31824f800a>.
12. Gratton SM, Powell TR, Theeler BJ, Hawley JS, Amjad FS, Tornatore C. Neurological involvement and characterization in acquired hemophagocytic lymphohistiocytosis in adulthood. *J Neurol Sci*. 2015;357(1–2):136–42. <https://doi.org/10.1016/j.jns.2015.07.017>.
13. Haddad E, Sulis ML, Jabado N, Blanche S, Fischer A, Tardieu M. Frequency and severity of central nervous system lesions in hemophagocytic lymphohistiocytosis. *Blood*. 1997;89(3):794–800.
14. Henter JI, Nennesmo I. Neuropathologic findings and neurologic symptoms in twenty-three children with hemophagocytic lymphohistiocytosis. *J Pediatr*. 1997;130(3):358–65. [https://doi.org/10.1016/s0022-3476\(97\)70196-3](https://doi.org/10.1016/s0022-3476(97)70196-3).
15. Horne A, Trottestam H, Arico M, Egeler RM, Filipovich AH, Gadner H, et al. Frequency and spectrum of central nervous system involvement in 193 children with haemophagocytic lymphohistiocytosis. *Br J Haematol*. 2008;140(3):327–35. <https://doi.org/10.1111/j.1365-2141.2007.06922.x>.
16. Jovanovic A, Kuzmanovic M, Kravljanac R, Micic D, Jovic M, Gazikalovic S, et al. Central nervous system involvement in hemophagocytic lymphohistiocytosis: a single-center experience. *Pediatr Neurol*. 2014;50(3):233–7. <https://doi.org/10.1016/j.pediatrneurol.2013.10.014>.
17. Kim MM, Yum MS, Choi HW, Ko TS, Im HJ, Seo JJ, et al. Central nervous system (CNS) involvement is a critical prognostic factor for hemophagocytic lymphohistiocytosis. *The Korean journal of hematology*. 2012;47(4):273–80. <https://doi.org/10.5045/kjh.2012.47.4.273>.
18. Yang S, Zhang L, Jia C, Ma H, Henter JI, Shen K. Frequency and development of CNS involvement in Chinese children with hemophagocytic lymphohistiocytosis. *Pediatr Blood Cancer*. 2010;54(3):408–15. <https://doi.org/10.1002/pbc.22239>.
19. Klein C, Kleinschmidt-DeMasters BK, Liang X, Stence N, Tudor RM, Moore BE. A review of neuropathological features of familial and adult hemophagocytic lymphohistiocytosis. *J Neuropathol Exp Neurol*. 2019;78(3):197–208. <https://doi.org/10.1093/jnen/nlz001>.
20. Benson LA, Li H, Henderson LA, Solomon IH, Soldatos A, Murphy J, et al. Pediatric CNS-isolated hemophagocytic lymphohistiocytosis. *Neurol Neuroimmunol Neuroinflammation*. 2019;6(3):e560. <https://doi.org/10.1212/NXI.0000000000000560>.
21. Blincoe A, Heeg M, Campbell PK, Hines M, Khojah A, Klein-Gitelman M, et al. Neuroinflammatory Disease as an Isolated Manifestation of Hemophagocytic Lymphohistiocytosis. *J Clin Immunol*. 2020;40(6):901–16. <https://doi.org/10.1007/s10875-020-00814-6>.
22. Henter JI, Arico M, Egeler RM, Elinder G, Favara BE, Filipovich AH, et al. HLH-94: a treatment protocol for hemophagocytic lymphohistiocytosis. HLH study Group of the Histiocyte Society. *Med Pediatr Oncol*. 1997;28(5):342–7. [https://doi.org/10.1002/\(SICI\)1096-911X\(199705\)28:5<342::AID-MPO3>3.0.CO;2-H](https://doi.org/10.1002/(SICI)1096-911X(199705)28:5<342::AID-MPO3>3.0.CO;2-H).
23. Moshous D, Feyen O, Lankisch P, Schwarz K, Schaper J, Schneider M, et al. Primary necrotizing lymphocytic central nervous system vasculitis due to perforin deficiency in a four-year-old girl. *Arthritis Rheum*. 2007;56(3):995–9. <https://doi.org/10.1002/art.22442>.
24. Janka GE, Lehmborg K. Hemophagocytic lymphohistiocytosis: pathogenesis and treatment. *Hematology Am Soc Hematol Educ Program*. 2013;2013:605–11. <https://doi.org/10.1182/asheducation-2013.1.605>.
25. Marsh RA, Haddad E. How I treat primary haemophagocytic lymphohistiocytosis. *Br J Haematol*. 2018;182:185–99.
26. Gholam C, Grigoriadou S, Gilmour KC, Gaspar HB. Familial haemophagocytic lymphohistiocytosis: advances in the genetic basis, diagnosis and management. *Clin Exp Immunol*. 2011;163(3):271–83. <https://doi.org/10.1111/j.1365-2249.2010.04302.x>.
27. Henter JI, Horne A, Arico M, Egeler RM, Filipovich AH, Imashuku S, et al. HLH-2004: Diagnostic and therapeutic guidelines for hemophagocytic lymphohistiocytosis. *Pediatr Blood Cancer*. 2007;48(2):124–31. <https://doi.org/10.1002/pbc.21039>.
28. Zhao Y, Zhang Q, Li Z, Zhang L, Lian H, Ma H, et al. Central nervous system involvement in 179 Chinese children with hemophagocytic lymphohistiocytosis. *Chin Med J*. 2018;131(15):1786–92.

29. De Armas R, Sindou P, Gelot A, Routon MC, Ponsot G, Vallat JM. Demyelinating peripheral neuropathy associated with hemophagocytic lymphohistiocytosis. An immuno-electron microscopic study *Acta neuropathologica*. 2004;108(4):341–4. <https://doi.org/10.1007/s00401-004-0897-0>.
30. Murphy C, Nanthapaisal S, Gilmour K, Laurent S, D'Arco F, Hemingway C, et al. Progressive neurologic disorder: Initial manifestation of hemophagocytic lymphohistiocytosis. *Neurology*. 2016;86(22):2109–11. <https://doi.org/10.1212/WNL.0000000000002729>.
31. Chiapparini L, Uziel G, Vallinoto C, Bruzzone MG, Rovelli A, Tricomi G, et al. Hemophagocytic lymphohistiocytosis with neurological presentation: MRI findings and a nearly miss diagnosis. *Neurological sciences : official journal of the Italian Neurological Society and of the Italian Society of Clinical Neurophysiology*. 2011;32(3):473–7. <https://doi.org/10.1007/s10072-010-0467-2>.
32. Horne A, Wickstrom R, Jordan MB, Yeh EA, Naqvi A, Henter JL, et al. How to treat involvement of the central nervous system in hemophagocytic lymphohistiocytosis? *Curr Treat Options Neurol*. 2017;19(1):3. <https://doi.org/10.1007/s11940-017-0439-4>.
33. Goo HW, Weon YC. A spectrum of neuroradiological findings in children with haemophagocytic lymphohistiocytosis. *Pediatr Radiol*. 2007;37(11):1110–7. <https://doi.org/10.1007/s00247-007-0569-z>.
34. Guandalini M, Butler A, Mandelstam S. Spectrum of imaging appearances in Australian children with central nervous system hemophagocytic lymphohistiocytosis. *Journal of clinical neuroscience: official journal of the Neurosurgical Society of Australasia*. 2014;21(2):305–10. <https://doi.org/10.1016/j.jocn.2013.03.032>.
35. Rego I, Severino M, Micalizzi C, Faraci M, Pende D, Dufour C, et al. Neuroradiologic findings and follow-up with magnetic resonance imaging of the genetic forms of haemophagocytic lymphohistiocytosis with CNS involvement. *Pediatr Blood Cancer*. 2012;58(5):810–4. <https://doi.org/10.1002/pbc.23405>.
36. Beken B, Aytac S, Balta G, Kuskonmaz B, Uckan D, Unal S, et al. The clinical and laboratory evaluation of familial hemophagocytic lymphohistiocytosis and the importance of hepatic and spinal cord involvement: a single center experience. *Haematologica*. 2018;103(2):231–6. <https://doi.org/10.3324/haematol.2017.178038>.
37. Solomon IH, Li H, Benson LA, Henderson LA, Degar BA, Gorman MP, et al. Histopathologic correlates of familial hemophagocytic lymphohistiocytosis isolated to the central nervous system. *J Neuropathol Exp Neurol*. 2018;77(12):1079–84. <https://doi.org/10.1093/jnen/nly094>.
38. Chhabda S, Malik P, Reddy N, Muthusamy K, Mirsky D, Sudhakar S, et al. Relapsing demyelinating syndromes in children: a practical review of neuroradiological mimics. *Front Neurol*. 2020;11:627. <https://doi.org/10.3389/fneur.2020.00627>.
39. Thompson AJ, Banwell BL, Barkhof F, Carroll WM, Coetsee T, Comi G, et al. Diagnosis of multiple sclerosis: 2017 revisions of the McDonald criteria. *The Lancet Neurology*. 2018;17(2):162–73. [https://doi.org/10.1016/S1474-4422\(17\)30470-2](https://doi.org/10.1016/S1474-4422(17)30470-2).
40. Rempe T, Becktepe JS, Metz I, Bruck W, Stürner KH, Deuschl G, et al. A case of CLIPPERS syndrome responsive to tocilizumab. *Neurol Neuroimmunol Neuroinflammation*. 2019;6(3):e545. <https://doi.org/10.1212/NXI.0000000000000545>.
41. Parida A, Hemmingway C, Eleftheriou D, Wassmer E. Is it "CLIPPERS"? The expanding spectrum of Paediatric Demyelination; three cases of familial Hemophagocytic Lymphohistiocytosis (fHLH). *Dev Med Child Neurol*. 2020;62(Supplement 1):35.
42. Alter G, Malenfant JM, Altfeld M. CD107a as a functional marker for the identification of natural killer cell activity. *J Immunol Methods*. 2004;294(1–2):15–22. <https://doi.org/10.1016/j.jim.2004.08.008>.
43. Bryceson YT, Pende D, Maul-Pavicic A, Gilmour KC, Ufheil H, Vraetz T, et al. A prospective evaluation of degranulation assays in the rapid diagnosis of familial hemophagocytic syndromes. *Blood*. 2012;119(12):2754–63. <https://doi.org/10.1182/blood-2011-08-374199>.
44. Tesi B, Rascon J, Chiang SCC, Burnyte B, Lofstedt A, Fasth A, et al. A RAB27A 5' untranslated region structural variant associated with late-onset hemophagocytic lymphohistiocytosis and normal pigmentation. *J Allergy Clin Immunol*. 2018;142(1):317–21 e8. <https://doi.org/10.1016/j.jaci.2018.02.031>.
45. Lehmborg K, Moshous D, Booth C. Haematopoietic stem cell transplantation for primary haemophagocytic lymphohistiocytosis. *Front Pediatr*. 2019;7:435. <https://doi.org/10.3389/fped.2019.00435>.
46. Bergsten E, Horne A, Hed Myrberg I, Arico M, Astigarraga I, Ishii E, et al. Stem cell transplantation for children with hemophagocytic lymphohistiocytosis: results from the HLH-2004 study. *Blood Adv*. 2020;4(15):3754–66. <https://doi.org/10.1182/bloodadvances.202002101>.
47. Nikiforow S, Berliner N. Targeting the inflammatory cascade in haemophagocytic lymphohistiocytosis. *The Lancet Haematology*. 2019;6:e602–3.
48. Mahlaoui N, Ouachee-Chardin M, de Saint BG, Neven B, Picard C, Blanche S, et al. Immunotherapy of familial hemophagocytic lymphohistiocytosis with antithymocyte globulins: a single-center retrospective report of 38 patients. *Pediatrics*. 2007;120(3):e622–8. <https://doi.org/10.1542/peds.2006-3164>.
49. Gerard LM, Xing K, Sherif I, Granton J, Barth D, Abdelhaleem M, et al. Adult hemophagocytic lymphohistiocytosis with severe pulmonary hypertension and a novel perforin gene mutation. *Int J*

- Hematol. 2012;95(4):445–50. <https://doi.org/10.1007/s12185-012-1029-6>.
50. Strout MP, Seropian S, Berliner N. Alemtuzumab as a bridge to allogeneic SCT in atypical hemophagocytic lymphohistiocytosis. *Nat Rev Clin Oncol*. 2010;7(7):415–20. <https://doi.org/10.1038/nrclinonc.2010.40>.
51. Marsh RA, Allen CE, McClain KL, Weinstein JL, Kanter J, Skiles J, et al. Salvage therapy of refractory hemophagocytic lymphohistiocytosis with alemtuzumab. *Pediatr Blood Cancer*. 2013;60(1):101–9. <https://doi.org/10.1002/pbc.24188>.
52. EMA launches 'urgent safety review' of alemtuzumab after two patient deaths. *Pharm J*. 2019. <https://pharmaceutical-journal.com/article/news/ema-launches-urgent-safety-review-of-alemtuzumab-after-two-patient-deaths>.
53. Cooper N, Rao K, Gilmour K, Hadad L, Adams S, Cale C, et al. Stem cell transplantation with reduced-intensity conditioning for hemophagocytic lymphohistiocytosis. *Blood*. 2006;107(3):1233–6. <https://doi.org/10.1182/blood-2005-05-1819>.
54. Marsh RA, Vaughn G, Kim MO, Li D, Jodele S, Joshi S, et al. Reduced-intensity conditioning significantly improves survival of patients with hemophagocytic lymphohistiocytosis undergoing allogeneic hematopoietic cell transplantation. *Blood*. 2010;116(26):5824–31. <https://doi.org/10.1182/blood-2010-04-282392>.
55. Rao K, Adams S, Qasim W, Allwood Z, Worth A, Silva J, et al. Effect of stem cell source on long-term chimerism and event-free survival in children with primary immunodeficiency disorders after fludarabine and melphalan conditioning regimen. *J Allergy Clin Immunol*. 2016;138(4):1152–60. <https://doi.org/10.1016/j.jaci.2016.01.053>.
56. Cooper N, Rao K, Goulden N, Webb D, Amrolia P, Veys P. The use of reduced-intensity stem cell transplantation in haemophagocytic lymphohistiocytosis and Langerhans cell histiocytosis. *Bone Marrow Transplant*. 2008;42(Suppl 2):S47–50. <https://doi.org/10.1038/bmt.2008.283>.
57. Marsh RA, Jordan MB, Filipovich AH. Reduced-intensity conditioning haematopoietic cell transplantation for haemophagocytic lymphohistiocytosis: an important step forward. *Br J Haematol*. 2011;154(5):556–63. <https://doi.org/10.1111/j.1365-2141.2011.08785.x>.
58. Neven B, Diana JS, Castelle M, Magnani A, Rosain J, Touzot F, et al. Haploidentical hematopoietic stem cell transplantation with post-transplant cyclophosphamide for primary immunodeficiencies and inherited disorders in children. *Biology of blood and marrow transplantation : journal of the American Society for Blood and Marrow Transplantation*. 2019;25(7):1363–73. <https://doi.org/10.1016/j.bbmt.2019.03.009>.
59. Hartz B, Marsh R, Rao K, Henter JI, Jordan M, Filipovich L, et al. The minimum required level of donor chimerism in hereditary hemophagocytic lymphohistiocytosis. *Blood*. 2016;127(25):3281–90. <https://doi.org/10.1182/blood-2015-12-684498>.
60. Ouachee-Chardin M, Elie C, de Saint BG, Le Deist F, Mahlaoui N, Picard C, et al. Hematopoietic stem cell transplantation in hemophagocytic lymphohistiocytosis: a single-center report of 48 patients. *Pediatrics*. 2006;117(4):e743–50. <https://doi.org/10.1542/peds.2005-1789>.
61. Sparber-Sauer M, Honig M, Schulz AS, zur Stadt U, Schutz C, Debatin KM, et al. Patients with early relapse of primary hemophagocytic syndromes or with persistent CNS involvement may benefit from immediate hematopoietic stem cell transplantation. *Bone Marrow Transplant*. 2009;44(6):333–8. <https://doi.org/10.1038/bmt.2009.34>.
62. Li H, Benson LA, Henderson LA, Solomon IH, Kennedy AL, Soldatos A, et al. Central nervous system-restricted familial hemophagocytic lymphohistiocytosis responds to hematopoietic cell transplantation. *Blood Adv*. 2019;3(4):503–7. <https://doi.org/10.1182/bloodadvances.2018027417>.
63. Cetica V, Sieni E, Pende D, Danesino C, De Fusco C, Locatelli F, et al. Genetic predisposition to hemophagocytic lymphohistiocytosis: report on 500 patients from the Italian registry. *J Allergy Clin Immunol*. 2016;137(1):188–96 e4. <https://doi.org/10.1016/j.jaci.2015.06.048>.
64. Tesi B, Lagerstedt-Robinson K, Chiang SC, Ben Bdira E, Abboud M, Belen B, et al. Targeted high-throughput sequencing for genetic diagnostics of hemophagocytic lymphohistiocytosis. *Genome medicine*. 2015;7:130. <https://doi.org/10.1186/s13073-015-0244-1>.
65. Bergsten E, Horne A, Arico M, Astigarraga I, Egeler RM, Filipovich AH, et al. Confirmed efficacy of etoposide and dexamethasone in HLH treatment: long-term results of the cooperative HLH-2004 study. *Blood*. 2017;130(25):2728–38. <https://doi.org/10.1182/blood-2017-06-788349>.
66. Das R, Guan P, Sprague L, Verbist K, Tedrick P, An QA, et al. Janus kinase inhibition lessens inflammation and ameliorates disease in murine models of hemophagocytic lymphohistiocytosis. *Blood*. 2016;127(13):1666–75. <https://doi.org/10.1182/blood-2015-12-684399>.
67. Maschalidi S, Sepulveda FE, Garrigue A, Fischer A, de Saint BG. Therapeutic effect of JAK1/2 blockade on the manifestations of hemophagocytic lymphohistiocytosis in mice. *Blood*. 2016;128(1):60–71. <https://doi.org/10.1182/blood-2016-02-700013>.
68. Hatterer E, Richard F, Malinge P, Sergé S, Startchick S, Kosco-Vilbois M, et al. P156 Investigating the novel mechanism of action for NI-0501, a human interferon gamma monoclonal antibody. *Cytokine*. 2012;59(3):570.
69. Vainchenker W, Leroy E, Gilles L, Marty C, Plo I, Constantinescu SN. JAK inhibitors for the treatment of myeloproliferative neoplasms and other

- disorders. *F1000 Res.* 2018;7:82. <https://doi.org/10.12688/f1000research.13167.1>.
70. Goldsmith SR, Saif Ur Rehman S, Shirai CL, Vij K, DiPersio JF. Resolution of secondary hemophagocytic lymphohistiocytosis after treatment with the JAK1/2 inhibitor ruxolitinib. *Blood Adv.* 2019;3(23):4131–5. <https://doi.org/10.1182/bloodadvances.2019000898>.
 71. Sin JH, Zangardi ML. Ruxolitinib for secondary hemophagocytic lymphohistiocytosis: First case report. *Hematol Oncol Stem Cell Ther.* 2019;12(3):166–70. <https://doi.org/10.1016/j.hemonc.2017.07.002>.
 72. Wang J, Wang Y, Wu L, Wang X, Jin Z, Gao Z, et al. Ruxolitinib for refractory/relapsed hemophagocytic lymphohistiocytosis. *Haematologica.* 2020;105(5):e210–2. <https://doi.org/10.3324/haematol.2019.222471>.
 73. Locatelli F, Jordan MB, Allen C, Cesaro S, Rizzari C, Rao A, et al. Emapalumab in children with primary hemophagocytic lymphohistiocytosis. *N Engl J Med.* 2020;382(19):1811–22. <https://doi.org/10.1056/NEJMoa1911326>.
 74. Agency EM. Gamifant: Opinion. 2020. <https://www.ema.europa.eu/en/medicines/human/summaries-opinion/gamifant>.
 75. Al-Salama ZT. Emapalumab: first global approval. *Drugs.* 2019;79(1):99–103. <https://doi.org/10.1007/s40265-018-1046-8>.
 76. Tanaka T, Narazaki M, Ogata A, Kishimoto T. A new era for the treatment of inflammatory autoimmune diseases by interleukin-6 blockade strategy. *Semin Immunol.* 2014;26(1):88–96. <https://doi.org/10.1016/j.smim.2014.01.009>.
 77. Brandstadter R, Katz SI. The use of natalizumab for multiple sclerosis. *Neuropsychiatr Dis Treat.* 2017;13:1691–702. <https://doi.org/10.2147/NDT.S114636>.
 78. Aytac S, Batu ED, Unal S, Bilginer Y, Cetin M, Tuncer M, et al. Macrophage activation syndrome in children with systemic juvenile idiopathic arthritis and systemic lupus erythematosus. *Rheumatol Int.* 2016;36(10):1421–9. <https://doi.org/10.1007/s00296-016-3545-9>.
 79. Barut K, Yucel G, Sinoplu AB, Sahin S, Adrovic A, Kasapcopur O. Evaluation of macrophage activation syndrome associated with systemic juvenile idiopathic arthritis: single center experience over a one-year period. *Turk pediatri arsivi.* 2015;50(4):206–10. <https://doi.org/10.5152/TurkPediatriArs.2015.3299>.
 80. Ravelli A, Grom A, Behrens EM, Cron RQ. Macrophage activation syndrome as part of systemic juvenile idiopathic arthritis: diagnosis, genetics, pathophysiology and treatment. *Genes Immun.* 2012;13:289–98.
 81. Sonmez HE, Demir S, Bilginer Y, Ozen S. Anakinra treatment in macrophage activation syndrome: a single center experience and systemic review of literature. *Clin Rheumatol.* 2018;37(12):3329–35. <https://doi.org/10.1007/s10067-018-4095-1>.
 82. Dufranc E, Del Bello A, Belliere J, Kamar N, Faguer S. IL6-R blocking with tocilizumab in critically ill patients with hemophagocytic syndrome. *Crit Care.* 2020;24(1):166. <https://doi.org/10.1186/s13054-020-02878-7>.
 83. Eloiseily EM, Weiser P, Crayne CB, Haines H, Mannion ML, Stoll ML, et al. Benefit of anakinra in treating pediatric secondary hemophagocytic lymphohistiocytosis. *Arthritis Rheumatol.* 2020;72(2):326–34. <https://doi.org/10.1002/art.41103>.
 84. Mehta P, Cron RQ, Hartwell J, Manson JJ, Tattersall RS. Silencing the cytokine storm: the use of intravenous anakinra in haemophagocytic lymphohistiocytosis or macrophage activation syndrome. *The Lancet Rheumatology.* 2020;2(6):e358–67. [https://doi.org/10.1016/S2665-9913\(20\)30096-5](https://doi.org/10.1016/S2665-9913(20)30096-5).
 85. Ghosh S, Carmo M, Calero-Garcia M, Ricciardelli I, Bustamante Ogando JC, Blundell MP, et al. T-cell gene therapy for perforin deficiency corrects cytotoxicity defects and prevents hemophagocytic lymphohistiocytosis manifestations. *J Allergy Clin Immunol.* 2018;142(3):904–13 e3. <https://doi.org/10.1016/j.jaci.2017.11.050>.
 86. Dettmer V, Bloom K, Gross M, Weissert K, Aichele P, Ehl S, et al. Retroviral UNC13D gene transfer restores cytotoxic activity of t cells derived from familial hemophagocytic lymphohistiocytosis type 3 patients in vitro. *Hum Gene Ther.* 2019;30(8):975–84. <https://doi.org/10.1089/hum.2019.025>.

Publisher's Note

Springer Nature remains neutral with regard to jurisdictional claims in published maps and institutional affiliations.