



## Clinical applications of magnetic resonance imaging based functional and structural connectivity



Chengyuan Wu<sup>a,b,\*</sup>, Francisca Ferreira<sup>c,d</sup>, Michael Fox<sup>e</sup>, Noam Harel<sup>f</sup>, Jona Hattangadi-Gluth<sup>g</sup>, Andreas Horn<sup>h</sup>, Saad Jbabdi<sup>i</sup>, Joshua Kahan<sup>j</sup>, Ashwini Oswal<sup>k</sup>, Sameer A. Sheth<sup>l</sup>, Yanmei Tie<sup>e,m</sup>, Vejay Vakharia<sup>c</sup>, Ludvic Zrinzo<sup>c,d</sup>, Harith Akram<sup>c,d</sup>

<sup>a</sup> Department of Neurological Surgery, Vickie and Jack Farber Institute for Neuroscience, Thomas Jefferson University, 909 Walnut Street, Third Floor, Philadelphia, PA 19107, USA

<sup>b</sup> Jefferson Integrated Magnetic Resonance Imaging Center, Department of Radiology, Thomas Jefferson University, 909 Walnut Street, First Floor, Philadelphia, PA 19107, USA

<sup>c</sup> Victor Horsley Department of Neurosurgery, National Hospital for Neurology and Neurosurgery, 33 Queen Square, London WC1N 3BG, UK

<sup>d</sup> Unit of Functional Neurosurgery, UCL Queen Square Institute of Neurology, 33 Queen Square, London WC1N 3BG, UK

<sup>e</sup> Center for Brain Circuit Therapeutics, Departments of Neurology, Psychiatry, Radiology, and Neurosurgery, Brigham and Women's Hospital, Harvard Medical School, 60 Fenwood Road, Boston, MA 02115, USA

<sup>f</sup> Center for Magnetic Resonance Research, University of Minnesota, 2021 Sixth Street S.E., Minneapolis, MN 55455, USA

<sup>g</sup> Department of Radiation Medicine and Applied Sciences, Center for Precision Radiation Medicine, University of California, San Diego, 3855 Health Sciences Drive, La Jolla, CA 92037, USA

<sup>h</sup> Neurology Department, Movement Disorders and Neuromodulation Section, Charité – University Medicine Berlin, Charitéplatz 1, D-10117, Berlin, Germany

<sup>i</sup> Wellcome Centre for Integrative Neuroimaging, Centre for Functional MRI of the Brain, Nuffield Department of Clinical Neurosciences, John Radcliffe Hospital, University of Oxford, Oxford OX3 9DU, UK

<sup>j</sup> Department of Neurology, Weill Cornell Medicine, 525 East 68th Street, New York, NY, 10065, USA

<sup>k</sup> Medical Research Council Brain Network Dynamics Unit, University of Oxford, Mansfield Rd, Oxford OX1 3TH, UK

<sup>l</sup> Department of Neurosurgery, Baylor College of Medicine, 7200 Cambridge, Ninth Floor, Houston, TX 77030, USA

<sup>m</sup> Department of Neurosurgery, Brigham and Women's Hospital, Harvard Medical School, 60 Fenwood Road, Boston, MA 02115, USA

**Abbreviations:** ADC, Apparent diffusion coefficient; ALIC, Anterior limb of the internal capsule; ASL, Arterial spin labeling; BOLD, Blood oxygen level-dependent; CCEP, Corticocortical evoked potential; CT, Computed tomography; cZI, Caudal zona incerta; dACC, Dorsal anterior cingulate cortex; DBS, Deep brain stimulation; DMN, Default mode network; dMRI, Diffusion magnetic resonance imaging; DTC, Dentato-thalamo-cortical pathways; DTI, Diffusion tensor imaging; ECS, Electro-cortical stimulation; EEG, Electroencephalography; ET, Essential tremor; FDA, Food and Drug Administration; fMRI, Functional magnetic resonance imaging; GKR, Gamma knife radiation; GPi, Globus pallidus pars interna; GPU, Graphics processing unit; GS, Global signal; GSR, Global signal regression; IC, Independent component; ICA, Independent component analysis; IED, Interictal epileptiform discharge; LGG, Low-grade glioma; M1, Primary motor cortex; MRI, Magnetic resonance imaging; OCD, Obsessive-compulsive disorder; PD, Parkinson's disease; RF, Radiofrequency; ROI, Region of Interest; rs-fMRI, Resting-state functional magnetic resonance imaging; RSN, Resting state network; RT, Radiotherapy; SCA, Seed-based correlation analysis; SCC, Sub-callosal cingulate; SMA, Supplementary motor area; SNR, Signal-to-noise ratio; SRS, Stereotactic radiosurgery; STN, Subthalamic nucleus; TLE, Temporal lobe epilepsy; TR, Repetition time; TRD, Treatment-resistant depression; tb-fMRI, Task-based functional magnetic resonance imaging; VC/Vs, Ventral capsule/ventral striatum; Vim, Ventral intermediate nucleus.

\* Corresponding author at: Department of Neurosurgery, Vickie and Jack Farber Institute for Neuroscience, Thomas Jefferson University, 909 Walnut Street, Third Floor, Philadelphia, PA 19107, USA.

**E-mail addresses:** [Chengyuan.Wu@jefferson.edu](mailto:Chengyuan.Wu@jefferson.edu) (C. Wu), [francisca.ferreira.16@ucl.ac.uk](mailto:francisca.ferreira.16@ucl.ac.uk) (F. Ferreira), [mdfox@bwh.harvard.edu](mailto:mdfox@bwh.harvard.edu) (M. Fox), [HAREL002@umn.edu](mailto:HAREL002@umn.edu) (N. Harel), [jhattangadi@health.ucsd.edu](mailto:jhattangadi@health.ucsd.edu) (J. Hattangadi-Gluth), [andreas.horn@charite.de](mailto:andreas.horn@charite.de) (A. Horn), [saad.jbabdi@ndcn.ox.ac.uk](mailto:saad.jbabdi@ndcn.ox.ac.uk) (S. Jbabdi), [jok2041@nyp.org](mailto:jok2041@nyp.org) (J. Kahan), [ashwini.oswal@bndu.ox.ac.uk](mailto:ashwini.oswal@bndu.ox.ac.uk) (A. Oswal), [sameer.sheth@bcm.edu](mailto:sameer.sheth@bcm.edu) (S.A. Sheth), [ytie@bwh.harvard.edu](mailto:ytie@bwh.harvard.edu) (Y. Tie), [v.vakharia@ucl.ac.uk](mailto:v.vakharia@ucl.ac.uk) (V. Vakharia), [l.zrinzo@ucl.ac.uk](mailto:l.zrinzo@ucl.ac.uk) (L. Zrinzo), [harith.akram@ucl.ac.uk](mailto:harith.akram@ucl.ac.uk) (H. Akram).

<https://doi.org/10.1016/j.neuroimage.2021.118649>.

Received 15 April 2021; Received in revised form 24 September 2021; Accepted 10 October 2021

Available online 11 October 2021.

1053-8119/© 2021 The Authors. Published by Elsevier Inc. This is an open access article under the CC BY-NC-ND license

(<http://creativecommons.org/licenses/by-nc-nd/4.0/>)

## ARTICLE INFO

## Keywords:

Connectome  
Connectomics  
Structural connectivity  
Tractography  
Functional connectivity  
Clinical applications

## ABSTRACT

Advances in computational neuroimaging techniques have expanded the armamentarium of imaging tools available for clinical applications in clinical neuroscience. Non-invasive, *in vivo* brain MRI structural and functional network mapping has been used to identify therapeutic targets, define eloquent brain regions to preserve, and gain insight into pathological processes and treatments as well as prognostic biomarkers. These tools have the real potential to inform patient-specific treatment strategies. Nevertheless, a realistic appraisal of clinical utility is needed that balances the growing excitement and interest in the field with important limitations associated with these techniques. Quality of the raw data, minutiae of the processing methodology, and the statistical models applied can all impact on the results and their interpretation. A lack of standardization in data acquisition and processing has also resulted in issues with reproducibility. This limitation has had a direct impact on the reliability of these tools and ultimately, confidence in their clinical use. Advances in MRI technology and computational power as well as automation and standardization of processing methods, including machine learning approaches, may help address some of these issues and make these tools more reliable in clinical use. In this review, we will highlight the current clinical uses of MRI connectomics in the diagnosis and treatment of neurological disorders; balancing emerging applications and technologies with limitations of connectivity analytic approaches to present an encompassing and appropriate perspective.

## 1. Introduction

The success of intracranial interventions relies on accurate and precise visualization and mapping of relevant anatomical brain structures. Developments in imaging techniques has evolved in parallel and enabled advances in neurosurgery and radiosurgery. The ability to ‘see’ inside the skull meant that neurosurgeons could plan to remove structural abnormalities such as tumors, blood clots, and brain abscesses. Cortical, subcortical brain regions, and large white matter bundles have been studied through anatomical dissection studies. (Horsley and Schafer, 1888) Post-mortem lesion studies (following strokes, trauma or surgery) provided various pieces of the jigsaw to map out functional regions, (Brodmann, 1909) and direct electrical stimulation during neurosurgical procedures in awake patients provided a means to map brain function (Penfield, 1972, Ferrier, 1886, Hughlings Jackson, 1868, Horsely, 1886). It was not until the arrival of advanced MRI methods that *in vivo* structural and functional connectivity studies was possible in humans.

Prior to the advent of computed tomography (CT) and magnetic resonance imaging (MRI), the historical inability to directly visualize neuroanatomy was tackled by the development of stereotactic atlases, providing an estimation of spatial relations with respect to landmarks visible on ventriculography or angiography such as the anterior and posterior commissures. (Spiegel et al., 1947) This approach, however, lacked the ability to identify individual anatomic variability. The use of invasive intraoperative mapping and target adjustment was therefore crucial. (Akram et al., 2018) While the introduction of CT allowed visualization of landmarks in a non-invasive fashion, it was the advent of MRI that made it possible to directly visualize and localize target structures. Lars Leksell emphasized that “stereotactic localization ... is part of the therapeutic procedure ... is the surgeon’s responsibility and should be closely integrated with the operation.” (Leksell et al., 1985)

The subsequent introduction of diffusion-weighted MR imaging has allowed for *in vivo* localization of relevant targets by dint of their MR connectivity. While structural connectivity typically allows for the exploration of monosynaptic connections, functional connectivity can identify polysynaptic connections through the identification of areas with synchronized activity. Functional imaging of metabolic activity or blood flow using positron emission tomography and functional MRI (fMRI) has provided theoretical impetus to the identification of potential surgical targets in a variety of different pathologies. (Hamani et al., 2011, May et al., 1998) Functional connectivity imaging has also been used as a research tool to shed light on the physiologic mechanisms leading to clinical improvement after surgical intervention. (Kahan et al., 2012)

Ultimately, the continued evolution of computational neuroimaging techniques has expanded the armamentarium of imaging tools available

for clinical applications in Neurosurgery, Neuro-Oncology, and Neuro-radiology. The ability to visualize structural connectivity has become particularly useful in clinical applications where white matter pathways may either determine the therapeutic target or define regions that must be preserved during treatment – delineations that are needed when tissue MR contrast is lacking on structural MRI sequences. Meanwhile, functional connectivity can be used to gain insight into whole brain network changes that may occur in response to pathological processes or therapeutic interventions. Analyses of both structural and functional connectivity can potentially inform patient-specific treatment strategies by providing insight into the interconnections between various brain regions. (Hagmann, 2005, Sporns et al., 2005)

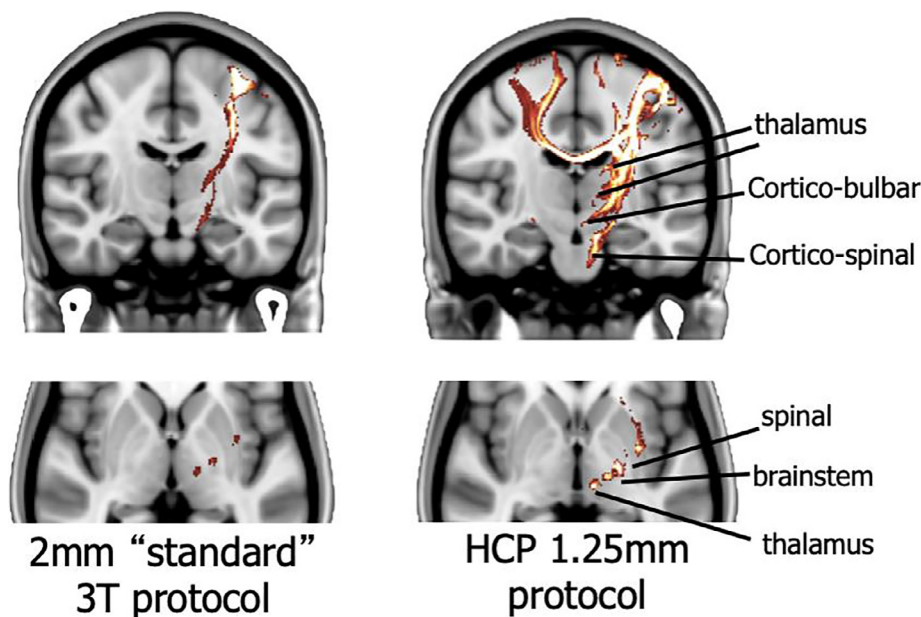
This non-invasive mapping of networks in the *in vivo* human brain has led to the birth of a field focused on the study of brain networks, or connectomes, which has been dubbed as *connectomics* – the formal description of the whole brain and its interconnections. Since the term was introduced in 2005, (Sporns et al., 2005) this field has blossomed and continues to gain interest. (Sporns and Bassett, 2018) By improving our understanding of underlying pathophysiology and mechanisms of therapeutic interventions, such research has the potential to improve patient selection for treatment, allow for tailored surgical planning, improve the efficacy of surgical interventions, and support outcome prediction.

With the excitement and interest that accompanies the rapid growth of research in brain connectivity and connectomics, it can be easy to overlook the barriers to clinical applications. We therefore intend to highlight the current clinical uses of structural and functional connectivity in the diagnosis and treatment of neurological disorders; while balancing emerging applications and technologies with limitations of connectivity analytic approaches to provide appropriate perspective.

## 2. Data acquisition and analysis of connectivity MRI data

## 2.1. Diffusion MRI

Diffusion MRI (dMRI) allows measurements of random molecular motion of water molecules in a medium or tissue. By analyzing the directional propensity of this random (Brownian) motion, we can infer the distribution of one or more axonal bundle orientations (which hinder diffusion in particular directions) within each imaging voxel. (Le Bihan, 2003) This makes dMRI uniquely capable of providing information on the route of white matter pathways *in vivo*. dMRI has long been routinely used clinically, particularly for mapping apparent diffusion coefficients (ADC) in the context of acute stroke. (Lansberg et al., 2001) But in recent years, its use in mapping connectivity for surgical planning has expanded. (Romano et al., 2009, Essayed et al., 2017, Rodrigues et al., 2018) While ADC mapping is a quick scan with minimal overhead, mapping connectivity is more involved and requires more care.



**Fig. 1.** The importance of high-resolution diffusion data. Increased resolution of diffusion data can help increase the sensitivity of fiber tracking.

Mapping structural connectivity in an individual patient with sufficient accuracy requires both good quality data and careful processing. (Sotiropoulos et al., 2013) In deciding on the optimal set of acquisition parameters, many factors need to be balanced, often against each other. A protocol is optimized for the needs of a given application. For example, with high spatial resolution ( $\sim 1\text{-}1.5\text{mm}$ ) one can better resolve white matter projections to different subcortical targets, (Sotiropoulos and Zalesky, 2019) which is important in deep brain stimulation (DBS) applications. [Fig. 1]

If one is instead interested in mapping the bulk of major pathways for planning tumor surgery, it is more important to be able to model crossing fibers in each voxel, and thus the emphasis is on acquiring data with multiple gradient orientations and a sufficiently high  $b$ -value to have good orientational contrast. (Jbabdi et al., 2012, Behrens et al., 2007) In both cases (spatial resolution vs. diffusion contrast), this needs to be balanced against a lower SNR and longer scan times. It is important to run pilot acquisitions and design tests that are tailored for the application to ensure test-retest reliability.

Once data have been collected, the standard analysis pipeline is as follows: (1) correction for motion and geometric distortions, (Kober et al., 2012, Andersson et al., 2003) (2) image registration to high resolution anatomical scans, (Klein et al., 2009) (3) voxelwise modelling of diffusion (modelling the diffusivity in each individual voxel), (Dell'Acqua and Tournier, 2019) (4) tractography (modelling diffusivity across multiple voxels) (Catani et al., 2002). All these steps involve different methodological choices that can affect the final outcome. However, step (1) is crucial for anatomical fidelity, yet it is often overlooked.

Echo planar imaging, which remains the predominant method for dMRI acquisition is subject to geometric distortions caused by variations in magnetic susceptibility can be of the order of centimeters in the vicinity of brain-air interfaces (e.g. temporal poles and ventral prefrontal cortex). These distortions can affect alignment with anatomical scans, which are generally undistorted, and cause major inaccuracies in mapping connections in individuals. In addition, eddy-current distortions in diffusion imaging can cause additional distortions that affect the signal modelling itself, and thus further impact downstream modelling of anatomical connectivity (steps (3) and (4)). Acquisition strategies, including field mapping for unwarping (Reber et al., 1998) and reversed phase-encoding gradients (Chang and Fitzpatrick, 1992) can be used to directly correct for such distortions. In addition, state-of-the-art academic software now allow sophisticated corrections that account

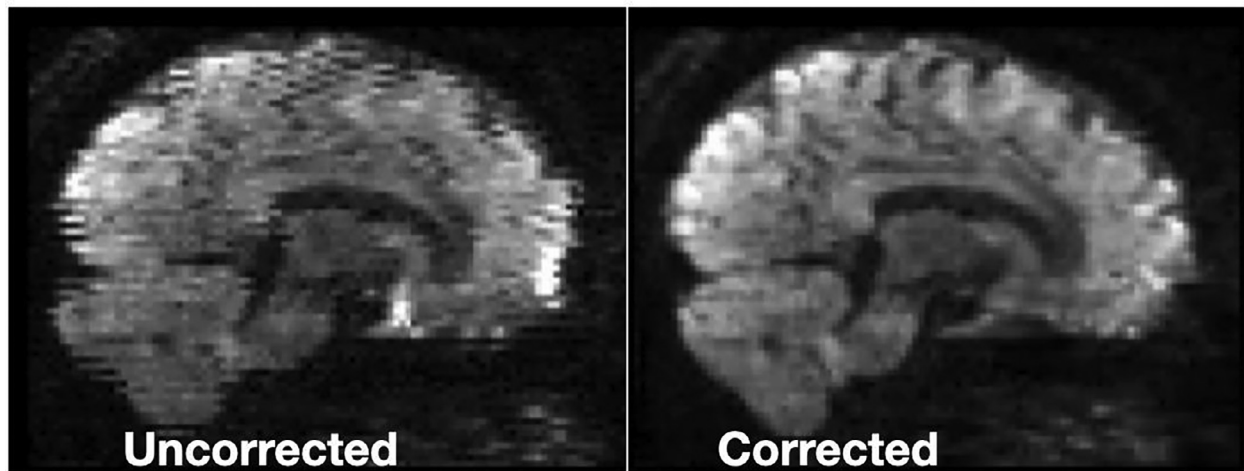
for these sources of distortions and their interactions, (Andersson et al., 2016, Andersson et al., 2017, Andersson et al., 2018) but these tools are often developmental and time consuming, requiring expertise and computer power that limits their clinical applicability. [Fig. 2]

## 2.2. Blood oxygen level-dependent imaging

Blood oxygen level-dependent (BOLD) fMRI is a 4-dimensional image that relies on multi-slice gradient-echo echoplanar imaging sequences, (Bollmann and Barth, 2020) which are particularly sensitive to changes in local ratios of paramagnetic deoxyhemoglobin to diamagnetic oxyhemoglobin. Such imaging is therefore capable of detecting local tissue oxygenation levels, which serves as a surrogate marker for levels of neuronal activity. Individual slices are typically acquired sequentially over the course of a designated repetition time (TR), which is typically on the order of 2 seconds for current clinical scans. (Wardle and Baker, 2020, Soares et al., 2016) In order to minimize the effects of slice excitation on spatially adjacent slices, images are commonly acquired with interleaved slices. (Parker et al., 2014) As part of the tradeoff between SNR and total acquisition time, the typical clinical fMRI consists of voxel sizes of 2-3mm in one direction. (Soares et al., 2016, Goense et al., 2016, Ing and Schwarzbauer, 2014, Conrad et al., 2018) With the sacrifice of spatial resolution, fMRI has a key advantage in its ability to detect temporal changes in functional activation. Significant challenges in current hardware, acquisition and reconstruction techniques, and distinction of functional activations must first be addressed if we are to overcome current limits on spatial resolution. (Bollmann and Barth, 2020, Silva et al., 2018)

Such sequences can be used to assess changes in BOLD activation associated with a specific task or event (task-based fMRI, tb-fMRI) or with the patient at rest (resting state fMRI, rs-fMRI). rs-fMRI has grown in popularity because it obviates the need for specific task paradigms and in some cases, has been shown to be comparable to tb-fMRI. (Mannfolk et al., 2011, Rosazza et al., 2014, Kokkonen et al., 2009, Dierker et al., 2017) It is important to note, however, that rs-fMRI may represent an extended 'resting task' – as patients are asked to passively rest or stare at a fixation point. (Buckner et al., 2013) With the possibility of different brain states during this 'resting task', greater temporal sampling with acquisitions of at least 12-13 minutes may be necessary to optimize the reliability of rs-fMRI. (Birn et al., 2013) Ultimately, relatively poor test-retest reliability of tb- and rs-fMRI continues to limit





**Fig. 2.** The importance of distortion correction. Geometric distortions can affect alignment with anatomical scans and cause major inaccuracies in mapping connections. It is therefore important to implement distortion correction before modeling white matter tracts with diffusion-based imaging.

the clinical applicability of these tools. (Elliott et al., 2020, Wang et al., 2017, Holiga et al., 2018)

Functional connectivity can be established by temporal correlation of BOLD signals (believed to originate in small venules) or cerebral blood flow (arterial spin labelling, ASL, which corresponds to arteriole properties) between voxels (Fox and Raichle, 2007) and represents the synchronicity of spatially discrete neurophysiological processes. (Friston, 1994) While no consensus exists on the specifics of fMRI preprocessing, it is common practice to: (1) discard the initial volumes to ensure that scanner gradients have been stabilized; (2) perform slice timing correction to account for differences created in the sequential acquisition of slices (particularly for  $TR \geq 2$  seconds); (Sladky et al., 2011) (3) perform rigid-body coregistration of fMRI with anatomical sequences and apply gray matter, white matter, and CSF masks; (4) apply motion correction to account for and quantify head movement; (5) remove outlier volumes in the sequence; and increase SNR by (6) spatially smoothing (by approximately twice the voxel size) fMRI volumes and (7) applying temporal filtering to reduce noise at unwanted frequency bands. (Soares et al., 2016) [Fig. 2] For rs-fMRI, direct effects of motion and physiologic processes must also be handled by regressing out these confounds. (Murphy et al., 2013) Of note, it may also be necessary to utilize the quantification of head motion as a covariate or nuisance variable in subsequent statistical analysis in order to account for the possibility that such motion may simultaneously generate cortical activations that affect the intended analysis.

Following preprocessing, functional connectivity is commonly analyzed in the context of specific regions of interest (ROIs), rather than between individual voxels. It is therefore important to highlight the differences in methods used to define these ROIs. With seed-based correlation analysis (SCA), BOLD activation within a pre-defined ROI is correlated with individual voxels throughout the brain or with other pre-defined ROIs. This *a priori* selection of a ROIs makes SCA well suited for investigating the functional connectivity to a specific seed region – allowing for direct testing of a specific hypothesis and straightforward interpretation of results. (Cole et al., 2010, Joel et al., 2011) Of note, the way in which these ROIs are defined can alter estimates of functional connectivity. (Cole et al., 2010, Marrelec and Fransson, 2011, Sohn et al., 2015) Since ROIs in SCA are based on anatomical or functional atlases, lack of consideration of variability between patients can introduce noise into the analysis and ultimately bias the results. Meanwhile, spatial independent component analysis (ICA) is a data-driven approach in which statistically independent, non-Gaussian components are extracted from the rs-fMRI. This approach yields ROIs defined by independent components that by definition are not highly co-linear and possess maximal

spatial independence. (Cole et al., 2010) Without *a priori* selection of ROIs, ICA serves as a useful method for exploration of intrinsically connected networks and their interactions. (Joel et al., 2011) Although ICA is inherently less prone to artifact, bias can still be introduced in the selection of independent components, which typically requires manual review. Furthermore, while this approach generates a more complete picture of whole brain networks, results of this data-driven approach can be more difficult to interpret without a clear hypothesis. Ultimately, these two approaches have been shown to produce results that differ quantitatively, but lead to comparable representations of major networks (such as motor, visual, default, and attention networks). (Marrelec and Fransson, 2011, Van Dijk et al., 2010) For exploratory investigations of functional connectivity, however, subject-specific ROIs have been shown to yield more accurate results. (Sohn et al., 2015)

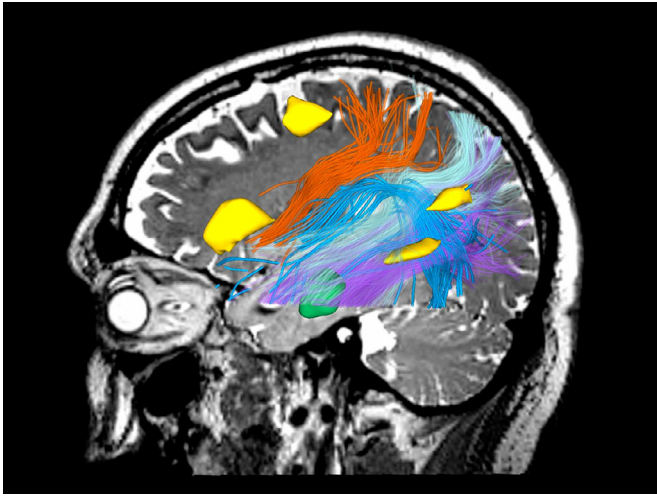
### 3. Applications in neuro-oncology and radiotherapy

Neurosurgical mapping of eloquent cortex (e.g., sensorimotor and language areas) as well as connecting white matter bundles (e.g., the pyramidal tract, visual pathways) is essential for planning safe and maximal resection of brain tumors; this mapping can also benefit intraoperative decision making and prediction of postoperative functional outcome.

#### 3.1. Clinical applications

Structural connectivity as measured by white matter tractography derived from dMRI has long been used for preoperative delineation of critical tracts for surgical planning. (Essayed et al., 2017) Use of tractography has been associated with the extent of tumor resection and functional outcomes. (Essayed et al., 2017, Henderson et al., 2020) Advanced approaches, such as multi-fiber tractography (to better identify crossing fibers within a single voxel) (Gong et al., 2018, Chen et al., 2016, Chen et al., 2015) and free water modeling (Gong et al., 2018, Parker et al., 2020), have also been developed for sensitive white matter tract identification in challenging situations where crossing fiber and peritumoral edema are present.

With its ability to investigate large-scale resting-state networks (RSNs), (Fox and Raichle, 2007, Biswal et al., 1995) rs-fMRI has gained traction for neurosurgical brain mapping because it does not require active task performance, and thus can be deployed in patients with neurological deficits who may not be able to undergo conventional tb-fMRI. (Kokkonen et al., 2009, Liu et al., 2009, Zhang et al., 2009) While earlier studies focused on sensorimotor mapping, more recent work has mapped



**Fig. 3.** rs-fMRI ICA-derived language component (yellow) (Tie et al., 2014) and language-related white matter tracts of a patient with a recurrent left temporal glioblastoma multiforme tumor (green). Identified tracts include the arcuate fasciculus (blue), medial longitudinal fasciculus (cyan), inferior longitudinal fasciculus (purple), and the superior longitudinal fasciculus (orange). Tractography parcellation (anatomical tract identification) was performed using the whitematteranalysis package and the ORG tractography atlas (<http://dmri.slicer.org/atlas/>). (Zhang et al., 2018, O'Donnell et al., 2017). (For interpretation of the references to color in this figure legend, the reader is referred to the web version of this article.)

the complex and highly individually variable language networks with SCA (Hsu et al., 2020) or ICA (Branco et al., 2016, Lu et al., 2017, Tie et al., 2014). [Fig. 3]

These rs-fMRI-based functional connectivity approaches require expertise for seed selection (for SCA) or identification of components-of-interest (for ICA), which may be challenged by tumor-induced mass effect, anatomic distortion, and functional reorganization. Automated rs-fMRI analytic approaches based on supervised machine learning algorithms have shown promising results in mapping of eloquent cortex (Penfield, 1972, Leuthardt et al., 2018, Mitchell et al., 2013, Luckett et al., 2020) and prediction of tb-fMRI activations (Parker Jones et al., 2017) in patient populations.

Validation of rs-fMRI-based functional connectivity for mapping of eloquent cortex in brain tumor patients has shown good concordance between RSN maps and clinical gold-standard of brain mapping, such as intraoperative electrocortical stimulation (ECS). (Rosazza et al., 2014, Zhang et al., 2009, Mitchell et al., 2013, Zaca et al., 2018, Qiu et al., 2014, Cochereau et al., 2016, Fox et al., 2016, Wang et al., 2015) In a large study of 98 patients with a diffuse low-grade glioma (LGG), significant correlation between SCA-identified RSNs and ECS sites was observed. (Cochereau et al., 2016) Furthermore, when compared to tb-fMRI, rs-fMRI has shown lower failure rates in mapping eloquent cortex in tumor patients. (Rosazza et al., 2014, Branco et al., 2016, Leuthardt et al., 2018)

### 3.2. Current research

#### 3.2.1. Functional reorganization in brain tumor patients

The dynamic connectome perspective promotes a paradigm shift from the localizationism to network-based approach in neurosurgical brain mapping. This approach can be a powerful tool to study functional reorganization in tumor patients, particularly those with slow growing, intrinsic tumors such as LGG. (Desmurget et al., 2007) Language network reorganization has been demonstrated in these patients, by comparing brain network changes before and after tumor resection, or by

comparing preoperative LGG patients with healthy subjects. (Jin et al., 2021, van Dokkum et al., 2019)

#### 3.2.2. Microstructural injury induced by intracranial radiotherapy

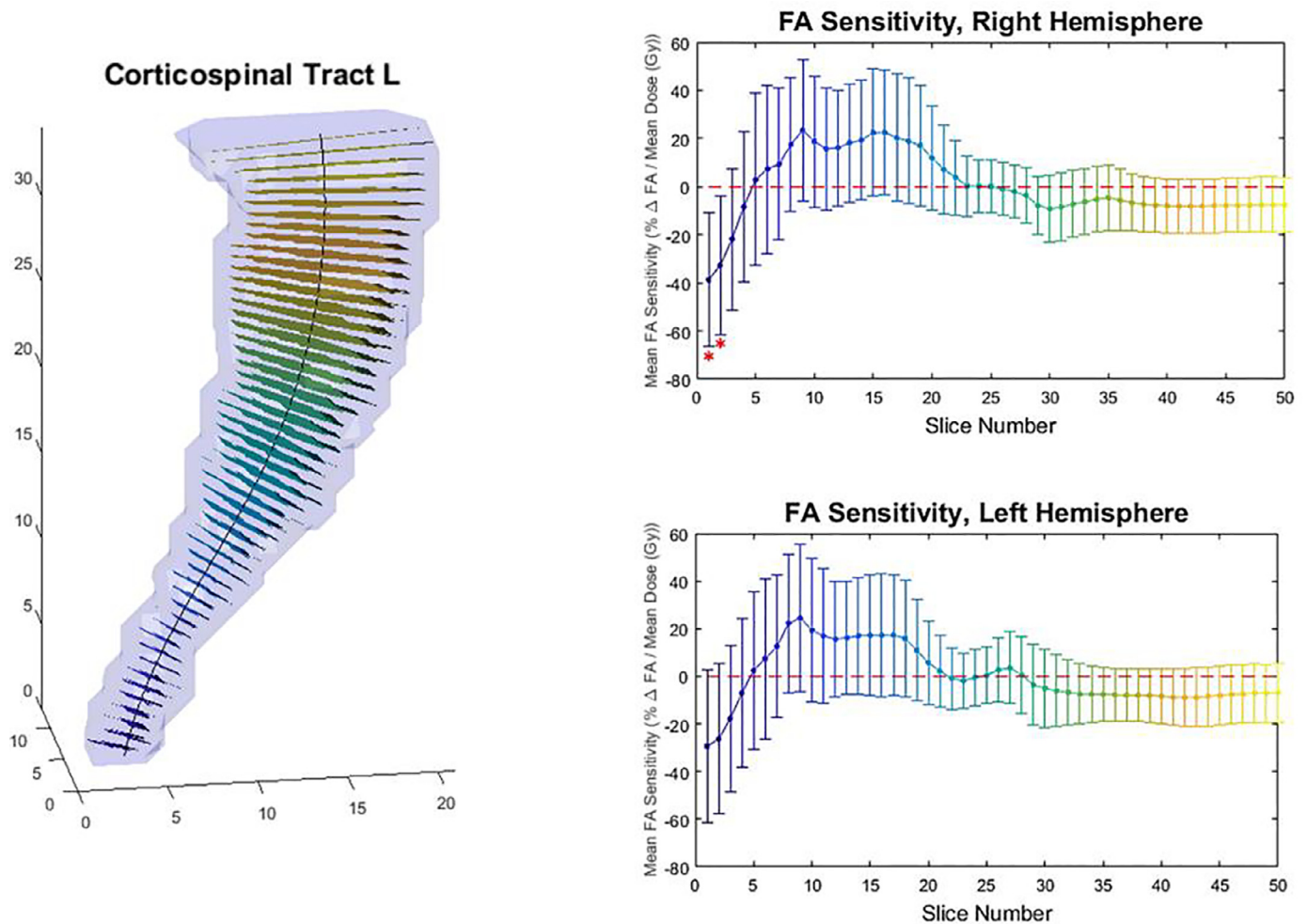
Intracranial radiotherapy (RT) is an indispensable noninvasive tool for the management of primary and metastatic brain tumors. However, brain RT is associated with potential for neurocognitive decline, likely due to injury to eloquent tissue. (Greene-Schloesser et al., 2012) The pathogenesis of radiation-induced brain injury is complex, driven in part by vascular injury, neuroinflammation, and depletion of neurogenic progenitor cells. (Brown et al., 2005, Greene-Schloesser and Robbins, 2012, Wu et al., 2012, Monje et al., 2002, Makale et al., 2017) Thus, efforts to create safer, more precise radiation treatments by preserving structural and functional connectivity are paramount. (Duffau, 2020) Advanced neuroimaging techniques and quantitative imaging biomarkers allow us to better understand microstructural injury as it contributes to cognitive decline, and to guide efforts to avoid unnecessary damage to eloquent areas.

Changes in dMRI biomarkers correlate with pathologic white matter demyelination and axonal injury in animal models treated with RT. (Wang et al., 2009, Peiffer et al., 2010) In humans, dMRI is used to study radiation-induced white matter changes. (Connor et al., 2016, Zhu et al., 2016) with greater susceptibility to injury among white matter tracts critical for neurocognition. (Connor et al., 2017) [Fig. 4] Furthermore, the particular susceptibility of neurocognitive networks has also been demonstrated with rs-fMRI. (Mitchell et al., 2020)

Radiation dose-dependent white matter injury has been demonstrated, using different b-values to query extra-axonal versus intra-axonal white matter compartments. (Connor et al., 2016) Moreover, an association between diffusion biomarkers of white matter injury and cognitive functioning in brain tumor patients has been shown in multiple studies, (Chapman et al., 2012, Chapman et al., 2016) including domain-specific studies of memory, (Tringale et al., 2019) language, (Tibbs et al., 2020) attention and processing speed, (Huynh-Le et al., 2021) and executive functioning. (Tringale et al., 2019) Tractography has been used to guide white matter tract sparing efforts with RT, (Wang et al., 2015, Koga et al., 2012) though most studies are small and retrospective. Prospective investigation of such techniques in RT planning are warranted; a novel clinical trial of image-guided white matter and hippocampal sparing stereotactic radiosurgery (SRS) in brain metastases is ongoing. (<https://clinicaltrials.gov/ct2/show/NCT04343157>) [Fig. 5]

#### 3.2.3. Movie-watching fMRI

More recently, a promising brain mapping approach of using movie-watching fMRI (mw-fMRI) (Spiers and Maguire, 2007, Hasson et al., 2004) has gained attraction in studies consisting of psychiatric (Eickhoff et al., 2020) and pediatric populations (Vanderwal et al., 2019). mw-fMRI uses naturalistic and ecologically valid stimuli that mimic real-life experience, thus it can probe neural activity involving emotion, cognition, mentalization, and theory-of-mind. Compared to typical language mapping tasks, movie-watching can better engage the distributed, multimodal neural networks that support language function in real life, including the preserved functional areas in patients with language deficits. The feasibility of mw-fMRI for mapping putative language areas in individual subjects has been demonstrated in healthy controls. (Tie et al., 2015) A more recent study in 34 brain tumor patients demonstrated reduced in-scanner head motion, higher mapping sensitivity in receptive language areas, and overall higher language mapping specificity (with respect to a multimodal canonical language template), of mw-fMRI versus antonym generation task-based fMRI. (Yao et al., 2021) Future studies on mw-fMRI paradigm design, related connectome approach development, intra-operative mapping of non-eloquent functions, (Yordanova et al., 2019, Duffau, 2021) and incorporation of systematic neuropsychological assessment will help to advance neurosur-



**Fig. 4.** Novel computational tools allow exploration of differential dose sensitivities based on diffusion metrics along a white matter tract. (Houri et al., 2018) 3-dimensional view of corticospinal tract with “slices” overlaid on tract axis (left). FA sensitivity to dose in Gray vs. slice number for entire tract in each hemisphere (right).

gical brain mapping of extensive eloquent and non-eloquent brain networks related to human behavior and quality of life.

### 3.3. Potential future applications

Network-based approaches are able to assess brain network changes caused by tumors as well as tumor surgery, which could contribute to tumor tissue detection (Huang et al., 2018, Feldman et al., 2009) and prediction of functional outcome and overall survival (Sparacia et al., 2020, Lang et al., 2017, Daniel et al., 2021). Graph theory analysis, based on both functional (De Vico Fallani et al., 2014, Hart et al., 2016) and structural (Ahsan et al., 2020) connectivity, has been used to characterize complex network topology and identify critical brain regions. Future large-scale validation studies and clinical trials (Wu et al., 2007) are needed to truly assess the utility of these techniques in the pre- and post-operative assessments of brain tumor patients.

While neurosurgical brain mapping has largely focused on localizing sensorimotor and language functions, mapping of non-eloquent areas, such as networks involving emotion, cognition, and memory is critical for preserving and improving patients' quality of life. (Yordanova et al., 2019, Duffau, 2021, Lang et al., 2017, Catalino et al., 2020) To this end, rs-fMRI can be used to simultaneously explore multiple large-scale RSNs related to these higher order functions, such as the default mode, attention, salience, and executive functional networks. (Catalino et al., 2020)

Intra-operative rs-fMRI (Qiu et al., 2017) has been proposed for real-time eloquent area localization; with the help of real-time tb-fMRI analysis, it may evolve into a valuable strategy for neurosurgical brain mapping. (Vakamudi et al., 2020) Furthermore, multi-modality assessment of brain connectivity with navigated transcranial magnetic stimulation (Tarapore et al., 2013, Krieg et al., 2015) and magnetoencephalography (Martino et al., 2011, Tarapore et al., 2012) can help to evaluate the clinical relevance of brain connectome approaches in neurosurgical settings.

## 4. Applications in epilepsy

Epilepsy is widely accepted as a brain network disorder. Seizures are the manifestation of aberrant neuronal synchronization and ictal networks display complex and rapidly evolving propagation patterns. The functional and structural connectivity underlying these networks is fundamental to the preoperative evaluation of epilepsy. (Vakharia et al., 2018) Understanding ictal propagation patterns, seizure semiology, and potential sequelae of different surgical procedures are critical to guiding diagnostic and therapeutic interventions.

### 4.1. Clinical applications

Since standard anterior temporal lobe resection remains a common surgical treatment for drug-resistant epilepsy, use of tractography to



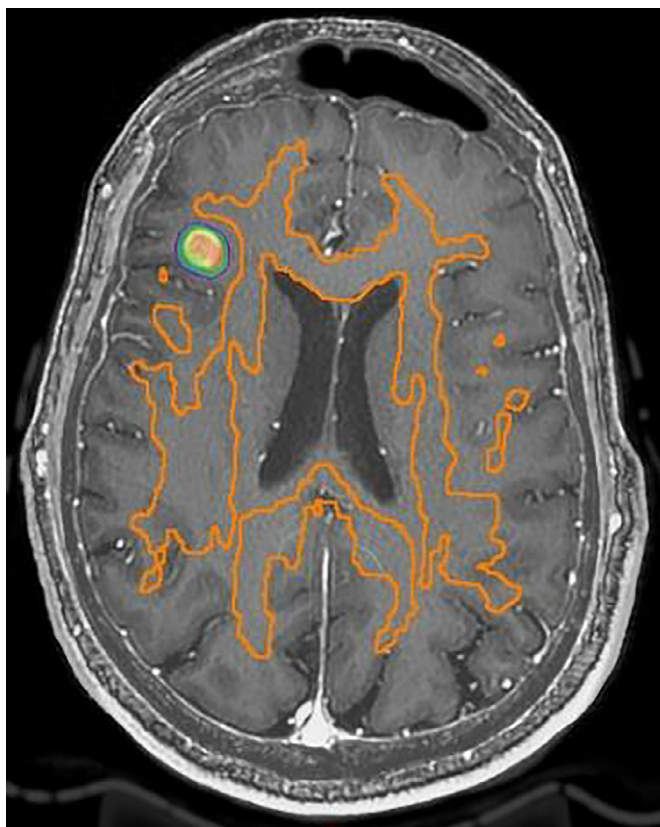

Fig. 5. Axial T1+c MRI slice with right frontal brain metastasis in a patient with metastatic breast cancer. Stereotactic radiosurgery (SRS) dose shown in colorwash; white matter tracts for avoidance shown in orange.

characterize the inter-subject variability of temporal lobe optic radiations is of particular interest. A number of studies have demonstrated a strong correlation between resection of Meyer's loop tract reconstructions and postoperative visual deficits. (James et al., 2015, Borius et al., 2014, Piper et al., 2014) Prospective implementation of tractography with intraoperative MRI has been shown to prevent a significant visual field deficit after temporal lobectomy. (Winston et al., 2014) [Fig. 6]

At the same time, the exact advantage of tractography in guiding surgical resection has yet to be determined – as prospective studies directly quantifying the benefit in outcomes using these methods are yet to be conducted. (Piper et al., 2014)

In addition to tractography, fMRI plays a significant role in surgical planning for epilepsy. tb-fMRI activation allows for localization of the eloquent cortex relative to the epileptogenic zone. (Ganesan and Ursekar, 2014) Preoperative identification of regions representing sensorimotor and language functions can help guide selection of a specific intervention and be used to tailor surgical approaches. Gross localization of memory functions can also be used to help counsel patients about potential deficits associated with certain interventions. (Rabin et al., 2004, Baxendale et al., 2006, Sidhu et al., 2015) Although the accuracy and reliability of language localization is debated, lateralization of language to a dominant hemisphere can reliably be achieved with fMRI. (Fernandez et al., 2003, Szaflarski et al., 2017) Given the high congruency between fMRI and invasive intracarotid sodium amobarbital testing, fMRI serves as a valuable non-invasive means of identifying the dominant hemisphere for language in preoperative evaluations. (Ishikawa et al., 2017, Tracy et al., 2009) Overall, current clinical practices commonly utilize fMRI to help refine clinical decisions that are based on a synthesis of multimodal information acquired during the preoperative evaluation.

## 4.2. Current research

### 4.2.1. Whole brain structural connectivity changes in epilepsy

Network analyses of whole-brain structural connectivity can be applied at local and global scales through the application of graph theory metrics, (He and Evans, 2010, Rubinov and Sporns, 2010) which have been used to explore the structural connectivity relationships and potential perturbations within disease states. (Gleichgerrcht et al., 2017) Comparison of whole-brain connectivity in patients with temporal lobe epilepsy (TLE) compared to control subjects revealed a marked reduction in connectivity which lateralizes to the side of hippocampal sclerosis. (Besson et al., 2014) While TLE was associated with diffuse global and interhemispheric connectivity reductions, those with left TLE demonstrated connectivity changes that were particularly pronounced in the perisylvian language circuitry – indicating the wide-ranging effects of a focal pathology on the whole brain network connectivity. Machine learning classifiers have also been employed based solely on preoperative connectome data and can correctly distinguish patients with TLE from normal controls with 80% accuracy, which is comparable to expert-based clinical predictions. (Gleichgerrcht et al., 2018) Additionally, histopathological findings such as hippocampal sclerosis with both atrophy and gliosis result in greater remodeling of the structural connectome compared to those with isolated gliosis. (Bernhardt et al., 2019)

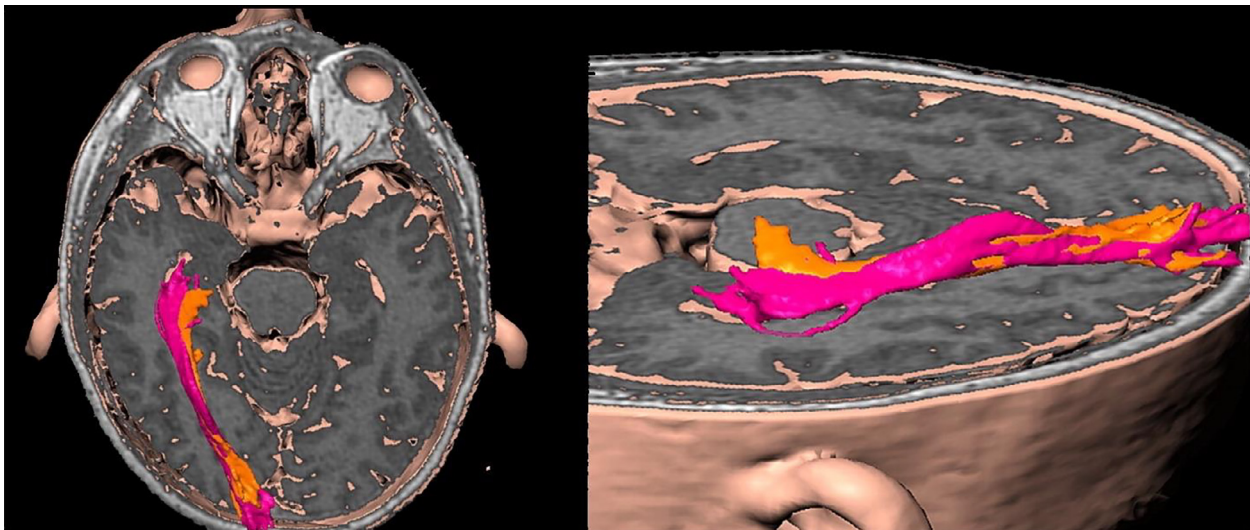
### 4.2.2. The role of structural connectivity in seizure propagation

Electroencephalography (EEG) data is fundamental to the lateralization and localization of pathological activity in epilepsy. Recent evidence has suggested that in addition to slower cortical spreading between contiguous regions, rapid seizure propagation patterns to non-contiguous brain regions reliably follows structural connections. The connections with the greatest contribution to focal epilepsy propagation manifest through direct short-range association fiber bundles. (Parker et al., 2018, Shah et al., 2019) Further evidence from cortico-cortical evoked potentials (CCEPs) employing single-pulse electrical stimulation confirms a high degree of concordance between the CCEP latency and the streamline density. (Matsumoto et al., 2007, Swann et al., 2012) Directly connected regions have been recorded in both adjacent gyri, through U-fiber propagation, and also at remote locations through association fiber bundles. Moreover, propagation of stimulated electrical activity from within the seizure onset zone has been shown to elicit CCEPs with greater amplitudes. (Parker et al., 2018) Whilst the precise mechanism underlying this phenomenon remains unclear, it does suggest that the seizure onset zone is hyperexcitable and may reflect a down-regulation of inhibitory circuits or innate property of cortical dysplastic tissue. (Turkdogan et al., 2005)

In a study of patients undergoing structural connectivity analysis before and after temporal lobe surgery, the number of nodes with abnormal connectivity was identified by comparing the epileptogenic connectomes to those derived from healthy controls. (Sinha et al., 2021) The number of residual abnormal nodes within the connectome following surgery showed an inverse correlation with sustained seizure remission and was able to predict seizure outcome at 12 months following surgery with 100% specificity and an area under the curve of 0.91.

### 4.2.3. Functional connectivity may define epilepsy networks

rs-fMRI may serve as a useful tool for the identification of pathological epilepsy networks. Given the nature of the BOLD signal, it is logical that it can reflect local field potentials generated by the summation of synaptic activity from a group of neurons. (Ekstrom, 2010) Studies leveraging the capabilities of concurrent EEG and fMRI acquisitions have demonstrated that increases in BOLD occur approximately 6 to 7 seconds after interictal epileptiform discharges (IEDs). (Benar et al., 2002) This relationship, however, is not consistent, as it can differ according to brain region and be influenced by fMRI methodology. (Ekstrom, 2010) Abnormalities in neurovascular coupling in patients with epilepsy may further affect this relationship. (Bettus et al., 2011) As such, functional



**Fig. 6.** Example of preoperative (pink) and intraoperative (orange) representations of Meyer's loop fibers of the optic radiations, which can be used to plan surgical resection. Adapted from Chen et al. (Chen et al., 2009)

connectivity within epileptic networks have been shown to both be positively (Su et al., 2019) and negatively (Bettus et al., 2011) correlated with IEDs. Furthermore, using ICA, it has been shown that epilepsy-related independent components can be identified even in the absence of IEDs. (van Houdt et al., 2015)

With regards to surgical interventions, recovery of these networks after surgery has been strongly correlated with clinical outcomes. (Neal et al., 2020, Boerwinkle et al., 2019) In one study, source localization of surface EEG was used to identify a potential irritative zone. The epilepsy network was then defined by regions with high functional connectivity to this zone. (Neal et al., 2020) Preoperatively these networks demonstrated higher functional connectivity relative to healthy controls. More importantly, after surgery seizure-free patients demonstrated greater recovery with increased network disconnection. In the absence of surface EEG, advanced analysis of rs-fMRI may still allow for the identification of the seizure onset zone. Using ICA, independent components (ICs) may be pathological if they are located within gray matter regions that cannot be attributed to a typical RSN, have an irregular time course, and have greater higher frequency activity (>0.4Hz) in their BOLD signal. (Boerwinkle et al., 2017) A presumed seizure onset zone may be defined by overlapping pathological ICs, which have been used to guide surgery to directly resect or disconnect these regions. Furthermore, postoperative recovery of the frequency power spectra in rs-fMRI BOLD signals within the epilepsy network predicted seizure freedom with an accuracy of 94%, with 96% sensitivity and 93% specificity. (Boerwinkle et al., 2019)

A combination of dMRI and rs-fMRI data has revealed a decoupling between the structural and functional networks within the default mode network (DMN) in patients with epilepsy. (Zhang et al., 2011, Wirsich et al., 2016) Greater structural-functional connectivity decoupling has also been associated with idiopathic generalized epilepsies, (Zhang et al., 2011) left TLE, and higher seizure burden. (Wirsich et al., 2016) Furthermore, restoration of the DMN has been associated with memory preservation after temporal lobe surgery. (McCormick et al., 2013)

#### 4.3. Potential future applications

Once the important connections and propagation patterns between epileptogenic brain regions have been identified, it may be possible to guide surgical interventions to disconnect or remove them whilst preventing damage to surrounding critical connections that may be impor-

tant for normal brain functions. Understanding the structural connectivity underlying seizure networks is essential for elucidating the potential propagation patterns as well as guiding and improving the safety of surgical interventions. During surgical resections in eloquent brain regions, prevention of damage to the major white matter fiber tracts is considered more critical than the overlaying grey matter as unlike the cortex, white matter tracts do not exhibit plasticity and therefore functional recovery following damage is not possible. (Jellison et al., 2004)

With this in mind, future applications are likely to focus on using connectomes to fine-tune invasive EEG implantations to quantify connectivity between abnormal nodes and to tailor resections or disconnections to reduce the burden of residual abnormal nodes following surgery. Simulated resections, in which presumed postoperative brain networks are used to predict outcomes, may allow more accurate patient counselling regarding the potential functional comorbidities related to surgery and seizure remission prediction – extending beyond motor and language networks to networks involving emotion, cognition, and memory. Such approaches also open the potential for precision medicine through minimally invasive techniques, such as laser interstitial thermal therapy, to disrupt the seizure network and prevent seizures from spreading. (Vakharia et al., 2020)

## 5. Applications in stereotactic and functional neurosurgery

### 5.1. Clinical applications

Surgical interventions in Functional Neurosurgery can be highly effective at improving symptoms and enhancing the patient's quality of life. However, clinical outcomes can vary significantly within and across studies. Much of this variability can likely be accounted for by differences in the specific location of an implanted electrode or an ablation. (Starr et al., 1999, Rolston et al., 2016, Wodarg et al., 2012, Aviles-Olmos et al., 2014)

A visible target is easier to reach than an invisible one. Stereotactic MRI can “remove the blindfold” but there are a number of caveats. (Zrinzo et al., 2013) Appropriate stereotactic MRI sequences must be used to capitalize on the ability to visualize intracranial structures directly. This approach addresses the challenge of anatomical variability. However, geometric distortion of images must be minimized and corrected. The neurosurgeon must also be aware that image-fusion can introduce stereotactic errors and that linear co-registration of images (e.g., between a non-stereotactic MRI and a stereotactic CT) cannot correct



for the non-linear distortions present on MR images. Nevertheless, with adequate care and quality control, high-fidelity stereotactic MR images offer a true geometric representation of spatial arrangement with distortion errors in the sub-voxel range. (Zrinzo, 2012) Such images can be leveraged in applications ranging from surgical procedures such as DBS and radiofrequency ablation (RF), to incisionless ablative procedures such as high frequency focused ultrasound and gamma knife radiation (GKR).

Stereotactic imaging also best documents the accuracy and precision of the surgical intervention by allowing a mathematical comparison of intended with actual target coordinates. An image-verified approach ensures that suboptimal lead placement is recognized during a DBS procedure, and this can be rectified immediately. The mathematical deviation observed between intended and actual lead placement can direct the single additional pass necessary for lead relocation. (Holl et al., 2010) Conversely, when performing ablative procedures, suboptimal lesion placement cannot be reversed. One strategy to improve safety is to perform surgery under local anesthesia, using electrical stimulation and reversible lesions to check for beneficial and adverse effects prior to making a permanent lesion. An alternative approach for RF ablation is to perform surgery under general anesthesia, but to obtain an intraoperative stereotactic MRI with a “marker” at the target (for example a plastic stylet or DBS lead) to confirm accurate targeting before an RF probe is passed down the same track to generate the permanent lesion.

#### 5.1.1. Tractography-based targeting

With the capability of reliable white matter reconstruction, DBS and ablative procedures can now be guided by white matter reconstructions of relevant tracts. At present, the main application of connectivity in functional neurosurgery is in thalamic surgery for medically refractory tremor.

The conventional, established surgical target is the ventral intermediate nucleus (Vim) in both stereotactic ablative procedures and DBS. The Vim acts as a relay nucleus centrally placed on a dentato-thalamo-cortical pathways (DTC), (Llinas et al., 2005, Llinas, 1988, Steriade and Llinas, 1988) which contains neurons predisposed to oscillatory firing behavior, making this structure instrumental in synchronizing and propagating tremor-generating oscillations seen in both essential tremor (ET) and Parkinson’s Disease (PD). (Duval et al., 2016, Raethjen and Deuschl, 2012) The cortical focus in this tremor network is in the primary motor cortex, receiving input from the dentate nucleus of the contralateral cerebellum via the Vim; and projecting back to the cerebellum via collaterals to the pontine nuclei and superior olive. (Baker et al., 2010, Helmich et al., 2012, Dum and Strick, 2003, Jorntell and Ekerot, 1999, McIntyre and Hahn, 2010, Gallay et al., 2008) A subjacent area, the caudal zona incerta (cZI), is another effective DBS target for the treatment of tremor. (Plaha et al., 2008, Blomstedt et al., 2007, Blomstedt et al., 2010, Blomstedt et al., 2009, Murata et al., 2003) The fact that the stimulation of various targets that DTC traverses (e.g., Vim, cZI, and ventralis oralis posterior) leads to tremor control, albeit with various degrees of efficacy, suggests that modulation of this tract is important for tremor treatment. (Middlebrooks et al., 2020)

Unlike other stereotactic targets, the Vim is not visible on conventional stereotactic MRI sequences used in image guided and image verified surgery (Vassal et al., 2012, Traynor et al., 2011, Deistung et al., 2013, Lemaire et al., 2010) and has therefore been traditionally targeted using atlas-based coordinates along with other identifiable structures (Schaltenbrand et al., 1977). Unfortunately, this method does not completely account for individual anatomical variability. (Akram et al., 2018) Because of this, surgery has been often performed with the patient awake to allow for intraoperative confirmation of targeting, thus increasing patient discomfort. (Gross et al., 2006) Moreover, intraoperative confirmation is not always readily feasible, such as when performing a thalamotomy using GKR. (Witjas et al., 2015)

Tractography has therefore been used in an attempt to more accurately locate the Vim *in vivo* by several groups. (Akram et al., 2018,

Coenen et al., 2011, Middlebrooks et al., 2018, Morrison et al., 2021, Pouratian et al., 2011, Sammartino et al., 2016, Tian et al., 2018) As with other stereotactic targets, tractography research involving the Vim began with retrospective analyses of tracts associated with good clinical response after DBS. Such studies demonstrated that tractography can be used to identify clinically relevant targets in the treatment of refractory tremor – namely the DTC, which is represented by structural connectivity between primary motor cortex, the thalamus, and the dentate cerebellar nucleus. Connectivity-based segmentation of the Vim can be performed in individual patients in, a clinically feasible timescale, using high angular resolution dMRI and high-performance computing with parallel GPU processing. (Akram et al., 2018) [Fig. 7]

Subsequent series by multiple groups have now shown the true clinical applicability of tractography-based targeting of Vim, as prospective use of tractography for stereotactic planning has yielded favorable clinical outcomes. (Coenen et al., 2011, Morrison et al., 2021, Tian et al., 2018, Matias et al., 2019 bib229) [Fig. 8]

As of this writing, while some have derived similar connectivity maps for other structures, (da Silva et al., 2017) incorporation of structural or functional connectivity has yet to gain acceptance for the prospective targeting of other structures.

## 5.2. Current research

### 5.2.1. Parkinson’s disease

In a study of PD patients, improvements in individual motor symptoms following subthalamic nucleus (STN) DBS were correlated with structural connectivity between the STN and the cortex. Connections between the stimulation site and supplementary motor area (SMA) were associated with improvement in bradykinesia and rigidity, while structural connections to the primary motor cortex (M1) were associated with improvement in tremor. (Akram et al., 2017) In a similar study, main effects of motor improvement were accounted for by structural connectivity between the stimulation site and the SMA and (negative) functional connectivity between the DBS site and M1. (Horn et al., 2017) [Fig. 9]

This model was trained on a first cohort of 51 patients from a first center and then used to predict outcomes in 44 patients from a second DBS center. While this study applied normative connectome data, the structural connectivity data of the model was subsequently validated using patient-specific connectivity data in an additional cohort of 33 patients from three additional DBS centers. (Wang et al., 2021) A similar approach has been used to investigate side-effects following STN-DBS, namely the occurrence of mood changes after surgery in PD. (Irmen et al., 2020, Mosley et al., 2019, Mosley et al., 2020, Mosley et al., 2018)

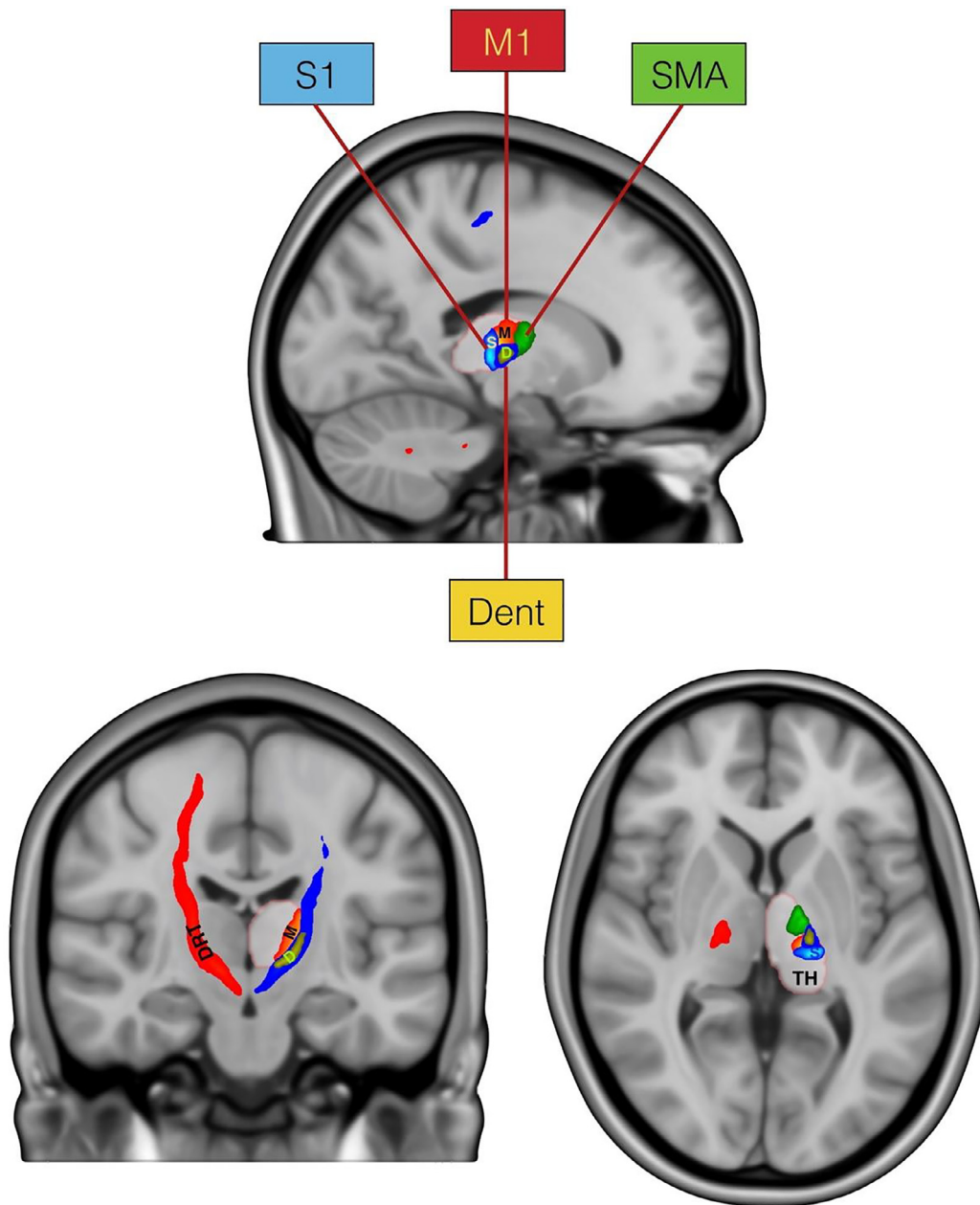
Analysis of connectivity has also demonstrated its potential in predicting response to DBS. In a study of functional connectivity in, it was found that patients with stronger preoperative connections between the STN and ipsilateral globus pallidus had more favorable responses to STN DBS. (Younce et al., 2021) A smaller study of 15 patients has also suggested that frontal lobe connectivity and characteristic structural network topology may predict response to DBS. (Koirala et al., 2018)

Further work in this field will be discussed in a later section within the context of specialized mapping techniques.

### 5.2.2. Essential tremor

Similar to PD studies, connectivity between DBS electrodes and M1 was associated with improved tremor following Vim-DBS in patients with ET. (Akram et al., 2018, Al-Fatly et al., 2019) Furthermore, proximity of the DBS site to the tractography defined cerebellar output into the ventral thalamus (DTC) explained clinical improvements better than proximity to the atlas defined DBS target in the Vim. (Calabrese et al., 2015)

Moreover; functional networks have been associated with the occurrence of ataxia and dysarthria in patients undergoing Vim-DBS for ET. (Al-Fatly et al., 2019) Here, occurrence of ataxia was associated with



**Fig. 7.** Connectivity derived thalamic template. Based on regions of interest consisting of the supplementary motor area (SMA), primary motor cortex (M1), primary sensory cortex (S1), and the dentate nucleus of the cerebellum (Dent), probabilistic tractography can be used to define connected regions of the thalamus. The dentatorubrothalamic tract (DRT) can then be identified by tracking fibers that connect the thalamus with the ipsilateral M1 and contralateral Dent. Adapted from Akram et al. (Akram et al., 2018)


functional connectivity to a specific site in the vermis that had been previously associated with ataxia. (Reich et al., 2016) Finally, the same study showed that electrodes implanted in locations specifically connected to hand vs. head regions within M1 and the cerebellum were predominantly effective in reducing hand vs. head tremor, respectively.

### 5.2.3. Psychiatric indications

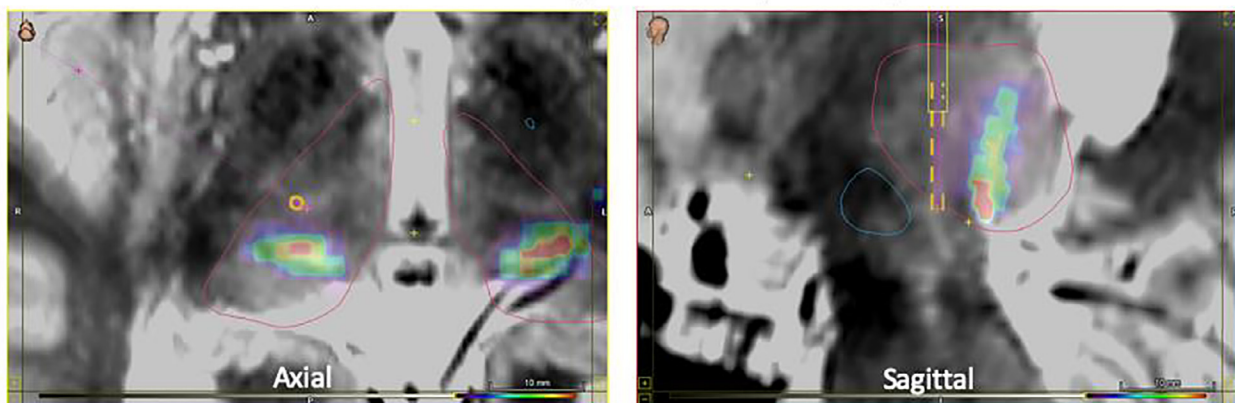
The majority of psychiatric neurosurgical applications of imaging connectomic techniques have focused on treatment-resistant depression (TRD) and obsessive-compulsive disorder (OCD). In the case of TRD in particular, this approach has been very promising in neurosurgical target planning. As mentioned above, the last decade has witnessed a notable shift from targeting regions to targeting networks. The chief example of this transition is DBS targeting the sub-callosal

cingulate (SCC). (Holtzheimer et al., 2017, Holtzheimer et al., 2012, Mayberg et al., 2005, Riva-Posse et al., 2018, Riva-Posse et al., 2020) Initial studies targeting this region were unable to distinguish successful implant strategies (producing treatment responders) from unsuccessful strategies (producing non-responders) based on coordinates alone. (Hamani et al., 2009) Subsequent fruitful work has demonstrated that a network-minded connectomic targeting approach is more successful at predicting responders and even for prospective planning. (Riva-Posse et al., 2018, Riva-Posse et al., 2020) The SCC region is now thought of as a “hub” allowing connection to frontotemporal networks via specific white matter tracts, including forceps minor (anterior corpus callosum), cingulum bundle, uncinate fasciculus, and brainstem tracts. (Tsolaki et al., 2017) Another promising target for TRD, previously called the superolateral branch of the medial forebrain bun-

## Structural Connectivity to Primary Motor Cortex



## Structural Connectivity to Primary Sensory Cortex



**Fig. 8.** Operative targeting to the connectivity-derived Vim. The top two panels contain a probabilistic heat map of structural connectivity to the primary motor cortex; and the bottom two panels contain a heat map of structural connectivity to the primary sensory cortex. As such, a surgical plan can then be developed to target the motor thalamus while avoiding the sensory thalamus (trajectory and modeled electrode in yellow/orange) (Matias et al., 2019bib229). (For interpretation of the references to color in this figure legend, the reader is referred to the web version of this article.)

dle (Coenen et al., 2019, Coenen et al., 2020, Schlaepfer et al., 2013) but now increasingly called the ventral tegmental area projection pathway, is also a tractography-defined target. It may represent another critical tract in DBS for TRD: a “hyperdirect” limbic pathway from orbital/ventral prefrontal cortex to STN, (Li et al., 2020) analogous to the hyperdirect motor pathway discussed in DBS for movement disorders. (Gunalan et al., 2017)

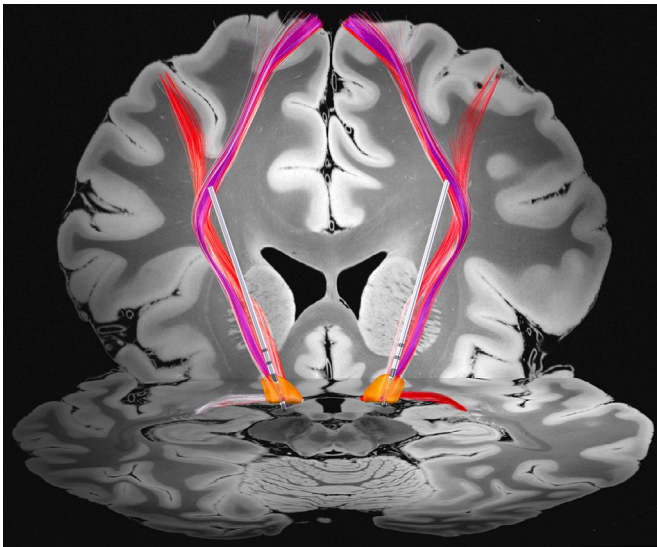
DBS for OCD has predominantly focused on targeting two regions: the ventral capsule/ventral striatum (VC/VS) (Greenberg et al., 2010, Luyten et al., 2016, Denys et al., 2010, Denys et al., 2020, Dougherty et al., 2015) and the ventromedial STN. (Mallet et al., 2008, Tyagi et al., 2019) Outcomes have been heterogeneous, with half to two-thirds of patients achieving response criteria. Recent imaging connectomic analyses have demonstrated the potential of performing individual-specific targeting in hopes of improving outcomes. In particular, multi-center data have highlighted the importance of a pathway from dorsal anterior cingulate cortex (dACC) that passes through the anterior limb of the internal capsule (ALIC) on the way to the STN region. (Li et al., 2020) This “dACC hyperdirect” pathway, again analogous to the one previously mentioned for TRD, may be a critical network component for neuromodulation in OCD. This framework is a parsimonious explanation for the observation that targeting various nodes along this pathway is effective: cingulotomy targeting dACC, (Sheth et al., 2013) VC/VS DBS targeting the pathway coursing through ALIC, (Greenberg et al., 2010, Luyten et al., 2016, Denys et al., 2010,

Denys et al., 2020, Dougherty et al., 2015) and STN-DBS targeting its terminus. (Mallet et al., 2008, Tyagi et al., 2019)

### 5.2.4. Chronic pain

Given its highly subjective and multifaceted nature, pain continues to challenge clinicians both in terms of diagnosis and treatment. Patient-reported scores remain the current standard for assessing pain despite their vulnerability to influence from comorbid conditions, psychological state, and environmental factors. As such, in an effort to objectively measure pain, investigations have focused on advanced MRI approaches. (Coppieters et al., 2016, Martucci et al., 2014) Such analyses have revealed associations between chronic pain and diffuse gray matter changes involving somatosensory and pain regions, as well as areas involved in motor function, cognitive processing, memory, and emotion. Subsequent interrogation of structural connectivity of associated tracts have yielded less robust findings. Meanwhile, functional connectivity, which is better suited to capturing acute changes, has been used to identify characteristic differences in structures within networks directly responsible for modulating afferent pain signals (e.g., rostral ventromedial medulla, periaqueductal gray, thalamus) and those involved in the affective and cognitive processing of pain (e.g., insula, cingulate, secondary association areas). Machine learning of whole-brain rs-fMRI has suggested the importance of these specific networks in characterizing the supraspinal contribution to pain sensitivity. (Spisak et al., 2020)





**Fig. 9.** Tracts activated by deep brain stimulation. By means of pathway activation modeling (Butenko et al., 2020), specific tracts from a set of predefined connections (Middlebrooks et al., 2020) were shown to be activated (red) by DBS electrodes (silver) that were localized using pre- and postoperative MRI (Horn and Kuhn, 2015). The subthalamic nucleus is shown in orange, planes from a high-resolution 7T template (Edlow et al., 2019) shown as backdrop.

Nevertheless, pain remains a heterogeneous entity, not only in its characteristics and clinical manifestations, but also in its underlying pathology and associated comorbidities – all of which likely play a role in the diversity of reported findings. Ultimately, without a clear understanding of causal relationships between pain and the associated imaging findings, translation into clinical applications remains challenging.

Meanwhile, there have been endeavors to use structural connectivity to aid DBS planning in patients with chronic pain. Three separate studies have demonstrated the importance of stimulating the trigemino-hypothalamic tract in the treatment in cluster headaches. (Akram et al., 2017, Seijo-Fernandez et al., 2018, Owen et al., 2007) This tract connects nuclei of the posterior mesencephalic tegmentum to the hypothalamus as well as to prefrontal and mesial temporal cortical regions. Interestingly, patients with cluster headache have been found to have a pathological increase in functional connectivity within this network, which involves midbrain dopaminergic systems. (Ferraro et al., 2018) In refractory neuropathic pain, direct stimulation of the ascending medial and trigeminal lemniscal pathways have demonstrated particular efficacy, (Hunsche et al., 2013, Coenen et al., 2015) with studies reporting the success of prospective targeting of these tracts within the internal capsule or as they synapse within the thalamus. (Polanski et al., 2019, Kovanlikaya et al., 2014) The anterior cingulate and the periaqueductal gray have also served as potential targets; and interestingly, may both impart their efficacy through modulation of the medial forebrain bundle. (Coenen et al., 2015, Boccard et al., 2016)

### 5.3. Specialized mapping techniques

#### 5.3.1. Lesion mapping

Lesion studies have provided the foundation for localization of most neurological and psychiatric symptoms because they provide a causal link between the lesion location and the resulting symptom. (Rorden and Karnath, 2004) However, similar symptoms can result from lesions in different locations, making localization to specific regions challenging. Further, symptoms may result from lesion-induced alterations in connected brain regions that are distant from the lesion location itself. (Carrera and Tononi, 2014)

Thanks to efforts like the Human Connectome Project, we now have a normative human connectome that can serve as an atlas for how different brain regions are anatomically and functionally connected. Using the human connectome, we can now test whether lesion locations map to a connected brain network rather than a single brain region. Called lesion network mapping, the approach has been used to map over 20 different neurological and psychiatric symptoms including parkinsonism, (Joutsa et al., 2018) dystonia, (Corp et al., 2019) tremor, (Joutsa et al., 2019) hemichorea, (Laganieri et al., 2016) freezing of gait, (Fasano et al., 2017) depression, (Padmanabhan et al., 2019) delusions, (Darby et al., 2017) hallucinations, (Kim et al., 2019) memory impairment, (Ferguson et al., 2019) and many others (for reviews see (Fox, 2018, Cohen and Fox, 2020)). Specificity is assessed through comparison to lesion locations not causing the symptom while reproducibility is assessed by comparing lesion networks across multiple independent cohorts. (Padmanabhan et al., 2019, Ferguson et al., 2019, Cotovio et al., 2020)

The most important impact of lesion network mapping is likely identifying therapeutic targets for neuromodulation including targets for essential tremor, (Joutsa et al., 2018) Holmes tremor, (Joutsa et al., 2019) Parkinson's disease, (Joutsa et al., 2018) cervical dystonia, (Corp et al., 2019) depression, (Padmanabhan et al., 2019) and mania (Cotovio et al., 2020). In all cases, brain stimulation to the circuit identified using lesion network mapping appears to be effective at treating that symptom, even in patients without brain lesions. Given this success, lesion network mapping has been adopted and utilized by many labs (Klingbeil et al., 2020, Wawrzyniak et al., 2018, Albazron et al., 2019, Hwang et al., 2020, Mansouri et al., 2020, Sutterer et al., 2016, Lee et al., 2019, Philippi et al., 2021, Elias et al., 2020, Mithani et al., 2019) and used to study an increasing variety of lesion etiologies (Cohen et al., 2021). The technique has also been expanded beyond “lesions” to map brain networks based on neuroimaging coordinates, (Salvalaggio et al., 2020, Kim et al., 2019) locations of brain atrophy, (Darby et al., 2017) transcranial magnetic stimulation sites, (Cash et al., 2020) and DBS sites (Horn and Fox, 2020).

#### 5.3.2. Effective connectivity

As demonstrated, network dynamics can be characterized using electrophysiology or functional imaging, with subsequent analyses to quantify between or within-region interactions. Functional connectivity is the most common means of achieving this, and refers broadly to any statistical dependency (e.g., correlation) between the functional time series of distant nodes. In order to have an in-depth study of how these ‘interacting nodes’ influence each other, additional statistical models are applied to explore *effective connectivity*. This approach is defined as the influence nodes exert on one another under a particular network model of causal dynamics. In contrast to functional connectivity, effective connectivity describes directed effects within a network, which allows a more specific characterization of the targeted functional anatomy, at the cost of a more limited network view requiring a priori assumptions. Analyses of effective connectivity include Granger causality modelling, (Granger, 1969) structural equation modelling, (McIntosh and Gonzalez-Lima, 1994) and dynamic causal modelling (Friston et al., 2003).

Such modelling of fMRI data from PD patients with STN-DBS has shown reductions in effective connectivity of afferents of the STN (hyperdirect and indirect pathways), as well as upregulation of the direct pathway and thalamo-cortical coupling. (Kahan et al., 2014) During motor tasks, there are additional modulatory effects on functional integration between the cortico-basal ganglia loop and cortico-cerebellar loop. (Kahan et al., 2019) When a broader network of motor regions are modelled, more widespread changes in cortico-cerebellar coupling have been noted. (Hanssen et al., 2019) Data from patients with ET and Vim-DBS have revealed changes in intrinsic cerebellar connectivity that correlated with clinical improvement. (Gibson et al., 2016) Similar work in patients with OCD and VC/VS DBS have shown changes in

the limbic cortico-basal ganglia and Papez circuits. (Gibson et al., 2017, Fridgeirsson et al., 2020) Systematic modeling of data from a variety of patient populations targeting different elements of the cortico-basal ganglia network will teach us more about how DBS alters pathological network interactions.

### 5.3.3. Neurophysiological correlates to structural and functional connectivity

A parallel and complimentary stream of research to advanced MRI techniques has focused on unravelling the temporal dynamics of neural populations in disease states; (Oswal et al., 2013) the premise being that abnormally synchronized population activity may be pathological and that specifically targeting involved areas with intelligent stimulation approaches offers the possibility to ameliorate disease symptoms. (Little et al., 2013, Tinkhauser et al., 2017) Ultimately, consideration for both the structural (space) and functional (time) characteristics of pathophysiological networks offers the greatest promise to bring about improvements for future DBS technologies. (Cagnan et al., 2019, Starr and Little, 2021)

Recordings from the STN in PD demonstrate that a major mechanism of STN-DBS is likely to be the suppression of pathologically exaggerated beta rhythms that occur in discrete quanta known as bursts. (Tinkhauser et al., 2017, Eusebio et al., 2011) Similar suppressive actions of DBS on neural activity have been reported within the globus pallidus pars interna (GPI) in dystonia. (Barow et al., 2014) Importantly however, nuclei that are targets for DBS form part of broader cognitive and motor networks whose functions maybe interrogated by performing simultaneous cortical recordings – for example using magnetoencephalography, electroencephalography, or electrocorticography – whilst recording from the DBS target nucleus. Using these approaches, it has been shown that specific cortical regions are functionally coupled across segregated frequency bands to subcortical sites in disease states. (Gratwicke et al., 2020, Hirschmann et al., 2011, Litvak et al., 2011) Moreover, DBS can exert modulatory effects not only within the target nucleus, but also on these large scale networks, highlighting that network dysfunction may play a role in disease pathogenesis. (Oswal et al., 2016, Chen et al., 2020, Miocinovic et al., 2018, Wang et al., 2018)

Important directions for future research will include refining the understanding of how short duration bursting activity propagates through cortico-subcortical circuits. Techniques for predicting and specifically targeting pathological bursting events may pave the way for the next generation of intelligent DBS technologies. In this regard, it will also be important to marry neurophysiological data with information from structural and functional imaging techniques. Although these modalities maybe distinct, recent studies have revealed interesting overlaps between structural and functional connectivity in DBS studies. (Oswal et al., 2020, Oswal et al., 2020) In PD, for example, it has been proposed that the hyperdirect pathway between cortex and the STN, which can be identified by dMRI techniques, has a detectable spectral signature at high beta frequencies. Furthermore, activity within this pathway may be responsible for promoting abnormal synchrony, thereby implicating its importance in effective therapy. (Kahan et al., 2014, Oswal et al., 2016, Oswal et al., 2020)

### 5.4. Potential future applications

The previous sections have detailed ongoing efforts to leverage connectomics in stereotactic and functional neurosurgery applications. Such efforts help to improve our understanding of the pathophysiology at hand and the network changes specific to a particular disease process. In turn, such knowledge will allow for the use of objective imaging data that will aid clinicians in diagnosis. This information has the potential to unveil different subtypes or phenotypes of a disease, which may better inform the selection of an appropriate treatment or intervention. Particularly for a field in which relies heavily on clinical diagnoses, the

prospect of objective imaging biomarkers is exciting – as it would significantly improve the consistency of clinical outcomes and facilitate discussions with patients regarding expectations for specific treatments.

From a treatment standpoint, it is likely that connectivity-based surgical targeting will continue to grow. In addition to using structural connectivity for targets other than the Vim, incorporation of functional connectivity may provide a more complete understanding of patient connectomes, which would allow surgeons to tailor surgical plans to accommodate for nuanced variations in both structure and function. Similarly, connectomics has potential applications outside of the operating room with the facilitation DBS programming. With DBS systems now capable of steering electrical stimulation towards or away from specific structures, clinicians could potentially apply programs that preferentially target elements of specific connectomes to modify clinical effects.

## 6. Limitations of connectivity analyses

“Seeing is not believing – it is only seeing.” (MacDonald, 1986)

–George MacDonald

Structural and functional connectivity studies are heavily reliant on statistical models, and the quality of raw data. The base MRI sequence acquisition (mainly gradient echo/echo planar imaging) has inherent limitations due to increased sensitivity to magnetic field inhomogeneity, susceptibility effects (off resonance field), and motion artifacts. It requires high-performance gradients to achieve desired *b*-values. The analysis strategy further impacts the results; it is vital that these models are validated against a ground truth model (e.g., with anatomical studies or against clinical outcomes) prior to clinical use.

Translation of brain connectome approaches to clinical practice is limited by the availability of expertise needed for data analysis and result interpretation for complicated approaches, as well as by a lack of standardization across institutions. Such discrepancies arise in registration methods, in which multiple registration steps using multimodal data can result in accumulated spatial error, as well as with variations in region-of-interest definition and selection. (Akram et al., 2019) Efforts have been devoted to the development of data analysis software packages (Zaca et al., 2018, Norton et al., 2017, Bottger et al., 2011, Huang et al., 2016) and algorithms for automatic identification of RSNs (Lu et al., 2017, Zaca et al., 2018, Huang et al., 2016) and white matter tracts (O'Donnell et al., 2017, Tunc et al., 2016, Mancini et al., 2019). Development of streamlined and standardized clinical tools will ultimately help advance the acceptance and deployment of brain connectome approaches in clinical practice.

Beyond standardization of acquisition and post-processing protocols exist inherent limitations associated with test-retest reliability, which is a greater concern for functional than structural connectivity. (Lin et al., 2015) Further heterogeneity of data arises when data is collected at different imaging centers – as scanner type, coil type, system calibration, acquisition parameters, software version, and patient positioning can all introduce variability into dMRI and fMRI. (Mirzaalian et al., 2016, Tax et al., 2019, Yamashita et al., 2019) Such differences may be responsible for upwards of 10% of variance between acquisitions. (Nielson et al., 2018) While investigations into correction methods that harmonize data collected at different centers are currently underway, challenges remain. (Tax et al., 2019, Yamashita et al., 2019) Although significant, the direct effect of scanning at different centers may be of a notably smaller magnitude than the variability seen in repeated scans of individual subjects. (Noble et al., 2017) It is the subtlety of these effects that makes it difficult to identify and address. Differences in patient populations at different institutions can further confound accurate quantification of scanner-related factors. (Yamashita et al., 2019, Nielson et al., 2018) Lastly, even when identified, correction of software-related issues is limited by the inability to investigate the specifics of a manufacturer's proprietary software. (Nielson et al., 2018) Ultimately, maximizing standardization of acquisition parameters and protocols while continuing to

report site-specific differences will help us better understand and interpret the data acquired in multicenter studies.

### 6.1. Structural connectivity

dMRI data suffer from low SNR (especially in areas of entanglement or increased pulsatility) and are susceptible to geometrical distortion and susceptibility artifacts. (Mueller et al., 2015) Several image acquisition and processing strategies have been developed to reduce the effects of these artifacts.

Although commercial platforms currently allow clinicians to reconstruct white matter pathways, it is imperative for clinicians to understand the limitations of their current methods. (Duffau, 2014, Duffau, 2014) Notably, different software packages with different reconstruction algorithms, each with potential for different parameter selection, directly affect tract estimations. (Ashmore et al., 2020, Feigl et al., 2014, Pujol et al., 2015) It is therefore particularly concerning that although tractography is frequently used for clinical purposes, many clinicians do not fully understand the methods or parameters used to derive such reconstructions. (Toescu et al., 2020)

The reliability of tract reconstructions has been based on an estimation of the known anatomical course – as there is no in-vivo gold-standard for comparison. Voxel-wise modelling of diffusion that uses the diffusion tensor imaging (DTI) model is computationally inexpensive but it fails to resolve crossing, kissing and fanning fiber configurations. (Shi and Toga, 2017) DTI also fails at higher b-values. While, higher order models handle this better, they are computationally expensive and require longer, more sophisticated image acquisitions. Deterministic (streamline) tractography does not consider the uncertainty within each voxel, partial volume effects and MR noise. (Lazar and Alexander, 2003) It is very useful in mapping out large, non-crossing white matter bundles but it fails when fractional anisotropy drops. It can also propagate error leading to issues with reproducibility. Probabilistic tractography generates a probability distribution function in each voxel and then runs multiple iterations of streamlines (in the thousands) to formulate probabilistic tracts; they can, however, produce false positive tracts (Zalesky et al., 2016) and are computationally more expensive.

Tractography cannot discern afferent from efferent fibers, showing only direct connections between brain areas, and is unable to resolve synapses. (Jbabdi and Johansen-Berg, 2011) As no standardized recommendations exist, arbitrary thresholding is inherent to tractography and may eliminate true tracts or allow the creation of false positives. (Nimsky et al., 2016) In future, machine learning approaches may avoid this step; (Zalesky et al., 2016) regardless, the most fundamental problem with tractography is lack of ground truth to compare and validate the tracts generated. (Nimsky et al., 2016)

Whilst efforts to standardize tractography through the implementation of automatically derived regions-of-interest have been shown to be comparable to expert human reconstructions, (Mancini et al., 2019, Keller et al., 2017) caution is still required when utilizing such tract reconstructions intra-operatively or for preoperative planning as they do not provide information regarding the function of the reconstructed tracts (Duffau, 2014, Duffau, 2014) or the implication of removing brain regions and connections from the wider network. As such, clinicians should be aware of these pitfalls and must continue to interpret tract estimations with caution in clinical practice.

### 6.2. Functional connectivity

While fMRI occupies an important role in connectivity studies, it is crucial to recognize its limitations. Both BOLD and ASL fMRI have low temporal resolution. Factors such as head motion, (Van Dijk et al., 2012, Power et al., 2012) the cardiac and respiratory cycles (Birn et al., 2008) and neural events themselves may induce motion and physiological artifacts leading to inaccuracies. (Buckner et al., 2013) Errors

may result from variability in both experimental design and in the acquisition protocols, image registration protocols, structural changes in the brain, non-standardized statistical analysis methods and resultant false positives and negatives, and errors in the interpretation of results. (Soares et al., 2016)

The handling of global signal (GS), the time series of signal intensity averaged across all brain voxels, remains a controversial topic. Various methods have been developed for correction of GS changes, the most frequently used being global signal regression (GSR). The opposing views on whether to use GSR in processing rs-fMRI result from the fact that GS encompasses the influence of non-neuronal confounds (and therefore GSR eliminates motion, cardiac and respiratory confounds), but also includes fluctuations in neuronal activity, as demonstrated by the fact that GS amplitude is influenced by changes in vigilance and significantly reduced by consumption of caffeine. (Wong et al., 2013) Such fluctuations are also likely dependent on the dataset and brain region being analyzed. (Fox et al., 2009) Therefore, GSR may introduce artefactual anti-correlations in the analysis. Additional reason for controversy arises as some studies suggest use of GSR reduces test-retest reliability in older subjects (Guo et al., 2012) while others demonstrate increase of consistency of within-subject functional connections (Song et al., 2012). Furthermore, test-retest reliability of graph theory-derived metrics has been shown to increase, decrease, or remain unchanged with the use of GSR. (Andellini et al., 2015, Braun et al., 2012, Liang et al., 2012) Alternatives to GSR in global signal correction exist, each with their own limitations. (He and Liu, 2012, Carbonell et al., 2011, Marx et al., 2013, Saad et al., 2013, Liu et al., 2017) Ultimately, it is challenging to infer which results may be artefactual as a gold standard does not exist.

These limitations can present a real obstacle to clinical translation. The development of quality control strategies, standardization of data acquisition protocols and data analysis pipelines and high-performance computing with GPU processing will likely help bring these methods closer to clinical practice.

## 7. Future directions

### 7.1. Machine learning

Both dMRI and fMRI have allowed the non-invasive in-vivo exploration of the brain connectome. However, conventional data analysis often relies heavily on a priori hypothesis definition and rigid processing rules. Developments in machine learning show theoretical potential to solve some challenges in tractography. (Poulin et al., 2019) For example, by learning the mapping between dMRI signals and local fiber orientations, they provide an opportunity for local fiber orientation model-free approaches, as the choice of model in tractography may itself be a source of error. (Cote et al., 2013) Machine learning could improve accuracy of streamline reconstruction as traditional tractography algorithms tend to miss the full spatial extent of white matter bundles, resulting in both false positives and false negatives. Machine learning could make arbitrary thresholding obsolete as a technique to control for false positive tracts, which is a known tractography source of error. (Zalesky et al., 2016) Both supervised and unsupervised algorithms have been employed to drive streamline progression, treating the problem as a regression (Poulin et al., 2017) or classification task (Neher et al., 2015), and in bundle-specific (Wasserthal et al., 2018) or global (Poulin et al., 2017) reconstruction approaches. Recurrent, (Poulin et al., 2017, Benou et al., 2019) convolutional, (S et al., 2017) and multi-layer perceptron (Wegmayr et al., 2018) architectures have been attempted in tackling the challenges of fiber tracking.

Other potential contributions of machine learning to functional neurosurgery include early diagnosis (Huo et al., 2020) and prediction of clinical outcomes of neurological disease (Gellerup, 2016, Galvis et al., 2016) and unsupervised subnetwork extraction, potentially shedding light on the mechanisms of such pathology. Finally, machine learning can have a role in patient selection for surgery, aiding the prediction of



patients likely to suffer complications through logistic regression analysis of risk factors, (Farrokhi et al., 2020) or cognitive decline through random forest modelling of EEG data. (Koch et al., 2019) Surgical targeting could be aided by machine learning anatomical border demarcation. To this effect, a group has developed a support vector machine to perform real-time automatic detection of the ventral STN border in DBS surgery. (Valsky et al., 2017) K-nearest neighbor classifiers could be used to optimize DBS programming, (Gómez-Orozco et al., 2019) a labor-intensive process which currently entails clinicians exploring and testing vast numbers of parameter combinations.

## 7.2. Ultra-high field MRI

Ultra-high field 7T MRI provides enhanced SNR and high-resolution images with an improved contrast of brain structures that are otherwise unobservable *in vivo*. (Forstmann et al., 2014, Abosch et al., 2010) Combining several cutting-edge, multi-modal, 7T MRI techniques including T1-weighted, T2-weighted, susceptibility weighted imaging, and multi-directional dMRI, a true comprehensive patient-specific 3D anatomical model of the target region and the associated connectivity networks can be created. (Lenglet et al., 2012, Plantinga et al., 2018, Duchin et al., 2018) Studies using 7T data have demonstrated marked inter-subject variability in the size, shape, and orientation of the main targets in the surgical treatment of PD: the STN and the GPi. (Plantinga et al., 2018, Duchin et al., 2018, Keuken et al., 2014, Patriat et al., 2018) Despite concerns for increased geometric distortion at higher field strengths, proper attention to distortion correction allows for reliable anatomical and structural imaging. (Patriat et al., 2018)

Acquisition of fMRI at 7T has been shown to provide increased SNR of BOLD signal, but are more vulnerable to susceptibility-related field inhomogeneities and physiologic noise. (Sladky et al., 2013) As such, ongoing investigations continue to explore ways in which parameters, including spatial and temporal resolution, can be adjusted to optimizing ultra high-field fMRI. (Yoo et al., 2018)

Pushing forward this technology, it is now feasible to perform a patient-specific dissection of the target structure into its subdivisions (e.g., parcellation to its functional domains). (Behrens et al., 2003) These new imaging capabilities allow for a direct targeting surgical approach with accurate delivery of the device or implant into the intended sub-region of the anatomical structure. Furthermore, for DBS, by combining the postoperative CT images with MRI, the final electrode location with its individual contacts and orientations, can be accurately determined. (Shamir et al., 2019, Aman et al., 2020) Lead location, in respect to the anatomical borders of the intended target structure and its functional domains, is a crucial information for an efficient programming of the patient for optimal benefits. (Schrock et al., 2021)

Another advantage that the 7T data provides is the ability to train deep-learning based algorithms for precise segmentations of basal ganglia structures. Robust, accurate, and automated techniques are needed for reliability and reduction of human bias as well as increased segmentation throughput. (Kim et al., 2019, Solomon et al., 2021)

## 8. Conclusions

Structural and functional connectivity have provided significant insight into the brain function and the pathophysiology of numerous neurological diseases. In clinical practice, these tools can help elucidate the location of important brain regions that otherwise would not be visible on anatomical MRI alone. As such, the surgical or treatment planning currently remains the primary use of structural and functional imaging. In addition to the expansion of planning capabilities, potential clinical applications include the use of connectomics in facilitating diagnosis and improving prognostic accuracy. Advances in automation and standardization of processing methods, including machine learning approaches, can increase the reproducibility and reliability of these tools – which is necessary for broadening clinical use.

## Credit authorship contribution statement

**Chengyuan Wu:** Conceptualization, Writing – original draft, Writing – review & editing, Supervision. **Francisca Ferreira:** Writing – original draft, Writing – review & editing. **Michael Fox:** Writing – original draft, Writing – review & editing. **Noam Harel:** Writing – original draft, Writing – review & editing. **Jona Hattangadi-Gluth:** Writing – original draft, Writing – review & editing. **Andreas Horn:** Writing – original draft, Writing – review & editing. **Saad Jbardi:** Writing – original draft, Writing – review & editing. **Joshua Kahan:** Writing – original draft, Writing – review & editing. **Ashwini Oswal:** Writing – original draft, Writing – review & editing. **Sameer A. Sheth:** Writing – original draft, Writing – review & editing. **Yanmei Tie:** Writing – original draft, Writing – review & editing. **Vejay Vakharia:** Writing – original draft, Writing – review & editing. **Ludvic Zrinzo:** Writing – original draft, Writing – review & editing. **Harith Akram:** Conceptualization, Writing – original draft, Writing – review & editing, Supervision.

## Acknowledgements

The authors would like to thank Parikshit Juvekar and Fan Zhang for their help in creating Fig. 3.

MDF was supported by research grants from the Nancy Lurie Marks Foundation and the NIH (R01 MH113929, MH115949, AG060987). JHG was supported by the National Institutes of Health (1KL2TR001444, R01 CA238783-01). AH was supported by the German Research Foundation (Deutsche Forschungsgemeinschaft, Emmy Noether Stipend 410169619 and 424778381 – TRR 295) as well as Deutsches Zentrum für Luft- und Raumfahrt (DynaSti grant within the EU Joint Programme Neurodegenerative Disease Research, JPND). YT was supported by the National Institutes of Health (NIH) grants R21NS075728 and R21CA198740. SS was supported by the McNair Foundation.

## Funding

This research did not receive any specific grant from funding agencies in the public, commercial, or not-for-profit sectors.

## Data and Code Availability Statement

Since this manuscript is a review of the existing literature, there is not original data to be shared or disseminated.

## References

- Abosch, A., Yacoub, E., Ugurbil, K., Harel, N., 2010. An assessment of current brain targets for deep brain stimulation surgery with susceptibility-weighted imaging at 7 tesla. *Neurosurgery* 67, 1745–1756 discussion 1756.
- Ahsan, S.A., Chendeb, K., Briggs, R.G., Fletcher, L.R., Jones, R.G., Chakraborty, A.R., Nix, C.E., Jacobs, C.C., Lack, A.M., Griffin, D.T., Teo, C., Sughrue, M.E., 2020. Beyond eloquence and onto centrality: a new paradigm in planning supratentorial neurosurgery. *J Neurooncol* 146, 229–238.
- Akram, H., Dayal, V., Mahlknecht, P., Georgiev, D., Hyam, J., Foltynie, T., Limousin, P., De Vita, E., Jahanshahi, M., Ashburner, J., Behrens, T., Hariz, M., Zrinzo, L., 2018. Connectivity derived thalamic segmentation in deep brain stimulation for tremor. *Neuroimage Clin* 18, 130–142.
- Akram, H., Hariz, M., Zrinzo, L., 2019. Connectivity derived thalamic segmentation: Separating myth from reality. *Neuroimage Clin* 22, 101758.
- Akram, H., Miller, S., Lagrata, S., Hariz, M., Ashburner, J., Behrens, T., Matharu, M., Zrinzo, L., 2017. Optimal deep brain stimulation site and target connectivity for chronic cluster headache. *Neurology* 89, 2083–2091.
- Al-Fatly, B., Ewert, S., Kubler, D., Kroneberg, D., Horn, A., Kuhn, A.A., 2019. Connectivity profile of thalamic deep brain stimulation to effectively treat essential tremor. *Brain* 142, 3086–3098.
- Albazon, F.M., Bruss, J., Jones, R.M., Yock, T.I., Pulsifer, M.B., Cohen, A.L., Nopoulos, P.C., Abrams, A.N., Sato, M., Boes, A.D., 2019. Pediatric postoperative cerebellar cognitive affective syndrome follows outflow pathway lesions. *Neurology* 93, e1561–e1571.
- Aman, J.E., Johnson, L.A., Sanabria, D.E., Wang, J., Patriat, R., Hill, M., Marshall, E., MacKinnon, C.D., Cooper, S.E., Schrock, L.E., Park, M.C., Harel, N., Vitek, J.L., 2020. Directional deep brain stimulation leads reveal spatially distinct oscillatory activity in the globus pallidus internus of Parkinson's disease patients. *Neurobiol Dis* 139, 104819.

- Andellini, M., Cannata, V., Gazzellini, S., Bernardi, B., Napolitano, A., 2015. Test-retest reliability of graph metrics of resting state MRI functional brain networks: A review. *J Neurosci Methods* 253, 183–192.
- Andersson, J.L.R., Skare, S., Ashburner, J., 2003. How to correct susceptibility distortions in spin-echo echo-planar images: application to diffusion tensor imaging. *Neuroimage* 20, 870–888.
- Andersson, J.L.R., Graham, M.S., Drobnyak, I., Zhang, H., Campbell, J., 2018. Susceptibility-induced distortion that varies due to motion: Correction in diffusion MR without acquiring additional data. *Neuroimage* 171, 277–295.
- Andersson, J.L.R., Graham, M.S., Drobnyak, I., Zhang, H., Filippini, N., Bastiani, M., 2017. Towards a comprehensive framework for movement and distortion correction of diffusion MR images: Within volume movement. *Neuroimage* 152, 450–466.
- Andersson, J.L.R., Graham, M.S., Zsoldos, E., Sotiropoulos, S.N., 2016. Incorporating outlier detection and replacement into a non-parametric framework for movement and distortion correction of diffusion MR images. *Neuroimage* 141, 556–572.
- Ashmore, J., Pemberton, H.G., Crum, W.D., Jarosz, J., Barker, G.J., 2020. Implementation of clinical tractography for pre-surgical planning of space occupying lesions: An investigation of common acquisition and post-processing methods compared to dissection studies. *PLoS One* 15, e0231440.
- Aviles-Olmos, I., Kefalopoulou, Z., Tripoliti, E., Candelario, J., Akram, H., Martinez-Torres, I., Jahanshahi, M., Foltynie, T., Hariz, M., Zrinzo, L., Limousin, P., 2014. Long-term outcome of subthalamic nucleus deep brain stimulation for Parkinson's disease using an MRI-guided and MRI-verified approach. *J Neurol Neurosurg Psychiatry* 85, 1419–1425.
- Baker, K.B., Schuster, D., Cooperrider, J., Machado, A.G., 2010. Deep brain stimulation of the lateral cerebellar nucleus produces frequency-specific alterations in motor evoked potentials in the rat in vivo. *Exp Neurol* 226, 259–264.
- Barow, E., Neumann, W.J., Brucke, C., Huebl, J., Horn, A., Brown, P., Krauss, J.K., Schneider, G.H., Kuhn, A.A., 2014. Deep brain stimulation suppresses pallidal low frequency activity in patients with phasic dystonic movements. *Brain* 137, 3012–3024.
- Baxendale, S., Thompson, P., Harkness, W., Duncan, J., 2006. Predicting memory decline following epilepsy surgery: a multivariate approach. *Epilepsia* 47, 1887–1894.
- Behrens, T.E., Berg, H.J., Jbabdi, S., Rushworth, M.F., Woolrich, M.W., 2007. Probabilistic diffusion tractography with multiple fibre orientations: What can we gain? *Neuroimage* 34, 144–155.
- Behrens, T.E., Johansen-Berg, H., Woolrich, M.W., Smith, S.M., Wheeler-Kingshott, C.A., Boulby, P.A., Barker, G.J., Sillery, E.L., Sheehan, K., Ciccarelli, O., Thompson, A.J., Brady, J.M., Matthews, P.M., 2003. Non-invasive mapping of connections between human thalamus and cortex using diffusion imaging. *Nat Neurosci* 6, 750–757.
- Benar, C.G., Gross, D.W., Wang, Y., Petre, V., Pike, B., Dubeau, F., Gotman, J., 2002. The BOLD response to interictal epileptiform discharges. *Neuroimage* 17, 1182–1192.
- Benou, I., Riklin Raviv, T., 2019. DeepTract: A Probabilistic Deep Learning Framework for White Matter Fiber Tractography. *Lecture Notes in Computer Science*. Springer International Publishing, pp. 626–635.
- Bernhardt, B.C., Fadaie, F., Liu, M., Caldarou, B., Gu, S., Jefferies, E., Smallwood, J., Bassett, D.S., Bernasconi, A., Bernasconi, N., 2019. Temporal lobe epilepsy. *Neurology* 92, e2209–e2220.
- Besson, P., Dinkelacker, V., Valabregue, R., Thivard, L., Leclerc, X., Baulac, M., Sammler, D., Colliot, O., Lehericy, S., Samson, S., Dupont, S., 2014. Structural connectivity differences in left and right temporal lobe epilepsy. *Neuroimage* 100, 135–144.
- Bettus, G., Ranjeva, J.P., Wendling, F., Benar, C.G., Confort-Gouny, S., Regis, J., Chauvel, P., Cozzone, P.J., Lemieux, L., Bartolomei, F., Guye, M., 2011. Interictal functional connectivity of human epileptic networks assessed by intracerebral EEG and BOLD signal fluctuations. *PLoS One* 6, e20071.
- Birn, R.M., Molloy, E.K., Patriat, R., Parker, T., Meier, T.B., Kirk, G.R., Nair, V.A., Meyerand, M.E., Prabhakaran, V., 2013. The effect of scan length on the reliability of resting-state fMRI connectivity estimates. *Neuroimage* 83, 550–558.
- Birn, R.M., Smith, M.A., Jones, T.B., Bandettini, P.A., 2008. The respiration response function: the temporal dynamics of fMRI signal fluctuations related to changes in respiration. *Neuroimage* 40, 644–654.
- Biswal, B., Yetkin, F.Z., Haughton, V.M., Hyde, J.S., 1995. Functional connectivity in the motor cortex of resting human brain using echo-planar MRI. *Magn Reson Med* 34, 537–541.
- Blomstedt, P., Hariz, G.M., Hariz, M.I., Koskinen, L.O., 2007. Thalamic deep brain stimulation in the treatment of essential tremor: a long-term follow-up. *Br J Neurosurg* 21, 504–509.
- Blomstedt, P., Sandvik, U., Fyttagoridis, A., Tisch, S., 2009. The posterior subthalamic area in the treatment of movement disorders: past, present, and future. *Neurosurgery* 64, 1029–1038 discussion 1038–1042.
- Blomstedt, P., Sandvik, U., Tisch, S., 2010. Deep brain stimulation in the posterior subthalamic area in the treatment of essential tremor. *Mov Disord* 25, 1350–1356.
- Boccard, S.G., Fernandes, H.M., Jbabdi, S., Van Hartevelt, T.J., Kringelbach, M.L., Quaghebeur, G., Moir, L., Mancebo, V.P., Pereira, E.A., Fitzgerald, J.J., Green, A.L., Stein, J., Aziz, T.Z., 2016. Tractography Study of Deep Brain Stimulation of the Anterior Cingulate Cortex in Chronic Pain: Key to Improve the Targeting. *World Neurosurg* 86, 361–370 e361–363.
- Boerwinkle, V.L., Cedi, E.G., Mirea, L., Williams, K., Kerrigan, J.F., Lam, S., Raskin, J.S., Desai, V.R., Wilfong, A.A., Adelson, P.D., Curry, D.J., 2019. Network-targeted approach and postoperative resting-state functional magnetic resonance imaging are associated with seizure outcome. *Annals of Neurology* 86, 344–356.
- Boerwinkle, V.L., Mohanty, D., Folders, S.T., Guffey, D., Minard, C.G., Vedantam, A., Raskin, J.S., Lam, S., Bond, M., Mirea, L., Adelson, P.D., Wilfong, A.A., Curry, D.J., 2017. Correlating Resting-State Functional Magnetic Resonance Imaging Connectivity by Independent Component Analysis-Based Epileptogenic Zones with Intracranial Electroencephalogram Localized Seizure Onset Zones and Surgical Outcomes in Prospective Pediatric Intractable Epilepsy Study. *Brain Connect* 7, 424–442.
- Bollmann, S., Barth, M., 2020. New acquisition techniques and their prospects for the achievable resolution of fMRI. *Prog Neurobiol*, 101936.
- Borius, P.Y., Roux, F.E., Valton, L., Sol, J.C., Lotterie, J.A., Berry, I., 2014. Can DTI fiber tracking of the optic radiations predict visual deficit after surgery? *Clin Neurol Neurosurg* 122, 87–91.
- Bottger, J., Margulies, D.S., Horn, P., Thomale, U.W., Podlipsky, I., Shapira-Lichter, I., Chaudhry, S.J., Szkludarek, C., Mueller, K., Lohmann, G., Hendl, T., Bohner, G., Fiebach, J.B., Villringer, A., Vajkoczy, P., Abbushi, A., 2011. A software tool for interactive exploration of intrinsic functional connectivity opens new perspectives for brain surgery. *Acta Neurochir (Wien)* 153, 1561–1572.
- Branco, P., Seixas, D., Deprez, S., Kovacs, S., Peeters, R., Castro, S.L., Sunaert, S., 2016. Resting-State Functional Magnetic Resonance Imaging for Language Preoperative Planning. *Front Hum Neurosci* 10, 11.
- Braun, U., Plichta, M.M., Esslinger, C., Sauer, C., Haddad, L., Grimm, O., Mier, D., Mohnke, S., Heinz, A., Erk, S., Walter, H., Seiferth, N., Kirsch, P., Meyer-Lindenberg, A., 2012. Test-retest reliability of resting-state connectivity network characteristics using fMRI and graph theoretical measures. *Neuroimage* 59, 1404–1412.
- Brodman, K., 1909. Vergleichende Lokalisationslehre der Grosshirnrinde in ihren Prinzipien dargestellt auf Grund des Zellenbaues. Leipzig, Barth.
- Brown, W.R., Thore, C.R., Moody, D.M., Robbins, M.E., Wheeler, K.T., 2005. Vascular damage after fractionated whole-brain irradiation in rats. *Radiat Res* 164, 662–668.
- Buckner, R.L., Krienen, F.M., Yeo, B.T., 2013. Opportunities and limitations of intrinsic functional connectivity MRI. *Nat Neurosci* 16, 832–837.
- Butenko, K., Bahls, C., Schroder, M., Kohling, R., van Rienen, U., 2020. OSS-DBS: Open-source simulation platform for deep brain stimulation with a comprehensive automated modeling. *PLoS Comput Biol* 16, e1008023.
- Cagnan, H., Denison, T., McIntyre, C., Brown, P., 2019. Emerging technologies for improved deep brain stimulation. *Nat Biotechnol* 37, 1024–1033.
- Calabrese, E., Hickey, P., Huette, C., Zhang, J., Parente, B., Lad, S.P., Johnson, G.A., 2015. Postmortem diffusion MRI of the human brainstem and thalamus for deep brain stimulator electrode localization. *Hum Brain Mapp* 36, 3167–3178.
- Carbonell, F., Bellec, P., Shmuel, A., 2011. Global and system-specific resting-state fMRI fluctuations are uncorrelated: principal component analysis reveals anti-correlated networks. *Brain Connect* 1, 496–510.
- Carrera, E., Tononi, G., 2014. Diaschisis: past, present, future. *Brain: a journal of neurology*.
- Cash, R.F., Weigand, A., Zalesky, A., SIDIQI, S.H., Downar, J., Fitzgerald, P.B., Fox, M.D., 2020. Using brain imaging to improve spatial targeting of TMS for depression. *BPS*.
- Catalino, M.P., Yao, S., Green, D.L., Laws, E.R., Golby, A.J., Tie, Y., 2020. Mapping cognitive and emotional networks in neurosurgical patients using resting-state functional magnetic resonance imaging. *Neurosurg Focus* 48, E9.
- Catani, M., Howard, R.J., Pajevic, S., Jones, D.K., 2002. Virtual in vivo interactive dissection of white matter fasciculi in the human brain. *Neuroimage* 17, 77–94.
- Chang, H., Fitzpatrick, J.M., 1992. A technique for accurate magnetic resonance imaging in the presence of field inhomogeneities. *IEEE Trans Med Imaging* 11, 319–329.
- Chapman, C.H., Nagesh, V., Sundgren, P.C., Buchtel, H., Chenevert, T.L., Junck, L., Lawrence, T.S., Tsien, C.I., Cao, Y., 2012. Diffusion tensor imaging of normal-appearing white matter as biomarker for radiation-induced late delayed cognitive decline. *Int J Radiat Oncol Biol Phys* 82, 2033–2040.
- Chapman, C.H., Zhu, T., Nazem-Zadeh, M., Tao, Y., Buchtel, H.A., Tsien, C.I., Lawrence, T.S., Cao, Y., 2016. Diffusion tensor imaging predicts cognitive function change following partial brain radiotherapy for low-grade and benign tumors. *Radiother Oncol* 120, 234–240.
- Chen, W., de Hemptinne, C., Miller, A.M., Leibbrand, M., Little, S.J., Lim, D.A., Larson, P.S., Starr, P.A., 2020. Prefrontal-Subthalamic Hyperdirect Pathway Modulates Movement Inhibition in Humans. *Neuron* 106, 579–588 e573.
- Chen, X., Weigel, D., Ganslandt, O., Buchfelder, M., Nimsky, C., 2009. Prediction of visual field deficits by diffusion tensor imaging in temporal lobe epilepsy surgery. *Neuroimage* 45, 286–297.
- Chen, Z., Tie, Y., Olubi, O., Rigolo, L., Mehrstah, A., Norton, I., Pasternak, O., Rathi, Y., Golby, A.J., O'Donnell, L.J., 2015. Reconstruction of the arcuate fasciculus for surgical planning in the setting of peritumoral edema using two-tensor unscented Kalman filter tractography. *Neuroimage Clin* 7, 815–822.
- Chen, Z., Tie, Y., Olubi, O., Zhang, F., Mehrstah, A., Rigolo, L., Kahali, P., Norton, I., Pasternak, O., Rathi, Y., Golby, A.J., O'Donnell, L.J., 2016. Corticospinal tract modeling for neurosurgical planning by tracking through regions of peritumoral edema and crossing fibers using two-tensor unscented Kalman filter tractography. *Int J Comput Assist Radiol Surg* 11, 1475–1486.
- Cochereau, J., Deverduin, J., Herbet, G., Charroud, C., Boyer, A., Moritz-Gasser, S., Le Bars, E., Molino, F., Bonafe, A., Menot de Champfleury, N., Duffau, H., 2016. Comparison between resting state fMRI networks and responsive cortical stimulations in glioma patients. *Hum Brain Mapp* 37, 3721–3732.
- Coenen, V.A., Allert, N., Madler, B., 2011. A role of diffusion tensor imaging fiber tracking in deep brain stimulation surgery: DBS of the dentato-rubro-thalamic tract (drt) for the treatment of therapy-refractory tremor. *Acta Neurochir (Wien)* 153, 1579–1585 discussion 1585.
- Coenen, V.A., Bewernick, B.H., Kayser, S., Kilian, H., Bostrom, J., Greschus, S., Hurlmann, R., Klein, M.E., Spanier, S., Sajonz, B., Urbach, H., Schlaepfer, T.E., 2019. Supero-lateral medial forebrain bundle deep brain stimulation in major depression: a gateway trial. *Neuropsychopharmacology* 44, 1224–1232.
- Coenen, V.A., Kieslbach, K., Mader, I., Reinacher, P.C., 2015. Diffusion tensor magnetic resonance imaging (DTI) tractography-guided deep brain stimulation in neuropathic pain. *Acta Neurochir (Wien)* 157, 739–741.
- Coenen, V.A., Schlaepfer, T.E., Sajonz, B., Dobrossy, M., Kaller, C.P., Urbach, H., Reiser, M., 2020. Tractographic description of major subcortical projection pathways

- passing the anterior limb of the internal capsule. Corticopetal organization of networks relevant for psychiatric disorders. *Neuroimage Clin* 25, 102165.
- Cohen, A.L., Fox, M.D., 2020. Reply: The influence of sample size and arbitrary statistical thresholds in lesion-network mapping. *Brain* 143, e41.
- Cohen, A.L., Mulder, B.P., Prohl, A.K., Soussand, L., Davis, P., Kroeck, M.R., McManus, P., Gholipour, A., Scherrer, B., Bebin, E.M., Wu, J.Y., Northrup, H., Krueger, D.A., Sahin, M., Warfield, S.K., Fox, M.D., Peters, J.M., 2021. Tuber locations associated with infantile spasms map to a common brain network. *Annals of Neurology*.
- Cole, D.M., Smith, S.M., Beckmann, C.F., 2010. Advances and pitfalls in the analysis and interpretation of resting-state fMRI data. *Front Syst Neurosci* 4, 8.
- Connor, M., Karunamuni, R., McDonald, C., Seibert, T., White, N., Moiseenko, V., Bartsch, H., Farid, N., Kuperman, J., Krishnan, A., Dale, A., Hattangadi-Gluth, J.A., 2017. Regional susceptibility to dose-dependent white matter damage after brain radiotherapy. *Radiother Oncol* 123, 209–217.
- Connor, M., Karunamuni, R., McDonald, C., White, N., Pettersson, N., Moiseenko, V., Seibert, T., Marshall, D., Cervino, L., Bartsch, H., Kuperman, J., Murzin, V., Krishnan, A., Farid, N., Dale, A., Hattangadi-Gluth, J., 2016. Dose-dependent white matter damage after brain radiotherapy. *Radiother Oncol* 121, 209–216.
- Conrad, B.N., Barry, R.L., Rogers, B.P., Maki, S., Mishra, A., Thukral, S., Sriram, S., Bhatia, A., Pawate, S., Gore, J.C., Smith, S.A., 2018. Multiple sclerosis lesions affect intrinsic functional connectivity of the spinal cord. *Brain* 141, 1650–1664.
- Coppieters, I., Meeus, M., Kregel, J., Caeyenberghs, K., De Pauw, R., Goubert, D., Cagnie, B., 2016. Relations Between Brain Alterations and Clinical Pain Measures in Chronic Musculoskeletal Pain: A Systematic Review. *J Pain* 17, 949–962.
- Corp, D.T., Joutsa, J., Darby, R.R., Delnooz, C.C.S., van de Warrenburg, B.P.C., Cooke, D., Prudente, C.N., Ren, J., Reich, M.M., Batla, A., Bhatia, K.P., Jinnah, H.A., Liu, H., Fox, M.D., 2019a. Network localization of cervical dystonia based on causal brain lesions. *Brain* 142, 1660–1674.
- Corp, D.T., Joutsa, J., Darby, R.R., Delnooz, C.C.S., van de Warrenburg, B.P.C., Cooke, D., Prudente, C.N., Ren, J., Reich, M.M., Batla, A., Bhatia, K.P., Jinnah, H.A., Liu, H., Fox, M.D., 2019b. Network localization of cervical dystonia based on causal brain lesions. *Brain: a journal of neurology* 142, 1660–1674.
- Cote, M.A., Girard, G., Bore, A., Garyfallidis, E., Houde, J.C., Descoteaux, M., 2013. Tractometer: towards validation of tractography pipelines. *Med Image Anal* 17, 844–857.
- Cotovio, G., Talmasov, D., Barahona-Corrêa, J.B., Hsu, J., Senova, S., Ribeiro, R., Sous-sand, L., Velosa, A., Silva, V.C.E., Rost, N., Wu, O., Cohen, A.L., Oliveira-Maia, A.J., Fox, M.D., 2020a. Mapping mania symptoms based on focal brain damage. *J Clin Invest* 130, 5209–5222.
- Cotovio, G., Talmasov, D., Barahona-Corrêa, J.B., Hsu, J., Senova, S., Ribeiro, R., Sous-sand, L., Velosa, A., Silva, V.C.E., Rost, N., Wu, O., Cohen, A.L., Oliveira-Maia, A.J., Fox, M.D., 2020b. Mapping mania symptoms based on focal brain damage. *Journal of Clinical Investigation* 130, 5209–5222.
- da Silva, N.M., Ahmadi, S.A., Tafala, S.N., Cunha, J.P.S., Botzel, K., Vollmar, C., Rozanski, V.E., 2017. A diffusion-based connectivity map of the GPI for optimised stereotactic targeting in DBS. *Neuroimage* 144, 83–91.
- Daniel, A.G.S., Park, K.Y., Roland, J.L., Dierker, D., Gross, J., Humphries, J.B., Hacker, C.D., Snyder, A.Z., Shimony, J.S., Leuthardt, E.C., 2021. Functional connectivity within glioblastoma impacts overall survival. *Neuro Oncol* 23, 412–421.
- Darby, R.R., Laganriere, S., Pascual-Leone, A., Prasad, S., Fox, M.D., 2017a. Finding the imposter: brain connectivity of lesions causing delusional misidentifications. *Brain* 140, 497–507.
- Darby, R.R., Laganriere, S., Pascual-Leone, A., Prasad, S., Fox, M.D., 2017b. Finding the imposter: brain connectivity of lesions causing delusional misidentifications. *Brain* 140, 497–507.
- De Vico Fallani, F., Richiardi, J., Chavez, M., Achard, S., 2014. Graph analysis of functional brain networks: practical issues in translational neuroscience. *Philos Trans R Soc Lond B Biol Sci* 369.
- Deistung, A., Schafer, A., Schweser, F., Biedermann, U., Turner, R., Reichenbach, J.R., 2013. Toward in vivo histology: a comparison of quantitative susceptibility mapping (QSM) with magnitude-, phase-, and R2\* -imaging at ultra-high magnetic field strength. *Neuroimage* 65, 299–314.
- Dell'Acqua, F., Tournier, J.D., 2019. Modelling white matter with spherical deconvolution: How and why? *NMR Biomed* 32, e3945.
- Denys, D., Graat, I., Mocking, R., de Koning, P., Vulink, N., Figeet, M., Ooms, P., Mantione, M., van den Munckhof, P., Schuurman, R., 2020. Efficacy of Deep Brain Stimulation of the Ventral Anterior Limb of the Internal Capsule for Refractory Obsessive-Compulsive Disorder: A Clinical Cohort of 70 Patients. *Am J Psychiatry* 177, 265–271.
- Denys, D., Mantione, M., Figeet, M., van den Munckhof, P., Koerselman, F., Westenberg, H., Bosch, A., Schuurman, R., 2010. Deep brain stimulation of the nucleus accumbens for treatment-refractory obsessive-compulsive disorder. *Arch Gen Psychiatry* 67, 1061–1068.
- Desmurget, M., Bonnetblanc, F., Duffau, H., 2007. Contrasting acute and slow-growing lesions: a new door to brain plasticity. *Brain* 130, 898–914.
- Dierker, D., Roland, J.L., Kamran, M., Rutlin, J., Hacker, C.D., Marcus, D.S., Milchenko, M., Miller-Thomas, M.M., Benzinger, T.L., Snyder, A.Z., Leuthardt, E.C., Shimony, J.S., 2017. Resting-state Functional Magnetic Resonance Imaging in Presurgical Functional Mapping: Sensorimotor Localization. *Neuroimaging Clin N Am* 27, 621–633.
- Dougherty, D.D., Rezaei, A.R., Carpenter, L.L., Howland, R.H., Bhati, M.T., O'Reardon, J.P., Eskandar, E.N., Baltuch, G.H., Machado, A.D., Kondziolka, D., Cusin, C., Evans, K.C., Price, L.H., Jacobs, K., Pandya, M., Denko, T., Tyrka, A.R., Brelje, T., Deckersbach, T., Kubu, C., Malone Jr., D.A., 2015. A Randomized Sham-Controlled Trial of Deep Brain Stimulation of the Ventral Capsule/Ventral Striatum for Chronic Treatment-Resistant Depression. *Biol Psychiatry* 78, 240–248.
- Duchin, Y., Shamir, R.R., Patriat, R., Kim, J., Vitek, J.L., Sapiro, G., Harel, N., 2018. Patient-specific anatomical model for deep brain stimulation based on 7 Tesla MRI. *PLoS One* 13, e0201469.
- Duffau, H., 2014a. The dangers of magnetic resonance imaging diffusion tensor tractography in brain surgery. *World Neurosurg* 81, 56–58.
- Duffau, H., 2014b. Diffusion tensor imaging is a research and educational tool, but not yet a clinical tool. *World Neurosurg* 82, e43–e45.
- Duffau, H., 2020. Why brain radiation therapy should take account of the individual structural and functional connectivity: Toward an irradiation "a la carte". *Crit Rev Oncol Hematol* 154, 103073.
- Duffau, H., 2021. New Philosophy, Clinical Pearls, and Methods for Intraoperative Cognition Mapping and Monitoring "a la carte". *Brain Tumor Patients. Neurosurgery*.
- Dum, R.P., Strick, P.L., 2003. An unfolded map of the cerebellar dentate nucleus and its projections to the cerebral cortex. *J Neurophysiol* 89, 634–639.
- Duval, C., Daneault, J.F., Hutchison, W.D., Sadikot, A.F., 2016. A brain network model explaining tremor in Parkinson's disease. *Neurobiol Dis* 85, 49–59.
- Edlow, B.L., Mareyam, A., Horn, A., Polimeni, J.R., Witzel, T., Tisdall, M.D., Augustinack, J.C., Stockmann, J.P., Diamond, B.R., Stevens, A., Tirrell, L.S., Folkerth, R.D., Wald, L.L., Fischl, B., van der Kouwe, A., 2019. 7 Tesla MRI of the ex vivo human brain at 100 micron resolution. *Sci Data* 6, 244.
- Eickhoff, S.B., Milham, M., Vanderwal, T., 2020. Towards clinical applications of movie fMRI. *Neuroimage* 217, 116860.
- Ekstrom, A., 2010. How and when the fMRI BOLD signal relates to underlying neural activity: the danger in dissociation. *Brain Res Rev* 62, 233–244.
- Elias, G.J.B., De Vloot, P., Germann, J., Boutet, A., Gramer, R.M., Joel, S.E., Morlion, B., Nuttin, B., Lozano, A.M., 2020. Mapping the network underpinnings of central post-stroke pain and analgesic neuromodulation. *PAIN®*.
- Elliott, M.L., Knodt, A.R., Ireland, D., Morris, M.L., Poulton, R., Ramrakha, S., Sison, M.L., Moffitt, T.E., Caspi, A., Hariri, A.R., 2020. What Is the Test-Retest Reliability of Common Task-Functional MRI Measures? New Empirical Evidence and a Meta-Analysis. *Psychol Sci* 31, 792–806.
- Essayed, W.I., Zhang, F., Unadkat, P., Cosgrove, G.R., Golby, A.J., O'Donnell, L.J., 2017. White matter tractography for neurosurgical planning: A topography-based review of the current state of the art. *Neuroimage Clin* 15, 659–672.
- Eusebio, A., Thevathasan, W., Doyle Gaynor, L., Pogoyan, A., Bye, E., Foltynie, T., Zrinzo, L., Ashkan, K., Aziz, T., Brown, P., 2011. Deep brain stimulation can suppress pathological synchronisation in parkinsonian patients. *J Neurol Neurosurg Psychiatry* 82, 569–573.
- Farrokhi, F., Buchlak, Q.D., Sikora, M., Esmaili, N., Marsans, M., McLeod, P., Mark, J., Cox, E., Bennett, C., Carlson, J., 2020. Investigating Risk Factors and Predicting Complications in Deep Brain Stimulation Surgery with Machine Learning Algorithms. *World Neurosurg* 134, e325–e338.
- Fasano, A., Laganriere, S.E., Lam, S., Fox, M.D., 2017. Lesions causing freezing of gait localize to a cerebellar functional network. *Ann Neurol* 81, 129–141.
- Feigl, G.C., Hiergeist, W., Fellner, C., Schebesch, K.M., Doenitz, C., Finkenzeller, T., Brawanski, A., Schlaier, J., 2014. Magnetic resonance imaging diffusion tensor tractography: evaluation of anatomic accuracy of different fiber tracking software packages. *World Neurosurg* 81, 144–150.
- Feldman, S.C., Chu, D., Schulder, M., Pawar, R., Barry, M., Cho, E., Liu, W., 2009. The blood oxygen level-dependent functional MR imaging signal can be used to identify brain tumors and distinguish them from normal tissue. *AJNR Am J Neuroradiol* 30, 389–395.
- Ferguson, M.A., Lim, C., Cooke, D., Darby, R.R., Wu, O., Rost, N.S., Corbetta, M., Grafman, J., Fox, M.D., 2019a. A human memory circuit derived from brain lesions causing amnesia. *Nat Commun* 10, 3497.
- Ferguson, M.A., Lim, C., Cooke, D., Darby, R.R., Wu, O., Rost, N.S., Corbetta, M., Grafman, J., Fox, M.D., 2019b. A human memory circuit derived from brain lesions causing amnesia. *Nature communications* 10, 3497–3499.
- Fernandez, G., Specht, K., Weis, S., Tendolkar, I., Reuber, M., Fell, J., Klaver, P., Ruhlmann, J., Reul, J., Elger, C.E., 2003. Intrasubject reproducibility of presurgical language lateralization and mapping using fMRI. *Neurology* 60, 969–975.
- Ferraro, S., Nigri, A., Bruzzone, M.G., Brivio, L., Proietti Cecchini, A., Verri, M., Chiapparini, L., Leone, M., 2018. Defective functional connectivity between posterior hypothalamus and regions of the diencephalic-mesencephalic junction in chronic cluster headache. *Cephalalgia* 38, 1910–1918.
- Ferrier, D., 1886. *The functions of the brain*, 2nd ed. ed. Smith Elder, London.
- Forstmann, B.U., Keuken, M.C., Schafer, A., Bazin, P.L., Alkemade, A., Turner, R., 2014. Multi-modal ultra-high resolution structural 7-Tesla MRI data repository. *Sci Data* 1, 140050.
- Fox, M.D., 2018. Mapping Symptoms to Brain Networks with the Human Connectome. *The New England journal of medicine* 379, 2237–2245.
- Fox, M.D., Qian, T., Madsen, J.R., Wang, D., Li, M., Ge, M., Zuo, H.-C., Groppe, D.M., Mehta, A.D., Hong, B., Liu, H., 2016. Combining task-evoked and spontaneous activity to improve pre-operative brain mapping with fMRI. *Neuroimage* 124, 714–723.
- Fox, M.D., Raichle, M.E., 2007. Spontaneous fluctuations in brain activity observed with functional magnetic resonance imaging. *Nat Rev Neurosci* 8, 700–711.
- Fox, M.D., Zhang, D., Snyder, A.Z., Raichle, M.E., 2009. The global signal and observed anticorrelated resting state brain networks. *J Neurophysiol* 101, 3270–3283.
- Fridericsson, E.A., Figeet, M., Luigjes, J., van den Munckhof, P., Schuurman, P.R., van Wingen, G., Denys, D., 2020. Deep brain stimulation modulates directional limbic connectivity in obsessive-compulsive disorder. *Brain* 143, 1603–1612.
- Friston, K.J., 1994. Functional and effective connectivity in neuroimaging: A synthesis. *Human Brain Mapping* 2, 56–78.
- Friston, K.J., Harrison, L., Penny, W., 2003. Dynamic causal modelling. *Neuroimage* 19, 1273–1302.
- Gallay, M.N., Jeanmonod, D., Liu, J., Morel, A., 2008. Human pallidothalamic and cerebellothalamic tracts: anatomical basis for functional stereotactic neurosurgery. *Brain Struct Funct* 212, 443–463.
- Galvis, J., Mezher, A.F., Ragothaman, A., Villalon-Reina, J.E., Fletcher, P.T., Thomp-



- son, P.M., Prasad, G., 2016. Effects of EPI distortion correction pipelines on the connectome in Parkinson's Disease. *Medical Imaging 2016: Image Processing*. San Diego, CA, USA, p. 97843D.
- Ganesan, K., Ursekar, M., 2014. Clinical utility of BOLD fMRI in preoperative work-up of epilepsy. *Indian J Radiol Imaging* 24, 22–36.
- Gellerup, D., 2016. Discriminating Parkinson's disease using functional connectivity and brain network analysis. *Industrial Engineering*. The University of Texas at Arlington, Arlington, TX, p. 54.
- Gibson, W.S., Cho, S., Abulseoud, O.A., Gorny, K.R., Felmlee, J.P., Welker, K.M., Klassen, B.T., Min, H.K., Lee, K.H., 2017. The Impact of Mirth-Inducing Ventral Striatal Deep Brain Stimulation on Functional and Effective Connectivity. *Cereb Cortex* 27, 2183–2194.
- Gibson, W.S., Jo, H.J., Testini, P., Cho, S., Felmlee, J.P., Welker, K.M., Klassen, B.T., Min, H.K., Lee, K.H., 2016. Functional correlates of the therapeutic and adverse effects evoked by thalamic stimulation for essential tremor. *Brain* 139, 2198–2210.
- Gleichgerricht, E., Fridriksson, J., Rorden, C., Bonilha, L., 2017. Connectome-based lesion-symptom mapping (CLSM): A novel approach to map neurological function. *Neuroimage Clin* 16, 461–467.
- Gleichgerricht, E., Munsell, B., Bhatia, S., Vandergrift 3rd, W.A., Rorden, C., McDonald, C., Edwards, J., Kuzniecky, R., Bonilha, L., 2018. Deep learning applied to whole-brain connectome to determine seizure control after epilepsy surgery. *Epilepsia* 59, 1643–1654.
- Goense, J., Bohraus, Y., Logothetis, N.K., 2016. fMRI at High Spatial Resolution: Implications for BOLD-Models. *Front Comput Neurosci* 10, 66.
- Gómez-Orozco, V., De La Pava Panche, I., Álvarez-Meza, A.M., Álvarez-López, M.A., Orozco-Gutiérrez, Á.Á., 2019. A machine learning approach to support deep brain stimulation programming. *Revista Facultad de Ingeniería Universidad de Antioquia*, pp. 20–33.
- Gong, S., Zhang, F., Norton, I., Essayed, W.I., Unadkat, P., Rigolo, L., Pasternak, O., Rathi, Y., Hou, L., Golby, A.J., O'Donnell, L.J., 2018. Free water modeling of peritumoral edema using multi-fiber tractography: Application to tracking the arcuate fasciculus for neurosurgical planning. *PLoS One* 13, e0197056.
- Granger, C.W.J., 1969. Investigating Causal Relations by Econometric Models and Cross-spectral Methods. *Econometrica* 37, 424.
- Gratwicke, J., Oswal, A., Akram, H., Jahanshahi, M., Hariz, M., Zrinzo, L., Foltynie, T., Litvak, V., 2020. Resting state activity and connectivity of the nucleus basalis of Meynert and globus pallidus in Lewy body dementia and Parkinson's disease dementia. *Neuroimage* 221, 117184.
- Greenberg, B.D., Gabriels, L.A., Malone Jr., D.A., Rezaei, A.R., Friebs, G.M., Okun, M.S., Shapira, N.A., Foote, K.D., Cosyns, P.R., Kubu, C.S., Malloy, P.F., Salloway, S.P., Giftakis, J.E., Rise, M.T., Machado, A.G., Baker, K.B., Stypulkowski, P.H., Goodman, W.K., Rasmussen, S.A., Nuttin, B.J., 2010. Deep brain stimulation of the ventral internal capsule/ventral striatum for obsessive-compulsive disorder: worldwide experience. *Mol Psychiatry* 15, 64–79.
- Greene-Schloesser, D., Robbins, M.E., 2012. Radiation-induced cognitive impairment—from bench to bedside. *Neuro Oncol* 14 (4) Suppl37–44.
- Greene-Schloesser, D., Robbins, M.E., Peiffer, A.M., Shaw, E.G., Wheeler, K.T., Chan, M.D., 2012. Radiation-induced brain injury: A review. *Front Oncol* 2, 73.
- Gross, R.E., Krack, P., Rodriguez-Oroz, M.C., Rezaei, A.R., Benabid, A.L., 2006. Electrophysiological mapping for the implantation of deep brain stimulators for Parkinson's disease and tremor. *Mov Disord* 21 (14), S259–S283 Suppl.
- Gunalan, K., Chaturvedi, A., Howell, B., Duchin, Y., Lempka, S.F., Patriat, R., Sapiro, G., Harel, N., McIntyre, C.C., 2017. Creating and parameterizing patient-specific deep brain stimulation pathway-activation models using the hyperdirect pathway as an example. *PLoS One* 12, e0176132.
- Guo, C.C., Kurth, F., Zhou, J., Mayer, E.A., Eickhoff, S.B., Kramer, J.H., Seeley, W.W., 2012. One-year test-retest reliability of intrinsic connectivity network fMRI in older adults. *Neuroimage* 61, 1471–1483.
- Hagmann, P., 2005. From diffusion MRI to brain connectomics. Signal Processing Institute. École polytechnique fédérale de Lausanne, Lausanne, Switzerland.
- Hamani, C., Mayberg, H., Snyder, B., Giacobbe, P., Kennedy, S., Lozano, A.M., 2009. Deep brain stimulation of the subcallosal cingulate gyrus for depression: anatomical location of active contacts in clinical responders and a suggested guideline for targeting. *J Neurosurg* 111, 1209–1215.
- Hamani, C., Mayberg, H., Stone, S., Laxton, A., Haber, S., Lozano, A.M., 2011. The subcallosal cingulate gyrus in the context of major depression. *Biol Psychiatry* 69, 301–308.
- Hanssen, H., Steinhardt, J., Munchau, A., Al-Zubaidi, A., Tzvi, E., Heldmann, M., Schramm, P., Neumann, A., Rasche, D., Saryyeva, A., Voges, J., Galazky, I., Buntjen, L., Heinze, H.J., Krauss, J.K., Tronnier, V., Munte, T.F., Bruggemann, N., 2019. Cerebello-striatal interaction mediates effects of subthalamic nucleus deep brain stimulation in Parkinson's disease. *Parkinsonism Relat Disord* 67, 99–104.
- Hart, M.G., Price, S.J., Suckling, J., 2016. Connectome analysis for pre-operative brain mapping in neurosurgery. *Br J Neurosurg* 30, 506–517.
- Hasson, U., Nir, Y., Levy, I., Fuhrmann, G., Malach, R., 2004. Intersubject synchronization of cortical activity during natural vision. *Science* 303, 1634–1640.
- He, H., Liu, T.T., 2012. A geometric view of global signal confounds in resting-state functional MRI. *Neuroimage* 59, 2339–2348.
- He, Y., Evans, A., 2010. Graph theoretical modeling of brain connectivity. *Curr Opin Neurobiol* 23, 341–350.
- Helmich, R.C., Hallett, M., Deuschl, G., Toni, I., Bloem, B.R., 2012. Cerebral causes and consequences of parkinsonian resting tremor: a tale of two circuits? *Brain* 135, 3206–3226.
- Henderson, F., Abdullah, K.G., Verma, R., Brem, S., 2020. Tractography and the connectome in neurosurgical treatment of gliomas: the premise, the progress, and the potential. *Neurosurg Focus* 48, E6.
- Hirschmann, J., Ozkurt, T.E., Butz, M., Homburger, M., Elben, S., Hartmann, C.J., Verser, J., Wojtecki, L., Schnitzler, A., 2011. Distinct oscillatory STN-cortical loops revealed by simultaneous MEG and local field potential recordings in patients with Parkinson's disease. *Neuroimage* 55, 1159–1168.
- Holiga, S., Sambataro, F., Luzy, C., Greig, G., Sarkar, N., Renken, R.J., Marsman, J.C., Schobel, S.A., Bertolino, A., Dukart, J., 2018. Test-retest reliability of task-based and resting-state blood oxygen level dependence and cerebral blood flow measures. *PLoS One* 13, e0206583.
- Holl, E.M., Petersen, E.A., Foltynie, T., Martinez-Torres, I., Limousin, P., Hariz, M.I., Zrinzo, L., 2010. Improving targeting in image-guided frame-based deep brain stimulation. *Neurosurgery* 67, 437–447.
- Holtzheimer, P.E., Husain, M.M., Lisanby, S.H., Taylor, S.F., Whitworth, L.A., McClintock, S., Slavin, K.V., Berman, J., McKhann, G.M., Patil, P.G., Rittberg, B.R., Abosch, A., Pandurangi, A.K., Holloway, K.L., Lam, R.W., Honey, C.R., Neimat, J.S., Henderson, J.M., DeBattista, C., Rothschild, A.J., Pilitsis, J.G., Espinoza, R.T., Petrides, G., Mogilner, A.Y., Matthews, K., Peichel, D., Gross, R.E., Hamani, C., Lozano, A.M., Mayberg, H.S., 2017. Subcallosal cingulate deep brain stimulation for treatment-resistant depression: a multisite, randomised, sham-controlled trial. *Lancet Psychiatry* 4, 839–849.
- Holtzheimer, P.E., Kelley, M.E., Gross, R.E., Filkowski, M.M., Garlow, S.J., Barrocas, A., Wint, D., Craighead, M.C., Kozarsky, J., Chismar, R., Moreines, J.L., Mewes, K., Posse, P.R., Gutman, D.A., Mayberg, H.S., 2012. Subcallosal cingulate deep brain stimulation for treatment-resistant unipolar and bipolar depression. *Arch Gen Psychiatry* 69, 150–158.
- Horn, A., Fox, M.D., 2020. Opportunities of connectomic neuromodulation. *Neuroimage* 221, 117180.
- Horn, A., Kuhn, A.A., 2015. Lead-DBS: a toolbox for deep brain stimulation electrode localizations and visualizations. *Neuroimage* 107, 127–135.
- Horn, A., Reich, M., Vorwerk, J., Li, N., Wenzel, G., Fang, Q., Schmitz-Hubsch, T., Nickl, R., Kupsch, A., Volkmann, J., Kuhn, A.A., Fox, M.D., 2017. Connectivity Predicts deep brain stimulation outcome in Parkinson disease. *Ann Neurol* 82, 67–78.
- Horsely, V., 1886. *Brain Surgery*. Br Med J 2, 670–677.
- Horsely, V., Schafer, E.A., 1888. I. A record of experiments upon the functions of the cerebral cortex. *Philosophical Transactions of the Royal Society of London*. (B.) 179, 1–45.
- Houri, J., Karunamuni, R., Connor, M., Pettersson, N., McDonald, C., Farid, N., White, N., Dale, A., Hattangadi-Gluth, J.A., Moiseenko, V., 2018. Analyses of regional radiosensitivity of white matter structures along tract axes using novel white matter segmentation and diffusion imaging biomarkers. *Physics and Imaging in Radiation Oncology* 6, 39–46.
- Hsu, A.L., Chen, H.S., Hou, P., Wu, C.W., Johnson, J.M., Noll, K.R., Prabhu, S.S., Ferguson, S.D., Kumar, V.A., Schomer, D.F., Chen, J.H., Liu, H.L., 2020. Presurgical resting-state functional MRI language mapping with seed selection guided by regional homogeneity. *Magn Reson Med* 84, 375–383.
- Huang, H., Ding, Z., Mao, D., Yuan, J., Zhu, F., Chen, S., Xu, Y., Lou, L., Feng, X., Qi, L., Qiu, W., Zhang, H., Zang, Y.F., 2016. PreSurgMapp: a MATLAB Toolbox for Presurgical Mapping of Eloquent Functional Areas Based on Task-Related and Resting-State Functional MRI. *Neuroinformatics* 14, 421–438.
- Huang, H., Lu, J., Wu, J., Ding, Z., Chen, S., Duan, L., Cui, J., Chen, F., Kang, D., Qi, L., Qiu, W., Lee, S.W., Qiu, S., Shen, D., Zang, Y.F., Zhang, H., 2018. Tumor Tissue Detection using Blood-Oxygen-Level-Dependent Functional MRI based on Independent Component Analysis. *Sci Rep* 8, 1223.
- Hughlings Jackson, J., 1868. Notes on the physiology and pathology of the nervous system. *Med Times Gaz* ii, pp. 177–179.
- Hunsche, S., Sauner, D., Runge, M.J., Lenartz, D., El Majdoub, F., Treuer, H., Sturm, V., Maarouf, M., 2013. Tractography-guided stimulation of somatosensory fibers for thalamic pain relief. *Stereotact Funct Neurosurg* 91, 328–334.
- Huo, W., Angeles, P., Tai, Y.F., Pavese, N., Wilson, S., Hu, M.T., Vaidyanathan, R., 2020. A Heterogeneous Sensing Suite for Multisymptom Quantification of Parkinson's Disease. *IEEE Trans Neural Syst Rehabil Eng* 28, 1397–1406.
- Huynh-Le, M.P., Tibbs, M.D., Karunamuni, R., Tringale, K.R., Salans, M., Yip, A., Connor, M., Simon, A.B., Vitzthum, L.K., Reyes, A., Macari, A.C., Moiseenko, V., McDonald, C.R., Hattangadi-Gluth, J.A., 2021. Microstructural injury to corpus callosum and intra-hemispheric white matter tracts correlate with attention and processing speed decline after brain radiation. *Int J Radiat Oncol Biol Phys*.
- Hwang, K., Bruss, J., Tranel, D., Boes, A.D., 2020. Network Localization of Executive Function Deficits in Patients with Focal Thalamic Lesions. *J Cogn Neurosci* 32, 2303–2319.
- Ing, A., Schwarzbauer, C., 2014. Cluster size statistic and cluster mass statistic: two novel methods for identifying changes in functional connectivity between groups or conditions. *PLoS One* 9, e98697.
- Irmen, F., Horn, A., Mosley, P., Perry, A., Petry-Schmelzer, J.N., Dafsari, H.S., Barbe, M., Visser-Vandewalle, V., Schneider, G.H., Li, N., Kubler, D., Wenzel, G., Kuhn, A.A., 2020. Left Prefrontal Connectivity Links Subthalamic Stimulation with Depressive Symptoms. *Ann Neurol* 87, 962–975.
- Ishikawa, T., Muragaki, Y., Maruyama, T., Abe, K., Kawamata, T., 2017. Roles of the Wada Test and Functional Magnetic Resonance Imaging in Identifying the Language-dominant Hemisphere among Patients with Gliomas Located near Speech Areas. *Neurol Med Chir (Tokyo)* 57, 28–34.
- James, J.S., Radhakrishnan, A., Thomas, B., Madhusoodanan, M., Kesavadas, C., Abraham, M., Menon, R., Rathore, C., Vilanilam, G., 2015. Diffusion tensor imaging tractography of Meyer's loop in planning resective surgery for drug-resistant temporal lobe epilepsy. *Epilepsy Res* 110, 95–104.
- Jbabdi, S., Johansen-Berg, H., 2011. Tractography: where do we go from here? *Brain Connect* 1, 169–183.
- Jbabdi, S., Sotiropoulos, S.N., Savio, A.M., Grana, M., Behrens, T.E., 2012. Model-based analysis of multipool diffusion MR data for tractography: how to get over fitting problems. *Magn Reson Med* 68, 1846–1855.

- Jellison, B.J., Field, A.S., Medow, J., Lazar, M., Salamat, M.S., Alexander, A.L., 2004. Diffusion tensor imaging of cerebral white matter: a pictorial review of physics, fiber tract anatomy, and tumor imaging patterns. *AJNR Am J Neuroradiol* 25, 356–369.
- Jin, L., Li, C., Zhang, Y., Yuan, T., Ying, J., Zuo, Z., Gui, S., 2021. The Functional Reorganization of Language Network Modules in Glioma Patients: New Insights From Resting State fMRI Study. *Front Oncol* 11, 617179.
- Joel, S.E., Caffo, B.S., van Zijl, P.C., Pekar, J.J., 2011. On the relationship between seed-based and ICA-based measures of functional connectivity. *Magn Reson Med* 66, 644–657.
- Jornfelt, H., Ekerot, C.F., 1999. Topographical organization of projections to cat motor cortex from nucleus interpositus anterior and forelimb skin. *J Physiol* 514 (2), 551–566 Pt.
- Joutsa, J., Horn, A., Hsu, J., Fox, M.D., 2018a. Localizing parkinsonism based on focal brain lesions. *Brain* 141, 2445–2456.
- Joutsa, J., Horn, A., Hsu, J., Fox, M.D., 2018b. Localizing parkinsonism based on focal brain lesions. *Brain* 141, 2225–2229.
- Joutsa, J., Shih, L.C., Fox, M.D., 2019. Mapping holmes tremor circuit using the human brain connectome. *Ann Neurol* 86, 812–820.
- Joutsa, J., Shih, L.C., Horn, A., Reich, M.M., Wu, O., Rost, N.S., Fox, M.D., 2018c. Identifying therapeutic targets from spontaneous beneficial brain lesions. *Ann Neurol* 84, 153–157.
- Kahan, J., Mancini, L., Flandin, G., White, M., Papadaki, A., Thornton, J., Yousry, T., Zrinzo, L., Hariz, M., Limousin, P., Friston, K., Foltynie, T., 2019. Deep brain stimulation has state-dependent effects on motor connectivity in Parkinson's disease. *Brain* 142, 2417–2431.
- Kahan, J., Mancini, L., Urner, M., Friston, K., Hariz, M., Holl, E., White, M., Ruge, D., Jahanshahi, M., Boertien, T., Yousry, T., Thornton, J.S., Limousin, P., Zrinzo, L., Foltynie, T., 2012. Therapeutic subthalamic nucleus deep brain stimulation reverses cortico-thalamic coupling during voluntary movements in Parkinson's disease. *PLoS One* 7, e50270.
- Kahan, J., Urner, M., Moran, R., Flandin, G., Marreiros, A., Mancini, L., White, M., Thornton, J., Yousry, T., Zrinzo, L., Hariz, M., Limousin, P., Friston, K., Foltynie, T., 2014. Resting state functional MRI in Parkinson's disease: the impact of deep brain stimulation on 'effective' connectivity. *Brain* 137, 1130–1144.
- Keller, S.S., Glenn, G.R., Weber, B., Kreilkamp, B.A., Jensen, J.H., Helpner, J.A., Wagner, J., Barker, G.J., Richardson, M.P., Bonilha, L., 2017. Preoperative automated fibre quantification predicts postoperative seizure outcome in temporal lobe epilepsy. *Brain* 140, 68–82.
- Keuken, M.C., Bazin, P.L., Crown, L., Hootsmans, J., Laufer, A., Muller-Axt, C., Sier, R., van der Putten, E.J., Schafer, A., Turner, R., Forstmann, B.U., 2014. Quantifying inter-individual anatomical variability in the subcortex using 7 T structural MRI. *Neuroimage* 94, 40–46.
- Kim, J., Duchin, Y., Shamir, R.R., Patriat, R., Vitek, J., Harel, N., Sapiro, G., 2019a. Automatic localization of the subthalamic nucleus on patient-specific clinical MRI by incorporating 7 T MRI and machine learning: Application in deep brain stimulation. *Hum Brain Mapp* 40, 679–698.
- Kim, N.Y., Hsu, J., Talmassov, D., Joutsa, J., Soussand, L., Wu, O., Rost, N.S., Morenas-Rodríguez, E., Martí-Fàbregas, J., Pascual-Leone, A., Corlett, P.R., Fox, M.D., 2019b. Lesions causing hallucinations localize to one common brain network. *Mol Psychiatry*.
- Kim, N.Y., Hsu, J., Talmassov, D., Joutsa, J., Soussand, L., Wu, O., Rost, N.S., Morenas-Rodríguez, E., Martí-Fàbregas, J., Pascual-Leone, A., Corlett, P.R., Fox, M.D., 2019c. Lesions causing hallucinations localize to one common brain network. *Molecular Psychiatry* 1–11.
- Klein, A., Andersson, J., Ardekani, B.A., Ashburner, J., Avants, B., Chiang, M.C., Christensen, G.E., Collins, D.L., Gee, J., Hellier, P., Song, J.H., Jenkinson, M., Lepage, C., Rueckert, D., Thompson, P., Vercauteren, T., Woods, R.P., Mann, J.J., Parsey, R.V., 2009. Evaluation of 14 nonlinear deformation algorithms applied to human brain MRI registration. *Neuroimage* 46, 786–802.
- Klingbeil, J., Wawrzyniak, M., Stockert, A., Karnath, H.O., Saur, D., 2020. Hippocampal diaschisis contributes to anosognosia for hemiplegia: Evidence from lesion network-symptom-mapping. *Neuroimage* 208, 116485.
- Kober, T., Gruetter, R., Krueger, G., 2012. Prospective and retrospective motion correction in diffusion magnetic resonance imaging of the human brain. *Neuroimage* 59, 389–398.
- Koch, M., Geraedts, V., Wang, H., Tannemaat, M., Bäck, T., 2019. Automated Machine Learning for EEG-Based Classification of Parkinson's Disease Patients. In: 2019 IEEE International Conference on Big Data (Big Data), Los Angeles, CA, USA, pp. 4845–4852.
- Koga, T., Maruyama, K., Kamada, K., Ota, T., Shin, M., Itoh, D., Kunii, N., Ino, K., Terahara, A., Aoki, S., Masutani, Y., Saito, N., 2012. Outcomes of diffusion tensor tractography-integrated stereotactic radiosurgery. *Int J Radiat Oncol Biol Phys* 82, 799–802.
- Koivuala, N., Fleischer, V., Glaser, M., Zeuner, K.E., Deuschl, G., Volkman, J., Muthuraman, M., Groppa, S., 2018. Frontal Lobe Connectivity and Network Community Characteristics are Associated with the Outcome of Subthalamic Nucleus Deep Brain Stimulation in Patients with Parkinson's Disease. *Brain Topogr* 31, 311–321.
- Kokkonen, S.M., Nikkinen, J., Remes, J., Kantola, J., Starck, T., Haapea, M., Tuominen, J., Tervonen, O., Kiviniemi, V., 2009. Preoperative localization of the sensorimotor area using independent component analysis of resting-state fMRI. *Magn Reson Imaging* 27, 733–740.
- Kovanlikaya, I., Heier, L., Kaplitt, M., 2014. Treatment of chronic pain: diffusion tensor imaging identification of the ventroposterolateral nucleus confirmed with successful deep brain stimulation. *Stereotact Funct Neurosurg* 92, 365–371.
- Krieg, S.M., Sollmann, N., Obermueller, T., Sabih, J., Bulbas, L., Negwer, C., Moser, T., Droese, D., Boeckh-Behrens, T., Ringel, F., Meyer, B., 2015. Changing the clinical course of glioma patients by preoperative motor mapping with navigated transcranial magnetic brain stimulation. *BMC Cancer* 15, 231.
- Laganieri, S., Boes, A.D., Fox, M.D., 2016. Network localization of hemichorea-hemiballism. *Neurology* 86, 2187–2195.
- Lang, S., Gaxiola-Valdez, I., Opoku-Darko, M., Partlo, L.A., Goodyear, B.G., Kelly, J.J.P., Federico, P., 2017. Functional Connectivity in Frontoparietal Network: Indicator of Preoperative Cognitive Function and Cognitive Outcome Following Surgery in Patients with Glioma. *World Neurosurg* 105, 913–922 e912.
- Lansberg, M.G., Thijs, V.N., O'Brien, M.W., Ali, J.O., de Crespigny, A.J., Tong, D.C., Moseley, M.E., Albers, G.W., 2001. Evolution of apparent diffusion coefficient, diffusion-weighted, and T2-weighted signal intensity of acute stroke. *AJNR Am J Neuroradiol* 22, 637–644.
- Lazar, M., Alexander, A.L., 2003. An error analysis of white matter tractography methods: synthetic diffusion tensor field simulations. *Neuroimage* 20, 1140–1153.
- Le Bihan, D., 2003. Looking into the functional architecture of the brain with diffusion MRI. *Nat Rev Neurosci* 4, 469–480.
- Lee, I., Nielsen, K., Nawaz, U., Hall, M.H., Öngür, D., Keshavan, M., Brady, R., 2019. Diverse pathophysiological processes converge on network disruption in mania. *J Affect Disord* 244, 115–123.
- Leksell, L., Leksell, D., Schwebel, J., 1985. Stereotaxis and nuclear magnetic resonance. *J Neurol Neurosurg Psychiatry* 48, 14–18.
- Lemaire, J.J., Sakka, L., Ouchchane, L., Caire, F., Gabrillargues, J., Bonny, J.M., 2010. Anatomy of the human thalamus based on spontaneous contrast and microscopic voxels in high-field magnetic resonance imaging. *Neurosurgery* 66, 161–172.
- Lenglet, C., Aboch, A., Yacoub, E., De Martino, F., Sapiro, G., Harel, N., 2012. Comprehensive in vivo mapping of the human basal ganglia and thalamic connectome in individuals using 7T MRI. *PLoS One* 7, e29153.
- Leuthardt, E.C., Guzman, G., Bandt, S.K., Hacker, C., Vellimano, A.K., Limbrick, D., Milchenko, M., Lamontagne, P., Speidel, B., Roland, J., Miller-Thomas, M., Snyder, A.Z., Marcus, D., Shimony, J., Benzinger, T.L.S., 2018. Integration of resting state functional MRI into clinical practice - A large single institution experience. *PLoS One* 13, e0198349.
- Li, N., Baldermann, J.C., Kibler, A., Treu, S., Akram, H., Elias, G.J.B., Boutet, A., Lozano, A.M., Al-Fatly, B., Strange, B., Barcia, J.A., Zrinzo, L., Joyce, E., Chabardes, S., Visser-Vandewalle, V., Polosan, M., Kuhn, J., Kuhn, A.A., Horn, A., 2020. A unified connectomic target for deep brain stimulation in obsessive-compulsive disorder. *Nat Commun* 11, 3364.
- Liang, X., Wang, J., Yan, C., Shu, N., Xu, K., Gong, G., He, Y., 2012. Effects of different correlation metrics and preprocessing factors on small-world brain functional networks: a resting-state functional MRI study. *PLoS One* 7, e32766.
- Lin, Q., Dai, Z., Xia, M., Han, Z., Huang, R., Gong, G., Liu, C., Bi, Y., He, Y., 2015. A connectivity-based test-retest dataset of multi-modal magnetic resonance imaging in young healthy adults. *Sci Data* 2, 150056.
- Little, S., Pogoyan, A., Neal, S., Zavala, B., Zrinzo, L., Hariz, M., Foltynie, T., Limousin, P., Ashkan, K., FitzGerald, J., Green, A.L., Aziz, T.Z., Brown, P., 2013. Adaptive deep brain stimulation in advanced Parkinson disease. *Ann Neurol* 74, 449–457.
- Litvak, V., Jha, A., Eusebio, A., Oostenveld, R., Foltynie, T., Limousin, P., Zrinzo, L., Hariz, M.I., Friston, K., Brown, P., 2011. Resting oscillatory cortico-subthalamic connectivity in patients with Parkinson's disease. *Brain* 134, 359–374.
- Liu, H., Buckner, R.L., Talukdar, T., Tanaka, N., Madsen, J.R., Stufflebeam, S.M., 2009. Task-free presurgical mapping using functional magnetic resonance imaging intrinsic activity. *J Neurosurg* 111, 746–754.
- Liu, T.T., Nalci, A., Falahpour, M., 2017. The global signal in fMRI: Nuisance or Information? *Neuroimage* 150, 213–229.
- Llinas, R., Urbano, F.J., Leznik, E., Ramirez, R.R., van Marle, H.J., 2005. Rhythmic and dysrhythmic thalamocortical dynamics: GABA systems and the edge effect. *Trends Neurosci* 28, 325–333.
- Llinas, R.R., 1988. The intrinsic electrophysiological properties of mammalian neurons: insights into central nervous system function. *Science* 242, 1654–1664.
- Lu, J., Zhang, H., Hameed, N.U.F., Zhang, J., Yuan, S., Qiu, T., Shen, D., Wu, J., 2017. An automated method for identifying an independent component analysis-based language-related resting-state network in brain tumor subjects for surgical planning. *Sci Rep* 7, 13769.
- Luckett, P., Lee, J.J., Park, K.Y., Dierker, D., Daniel, A.G.S., Seitzman, B.A., Hacker, C.D., Ances, B.M., Leuthardt, E.C., Snyder, A.Z., Shimony, J.S., 2020. Mapping of the Language Network With Deep Learning. *Front Neurol* 11, 819.
- Luyten, L., Hendrickx, S., Raymaekers, S., Gabriels, L., Nuttin, B., 2016. Electrical stimulation in the bed nucleus of the stria terminalis alleviates severe obsessive-compulsive disorder. *Mol Psychiatry* 21, 1272–1280.
- MacDonald, G., 1986. *The Princess and the Goblin*. Books of Wonder, New York, NY.
- Makale, M.T., McDonald, C.R., Hattangadi-Gluth, J.A., Kesari, S., 2017. Mechanisms of radiotherapy-associated cognitive disability in patients with brain tumours. *Nat Rev Neurosci* 13, 52–64.
- Mallet, L., Polosan, M., Jaafari, N., Baup, N., Welter, M.L., Fontaine, D., du Montcel, S.T., Zelink, J., Chereau, I., Arbus, C., Raoul, S., Aouizerate, B., Damier, P., Chabardes, S., Czernecki, V., Ardouin, C., Krebs, M.O., Bardinet, E., Chaynes, P., Burbaud, P., Cornu, P., Derost, P., Bougerol, T., Bataille, B., Mattei, V., Dormont, D., Devaux, B., Verin, M., Houeto, J.L., Pollak, P., Benabid, A.L., Agid, Y., Krack, P., Millet, B., Pelissolo, A., Group, S.S., 2008. Subthalamic nucleus stimulation in severe obsessive-compulsive disorder. *N Engl J Med* 359, 2121–2134.
- Mancini, M., Vos, S.B., Vakharia, V.N., O'Keefe, A.G., Trimmel, K., Barkhof, F., Dorfer, C., Soman, S., Winston, G.P., Wu, C., Duncan, J.S., Sparks, R., Ourselin, S., 2019. Automated fiber tract reconstruction for surgery planning: Extensive validation in language-related white matter tracts. *Neuroimage Clin* 23, 101883.
- Mannfolk, P., Nilsson, M., Hansson, H., Stahlberg, F., Fransson, P., Weibull, A., Svensson, J., Wirestam, R., Olsrud, J., 2011. Can resting-state functional MRI serve as a

- complement to task-based mapping of sensorimotor function? A test-retest reliability study in healthy volunteers. *J Magn Reson Imaging* 34, 511–517.
- Mansouri, A.M., Germann, J., Boutet, A., Elias, G.J.B., Mithani, K., Chow, C.T., Karmur, B., Ibrahim, G.M., McAndrews, M.P., Lozano, A.M., Zadeh, G., Valiante, T.A., 2020. Identification of neural networks preferentially engaged by epileptogenic mass lesions through lesion network mapping analysis. *Sci Rep* 10, 10989.
- Marrelec, G., Fransson, P., 2011. Assessing the influence of different ROI selection strategies on functional connectivity analyses of fMRI data acquired during steady-state conditions. *PLoS One* 6, e14788.
- Martino, J., Honma, S.M., Findlay, A.M., Guggisberg, A.G., Owen, J.P., Kirsch, H.E., Berger, M.S., Nagarajan, S.S., 2011. Resting functional connectivity in patients with brain tumors in eloquent areas. *Ann Neurol* 69, 521–532.
- Martucci, K.T., Ng, P., Mackey, S., 2014. Neuroimaging chronic pain: what have we learned and where are we going? *Future Neurol* 9, 615–626.
- Marx, M., Pauly, K.B., Chang, C., 2013. A novel approach for global noise reduction in resting-state fMRI: APPECOR. *Neuroimage* 64, 19–31.
- Matias, C.M., Alizadeh, M., Muller, J., Sharan, A., Wu, C., 2019. Tractography-based targeting of the ventral intermediate nucleus for asleep DBS implantation. 18th Meeting of the World Society for Stereotactic and Functional Neurosurgery. New York, NY.
- Matsumoto, R., Nair, D.R., LaPresto, E., Bingham, W., Shibasaki, H., Luders, H.O., 2007. Functional connectivity in human cortical motor system: a cortico-cortical evoked potential study. *Brain* 130, 181–197.
- May, A., Bahra, A., Buchel, C., Frackowiak, R.S., Goadsby, P.J., 1998. Hypothalamic activation in cluster headache attacks. *Lancet* 352, 275–278.
- Mayberg, H.S., Lozano, A.M., Voon, V., McNeely, H.E., Seminowicz, D., Hamani, C., Schwab, J.M., Kennedy, S.H., 2005. Deep brain stimulation for treatment-resistant depression. *Neuron* 45, 651–660.
- McCormick, C., Quraan, M., Cohn, M., Valiante, T.A., McAndrews, M.P., 2013. Default mode network connectivity indicates episodic memory capacity in mesial temporal lobe epilepsy. *Epilepsia* 54, 809–818.
- McIntosh, A.R., Gonzalez-Lima, F., 1994. Structural equation modeling and its application to network analysis in functional brain imaging. *Hum Brain Mapp* 2, 2–22.
- McIntyre, C.C., Hahn, P.J., 2010. Network perspectives on the mechanisms of deep brain stimulation. *Neurobiol Dis* 38, 329–337.
- Middlebrooks, E.H., Domingo, R.A., Vivas-Buitrago, T., Okromelidze, L., Tsuboi, T., Wong, J.K., Eisinger, R.S., Almeida, L., Burns, M.R., Horn, A., Uitti, R.J., Wharen Jr., R.E., Holanda, V.M., Grewal, S.S., 2020. Neuroimaging Advances in Deep Brain Stimulation: Review of Indications, Anatomy, and Brain Connectomics. *AJNR Am J Neuroradiol* 41, 1558–1568.
- Middlebrooks, E.H., Holanda, V.M., Tuna, I.S., Deshpande, H.D., Bredel, M., Almeida, L., Walker, H.C., Guthrie, B.L., Foote, K.D., Okun, M.S., 2018. A method for pre-operative single-subject thalamic segmentation based on probabilistic tractography for essential tremor deep brain stimulation. *Neuroradiology* 60, 303–309.
- Miocinovic, S., de Hemptinne, C., Chen, W., Isbaire, F., Willie, J.T., Ostrem, J.L., Starr, P.A., 2018. Cortical Potentials Evoked by Subthalamic Stimulation Demonstrate a Short Latency Hyperdirect Pathway in Humans. *J Neurosci* 38, 9129–9141.
- Mirzaalilian, H., Ning, L., Savadjiev, P., Pasternak, O., Bouix, S., Michailovich, O., Grant, G., Marx, C.E., Morey, R.A., Flashman, L.A., George, M.S., McAllister, T.W., Andaluz, N., Shutter, L., Coimbra, R., Zafonte, R.D., Coleman, M.J., Kubicki, M., Westin, C.F., Stein, M.B., Shenton, M.E., Rathi, Y., 2016. Inter-site and inter-scanner diffusion MRI data harmonization. *Neuroimage* 135, 311–323.
- Mitchell, T.J., Hacker, C.D., Breshears, J.D., Szrama, N.P., Sharma, M., Bundy, D.T., Pahwa, M., Corbetta, M., Snyder, A.Z., Shimony, J.S., Leuthardt, E.C., 2013. A novel data-driven approach to preoperative mapping of functional cortex using resting-state functional magnetic resonance imaging. *Neurosurgery* 73, 969–982 discussion 982–963.
- Mitchell, T.J., Seitzman, B.A., Ballard, N., Petersen, S.E., Shimony, J.S., Leuthardt, E.C., 2020. Human Brain Functional Network Organization Is Disrupted After Whole-Brain Radiation Therapy. *Brain Connect* 10, 29–38.
- Mithani, K., Boutet, A., Germann, J., Elias, G.J.B., Weil, A.G., Shah, A., Guillen, M., Bernal, B., Achua, J.K., Ragheb, J., Donner, E., Lozano, A.M., Widjaja, E., Ibrahim, G.M., 2019. Lesion Network Localization of Seizure Freedom following MR-guided Laser Interstitial Thermal Ablation. *Scientific reports* 9, 18598.
- Monje, M.L., Mizumatsu, S., Fike, J.R., Palmer, T.D., 2002. Irradiation induces neural precursor-cell dysfunction. *Nat Med* 8, 955–962.
- Morrison, M.A., Lee, A.T., Martin, A.J., Dietiker, C., Brown, E.G., Wang, D.D., 2021. DBS targeting for essential tremor using intersectional dentato-rubro-thalamic tractography and direct proton density visualization of the VIM: technical note on 2 cases. *J Neurosurg* 1–9.
- Mosley, P.E., Paliwal, S., Robinson, K., Coyne, T., Silburn, P., Tittgemeyer, M., Stephan, K.E., Breakspear, M., Perry, A., 2019. The structural connectivity of discrete networks underlies impulsivity and gambling in Parkinson's disease. *Brain* 142, 3917–3935.
- Mosley, P.E., Paliwal, S., Robinson, K., Coyne, T., Silburn, P., Tittgemeyer, M., Stephan, K.E., Perry, A., Breakspear, M., 2020. The structural connectivity of subthalamic deep brain stimulation correlates with impulsivity in Parkinson's disease. *Brain* 143, 2235–2254.
- Mosley, P.E., Smith, D., Coyne, T., Silburn, P., Breakspear, M., Perry, A., 2018. The site of stimulation moderates neuropsychiatric symptoms after subthalamic deep brain stimulation for Parkinson's disease. *Neuroimage Clin* 18, 996–1006.
- Mueller, B.A., Lim, K.O., Hemmy, L., Camchong, J., 2015. Diffusion MRI and its Role in Neuropsychology. *Neuropsychol Rev* 25, 250–271.
- Murata, J., Kitagawa, M., Uesugi, H., Saito, H., Iwasaki, Y., Kikuchi, S., Tashiro, K., Sawamura, Y., 2003. Electrical stimulation of the posterior subthalamic area for the treatment of intractable proximal tremor. *J Neurosurg* 99, 708–715.
- Murphy, K., Birn, R.M., Bandettini, P.A., 2013. Resting-state fMRI confounds and cleanup. *Neuroimage* 80, 349–359.
- UCSD Image-Guided Cognitive-Sparing Radiosurgery for Brain Metastases. <https://clinicaltrials.gov/ct2/show/NCT04343157>. 2019. (accessed 12 April 2021).
- Neal, E.G., Maciver, S., Schoenberg, M.R., Vale, F.L., 2020. Surgical disconnection of epilepsy network correlates with improved outcomes. *Seizure* 76, 56–63.
- Neher, P.F., Götz, M., Norajitra, T., Weber, C., Maier-Hein, K.H., 2015. A Machine Learning Based Approach to Fiber Tractography Using Classifier Voting. *Lecture Notes in Computer Science*. Springer International Publishing, pp. 45–52.
- Nielson, D.M., Pereira, F., Zheng, C.Y., Migineishvili, N., Lee, J.A., Thomas, A.G., Bandettini, P.A., 2018. Detecting and harmonizing scanner differences in the ABCD study - annual release 1.0. Cold Spring Harbor Laboratory.
- Nimsky, C., Bauer, M., Carl, B., 2016. Merits and Limits of Tractography Techniques for the Uninitiated. *Adv Tech Stand Neurosurg* 37–60.
- Noble, S., Scheinost, D., Finn, E.S., Shen, X., Papademetris, X., McEwen, S.C., Barden, C.E., Addingon, J., Goodyear, B., Cadenhead, K.S., Mirzakhani, H., Cornblatt, B.A., Olvet, D.M., Mathalon, D.H., McGlashan, T.H., Perkins, D.O., Belger, A., Seidman, L.J., Thermenos, H., Tsuang, M.T., van Erp, T.G.M., Walker, E.F., Hamann, S., Woods, S.W., Cannon, T.D., Constable, R.T., 2017. Multisite reliability of MR-based functional connectivity. *Neuroimage* 146, 959–970.
- Norton, I., Essayed, W., Zhang, F., Pujol, S., Yarmarkovich, A., Golby, A.J., Kindlmann, G., Wassermann, D., Estepar, R.S.J., Rathi, Y., Pieper, S., Kikinis, R., Johnson, H.J., Westin, C.F., O'Donnell, L.J., 2017. SlicerDMRI: Open Source Diffusion MRI Software for Brain Cancer Research. *Cancer Res* 77, e101–e103.
- O'Donnell, L.J., Suter, Y., Rigolo, L., Kahali, P., Zhang, F., Norton, I., Albi, A., Olubi, O., Meola, A., Essayed, W.I., Unadkat, P., Ciris, P.A., Wells 3rd, W.M., Rathi, Y., Westin, C.F., Golby, A.J., 2017. Automated white matter fiber tract identification in patients with brain tumors. *Neuroimage Clin* 13, 138–153.
- Oswal, A., Beudel, M., Zrinzo, L., Limousin, P., Hariz, M., Foltynie, T., Litvak, V., Brown, P., 2016. Deep brain stimulation modulates synchrony within spatially and spectrally distinct resting state networks in Parkinson's disease. *Brain* 139, 1482–1496.
- Oswal, A., Brown, P., Litvak, V., 2013. Synchronized neural oscillations and the pathophysiology of Parkinson's disease. *Curr Opin Neurol* 26, 662–670.
- Oswal, A., Gratwicke, J., Akram, H., Jahanshahi, M., Zaborszky, L., Brown, P., Hariz, M., Zrinzo, L., Foltynie, T., Litvak, V., 2020a. Cortical connectivity of the nucleus basalis of Meynert in Parkinson's disease and Lewy body dementias. *Brain*.
- Oswal, A., Yeh, C.-H., Neumann, W.-J., Gratwicke, J., Akram, H., Horn, A., Zrinzo, L., Foltynie, T., Limousin, P., Bogacz, R., Husain, M., Brown, P., Litvak, V., 2020b. Neural signatures of pathological hyperdirect pathway activity in Parkinson's disease. *Cold Spring Harbor Laboratory*.
- Owen, S.L., Green, A.L., Davies, P., Stein, J.F., Aziz, T.Z., Behrens, T., Voets, N.L., Johansen-Berg, H., 2007. Connectivity of an effective hypothalamic surgical target for cluster headache. *J Clin Neurosci* 14, 955–960.
- Padmanabhan, J.L., Cooke, D., Joutsa, J., Siddiqi, S.H., Ferguson, M., Darby, R.R., Sounsand, L., Horn, A., Kim, N.Y., Voss, J.L., Naidich, A.M., Brodtmann, A., Egorova, N., Gozzi, S., Phan, T.G., Corbetta, M., Grafman, J., Fox, M.D., 2019. A Human Depression Circuit Derived From Focal Brain Lesions. *Biol Psychiatry* 86, 749–758.
- Parker, C.S., Clayden, J.D., Cardoso, M.J., Rodionov, R., Duncan, J.S., Scott, C., Diehl, B., Ourselin, S., 2018. Structural and effective connectivity in focal epilepsy. *Neuroimage Clin* 17, 943–952.
- Parker, D., Ould Ismail, A.A., Wolf, R., Brem, S., Alexander, S., Hodges, W., Pasternak, O., Caruyer, E., Verma, R., 2020. Freewater estimator using iNTERpolated iTrialization (FERNET): Characterizing peritumoral edema using clinically feasible diffusion MRI data. *PLoS One* 15, e0233645.
- Parker, D., Rotival, G., Laine, A., Razlighi, Q.R., 2014. Retrospective Detection of Interleaved Slice Acquisition Parameters from Fmri Data. *Proc IEEE Int Symp Biomed Imaging* 2014 37–40.
- Parker Jones, O., Voets, N.L., Adcock, J.E., Stacey, R., Jbabdi, S., 2017. Resting connectivity predicts task activation in pre-surgical populations. *Neuroimage Clin* 13, 378–385.
- Patriat, R., Cooper, S.E., Duchin, Y., Niederer, J., Lenglet, C., Aman, J., Park, M.C., Vitek, J.L., Harel, N., 2018. Individualized tractography-based parcellation of the globus pallidus pars interna using 7T MRI in movement disorder patients prior to DBS surgery. *Neuroimage* 178, 198–209.
- Peiffer, A.M., Shi, L., Olson, J., Bruno-Bechtold, J.K., 2010. Differential effects of radiation and age on diffusion tensor imaging in rats. *Brain Res* 1351, 23–31.
- Penfield, W., 1972. The electrode, the brain and the mind. *Zeitschrift für Neurologie* 201, 297–309.
- Philippi, C.L., Bruss, J., Boes, A.D., Albazon, F.M., Deifelt Streese, C., Ciaramelli, E., Rudrauf, D., Tranel, D., 2021. Lesion network mapping demonstrates that mind-wandering is associated with the default mode network. *J Neurosci Res* 99, 361–373.
- Piper, R.J., Yoong, M.M., Kandasamy, J., Chin, R.F., 2014. Application of diffusion tensor imaging and tractography of the optic radiation in anterior temporal lobe resection for epilepsy: a systematic review. *Clin Neurol Neurosurg* 124, 59–65.
- Plaha, P., Khan, S., Gill, S.S., 2008. Bilateral stimulation of the caudal zona incerta nucleus for tremor control. *J Neurol Neurosurg Psychiatry* 79, 504–513.
- Plantinga, B.R., Temel, Y., Duchin, Y., Uludag, K., Patriat, R., Roebroek, A., Kuijff, M., Jahanshahi, A., Ter Haar Romenij, B., Vitek, J., Harel, N., 2018. Individualized parcellation of the subthalamic nucleus in patients with Parkinson's disease with 7T MRI. *Neuroimage* 168, 403–411.
- Polanski, W.H., Zolal, A., Klein, J., Kitzler, H.H., Schackert, G., Eisner, W., Sobottka, S.B., 2019. Somatosensory functional MRI tractography for individualized targeting of deep brain stimulation in patients with chronic pain after brachial plexus injury. *Acta Neurochir (Wien)* 161, 2485–2490.
- Poulin, P., Cote, M.A., Houde, J.C., Petit, L., Neher, P.F., Maier-Hein, K.H., Larochelle, H., Descoteaux, M., 2017. Learn to Track: Deep Learning for Tractography. *bioRxiv*.



- Poulin, P., Jorgens, D., Jodoin, P.M., Descoteaux, M., 2019. Tractography and machine learning: Current state and open challenges. *Magn Reson Imaging* 64, 37–48.
- Pouratian, N., Zheng, Z., Bari, A.A., Behnke, E., Elias, W.J., Desalles, A.A., 2011. Multi-institutional evaluation of deep brain stimulation targeting using probabilistic connectivity-based thalamic segmentation. *J Neurosurg* 115, 995–1004.
- Power, J.D., Barnes, K.A., Snyder, A.Z., Schlaggar, B.L., Petersen, S.E., 2012. Spurious but systematic correlations in functional connectivity MRI networks arise from subject motion. *Neuroimage* 59, 2142–2154.
- Pujol, S., Wells, W., Pierpaoli, C., Brun, C., Gee, J., Cheng, G., Vemuri, B., Commowick, O., Prima, S., Stamm, A., Goubran, M., Khan, A., Peters, T., Neher, P., Maier-Hein, K.H., Shi, Y., Tristan-Vega, A., Veni, G., Whitaker, R., Styner, M., Westin, C.F., Gouttard, S., Norton, I., Chauvin, L., Mamata, H., Gerig, G., Nabavi, A., Golby, A., Kikinis, R., 2015. The DTI Challenge: Toward Standardized Evaluation of Diffusion Tensor Imaging Tractography for Neurosurgery. *J Neuroimaging* 25, 875–882.
- Qiu, T.M., Gong, F.Y., Gong, X., Wu, J.S., Lin, C.P., Biswal, B.B., Zhuang, D.X., Yao, C.J., Zhang, X.L., Lu, J.F., Zhu, F.P., Mao, Y., Zhou, L.F., 2017. Real-Time Motor Cortex Mapping for the Safe Resection of Glioma: An Intraoperative Resting-State fMRI Study. *AJNR Am J Neuroradiol* 38, 2146–2152.
- Qiu, T.M., Yan, C.G., Tang, W.J., Wu, J.S., Zhuang, D.X., Yao, C.J., Lu, J.F., Zhu, F.P., Mao, Y., Zhou, L.F., 2014. Localizing hand motor area using resting-state fMRI: validated with direct cortical stimulation. *Acta Neurochir (Wien)* 156, 2295–2302.
- Rabin, M.L., Narayan, V.M., Kimberg, D.Y., Casasanto, D.J., Glosser, G., Tracy, J.I., French, J.A., Sperling, M.R., Detre, J.A., 2004. Functional MRI predicts post-surgical memory following temporal lobectomy. *Brain* 127, 2286–2298.
- Raethjen, J., Deuschl, G., 2012. The oscillating central network of Essential tremor. *Clin Neurophysiol* 123, 61–64.
- Reber, P.J., Wong, E.C., Buxton, R.B., Frank, L.R., 1998. Correction of off resonance-related distortion in echo-planar imaging using EPI-based field maps. *Magn Reson Med* 39, 328–330.
- Reich, M.M., Brumberg, J., Pozzi, N.G., Marotta, G., Roothans, J., Astrom, M., Musacchio, T., Lopiano, L., Lanotte, M., Lehrke, R., Buck, A.K., Volkman, J., Isaias, I.U., 2016. Progressive gait ataxia following deep brain stimulation for essential tremor: adverse effect or lack of efficacy? *Brain* 139, 2948–2956.
- Riva-Posse, P., Choi, K.S., Holtzheimer, P.E., Crowell, A.L., Garlow, S.J., Rajendra, J.K., McIntyre, C.C., Gross, R.E., Mayberg, H.S., 2018. A connectomic approach for subcallosal cingulate deep brain stimulation surgery: prospective targeting in treatment-resistant depression. *Mol Psychiatry* 23, 843–849.
- Riva-Posse, P., Crowell, A.L., Wright, K., Waters, A.C., Choi, K., Garlow, S.J., Holtzheimer, P.E., Gross, R.E., Mayberg, H.S., 2020. Rapid Antidepressant Effects of Deep Brain Stimulation and Their Relation to Surgical Protocol. *Biol Psychiatry* 88, e37–e39.
- Rodrigues, N.B., Mithani, K., Meng, Y., Lipsman, N., Hamani, C., 2018. The Emerging Role of Tractography in Deep Brain Stimulation: Basic Principles and Current Applications. *Brain Sci* 8.
- Rolston, J.D., Englot, D.J., Starr, P.A., Larson, P.S., 2016. An unexpectedly high rate of revisions and removals in deep brain stimulation surgery: Analysis of multiple databases. *Parkinsonism Relat Disord* 33, 72–77.
- Romano, A., D'Andrea, G., Minniti, G., Mastronardi, L., Ferrante, L., Fantozzi, L.M., Bozza, A., 2009. Pre-surgical planning and MR-tractography utility in brain tumour resection. *Eur Radiol* 19, 2798–2808.
- Rorden, C., Karnath, H.-O., 2004. Using human brain lesions to infer function: a relic from a past era in the fMRI age? *Nature Reviews Neuroscience* 5, 813–819.
- Rosazza, C., Aquino, D., D'Incerti, L., Cordella, R., Andronache, A., Zaca, D., Bruzzone, M.G., Tringali, G., Minati, L., 2014. Preoperative mapping of the sensorimotor cortex: comparative assessment of task-based and resting-state fMRI. *PLoS One* 9, e98860.
- Rubinov, M., Sporns, O., 2010. Complex network measures of brain connectivity: uses and interpretations. *Neuroimage* 52, 1059–1069.
- S, K., M, F., D, M., 2017. Reconstruction of Diffusion Anisotropies using 3D Deep Convolutional Neural Networks in Diffusion Imaging. In: Schultz, T., Ozarslan, E., Hotz, I. (Eds.), *Modeling, Analysis, and Visualization of Anisotropy*. Springer International Publishing, pp. 393–404.
- Saad, Z.S., Reynolds, R.C., Jo, H.J., Gotts, S.J., Chen, G., Martin, A., Cox, R.W., 2013. Correcting brain-wide correlation differences in resting-state fMRI. *Brain Connect* 3, 339–352.
- Salvalaggio, A., De Filippo De Grazia, M., Zorzi, M., Thiebaut de Schotten, M., Corbetta, M., 2020. Post-stroke deficit prediction from lesion and indirect structural and functional disconnection. *Brain: a journal of neurology*.
- Sammartino, F., Krishna, V., King, N.K., Lozano, A.M., Schwartz, M.L., Huang, Y., Hodaie, M., 2016. Tractography-Based Ventral Intermediate Nucleus Targeting: Novel Methodology and Intraoperative Validation. *Mov Disord* 31, 1217–1225.
- Schaltenbrand, G., Wahren, W., Hassler, R., 1977. *Atlas for Stereotaxy of the Human Brain*. Thieme Medical Publishers.
- Schlaepfer, T.E., Bewernick, B.H., Kayser, S., Madler, B., Coenen, V.A., 2013. Rapid effects of deep brain stimulation for treatment-resistant major depression. *Biol Psychiatry* 73, 1204–1212.
- Schrock, L.E., Patriat, R., Gofitari, M., Kim, J., Johnson, M.D., Harel, N., Vitek, J.L., 2021. 7T MRI and Computational Modeling Supports a Critical Role of Lead Location in Determining Outcomes for Deep Brain Stimulation: A Case Report. *Front Hum Neurosci* 15, 631778.
- Seijo-Fernandez, F., Saiz, A., Santamarta, E., Nader, L., Alvarez-Vega, M.A., Lozano, B., Seijo, E., Barcia, J.A., 2018. Long-Term Results of Deep Brain Stimulation of the Mammillothalamic Fasciculus in Chronic Cluster Headache. *Stereotact Funct Neurosurg* 96, 215–222.
- Shah, P., Ashourvan, A., Mikhail, F., Pines, A., Kini, L., Oechsel, K., Das, S.R., Stein, J.M., Shinohara, R.T., Bassett, D.S., Litt, B., Davis, K.A., 2019. Characterizing the role of the structural connectome in seizure dynamics. *Brain* 142, 1955–1972.
- Shamir, R.R., Duchin, Y., Kim, J., Patriat, R., Marmor, O., Bergman, H., Vitek, J.L., Sapiro, G., Bick, A., Eliahou, R., Eitan, R., Israel, Z., Harel, N., 2019. Microelectrode Recordings Validate the Clinical Visualization of Subthalamic-Nucleus Based on 7T Magnetic Resonance Imaging and Machine Learning for Deep Brain Stimulation Surgery. *Neurosurgery* 84, 749–757.
- Sheth, S.A., Neal, J., Tangherlini, F., Mian, M.K., Gentil, A., Cosgrove, G.R., Eskandar, E.N., Dougherty, D.D., 2013. Limbic system surgery for treatment-refractory obsessive-compulsive disorder: a prospective long-term follow-up of 64 patients. *J Neurosurg* 118, 491–497.
- Shi, Y., Toga, A.W., 2017. Connectome imaging for mapping human brain pathways. *Mol Psychiatry* 22, 1230–1240.
- Sidhu, M.K., Stretton, J., Winston, G.P., Symms, M., Thompson, P.J., Koeppe, M.J., Duncan, J.S., 2015. Memory fMRI predicts verbal memory decline after anterior temporal lobe resection. *Neurology* 84, 1512–1519.
- Silva, M.A., See, A.P., Essayed, W.I., Golby, A.J., Tie, Y., 2018. Challenges and techniques for presurgical brain mapping with functional MRI. *Neuroimage Clin* 17, 794–803.
- Sinha, N., Wang, Y., Moreira da Silva, N., Miserocchi, A., McEvoy, A.W., de Tisi, J., Vos, S.B., Winston, G.P., Duncan, J.S., Taylor, P.N., 2021. Structural Brain Network Abnormalities and the Probability of Seizure Recurrence After Epilepsy Surgery. *Neurology* 96, e758–e771.
- Sladky, R., Baldinger, P., Kranz, G.S., Trostl, J., Hoflich, A., Lanzenberger, R., Moser, E., Windischberger, C., 2013. High-resolution functional MRI of the human amygdala at 7 T. *Eur J Radiol* 82, 728–733.
- Sladky, R., Friston, K.J., Trostl, J., Cunnington, R., Moser, E., Windischberger, C., 2011. Slice-timing effects and their correction in functional MRI. *Neuroimage* 58, 588–594.
- Soares, J.M., Magalhaes, R., Moreira, P.S., Sousa, A., Ganz, E., Sampaio, A., Alves, V., Marques, P., Sousa, N., 2016. A Hitchhiker's Guide to Functional Magnetic Resonance Imaging. *Front Neurosci* 10, 515.
- Sohn, W.S., Yoo, K., Lee, Y.B., Seo, S.W., Na, D.L., Jeong, Y., 2015. Influence of ROI selection on resting state functional connectivity: an individualized approach for resting state fMRI analysis. *Front Neurosci* 9, 280.
- Solomon, O., Palnitkar, T., Patriat, R., Braun, H., Aman, J., Park, M.C., Vitek, J., Sapiro, G., Harel, N., 2021. Deep-learning based fully automatic segmentation of the globus pallidus interna and externa using ultra-high 7 Tesla MRI. *Hum Brain Mapp*.
- Song, J., Deshpande, A.S., Meier, T.B., Tudorascu, D.L., Vergun, S., Nair, V.A., Biswal, B.B., Meyerand, M.E., Birn, R.M., Bellec, P., Prabhakaran, V., 2012. Age-related differences in test-retest reliability in resting-state brain functional connectivity. *PLoS One* 7, e49847.
- Sotiropoulos, S.N., Jbabdi, S., Xu, J., Andersson, J.L., Moeller, S., Auerbach, E.J., Glasser, M.F., Hernandez, M., Sapiro, G., Jenkinson, M., Feinberg, D.A., Yacoub, E., Lenglet, C., Van Essen, D.C., Ugurbil, K., Behrens, T.E., Consortium, W.U.-M.H., 2013. Advances in diffusion MRI acquisition and processing in the Human Connectome Project. *Neuroimage* 80, 125–143.
- Sotiropoulos, S.N., Zalesky, A., 2019. Building connectomes using diffusion MRI: why, how and but. *NMR Biomed* 32, e3752.
- Sparacia, G., Parla, G., Lo Re, V., Cannella, R., Mamone, G., Carollo, V., Midiri, M., Grasso, G., 2020. Resting-State Functional Connectome in Patients with Brain Tumors Before and After Surgical Resection. *World Neurosurg* 141, e182–e194.
- Spiegel, E.A., Wycis, H.T., Marks, M., Lee, A.J., 1947. Stereotaxic Apparatus for Operations on the Human Brain. *Science* 106, 349–350.
- Spiers, H.J., Maguire, E.A., 2007. Decoding human brain activity during real-world experiences. *Trends Cogn Sci* 11, 356–365.
- Spisak, T., Kincses, B., Schlitt, F., Zunhammer, M., Schmidt-Wilcke, T., Kincses, Z.T., Bingel, U., 2020. Pain-free resting-state functional brain connectivity predicts individual pain sensitivity. *Nat Commun* 11, 187.
- Sporns, O., Bassett, D.S., 2018. Editorial: New Trends in Connectomics. *Netw Neurosci* 2, 125–127.
- Sporns, O., Tononi, G., Kotter, R., 2005. The human connectome: A structural description of the human brain. *PLoS Comput Biol* 1, e42.
- Starr, P., Little, S., 2021. A space-time continuum in DBS: structural and functional advances in Parkinson's disease. *Brain* 144, 357–359.
- Starr, P.A., Vitek, J.L., DeLong, M., Bakay, R.A., 1999. Magnetic resonance imaging-based stereotactic localization of the globus pallidus and subthalamic nucleus. *Neurosurgery* 44, 303–313 discussion 313–304.
- Steriade, M., Llinas, R.R., 1988. The functional states of the thalamus and the associated neuronal interplay. *Physiol Rev* 68, 649–742.
- Su, J., Khoo, H.M., von Ellenrieder, N., Zeng, L.L., Hu, D., Dubeau, F., Gotman, J., 2019. fMRI functional connectivity as an indicator of interictal epileptic discharges. *Neuroimage Clin* 24, 102038.
- Sutterer, M.J., Bruss, J., Boes, A.D., Voss, M.W., Bechara, A., Tranel, D., 2016. Canceled connections: Lesion-derived network mapping helps explain differences in performance on a complex decision-making task. *Cortex* 78, 31–43.
- Swann, N.C., Cai, W., Conner, C.R., Pieters, T.A., Claffey, M.P., George, J.S., Aron, A.R., Tandon, N., 2012. Roles for the pre-supplementary motor area and the right inferior frontal gyrus in stopping action: electrophysiological responses and functional and structural connectivity. *Neuroimage* 59, 2860–2870.
- Szafarski, J.P., Gloss, D., Binder, J.R., Gaillard, W.D., Golby, A.J., Holland, S.K., Ojemann, J., Spencer, D.C., Swanson, S.J., French, J.A., Theodore, W.H., 2017. Practice guideline summary: Use of fMRI in the presurgical evaluation of patients with epilepsy: Report of the Guideline Development, Dissemination, and Implementation Subcommittee of the American Academy of Neurology. *Neurology* 88, 395–402.
- Tarapore, P.E., Findlay, A.M., Honma, S.M., Mizuiri, D., Houde, J.F., Berger, M.S., Nagarajan, S.S., 2013. Language mapping with navigated repetitive TMS: proof of technique and validation. *Neuroimage* 82, 260–272.

- Tarapore, P.E., Martino, J., Guggisberg, A.G., Owen, J., Honma, S.M., Findlay, A., Berger, M.S., Kirsch, H.E., Nagarajan, S.S., 2012. Magnetoencephalographic imaging of resting-state functional connectivity predicts postsurgical neurological outcome in brain gliomas. *Neurosurgery* 71, 1012–1022.
- Tax, C.M., Grussu, F., Kaden, E., Ning, L., Rudrapatna, U., John Evans, C., St-Jean, S., Lee-mans, A., Koppers, S., Merhof, D., Ghosh, A., Tanno, R., Alexander, D.C., Zappala, S., Charron, C., Kusmia, S., Linden, D.E., Jones, D.K., Veraart, J., 2019. Cross-scanner and cross-protocol diffusion MRI data harmonisation: A benchmark database and evaluation of algorithms. *Neuroimage* 195, 285–299.
- Tian, Q., Wintermark, M., Jeffrey Elias, W., Ghanouni, P., Halpern, C.H., Henderson, J.M., Huss, D.S., Goubran, M., Thaler, C., Airan, R., Zeineh, M., Pauly, K.B., McNab, J.A., 2018. Diffusion MRI tractography for improved transcranial MRI-guided focused ultrasound thalamotomy targeting for essential tremor. *Neuroimage Clin* 19, 572–580.
- Tibbs, M.D., Huynh-Le, M.P., Karunamuni, R., Reyes, A., Macari, A.C., Tringale, K.R., Salans, M., Yip, A., Liu, E., Simon, A., McDonald, C.R., Hattangadi-Gluth, J.A., 2020. Microstructural Injury to Left-Sided Perisylvian White Matter Predicts Language Decline After Brain Radiation Therapy. *Int J Radiat Oncol Biol Phys*.
- Tie, Y., Rigolo, L., Norton, I.H., Huang, R.Y., Wu, W., Orringer, D., Mukundan Jr, S., Golby, A.J., 2014. Defining language networks from resting-state fMRI for surgical planning—a feasibility study. *Hum Brain Mapp* 35, 1018–1030.
- Tie, Y., Rigolo, L., Ozdemir Ovalioglu, A., Olubiyyi, O., Doolin, K.L., Mukundan Jr, S., Golby, A.J., 2015. A New Paradigm for Individual Subject Language Mapping: Movie-Watching fMRI. *J Neuroimaging* 25, 710–720.
- Tinkhauser, G., Pogoyan, A., Little, S., Beudel, M., Herz, D.M., Tan, H., Brown, P., 2017. The modulatory effect of adaptive deep brain stimulation on beta bursts in Parkinson's disease. *Brain* 140, 1053–1067.
- Toescu, S.M., Hales, P.W., Tisdall, M.M., Aquilina, K., Clark, C.A., 2020. Neurosurgical applications of tractography in the UK. *Br J Neurosurg* 1–6.
- Tracy, J.I., Waldron, B., Glosser, D., Sharan, A., Mintzer, S., Zangaladze, A., Skidmore, C., Siddiqui, I., Caris, E., Sperling, M.R., 2009. Hemispheric lateralization and language skill coherence in temporal lobe epilepsy. *Cortex* 45, 1178–1189.
- Traynor, C.R., Barker, G.J., Crum, W.R., Williams, S.C., Richardson, M.P., 2011. Segmentation of the thalamus in MRI based on T1 and T2. *Neuroimage* 56, 939–950.
- Tringale, K.R., Nguyen, T., Bahrami, N., Marshall, D.C., Leyden, K.M., Karunamuni, R., Seibert, T.M., Kay Gorman, M., Connor, M., Burkeen, J., Piccinio, D.E., Farid, N., Hattangadi-Gluth, J.A., McDonald, C.R., 2019a. Identifying early diffusion imaging biomarkers of regional white matter injury as indicators of executive function decline following brain radiotherapy: A prospective clinical trial in primary brain tumor patients. *Radiother Oncol* 132, 27–33.
- Tringale, K.R., Nguyen, T.T., Karunamuni, R., Seibert, T., Huynh-Le, M.P., Connor, M., Moiseenko, V., Gorman, M.K., Marshall, A., Tibbs, M.D., Farid, N., Simpson, D., Sanghvi, P., McDonald, C.R., Hattangadi-Gluth, J.A., 2019b. Quantitative Imaging Biomarkers of Damage to Critical Memory Regions Are Associated With Post-Radiation Therapy Memory Performance in Brain Tumor Patients. *Int J Radiat Oncol Biol Phys* 105, 773–783.
- Tsolaki, E., Espinoza, R., Pouratian, N., 2017. Using probabilistic tractography to target the subcallosal cingulate cortex in patients with treatment resistant depression. *Psychiatry Res Neuroimaging* 261, 72–74.
- Tunc, B., Ingallhalikar, M., Parker, D., Lecoeur, J., Singh, N., Wolf, R.L., Macyszyn, L., Brem, S., Verma, R., 2016. Individualized Map of White Matter Pathways: Connectivity-Based Paradigm for Neurosurgical Planning. *Neurosurgery* 79, 568–577.
- Turkdogan, D., Duchowny, M., Resnick, T., Jayakar, P., 2005. Subdural EEG patterns in children with taylor-type cortical dysplasia: comparison with nondysplastic lesions. *J Clin Neurophysiol* 22, 37–42.
- Tyagi, H., Apergis-Schoute, A.M., Akram, H., Foltynie, T., Limousin, P., Drummond, L.M., Fineberg, N.A., Matthews, K., Jahanshahi, M., Robbins, T.W., Sahakian, B.J., Zrinzo, L., Hariz, M., Joyce, E.M., 2019. A Randomized Trial Directly Comparing Ventral Capsule and Anteromedial Subthalamic Nucleus Stimulation in Obsessive-Compulsive Disorder: Clinical and Imaging Evidence for Dissociable Effects. *Biol Psychiatry* 85, 726–734.
- Vakamudi, K., Posse, S., Jung, R., Cushman, B., Chohan, M.O., 2020. Real-time presurgical resting-state fMRI in patients with brain tumors: Quality control and comparison with task-fMRI and intraoperative mapping. *Hum Brain Mapp* 41, 797–814.
- Vakharia, V.N., Duncan, J.S., Witt, J.A., Elger, C.E., Staba, R., Engel Jr, J., 2018. Getting the best outcomes from epilepsy surgery. *Ann Neurol* 83, 676–690.
- Vakharia, V.N., Sparks, R.E., Vos, S.B., Bezchlibnyk, Y., Mehta, A.D., Willie, J.T., Wu, C., Sharan, A., Ourselin, S., Duncan, J.S., 2020. Computer-assisted planning for minimally invasive anterior two-thirds laser corpus callosotomy: A feasibility study with probabilistic tractography validation. *Neuroimage Clin* 25, 102174.
- Valsky, D., Marmor-Levin, O., Deffains, M., Eitan, R., Blackwell, K.T., Bergman, H., Israel, Z., 2017. Stop! border ahead: Automatic detection of subthalamic exit during deep brain stimulation surgery. *Mov Disord* 32, 70–79.
- Van Dijk, K.R., Hedden, T., Venkataraman, A., Evans, K.C., Lazar, S.W., Buckner, R.L., 2010. Intrinsic functional connectivity as a tool for human connectomics: theory, properties, and optimization. *J Neurophysiol* 103, 297–321.
- Van Dijk, K.R., Sabuncu, M.R., Buckner, R.L., 2012. The influence of head motion on intrinsic functional connectivity MRI. *Neuroimage* 59, 431–438.
- van Dokkum, L.E.H., Moritz Gasser, S., Deverduin, J., Herbet, G., Mura, T., D'Agata, B., Picot, M.C., Menot de Champfleury, N., Duffau, H., Molino, F., le Bars, E., 2019. Resting state network plasticity related to picture naming in low-grade glioma patients before and after resection. *Neuroimage Clin* 24, 102010.
- van Houdt, P.J., Ossenblok, P.P., Colon, A.J., Hermans, K.H., Verdaasdonk, R.M., Boon, P.A., de Munck, J.C., 2015. Are Epilepsy-Related fMRI Components Dependent on the Presence of Interictal Epileptic Discharges in Scalp EEG? *Brain Topogr* 28, 606–618.
- Vanderwal, T., Eilbott, J., Castellanos, F.X., 2019. Movies in the magnet: Naturalistic paradigms in developmental functional neuroimaging. *Dev Cogn Neurosci* 36, 100600.
- Vassal, F., Coste, J., Derost, P., Mendes, V., Gabrillargues, J., Nuti, C., Durif, F., Lemaire, J.J., 2012. Direct stereotactic targeting of the ventrointermediate nucleus of the thalamus based on anatomic 1.5-T MRI mapping with a white matter attenuated inversion recovery (WAIR) sequence. *Brain Stimul* 5, 625–633.
- Wang, D., Buckner, R.L., Fox, M.D., Holt, D.J., Holmes, A.J., Stoercklein, S., Langa, G., Pan, R., Qian, T., Li, K., Baker, J.T., Stufflebeam, S.M., Wang, K., Wang, X., Hong, B., Liu, H., 2015a. Parcellating cortical functional networks in individuals. *Nature Neurosci* 18, 1853–1860.
- Wang, D.D., de Hemptinne, C., Miocinovic, S., Ostrem, J.L., Galifianakis, N.B., San Luciano, M., Starr, P.A., 2018. Pallidal Deep-Brain Stimulation Disrupts Pallidal Beta Oscillations and Coherence with Primary Motor Cortex in Parkinson's Disease. *J Neurosci* 38, 4556–4568.
- Wang, J., Han, J., Nguyen, V.T., Guo, L., Guo, C.C., 2017. Improving the Test-Retest Reliability of Resting State fMRI by Removing the Impact of Sleep. *Front Neurosci* 11, 249.
- Wang, M., Ma, H., Wang, X., Guo, Y., Xia, X., Xia, H., Guo, Y., Huang, X., He, H., Jia, X., Xie, Y., 2015b. Integration of BOLD-fMRI and DTI into radiation treatment planning for high-grade gliomas located near the primary motor cortex and corticospinal tracts. *Radiat Oncol* 10, 64.
- Wang, Q., Akram, H., Muthuraman, M., Gonzalez-Escamilla, G., Sheth, S.A., Oxenford, S., Yeh, F.C., Groppa, S., Vanegas-Arroyave, N., Zrinzo, L., Li, N., Kuhn, A., Horn, A., 2021. Normative vs. patient-specific brain connectivity in deep brain stimulation. *Neuroimage* 224, 117307.
- Wang, S., Wu, E.X., Qiu, D., Leung, L.H., Lau, H.F., Khong, P.L., 2009. Longitudinal diffusion tensor magnetic resonance imaging study of radiation-induced white matter damage in a rat model. *Cancer Res* 69, 1190–1198.
- Wardle, S.G., Baker, C., 2020. Recent advances in understanding object recognition in the human brain: deep neural networks, temporal dynamics, and context. *F1000Res* 9.
- Wasserthal, J., Neher, P.F., Maier-Hein, K.H., 2018. Tract orientation mapping for bundle-specific tractography.
- Wawrzyniak, M., Klingbeil, J., Zeller, D., Saur, D., Classen, J., 2018. The neuronal network involved in self-attribution of an artificial hand: A lesion network-symptom-mapping study. *Neuroimage* 166, 317–324.
- Wegmayr, V., Giuliani, G., Holdener, S., Buhmann, J., 2018. Data-driven fiber tractography with neural networks. In: 2018 IEEE 15th International Symposium on Biomedical Imaging (ISBI 2018), Washington DC, USA, pp. 1030–1033.
- Winston, G.P., Daga, P., White, M.J., Micallef, C., Misericchia, A., Mancini, L., Modat, M., Stretton, J., Sidhu, M.K., Symms, M.R., Lythgoe, D.J., Thornton, J., Yousry, T.A., Ourselin, S., Duncan, J.S., McEvoy, A.W., 2014. Preventing visual field deficits from neurosurgery. *Neurology* 83, 604–611.
- Wirisch, J., Perry, A., Ridley, B., Proix, T., Golos, M., Benar, C., Ranjeva, J.P., Bartolomei, F., Breakspear, M., Jirsa, V., Guye, M., 2016. Whole-brain analytic measures of network communication reveal increased structure-function correlation in right temporal lobe epilepsy. *Neuroimage Clin* 11, 707–718.
- Witjas, T., Carron, R., Krack, P., Eusebio, A., Vaugoyeau, M., Hariz, M., Azulay, J.P., Regis, J., 2015. A prospective single-blind study of Gamma Knife thalamotomy for tremor. *Neurology* 85, 1562–1568.
- Wodarg, F., Herzog, J., Reese, R., Falk, D., Pinsker, M.O., Steigerwald, F., Jansen, O., Deuschl, G., Mehdorn, H.M., Volkmann, J., 2012. Stimulation site within the MRI-defined STN predicts postoperative motor outcome. *Mov Disord* 27, 874–879.
- Wong, C.W., Olafsson, V., Tal, O., Liu, T.T., 2013. The amplitude of the resting-state fMRI global signal is related to EEG vigilance measures. *Neuroimage* 83, 983–990.
- Wu, J.S., Zhou, L.F., Tang, W.J., Mao, Y., Hu, J., Song, Y.Y., Hong, X.N., Du, G.H., 2007. Clinical evaluation and follow-up outcome of diffusion tensor imaging-based functional neuronavigation: a prospective, controlled study in patients with gliomas involving pyramidal tracts. *Neurosurgery* 61, 935–948 discussion 948–939.
- Wu, P.H., Coultrap, S., Pinnix, C., Davies, K.D., Taylor, R., Ang, K.K., Browning, M.D., Grosshans, D.R., 2012. Radiation induces acute alterations in neuronal function. *PLoS One* 7, e37677.
- Yamashita, A., Yahata, N., Itahashi, T., Lisi, G., Yamada, T., Ichikawa, N., Takamura, M., Yoshihara, Y., Kunitatsu, A., Okada, N., Yamagata, H., Matsuo, K., Hashimoto, R., Okada, G., Sakai, Y., Morimoto, J., Narumoto, J., Shimada, Y., Kasai, K., Kato, N., Takahashi, H., Okamoto, Y., Tanaka, S.C., Kawato, M., Yamashita, O., Imamizu, H., 2019. Harmonization of resting-state functional MRI data across multiple imaging sites via the separation of site differences into sampling bias and measurement bias. *PLoS Biol* 17, e3000042.
- Yao, S., Rigolo, L., Yang, F., Vangel, M.G., Wang, H., Golby, A.J., Liebenthal, E., Tie, Y., 2021. Movie-watching fMRI for presurgical language mapping in patients with brain tumour. *J Neurol Neurosurg Psychiatry*.
- Yoo, P.E., John, S.E., Farquharson, S., Cleary, J.O., Wong, Y.T., Ng, A., Mulcha, C.B., Grayden, D.B., Orndidge, R.J., Opie, N.L., O'Brien, T.J., Oxley, T.J., Moffat, B.A., 2018. 7T-fMRI: Faster temporal resolution yields optimal BOLD sensitivity for functional neuroimaging specifically at high spatial resolution. *Neuroimage* 164, 214–229.
- Yordanova, Y.N., Cochereau, J., Duffau, H., Herbet, G., 2019. Combining resting state functional MRI with intraoperative cortical stimulation to map the mentalizing network. *Neuroimage* 186, 628–636.
- Younce, J.R., Campbell, M.C., Hershey, T., Tanenbaum, A.B., Milchenko, M., Ushe, M., Karimi, M., Tabbal, S.D., Kim, A.E., Snyder, A.Z., Perlmutter, J.S., Norris, S.A., 2021. Resting-State Functional Connectivity Predicts STN DBS Clinical Response. *Mov Disord* 36, 662–671.
- Zaca, D., Jovicich, J., Corsini, F., Rozzanigo, U., Chioffi, F., Sarubbo, S., 2018. ReSt-NeuMap: a tool for automatic extraction of resting-state functional MRI networks in neurosurgical practice. *J Neurosurg* 131, 764–771.
- Zalesky, A., Fornito, A., Cocchi, L., Gollo, L.L., van den Heuvel, M.P., Breakspear, M.,

2016. Connectome sensitivity or specificity: which is more important? *Neuroimage* 142, 407–420.
- Zhang, D., Johnston, J.M., Fox, M.D., Leuthardt, E.C., Grubb, R.L., Chicoine, M.R., Smyth, M.D., Snyder, A.Z., Raichle, M.E., Shimony, J.S., 2009. Preoperative sensorimotor mapping in brain tumor patients using spontaneous fluctuations in neuronal activity imaged with functional magnetic resonance imaging: initial experience. *Neurosurgery* 65, 226–236.
- Zhang, F., Wu, Y., Norton, I., Rigolo, L., Rathi, Y., Makris, N., O'Donnell, L.J., 2018. An anatomically curated fiber clustering white matter atlas for consistent white matter tract parcellation across the lifespan. *Neuroimage* 179, 429–447.
- Zhang, Z., Liao, W., Chen, H., Mantini, D., Ding, J.R., Xu, Q., Wang, Z., Yuan, C., Chen, G., Jiao, Q., Lu, G., 2011. Altered functional-structural coupling of large-scale brain networks in idiopathic generalized epilepsy. *Brain* 134, 2912–2928.
- Zhu, T., Chapman, C.H., Tsien, C., Kim, M., Spratt, D.E., Lawrence, T.S., Cao, Y., 2016. Effect of the Maximum Dose on White Matter Fiber Bundles Using Longitudinal Diffusion Tensor Imaging. *Int J Radiat Oncol Biol Phys* 96, 696–705.
- Zrinzo, L., 2012. Pitfalls in precision stereotactic surgery. *Surg Neurol Int* 3, S53–S61.
- Zrinzo, L., Foltynie, T., Limousin, P., Hariz, M., 2013. Image-guided and image-verified deep brain stimulation. *Mov Disord* 28, 254.