

Resection of the piriform cortex for temporal lobe epilepsy: a Novel approach on imaging segmentation and surgical application

Jose E. Leon-Rojas, Sabahat Iqbal, Sjoerd B. Vos, Roman Rodionov, Anna Miserocchi, Andrew W McEvoy, Vejay N Vakharia, Laura Mancini, Marian Galovic, Rachel E Sparks, Sebastien Ourselin, Jorge M Cardoso, Matthias J Koeppe & John S Duncan

To cite this article: Jose E. Leon-Rojas, Sabahat Iqbal, Sjoerd B. Vos, Roman Rodionov, Anna Miserocchi, Andrew W McEvoy, Vejay N Vakharia, Laura Mancini, Marian Galovic, Rachel E Sparks, Sebastien Ourselin, Jorge M Cardoso, Matthias J Koeppe & John S Duncan (2021): Resection of the piriform cortex for temporal lobe epilepsy: a Novel approach on imaging segmentation and surgical application, British Journal of Neurosurgery, DOI: [10.1080/02688697.2021.1966385](https://doi.org/10.1080/02688697.2021.1966385)

To link to this article: <https://doi.org/10.1080/02688697.2021.1966385>



© 2021 The Author(s). Published by Informa UK Limited, trading as Taylor & Francis Group



Published online: 18 Aug 2021.



[Submit your article to this journal](#)



Article views: 233




[View related articles](#)



[View Crossmark data](#)

Resection of the piriform cortex for temporal lobe epilepsy: a Novel approach on imaging segmentation and surgical application

Jose E. Leon-Rojas^{a,b,c} , Sabahat Iqbal^{b,c}, Sjoerd B. Vos^{b,d,e}, Roman Rodionov^{b,c}, Anna Miserocchi^b, Andrew W McEvoy^b, Vejay N Vakharia^b, Laura Mancini^c, Marian Galovic^{b,c,f}, Rachel E Sparks^g, Sebastien Ourselin^g, Jorge M Cardoso^g, Matthias J Koeppe^{b,c,*} and John S Duncan^{b,c,*}

^aNeurALL Research Group, Medical School, Universidad Internacional del Ecuador, Quito, Ecuador; ^bUK National Institute for Health Research University College London Hospitals Biomedical Research Centre, and Department of Clinical and Experimental Epilepsy, UCL Queen Square Institute of Neurology, London, UK; ^cEpilepsy Society MRI Unit, Chalfont Centre for Epilepsy, Chalfont St Peter, UK; ^dCentre for Medical Image Computing (CMIC), Department of Computer Science, University College London, London, UK; ^eNeuroradiological Academic Unit, UCL Queen Square Institute of Neurology, London, UK; ^fDepartment of Neurology, Zurich University Hospital, Zurich, Switzerland; ^gSchool of Biomedical Engineering and Imaging Sciences, Kings College, St Thomas Hospital, London, UK

ABSTRACT

Background: The piriform cortex (PC) occupies both banks of the endorhinal sulcus and has an important role in the pathophysiology of temporal lobe epilepsy (TLE). A recent study showed that resection of more than 50% of PC increased the odds of becoming seizure free by a factor of 16.

Objective: We report the feasibility of manual segmentation of PC and application of the Geodesic Information Flows (GIF) algorithm to automated segmentation, to guide resection.

Methods: Manual segmentation of PC was performed by two blinded independent examiners in 60 patients with TLE (55% Left TLE, 52% female) with a median age of 35 years (IQR, 29–47 years) and 20 controls (60% Women) with a median age of 39.5 years (IQR, 31–49). The GIF algorithm was used to create an automated pipeline for parcellating PC which was used to guide excision as part of temporal lobe resection for TLE.

Results: Right PC was larger in patients and controls. Parcellation of PC was used to guide anterior temporal lobe resection, with subsequent seizure freedom and no visual field or language deficit.

Conclusion: Reliable segmentation of PC is feasible and can be applied prospectively to guide neurosurgical resection that increases the chances of a good outcome from temporal lobe resection for TLE.

ARTICLE HISTORY

Received 16 April 2021
Revised 9 July 2021
Accepted 5 August 2021

KEYWORDS

Epilepsy surgery; imaging; piriform cortex; segmentation; temporal lobe epilepsy

Introduction



The piriform cortex (PC) lies on the superior and inferior banks of the endorhinal sulcus (ES), at the boundary of the frontal and temporal lobes.^{1–3} The temporal stem borders its lateral aspect and its anterior limit is represented by the limen insulae. It extends superiorly over the mesial aspect of the amygdaloid nuclei anteriorly and the hippocampus posteriorly.^{2,4} (Figure 1) The human PC is very excitable to chemoconvulsants.⁵ An evaluation of individuals who had had anterior temporal lobe resection for medically refractory mesial temporal lobe epilepsy (TLE) found that removal of >50% of the PC was associated with a 16-fold increased chance of post-operative seizure remission.¹ The objective of this work is to report the feasibility of manual segmentation of the PC and the application of the Geodesic Information Flows (GIF) algorithm for automated segmentation, as well as its potential use in guiding resection for Drug-Resistant TLE patients in order to

achieve seizure freedom while reducing the surgical footprint on the brain.

Materials and methods

Subjects

We derived a PC segmentation that could be used surgically for guiding anterior temporal lobe resection. The cohort comprised 60 subjects with unilateral TLE (55% Left TLE, 52% female) and a median age of 35 years (IQR, 29–47 years), and 20 controls (60% female) with a median age of 39.5 years (IQR, 31–49) (Table 1). In controls, the mean volume of the right piriform cortex was 17.7% larger than the left, and the right piriform cortex extended a mean of 6 mm (Range: –4 to 12) more anteriorly than the left. This asymmetry was also seen in left and right TLE (Iqbal *et al.*, submitted)

CONTACT John S Duncan  j.duncan@ucl.ac.uk  UK National Institute for Health Research University College London Hospitals Biomedical Research Centre, and Department of Clinical and Experimental Epilepsy, UCL Queen Square Institute of Neurology, London WC1N3BG, UK

*These authors contributed equally to this article.

Parts of these papers were presented in abstract form at the ILAE UK Branch Virtual Conference and at the AES 2020 Annual Meeting.

© 2021 The Author(s). Published by Informa UK Limited, trading as Taylor & Francis Group

This is an Open Access article distributed under the terms of the Creative Commons Attribution License (<http://creativecommons.org/licenses/by/4.0/>), which permits unrestricted use, distribution, and reproduction in any medium, provided the original work is properly cited.

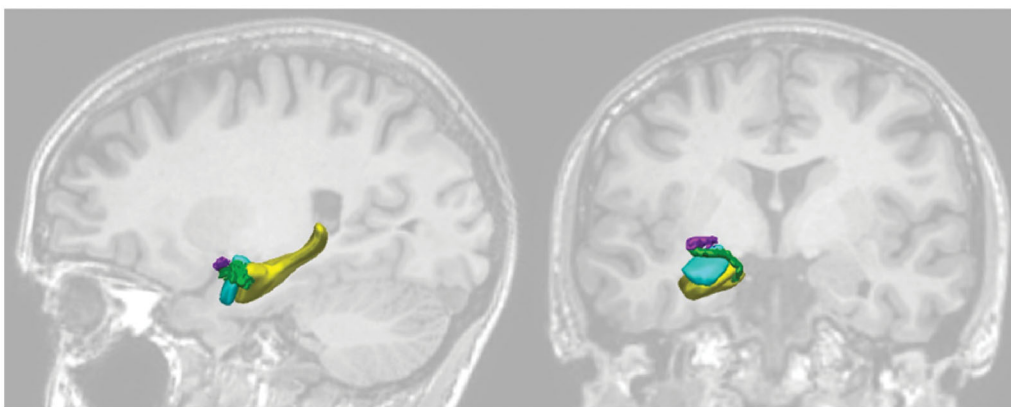


Figure 1. Three-Dimensional relationship of the right piriform cortex on the sagittal (right) and coronal (left) planes. The temporal portion of the piriform cortex (green) overlies the amygdala anteriorly (cyan) and hippocampus posteriorly (yellow). The endorhinal sulcus subdivides the piriform cortex into the temporal portion (green) and the frontal portion (purple).

Table 1. Demographic characteristics.

Control Group ($n = 20$)	
Variable	Value
Age, median (IQR), y	39.5 (31–49)
Sex, No. (%)	
Female	12 (60)
Male	8 (40)
TLE Group ($n = 60$)	
Age, median (IQR), y	35 (29–47)
Sex, No. (%)	
Female	31 (51.67)
Male	29 (48.33)
Side of TLE, No. (%)	
Left	33 (55)
Right	27 (45)
Duration of Epilepsy, median (IQR), y	19.5 (8–31)
Focal Seizure with impaired awareness Frequency per month, median (IQR)	8 (3–15)
No of AED Ever Taken, median (IQR)	5 (5–7)
No of AED Currently Taken, median (IQR)	2 (1–3)

IQR: Interquartile Range; NAED: Number of Antiepileptic Drugs; TLE: Temporal Lobe Epilepsy.

Image acquisition and processing

MR imaging was carried out on a 3T GE Discovery MR750 scanner with a 32-channel coil. Sequences included: (1) a three-dimensional (3D) T1-weighted inversion-recovery fast spoiled gradient recalled echo (TE/TR/TI 3.1/7.4/400 ms, field of view (FOV) $224 \times 256 \times 256$ mm, matrix $224 \times 256 \times 256$, SENSE factor 2. The T1-weighted scan was used for brain segmentation and parcellation using geodesic-information flow (GIF) as implemented in NiftySeg.⁶

Piriform cortex segmentation

ITK-SNAP (Version 3.8.0-beta; www.itksnap.org)⁷ was used by two independent blinded examiners (J.L.-R. and S.I). Segmentations were carried out on the coronal plane. A total of 160 segmentations (2 segmentations per patient and controls) were performed to measure inter-rater and repeated intra-rater variability. Manual segmentation was performed with a predefined protocol based on anatomical landmarks and histological correlation.^{1,4} The protocol involves a number of steps performed

in each 1-mm slice of the 3D-T1w MRI (Figure 2) (Iqbal *et al.*, submitted).

To delineate the frontal part of the PC, the medio-lateral extension is defined as 50% of the distance between an anterior-posterior line crossing the olfactory sulcus medially and the ES fundus laterally. The frontal part is more prominent on anterior slices and becomes progressively shorter when moving posteriorly. Thickness is defined by the gray-white matter interface superior to the upper bank of the ES and lateral to its fundus.

To determine the temporal part, on the first coronal slice the medio-lateral extension is defined as 30% of the distance between the ES and the peak of the gyrus semilunaris. This extension becomes larger when moving posteriorly. On the second, third and fourth slices, the medio-lateral extension is defined as 50%, 75% and 100% of this distance, respectively, and subsequently 100%. Supero-inferior extension, beginning at the fourth slice, is limited inferiorly by the temporal white matter extending superiorly towards the amygdala or until the sulcus semiannularis. Posteriorly, thickness is maintained at 2 mm, as there is no discernible boundary between PC and the rest of the amygdala. The most anterior slice is defined by the limen insulae the white matter connection between the frontal and temporal lobes. The most posterior slice is defined as the penultimate slice showing a complete connection of the cerebral peduncle between the pons and the diencephalon, and the interpeduncular cistern is clearly visible.

A total of 320 PC volumes were obtained from the manual segmentations and volumes were calculated using ITK-SNAP which outputs the volume of the mask created in mm^3 . The surgical boundary mask was determined as the temporal portion of the PC, to be removed during surgery while preserving the frontal component. The superior boundaries of the PC to be resected were defined by drawing a horizontal line from the fundus of the ES laterally resulting in a division of a superior portion (not to be resected) and an inferior portion (to be resected) (Figure 3). This limit was chosen because within the ES and on its superior bank, the middle cerebral artery gives off the lateral lenticulostriate arteries that pass through the anterior perforated substance to supply the internal capsule. It was noted that the right piriform cortex is a mean 18% larger than the left and extended a mean 6 mm more anteriorly in the frontal lobe (Iqbal *et al.*, submitted). Left and right segmentation masks were overlaid onto the previously performed segmentations, indicating the areas that would and would not be resected.

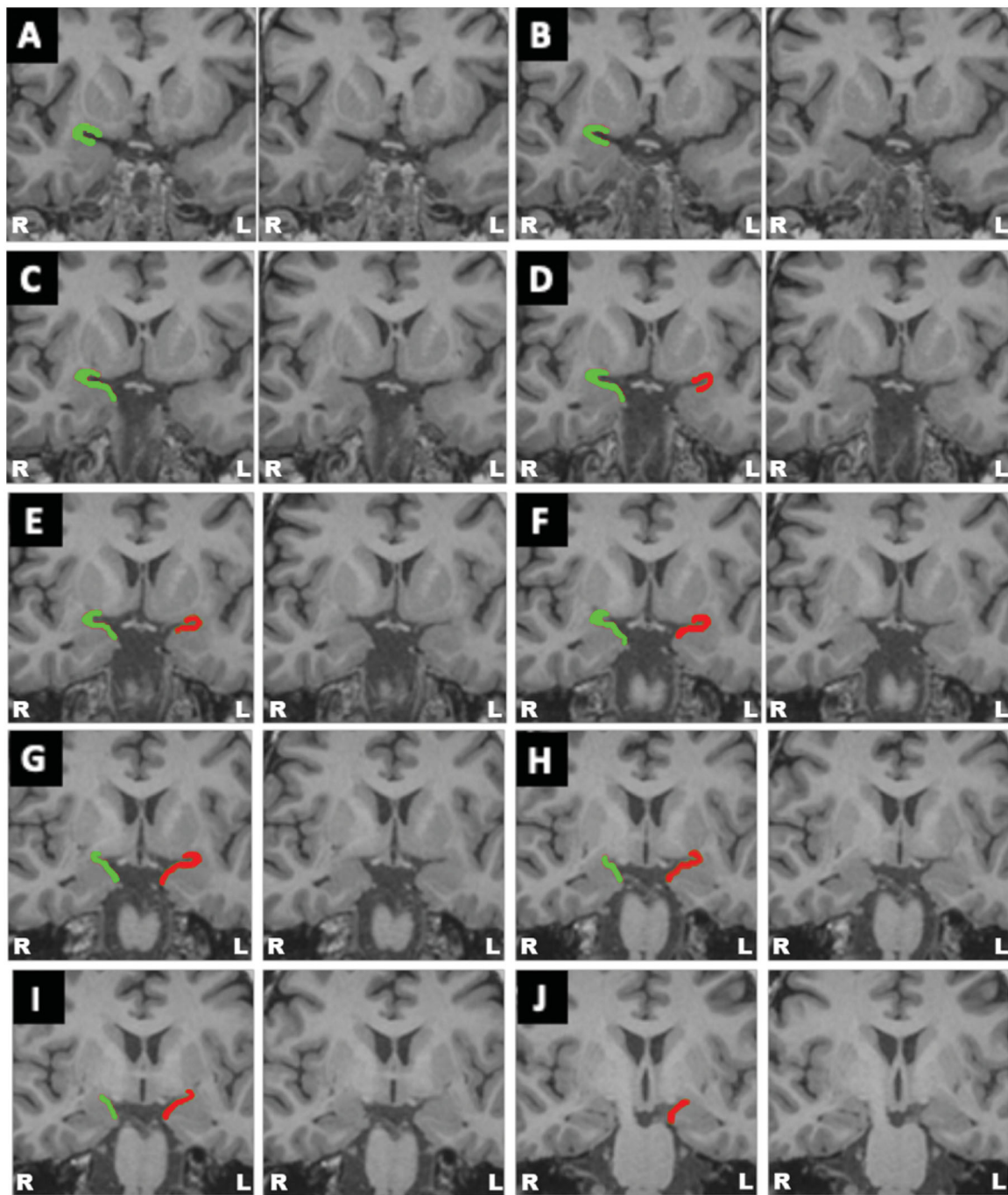


Figure 2. Manual Segmentation Steps: Labelled from A to J from anterior to posterior. On panels A, B, and C the asymmetry between left and right can be clearly seen, with the right limen insulae and right piriform cortex beginning more anteriorly. Additionally, note the progressive increase of the medio-lateral extension of the temporal part of the piriform cortex. Panel D shows the appearance of the left limen insulae and therefore the first slice for parcellation of the left piriform cortex. Note that from panels D–G, the left piriform cortex also has a progressive increase of its medio-lateral extension, while the right piriform cortex maintains its size. Finally, note the asymmetric end of the piriform cortex, the right ending in panel I while the Left ends in panel J because of the asymmetry of the cerebral peduncles (the right is anterior).

Template of piriform cortex to be removed

The GIF algorithm was used for automatic parcellation of the PC. By using geodesic propagation, this algorithm propagates and extrapolates manual labels into a new dataset of patients in order to facilitate the segmentation process and make it more accurate.⁶ GIF uses the principles of pairwise registration but rather than using the unseen image as one of the pairs it uses neighbouring image for registration, generating a restricted

neighbourhood propagation and reducing biases by taking into consideration both normal anatomical variability and pathological effects.⁶ The GIF algorithm was applied to 120 manual segmentations from 60 patients with TLE, to create a template for automatic piriform cortex segmentation that may be applied to individual patients scheduled for TLE surgery. Because of the asymmetry of PC, separate resection masks for left and right TLE surgery were created.

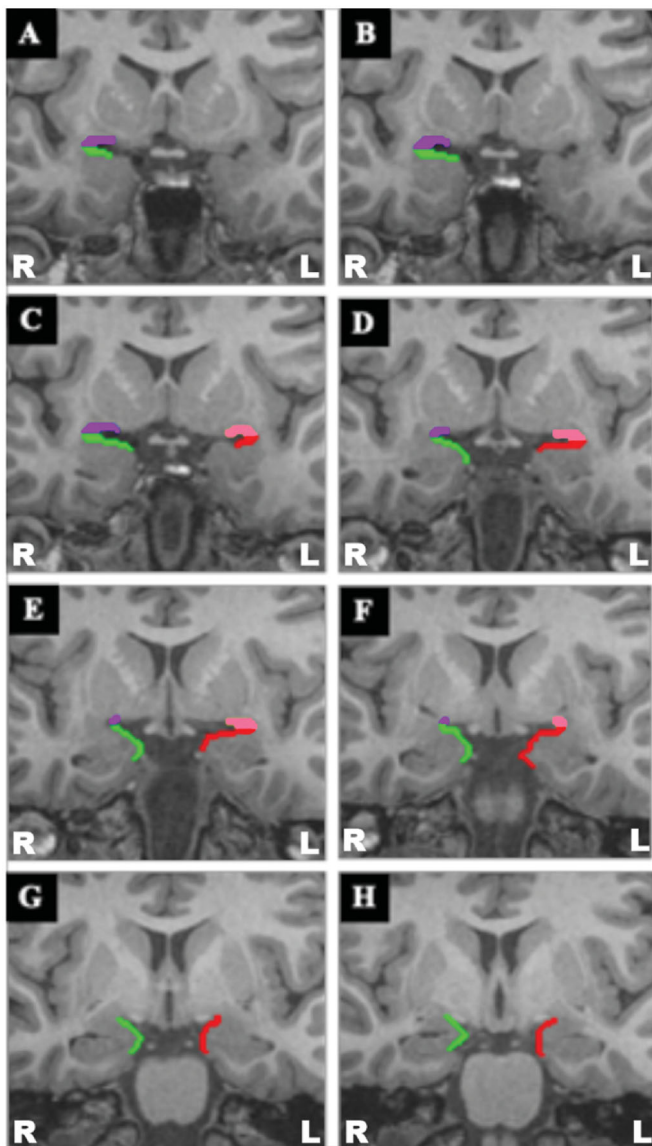


Figure 3. Surgical Resection Boundary Mask: In purple (right) and pink (left) note the surgical resection boundary mask, highlighting the frontal part of the piriform cortex that will not be resected. In comparison in green and red the temporal part, that would be surgically removed. In panels A and B the right piriform cortex begins more anteriorly than the Left. Panels C-H shows the posterior extension of the piriform cortex ending at the level of the interpeduncular cistern.

The binary masks of frontal lobe and temporal lobe parts of PC were rigid-body co-registered into the anatomical space of an MPRAGE T1 image. 3D models were created based on the binary masks to enable the review of spatial relationship between all relevant anatomical structures and individual brain anatomy in 3D space using EpiNav.⁸ The resulting images were uploaded to iPlan software (BrainLab AG, Munich, Germany) to enable segmentation of the relevant models for intra-operative use (Figure 4).

Results and case report

Case report

A 24 y/o mixed handed female had an encephalitic illness at age 6 years with a 45-minute generalized convulsion. The habitual epilepsy developed without an interval and was refractory to seven antiepileptic drugs. At the time of evaluation for surgery, seizures

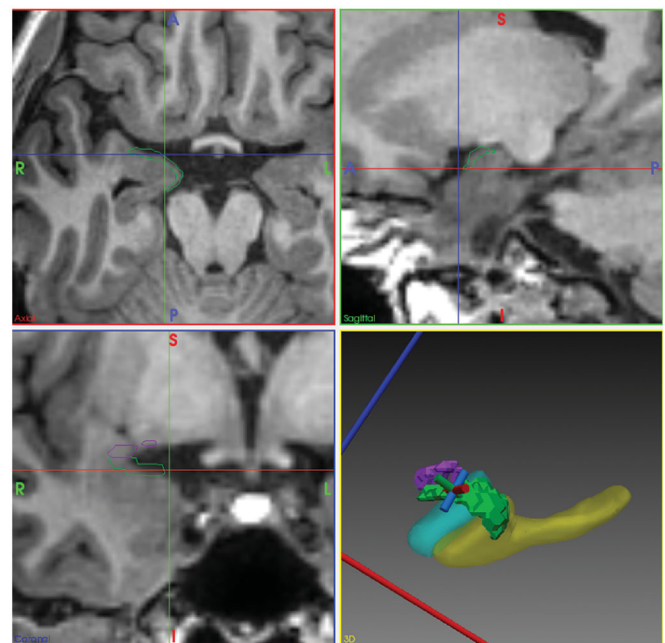


Figure 4. Visualisation of piriform cortex (PC) on the preoperative T1 MRI and in 3D (using EpiNavTM software): hippocampus (Yellow), amygdala (cyan), temporal part of piriform cortex (green); frontal part of piriform cortex (purple). Top left shows the PC on the axial plane, top right on the sagittal plane, bottom left on the coronal plane, and finally bottom right shows the 3D reconstruction.

comprised an epigastric rising sensation, nausea and anxiety followed by loss of awareness and an automotor seizure with post ictal dysphasia, 2–3 times a month. Secondly generalized seizures occurred less than once a year. Neurological examination was unremarkable. Scalp video-EEG telemetry showed right temporal interictal epileptic discharges and ictal onset. MRI showed right hippocampal sclerosis and mature right thalamic damage. Language fMRI (verbal fluency and verb generation) showed right hemispheric dominance. Neuropsychological examination showed no unequivocal lateralising or localising deficit. There were no psychiatric issues. The patient was offered a right anterior temporal lobe resection with a 50% chance of long-term seizure freedom. Written informed consent was given by the subject. Approval was also obtained from the Queen Square Research Ethics Committee 12/LO/0377 (Local Reference), CPMS 12050 (NIHR).

Resection method

The patient was anaesthetised and placed supine on the operative table within the iMRI suite. The head was turned to the left and right side up and fixed using the head-clamp (NORAS head coil) integrated into the iMRI table. The head coil was applied, and an MRI scan of the brain taken to allow neuronavigation. Registration was carried out by means of fiducials placed in the coil. A question mark skin incision was performed extending from the zygoma, anterior to the tragus, arching over the ipsilateral ear. At the posterior extent of the pinna, the incision was curved forward to extend above the Sylvian fissure frontally.

A fronto-temporal craniotomy was performed through the use of two burr holes, one in the temporal region above the root of the zygoma and the second, in the frontal region, above the greater wing of the sphenoid. The floor of the temporal fossa was exposed using a bone nibbler. Haemostasis was secured prior to opening of the dura in a cruciate fashion.

The temporal pole was resected en-bloc. A lateral neocortical incision was made between anterior and middle temporal

branches as they emerge from the Sylvian fissure, about 3 cm from the temporal pole. The superior temporal gyrus was stripped from the Sylvian fissure via subpial dissection. A subtemporal extension of the lateral neocortical incision was performed until the collateral sulcus was identified. The collateral sulcus was followed in order to enter the temporal horn of the lateral ventricle. The temporal pole and collateral sulcus incisions were then connected to remove the neocortex of the temporal pole.

Once the temporal pole was removed, the hippocampus and amygdala were identified. The head of the hippocampus was separated from the amygdala. The amygdala was removed with subpial dissection and with an ultrasonic surgical aspirator. Once the amygdala was debulked the remaining uncus was visualised and removed via subpial dissection, and the posterior communicating artery and oculomotor nerve were observed within the basal cisterns.

A single retractor was used to access and visualise the posterior temporal horn. The hippocampus was dissected free from its mesial attachment, the fimbria. Dissection through the fimbria exposed the hippocampal arcade overlying the mesial-most aspect of the parahippocampal gyrus. The dissection was then carried forward and the pes hippocampi, which forms the bulk of the posterior uncus was then divided along this plane. The remaining head, body and tail of the hippocampus were subsequently resected to the level of the tectum. After resection of the hippocampus, the remaining parahippocampal gyrus was removed using a subpial dissection technique and ultrasonic aspirator. The pes hippocampi were then removed to complete the resection of the uncus. The superior-most remnant of the amygdala was then resected and subpial dissection was performed along the inferior aspect of the endorhinal sulcus, using the 3D representation of the PC to aid resection. Care was taken not to breach the pia of the endorhinal sulcus so as not to damage the lateral lenticulostriate perforators. After macroscopic resection of the PC, an intraoperative MRI scan was performed prior to closure to confirm removal of the temporal portion of piriform cortex (Figure 5).

Histology showed hippocampal sclerosis with mossy fibre sprouting.

Follow-up Post-operative recovery was uncomplicated. Twelve months following surgery she was well, with no seizures or auras. Visual fields were full on Humphrey perimetry. MRI showed the right anterior temporal resection, including the temporal lobe portion of the piriform cortex, Neuropsychological assessment noted improved working memory, no naming deficits; verbal recall and learning were slightly less than pre-operatively.

Discussion and conclusion

The PC could be manually and reliably segmented. The GIF algorithm resulted in an accurate segmentation of the PC that could be used to guide temporal lobe resection and optimize the chance of a good outcome.

We developed a pipeline to segment the PC in individual patients using GIF, and to present this data to the operating surgeon through the operative microscope during resection in the intraoperative MRI (iMRI) suite. In a sample case, the intraoperative MRI showed that the intended resection was completed, and the frontal portion of the piriform cortex was not compromised, with an excellent result.

Having established this proof of principle, a prospective series is needed to verify the utility of this method and to identify any shortcomings. As per the recommendations of the IDEAL (Idea, Development, Exploration, Assessment and Long-term study) collaboration, surgical innovations should be introduced following a step-wise framework.⁹ Our previous retrospective study showed that resection of >50% of the PC was associated with increased chance of seizure freedom following anteromesial temporal resections, providing first-in-man outcome data satisfying Stage 1 of the framework. It is unclear whether resection of PC may increase risk of visual field deficit or post-operative language dysfunction by injuring the visual pathways or inferior fronto-

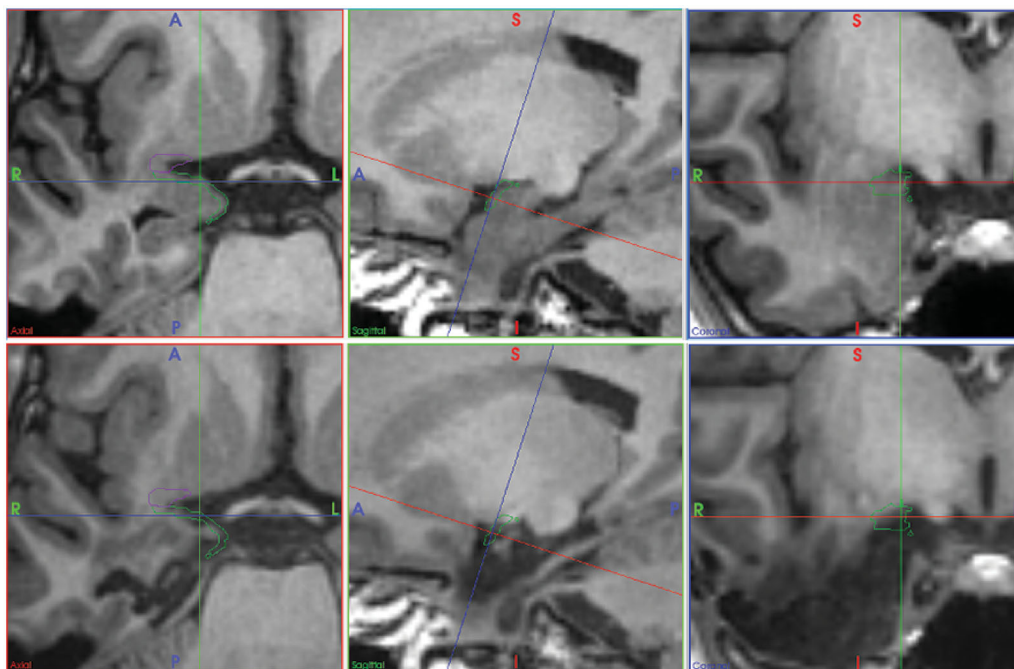


Figure 5. Segmentation of piriform cortex on pre- (top row) and post- (bottom row) resection T1 MRI. From left to right, the axial, sagittal and coronal planes are shown. The post-resection T1 MRI was acquired intraoperatively and nonlinearly co-registered to pre-operative T1 image using SPM toolbox (FIL, UCL, UK). Nonlinear registration was employed to take into account the intraoperative brain shift on an MR image following craniotomy. The right frontal piriform is shown in purple and right temporal piriform cortex shown in green. The postoperative image shows removal of the temporal portion of the piriform cortex.

occipital fasciculus, respectively. To prevent potential harm to study participants, we suggest using the cumulative summation (CUSUM) analysis to monitor seizure-free outcome rates and morbidity, compared to a recent historical cohort, to identify early whether resection of the PC is associated with an increased risk of morbidity.

Ethical approval

All procedures performed in studies involving human participants were in accordance with the ethical standards of the institutional and/or national research committee and with the 1964 Helsinki declaration and its later amendments or comparable ethical standards.

Informed consent

Informed consent was obtained from all individual participants included in the study.

Disclosure statement

No potential conflict of interest was reported by the author(s).

Funding

Research funding support from National Institute for Health Research Biomedical Research Centre: JSD, AM, AWM; Wellcome Trust (Grant no WT 218380): JSD, SO, AWM, AM.

ORCID

Jose E. Leon-Rojas  <http://orcid.org/0000-0002-8130-6460>

References

1. Koeppe MJ, Galovic M, Baudracco I, *et al.* Association of piriform cortex resection with surgical outcomes in patients with temporal lobe epilepsy. *JAMA Neurol* 2019;76:690–700.
2. Vaughan DN, Jackson GD. The piriform cortex and human focal epilepsy. *Front Neurol* 2014;5:259.
3. Young JC, Vaughan DN, Nasser HM, Jackson GD. Anatomical imaging of the piriform cortex in epilepsy. *Exp Neurol* 2019;320:113013.
4. Pereira PMG, Insausti R, Artacho-Pérula E, Salmenperä T, Kälviäinen R, Pitkänen A. MR volumetric analysis of the piriform cortex and cortical amygdala in drug-refractory temporal lobe epilepsy. *Am J Neuroradiol* 2005;26:319–32.
5. Gale K. Progression and generalization of seizure discharge: anatomical and neurochemical substrates. *Epilepsia* 1988;29:S15–S34.
6. Cardoso MJ, Modat M, Wolz R, *et al.* Geodesic information flows: spatially-variant graphs and their application to segmentation and fusion. *IEEE Trans Med Imaging* 2015;34:1976–88.
7. Yushkevich PA, Piven J, Hazlett HC, *et al.* User-guided 3D active contour segmentation of anatomical structures: significantly improved efficiency and reliability. *NeuroImage* 2006;31:1116–28.
8. Nowell M, Rodionov R, Zombori G, *et al.* A pipeline for 3D multimodality image integration and computer-assisted planning in epilepsy surgery. *J Vis Exp* 2016;(111):53450.
9. McCulloch P, Cook JA, Altman DG, Heneghan C, Diener MK. IDEAL framework for surgical innovation 1: the idea and development stages. *BMJ* 2013;346:f3012.