



Performance of image guided navigation in laparoscopic liver surgery – A systematic review

C. Schneider^{a,*}, M. Allam^{a,b}, D. Stoyanov^{c,d}, D.J. Hawkes^{d,e}, K. Gurusamy^a, B.R. Davidson^a

^a Department of Surgical Biotechnology, University College London, Pond Street, NW3 2QG, London, UK

^b General surgery Department, Tanta University, Egypt

^c Department of Computer Science, University College London, London, UK

^d Centre for Medical Image Computing (CMIC), University College London, London, UK

^e Wellcome / EPSRC Centre for Surgical and Interventional Sciences (WEISS), University College London, London, UK

ARTICLE INFO

Keywords:

Laparoscopic liver surgery
Laparoscopic liver resection
Robotic liver surgery
Image guided surgery
Computer assisted surgery
Computer assisted navigation
Augmented reality
Machine vision

ABSTRACT

Background: Compared to open surgery, minimally invasive liver resection has improved short term outcomes. It is however technically more challenging. Navigated image guidance systems (IGS) are being developed to overcome these challenges. The aim of this systematic review is to provide an overview of their current capabilities and limitations.

Methods: Medline, Embase and Cochrane databases were searched using free text terms and corresponding controlled vocabulary. Titles and abstracts of retrieved articles were screened for inclusion criteria. Due to the heterogeneity of the retrieved data it was not possible to conduct a meta-analysis. Therefore results are presented in tabulated and narrative format.

Results: Out of 2015 articles, 17 pre-clinical and 33 clinical papers met inclusion criteria. Data from 24 articles that reported on accuracy indicates that in recent years navigation accuracy has been in the range of 8–15 mm. Due to discrepancies in evaluation methods it is difficult to compare accuracy metrics between different systems. Surgeon feedback suggests that current state of the art IGS may be useful as a supplementary navigation tool, especially in small liver lesions that are difficult to locate. They are however not able to reliably localise all relevant anatomical structures. Only one article investigated IGS impact on clinical outcomes.

Conclusions: Further improvements in navigation accuracy are needed to enable reliable visualisation of tumour margins with the precision required for oncological resections. To enhance comparability between different IGS it is crucial to find a consensus on the assessment of navigation accuracy as a minimum reporting standard.

1. Introduction

Laparoscopic liver resection (LLR) has benefits over open resection in terms of improved patient recovery, better cosmesis, shorter length of hospital stay and reduced morbidity [1–5]. Unfortunately complex LLR such as major hepatectomies and segmental resections in superior-posterior segments are technically challenging and have therefore seen a slow uptake by the surgical community [1,3,6].

A number of factors make LLR technically more challenging than open resection. The inability to palpate the liver parenchyma makes it difficult to detect small liver lesions which has caused concerns about oncological clearance. Because of the liver's complex three-dimensional (3D) structure that is derived from its vascular anatomy, it can be challenging to find and maintain the correct anatomical orientation

within two-dimensional (2D) laparoscopic view which does not provide depth perception. Poor orientation may lead to incomplete oncological resection and inadvertent vascular or biliary injury [3,7–10].

Laparoscopic ultrasound (LUS) may be used prior to parenchymal transection to identify liver lesions and delineate the hepatic vasculature [11–15]. Once transection has started, however, use of LUS is demanding because it only provides 2D images which are difficult to interpret in conjunction with the orientation of the laparoscopic camera. An additional limitation of LUS is that its diagnostic accuracy is decreased in the presence of liver cirrhosis, small- or vanishing liver lesions [8,16–19].

Robotic assisted liver resection has been introduced to overcome the innate limitations of laparoscopic instruments. Surgical dexterity is improved by utilisation of *endo*-wristed instruments with 7° of freedom whereas routine use of stereoscopic laparoscopy enhances depth

* Corresponding author.

E-mail address: crispin.schneider.13@ucl.ac.uk (C. Schneider).

<https://doi.org/10.1016/j.suronc.2021.101637>

Received 12 April 2021; Received in revised form 4 July 2021; Accepted 24 July 2021

Available online 27 July 2021

0960-7404/© 2021 The Authors. Published by Elsevier Ltd. This is an open access article under the CC BY license (<http://creativecommons.org/licenses/by/4.0/>).

Abbreviations

AR	augmented reality
CBCT	Cone beam computer tomography
CNN	convolutional neural network
CRLM	colorectal liver metastasis
CT	Computer tomography
FPS	frames per second
IGS	Image guidance system
LLR	Laparoscopic liver resection
LUS	Laparoscopic ultrasound
MRI	Magnetic resonance imaging
SLAM	Simultaneous localisation and mapping
SSR	stereoscopic surface reconstruction
TRE	Target registration error
US	Ultrasound

perception [20]. Similar to LLR however, it is not possible to palpate the liver and intraoperative interpretation of the 3D anatomical situation is taxing.

To address these issues image guidance navigation systems (IGS) that enable intraoperative visualisation of the liver anatomy are being developed. IGS aim to display anatomical data, spatially correlated to the operative site, often in the form of 3D models that are created from cross-sectional imaging. Use of IGS in LLR is particularly appealing because the display of the highly variable vascular and tumour anatomy may aid in identifying tumour margins as well as blood vessels and bile ducts [21,22]. Although IGS are currently widely used in neurosurgery, orthopaedic surgery and otolaryngology, its evolution in LLR has been slow [23]. The main obstacles preventing meaningful implementation of this technology are the mobility of abdominal organs, lack of fixed bony landmarks for orientation and organ motion secondary to diaphragmatic and cardiac movement [8,23,24]. Further issues are the paucity of liver surface features and significant soft tissue deformation due to the increased intra-abdominal pressure from the pneumoperitoneum and surgical manipulation [24].

Because of the complexity of the technical challenges a number of IGS technologies have been developed. These can be broadly categorised according to the underlying imaging modality into video, ultrasound, computer tomography (CT) and magnetic resonance imaging (MRI)-based systems. The aim of this systematic review is to provide a comprehensive overview of the potential benefits and limitations of IGS in minimally invasive liver surgery.

2. Methods

A systematic literature search that included the free text and corresponding controlled vocabulary terms for “liver” and “laparoscopy” combined with those for computer vision terms (e.g. machine vision, augmented reality), or “image guided surgery” was performed using the Medline, Embase and Cochrane databases. A detailed description of the search strategy is stated in Appendix 1. To complement the initial search, each Medline search term indexed under “Diagnostic Techniques and Procedures” was screened for relevant image guidance modalities and included as a separate search term if appropriate.

Full text articles, conference -proceedings and -abstracts describing *in-vivo* pre-clinical studies or clinical research on image guidance systems in minimally invasive liver -resection or -ablation were retrieved. No backward time restriction was applied to the search and articles published up to the December 31, 2020 were included.

Exclusion criteria were image guidance for radiotherapy purposes, ex-vivo research, non-registered image guidance (e.g. preoperative planning) or non-primary research. No articles were excluded based on

language. Articles reporting on imaging in open liver resection or laparoscopic cholecystectomy were also excluded. To ensure mid-term clinical relevance, this review focuses exclusively on *in vivo* studies. Systems that do not provide navigation (i.e. lack spatial correlation) are not reviewed. Screening of the titles and abstracts of retrieved references was independently carried out by two authors (CS & MA). In case of disagreement a discussion took place and if the disagreement persisted, the final decision about inclusion was made by the senior author (BD).

Full texts for eligible articles were retrieved and read. A narrative summary of the findings is given in table and prose form. Where possible, system performance is quantified with objective data such as navigation accuracy and setup time. As the methodology used in the studies varied significantly no quantitative analysis or meta-analysis could be conducted.

2.1. General aspects of image guidance in laparoscopic surgery

Most IGS are based on three key components or processes which are: 1) 3D modelling - to create a virtual representation of patient anatomy 2) registration and tracking - to align “virtual” and real anatomy and 3) Visualisation - to make the information interpretable. 3D modelling is facilitated by processing volumetric data from CT or MRI scans. For LUS, CT and MRI -IGS, 3D models are not mandatory since these modalities have the capability to directly visualise liver anatomy during surgery.

Registration is the technically most challenging step and is thought to have the greatest impact on navigation accuracy (i.e. how precisely imaging reflects anatomy). To facilitate registration it is necessary to obtain biometrical features of the patients liver that can be aligned with corresponding features on the 3D model. These features may consist of only a few anatomical landmarks [17] or conversely they may incorporate a detailed geometrical liver surface representation [8]. In its most simple form registration can be carried out manually where the surgeon aligns 3D model and laparoscopic view [25–29]. Some groups advocate outlining the liver landmarks with a tracked stylus. Subsequent registration is achieved by computing the minimum distance between *in vivo* and virtual landmarks [8,30]. Laser range scanning may offer an alternative method for obtaining biometrical liver data [31].

More recently, semi-automatic registration methods have been popularised. Most commonly a technique called stereoscopic surface reconstruction (SSR) that requires a 3D laparoscope also known as a stereoscope is employed. The right and left video channels of the stereoscope triangulate points on the liver surface (Fig. 1) which are

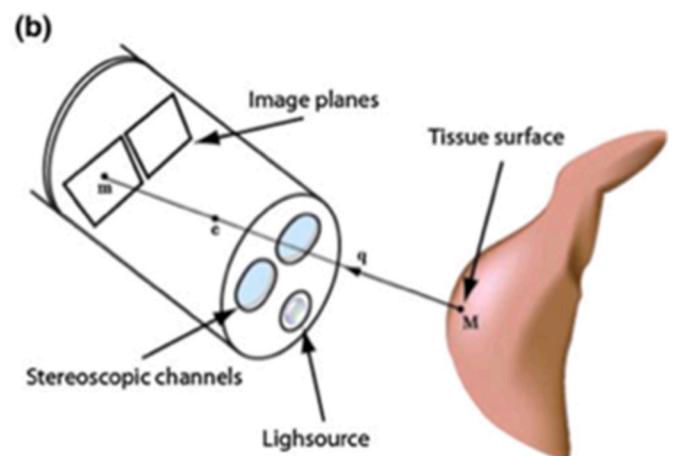


Fig. 1. Graphic illustrating the concept of SSR. On the left is a 3D laparoscopic camera with a right and left video channel pointing towards the liver surface on the right. Viewing the same point through two different spatially fixed video channels allows calculation of the point-to-camera distance. Reprinted with permission from Springer Nature [32].

subsequently amalgamated into a point cloud that is essentially a 3D points representation of the liver surface. Thereafter a process called ICP matching is used to align 3D model and point cloud to complete registration [32].

Tracking provides positional information which enables spatial correlation between laparoscope, patient anatomy and surgical instruments. Optical tracking is the most common method which employs reflective infrared markers that are attached to instruments [8,33,34]. The position of these markers is recorded by an optical tracking camera that requires a direct line of sight. This limitation can be avoided by using electromagnetic (EM) tracking which utilises phase changes within an EM field to determine positional changes. Calibration is the process that informs the fixed spatial relationship between tracking markers and camera optics. Novel concepts such as iterative closest point (ICP)- and simultaneous localisation and mapping (SLAM)-tracking are further detailed below.

Earlier systems utilised separate screens to show laparoscopic view and 3D model next to each other. More recently augmented reality (AR) displays have been increasingly employed. The advantage of AR is that patient anatomy and 3D model are visualised on the same screen in an overlay fashion (Fig. 2). AR is thought to render image interpretation more intuitive and an additional advantage is that surgical instruments do not require tracking because they are directly observed within the AR environment.

Navigation accuracy is often expressed as target registration error (TRE) which measures how accurately image guidance reflects the anatomical situation. As a simplification it can be regarded as the sum of registration- and tracking-error, with the former being the main contributor to the overall error. Because TRE evaluation is not standardised, care has to be taken when comparing different IGS [8,24,25]. In general TRE is calculated by measuring the distance between corresponding landmarks on the 3D model and the patients anatomy.

3. Results

The initial search identified 2015 articles (Fig. 3). Following screening of titles and abstracts, 1953 articles were excluded. After review of full texts a further 12 articles were excluded, because they either did not involve *in vivo* studies ($n = 4$), studied only cholecystectomy ($n = 1$), did not include navigation ($n = 3$) or were only based on open surgery ($n = 4$). Eventually 50 eligible articles, 17 based on preclinical and 33 based on clinical research were eligible for inclusion. Pre-clinical research was exclusively conducted on pigs. Information on methodology, number of test subjects, key findings and limitations were retrieved

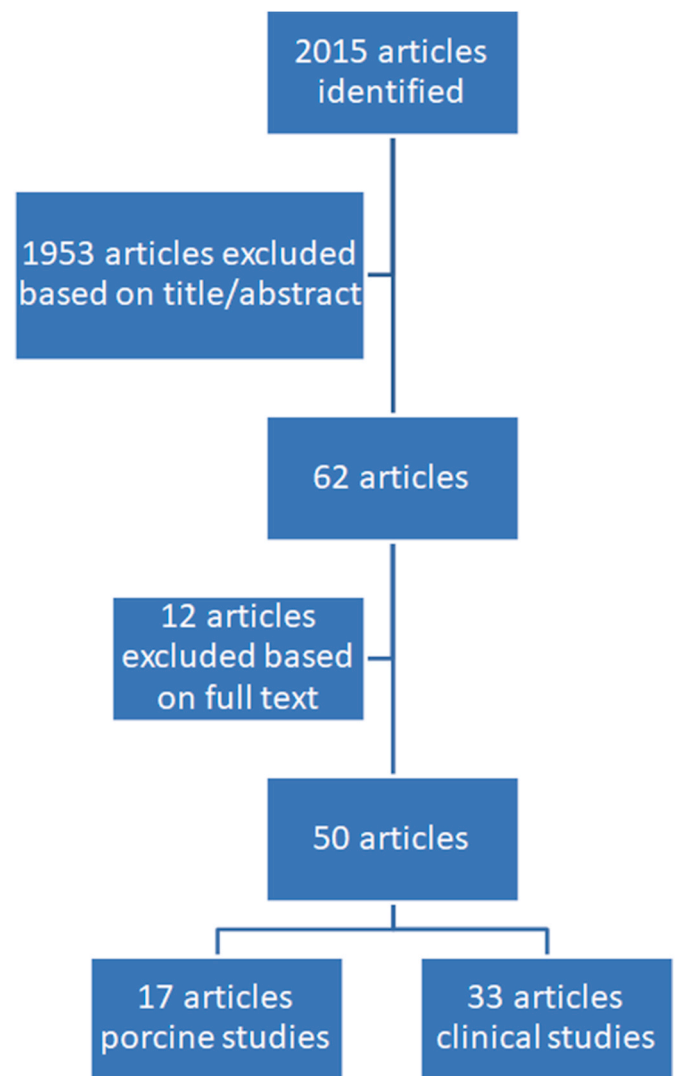


Fig. 3. Flowchart for selection of articles.

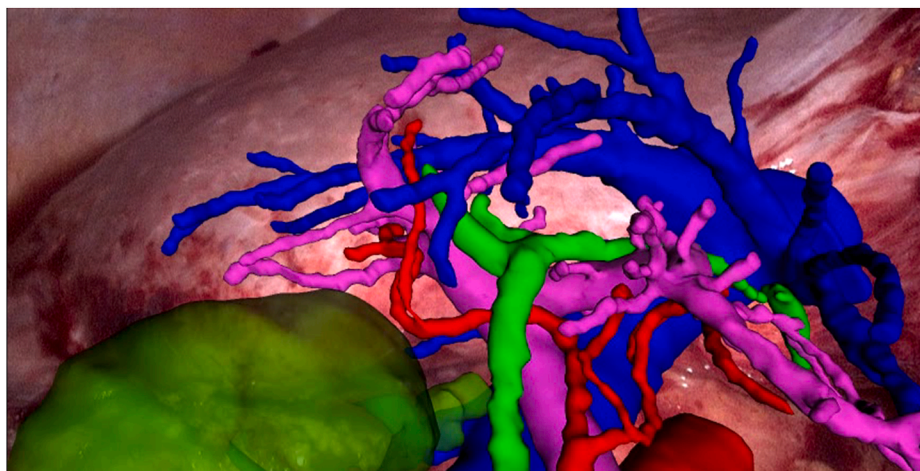


Fig. 2. AR visualisation showing the 3D model overlaid onto the operative site. The liver surface is not displayed to allow a clearer view of blood vessels and bile ducts (hepatic veins—blue; portal veins—purple; arteries—red, bile ducts & gallbladder—green). (original images by Ref. [75] licensed under CC-BY 4.0). (For interpretation of the references to colour in this figure legend, the reader is referred to the Web version of this article.)

and summarised in text and table format. To provide an introduction to the topic and standardise terminology, the results section begins with a brief description of the key principles underlying IGS and a summary of relevant findings.

3.1. Video IGS

The first article on Video-IGS published in 2006, investigated laser range scanning based surface reconstruction in a porcine model [31]. Since this publication there have been no new *in vivo* studies on this registration approach and in general most groups prefer to utilise manual registration with a tracked stylus or user manipulated overlay. Projecting 3D models externally onto a patients skin may aid laparoscopic port placement but visualisation can be altered by ports, instruments, and the uneven outline of the abdomen [35].

Currently AR is the most popular visualisation method because, as demonstrated in a porcine IGS study [36], it is thought to facilitate mental integration between image guidance data and operative site. The first clinical report on AR visualisation in LLR was published in 2011 [37]. AR is also a natural fit for robotic assisted liver resection since it utilises the inherent stereoscopic view of the DaVinci™ [17] console.

3.1.1. Surface reconstruction

Surface reconstruction describes the acquisition of biometric liver surface characteristics or in other words “reading the liver surface”. These characteristics can be used for semi-automatic registration but also to provide data streams to drive modelling of liver deformation (see below). It has been demonstrated in two porcine studies that semi-automatic registration is advantageous because it is less time consuming than manual registration and not influenced by user dependent registration errors(38,39).

Up to date SSR is the most widely researched surface reconstruction method. The first *in vivo* evaluation was published in 2015 on a porcine model. Using a non-deformable 3D liver model the authors achieved a TRE≈10 mm. It has been postulated that implementation of a deformable 3D model could improve the TRE to approximately 3–4 mm [25]. The application of SSR in humans has been more difficult. Some of the proposed methods to overcome this issue have been the use of deep learning to automatically segment (i.e. distinguish) the liver from surrounding organs [40] and the application of a scoring method to identify the optimal laparoscope position for SSR [29].

SSR can also facilitate tracking without the need for dedicated tracking equipment. One group proposed the use of ICP tracking, a method that utilises changes in liver surface biometry to infer laparoscope position. Studied in pre-clinical experiments this approach worked in real-time but navigation accuracy was inferior to that of optical tracking [33].

A potential alternative to SSR is SLAM which is a concept in computational geometry that enables updating of a map (e.g. liver surface) in an unknown environment while simultaneously tracking objects [32]. Using a standard monocular laparoscope, it has been demonstrated in a pre-clinical [41] and a clinical study [42] that SLAM has the potential to enable synchronous tracking and liver surface reconstruction.

3.1.2. Tissue deformation

Most IGS employ a rigid 3D model that cannot adjust shape or position to reflect physical forces (e.g. respiratory motion, surgical manipulation) exerted onto the liver. Based on results from porcine experiments, it has been postulated that deformable liver modelling is crucial in achieving navigation accuracies of <4 mm [25] and hence many researchers perceive this to be the holy grail of navigated image guidance.

The majority of publications are based on retrospective patient video data [24,43–45] whereas only some groups have attempted intraoperative evaluation in porcine [46,47] and human [48] studies. Various models based on complex problem-solving principles in maths

and physics have been postulated but a detailed methodological description goes beyond the scope of this review.

One of the main obstacles to clinical translation is the substantial computational expense (i.e. processing power demand), which makes it challenging to simulate deformable modelling in real-time. Generally, solutions can be categorised into biomechanical models and data driven models. The most popular biomechanical solution which has been successfully employed in patients, is the finite element method which utilises an organ mesh to represent tissue deformation [43,49]. Potentially less computationally expensive are data driven models which can be trained by observing laparoscopic video or synthetic simulations. These models utilise convolutional neural networks (CNN), a form of machine learning, which can use graphic processing units to drastically increase computing speed. It has been suggested that this advantage should enable real-time functionality in a clinical setting [44]. To the best of our knowledge however neither biomechanical nor data driven -models have been able to reliably simulate liver deformation in porcine [47] or clinical [43,44] studies. In summary, AR visualisation and semi-automatic registration are gaining popularity and have the potential to make Video-IGS easier to use. Fundamental improvements to navigation accuracy will probably depend on the development of reliable real-time tissue deformation.

3.2. Laparoscopic ultrasound IGS

One of the greatest obstacles in employing LUS is the difficulty of mentally integrating 2D US and laparoscopic images. Therefore the main focus of research has been on developing IGS that integrate LUS information into the intraoperative environment. The majority of LUS-IGS utilise B-mode US images as the primary source of visualisation [40,41] and hence integration of a 3D model is not mandatory. The first report on LUS-IGS was published in 2014 by a group that overlaid LUS images onto a 3D laparoscopic video feed in a porcine model. The authors stated that their system facilitated intuitive visualisation of sub-surface structures [36]. Optical tracking as utilised by this group cannot be combined with flexible LUS probes since changing the angle of the probe head is not reflected by the position of the optical tracker. To address this problem an IGS employing EM tracking markers at the tip of the LUS probe was developed and evaluated in a pre-clinical study [50]. Another group demonstrated in a clinical setting that LUS images may also be co-registered with CT images (i.e. correlating LUS images with spatial location on cross-sectional imaging) to aid in their simultaneous interpretation(51). It has been shown that LUS-IGS may aid laparoscopic liver ablation by enabling stereoscopic visualisation of probe trajectory and tumour position. In a series of 13 patients complete ablation was achieved in 12 cases [52]. Rather than using LUS for visualisation, one group demonstrated how it can be utilised for registration instead. Blood vessel centrelines were acquired with EM tracked LUS in a porcine model and this data enabled reconstruction of blood vessel anatomy which subsequently facilitated registration to the corresponding blood vessels on the 3D model. This approach also enabled integration of LUS images within the 3D model [53] (Fig. 4). In summary, data so far suggests that LUS-IGS seem to be particularly useful when co-registered with CT images or a 3D model. EM tracking is becoming increasingly popular since it is currently the only viable solution for tracking flexible LUS probes.

3.3. Computer tomography IGS

CT-IGS have the capacity to acquire volumetric anatomical data (e.g. liver shape) during surgery. This can then be used for direct visualisation of liver anatomy or for registration. A crucial step for the advent of CT-IGS has been an increased availability of cone beam CT (CBCT) within operating theatres. The first publication on this topic in 2008 reported the use of optically tracked CBCT during porcine laparoscopy. Registration of non-contrast and contrast enhanced CBCT was facilitated by

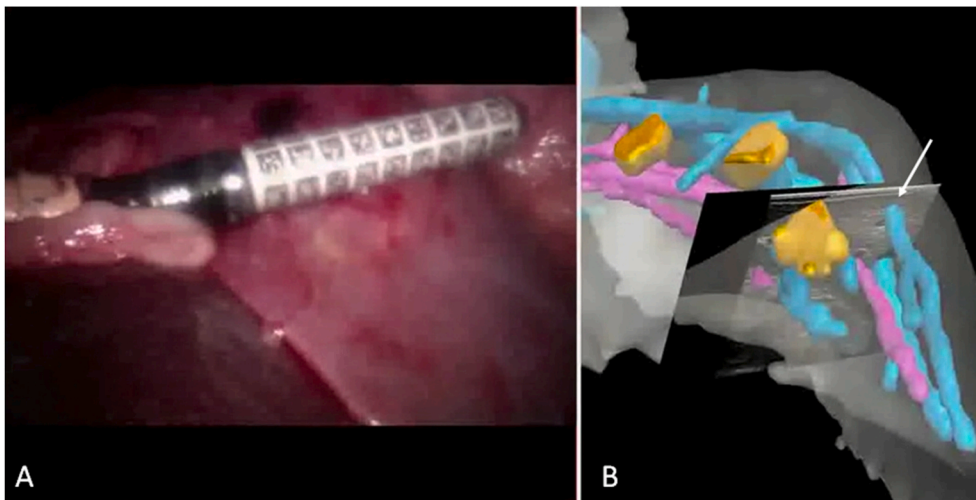


Fig. 4. LUS images can be integrated into an AR 3D model to enhance spatial correlation. A) LUS probe (in black) examining porcine liver. B) LUS image (monochrome square image) is integrated into a 3D porcine liver model. The position and content of the LUS image changes when the LUS probe is moved. Therefore there is spatial correlation of intrahepatic structures (e.g. blood vessel – arrow) on LUS image and 3D model. The liver borders are outlined in grey, hepatic veins are blue and portal veins are purple. Tumour locations are shown as yellow lesions. (original images by Ref. [53] licensed under CC-BY 4.0). (For interpretation of the references to colour in this figure legend, the reader is referred to the Web version of this article.)

attaching fiducials to either the skin or the liver surface, respectively. Following AR visualisation, navigation accuracy was app. 11 mm [54]. Two years later an IGS based on either intermittent or continuous low dose, non-contrast CT was developed and evaluated in a preclinical experiment. The low radiation dose of 25 mA enabled regular re-registration to adapt the 3D model to intraoperative liver deformation which resulted in a TRE of 1.45 mm. One-off rather than repeat registration was also explored but this resulted in decreased navigation accuracy since adjustment to liver deformation was not feasible. Major limitations were increased radiation exposure when using continuous CT and the requirement for a multi-slice CT scanner within the operating theatre [55]. Up to date, there has only been one report on CT-IGS application in a patient. In this report, biometric liver data was obtained by intraoperative CBCT to facilitate registration. Since the tumour was only visible on MRI, a preoperative MRI was used to process the 3D liver model. Intraoperative fluoroscopy enabled correlation between 3D model and surgical instruments [56]. In summary, CT-IGS technology is a precise registration tool but radiation exposure is high if it is used for intraoperative cross-sectional imaging.

3.4. Magnetic resonance imaging IGS

MRI guided liver ablation and surgery was made possible by the invention of the open plane MRI scanner which in contrast to conventional MRI scanners does not completely surround the patient and hence allows access to conduct procedures. In 2009 a group explored the use of open plane MRI in a porcine model of LLR. They determined that a T2 weighted sequence with fast spin echo provided the best image quality

while offering an acceptable image acquisition time. An electromagnetically shielded control room contained all non-MRI compatible equipment. Within the MR field surgeons used non-ferromagnetic laparoscopic ports in conjunction with a Nd:YAG laser which enabled tissue dissection and coagulation. The Nd:YAG titanium manufactured laser handle was marked with Gadolinium to aid its localisation in MR images [57]. The only other MRI-IGS study evaluated laparoscopic microwave ablation. Surgical instruments were constructed from weakly ferro-magnetic materials. The authors described successful ablation in 6 patients [58]. No 3D models were used in either of these works since MRI-IGS enabled direct correlation between instruments and liver anatomy (Fig. 5). In summary, MRI-IGS offers outstanding imaging quality compared to other IGS modalities but has restrictions in terms of operating room setup and instrument compatibility.

3.5. Data summary tables

For a table summary of included preclinical and clinical articles please see (Table 1) and (Table 2), respectively.

4. Discussion

This review has highlighted the current state of the art in navigated image guidance for minimally invasive liver surgery. The majority of publications are less than 10 years old which indicates that this technology is evolving rapidly. IGS have been evaluated in clinical scenarios right from the inception of this technology, a fact that is reflected by the large proportion of clinical articles in this review. Most studies were of

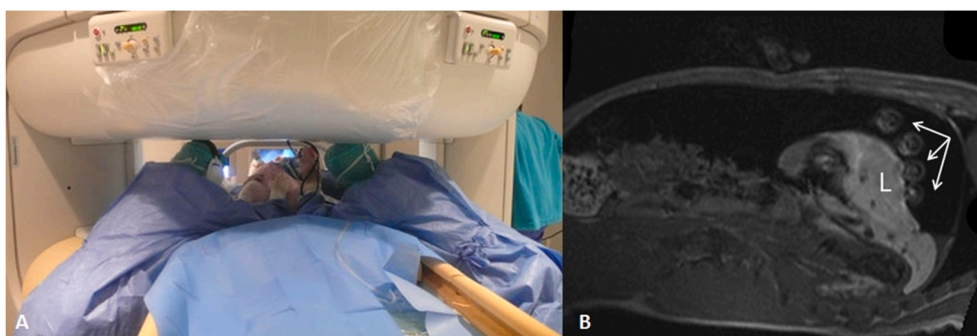


Fig. 5. A) Open plane MRI configuration restricts the surgeon's range of movement. Laparoscopic and MRI images can be visualised by non-ferromagnetic screens placed at the rear opening of the scanner B) Direct intraoperative visualisation of spatial relationship between the surgeon's fingers (arrows) and the liver (L). Liver vessels can be seen as dark circles within the parenchyma. reprinted with permission from Springer Nature [85].

Table 1
Pre-clinical studies

Author & Journal & Date and Country	Imaging modality & No. of subjects	Study design & Type of surgery	Methodology	Important findings	Important limitations
Hayashibe et al. [31] Medical Image Analysis August 2006, Japan	Video n = 1	Exploratory Laparoscopy	- Registration with laser surface scanning	- Allows reconstruction of biometrical liver surface data in real time. - Prevents collision of robotic instruments.	- No registration or visualisation demonstrated. - One subject only.
Konishi et al. [59] IJCARS June 2007, Japan	LUS n = 12	Exploratory Lap. ablation	- Co-registration of 3D LUS and video. - Optical tracking for rigid instruments. - EM tracking with magnetic distortion correction for flexible instruments.	- Magnetic distortion correction improved navigation accuracy from 17.2 mm to 1.96 mm . - LUS scanning time app. 30s. - Time to generate images app. 3 min.	- Lacks comparison of optical and EM tracking.
Feuerstein et al. [54] IEEE Transactions on Medical Imaging March 2008, Germany	CT-AR n = 2	Exploratory LLR	- CBCT used to create 3D model. - Display at expiration only to account for respiratory motion.	- Navigation accuracy = 11.05 ± 4.03 mm . - Visualisation of major liver vessels aided in laparoscopic port placement. - Respiratory motion increased TRE by app. 10 mm.	- Unable to visualise peripheral liver vessels. - 3D model lacks detail
Chopra et al. [57] European Radiology September 2009, Germany	MRI n = 2	Exploratory LLR	- Suitability of different MR sequences evaluated. - Development of MR-compatible theatre setup.	- Optimal MRI sequence is T2 fast spin echo. - Nitinol built laparoscope is MR compatible. - Tissue dissection with 1064-nm Nd:YAG laser is feasible and MR-compatible.	- No AR visualisation.
Shekhar et al. [55] Surgical Endoscopy August 2010, USA	CT-AR n = 6	Exploratory Laparoscopy	- Intraoperative multi-slice CT (not CBCT). - Registration with continuous or non-continuous low dose non-contrast CT.	- Navigation accuracy = 1.45 mm (low dose) vs. 1.47 mm (high dose) . - Low dose CT reduces radiation exposure eight fold. - Continuous scanning enabled registration updates.	- High radiation exposure with continuous CT compared to CBCT.
Kang et al. [36] Surgical Endoscopy July 2014, USA	LUS-AR n = 2	Exploratory Laparoscopy	- Overlay of LUS images onto 3D laparoscopic view.	- Successful registration of intrahepatic structures - Dark tissues (e.g. kidney) provide better contrast for overlaying LUS images.	- Feasibility only demonstrated with rigid LUS probe.
Thompson et al. [25] SPIE proceedings March 2015, UK	Video-AR (SmartLiver) n = 5	Exploratory LLR	- Semi-automatic registration with SSR - Accuracy comparison between rigid and deformable 3D models.	- Navigation accuracy app. 10 mm . - Successful registration n = 3/5. - Extensive liver deformation caused failure of SSR.	- Comparison rigid and deformable 3D models based on simulation only.
Reichard et al. [33] Journal of Medical Imaging October 2015, Germany	Video-AR n = 1	Exploratory Laparoscopy	- SSR registration. - Comparison of optical and ICP tracking.	- Navigation accuracy = 13 mm . - Best accuracy with combined ICP & optical tracking. - ICP tracking is more accurate with HD laparoscope. - Maximum frame rate 4/s.	- ICP tracking not working in real-time. - One subject only.
Song et al. [53] IJCARS December 2015, UK	LUS-AR (SmartLiver) n = 2	Exploratory Laparoscopy	- Registration to vascular landmarks with EM tracked LUS	- Navigation accuracy = 3.7–4.5 mm . - Accuracy better in proximity to landmarks. - LUS images integrated into 3D model.	- No comparison of SSR vs. LUS registration.
Reichard et al. [47] IJCARS July 2017, Germany	Video-AR n = 1	Exploratory Laparoscopy	- Semi-automatic registration with SSR. - Deformable, biomechanical 3D liver model.	- Demonstrated real-time registration and deformation on porcine spleen.	- <i>In-vivo</i> data on spleen only. - <i>No in vivo</i> accuracy data. - One subject only.
Ramalhinho et al. [60] IJCARS August 2018, UK	LUS-AR (SmartLiver) n = 1	Exploratory Laparoscopy	- LUS registration as in Ref. [53]. - Computer simulation to determine optimal LUS probe positions for registration.	- Navigation accuracy = 10.4–16.3 mm . - Higher vascular density in central liver segments improves registration.	- Re-evaluation of data from Ref. [53] but reports new findings. - One subject only.
Lau et al. [50] J Laparoendosc Adv Surg January 2019, USA	LUS-AR n = 1	Exploratory LLR	- EM tracked LUS. - LUS images overlaid onto laparoscopic view.	- LLR with AR 7 min. vs. 3 min. without AR.	- No accuracy data. - One subject only.

(continued on next page)

Table 1 (continued)

Author & Journal & Date and Country	Imaging modality & No. of subjects	Study design & Type of surgery	Methodology	Important findings	Important limitations
Modrzejewski et al. [46] IJCARS April 2019, France	Video-AR n = 1	Exploratory Laparoscopy	<ul style="list-style-type: none"> - Comparing liver resection margins, AR vs. no ARAR. - Semi-automatic registration with SSR. - Deformable, biomechanical 3D liver model. - Various dataset of liver deformation recorded for public use. 	<ul style="list-style-type: none"> - Clear resection margins in both groups. - Navigation accuracy = 20 mm (intrahepatic) vs. 15 mm (liver surface). - Self-collision restraint of deformable 3D model improved navigation accuracy by 1–2 mm. 	<ul style="list-style-type: none"> - SSR methodology not described in detail. - One subject only.
Luo et al. [61] Computer Methods and Programs in Biomedicine September 2019, China	Video-AR n = 5	Exploratory LLR	<ul style="list-style-type: none"> - Semi-automatic registration with SSR. - 3D modelling and registration with convolutional neural networks. - Liver surface fiducials to aid registration. 	<ul style="list-style-type: none"> - Navigation accuracy = 8.7 ± 2.4 mm -Liver surface reconstruction and registration in app. 3 min. - Frame rate 10–12 fps <i>ex-vivo</i>. - Review of different accuracy evaluation methods. 	<ul style="list-style-type: none"> - Navigation not in real-time. - <i>In vivo</i> frame rate not stated. - Requires intraoperative CT.
Teatini et al. [38] Scientific Reports December 2019, Norway	Video-AR n = 4	Exploratory Laparoscopy	<ul style="list-style-type: none"> - Manual registration. - Creation and comparison of pre- (multislice CT) and intra-operative (CBCT) 3D models. - Evaluation fiducials vs. user-defined landmarks. 	<ul style="list-style-type: none"> - Navigation accuracy = 19.04 mm (intraoperative 3D model) vs. 38.37 mm (preoperative 3D model). - Landmark dependent error 20.3 mm (manual selection) vs. 14.38 mm (fiducial). - Accuracy improved with minimum 4–5 landmarks. 	<ul style="list-style-type: none"> - Fiducial results only for three subjects. - Unclear how visible diathermy marking is on CT liver.
Teatini et al. [39] Min Invasive Ther Jan 2020, Norway	Video-AR n = 1	Exploratory Laparoscopy	<ul style="list-style-type: none"> - Comparison of manual registrations by different surgeons. - Evaluating impact of sampling error on accuracy. 	<ul style="list-style-type: none"> - Navigation accuracy 13.37 ± 6.25 mm - Different accuracy results between surgeons (p = 0.00045). 	<ul style="list-style-type: none"> - Only one <i>subject</i> - Usage of different accuracy metrics is confusing.
Liu et al. [62] IJCARS May 2020, USA	LUS n = 1	Exploratory Lap. ablation	<ul style="list-style-type: none"> - EM tracked LUS - LUS images showing needle trajectory overlaid onto laparoscopic view. 	<ul style="list-style-type: none"> - IGS feasibility demonstrated. - Artificial tumours successfully targeted. 	<ul style="list-style-type: none"> - Comparison of AR vs. LUS guided needle placement <i>ex vivo</i> only.

Table 1. Summary of included preclinical articles. Navigation accuracy data is highlighted in bold. Journal name abbreviations: IJCARS - International Journal of Computer Assisted Radiology and Surgery; J Laparoendosc Adv Surg - Journal of Laparoendoscopic & Advanced Surgical Techniques; Min Invasive Ther - Minimally Invasive Therapy & Allied Technologies.

an exploratory nature and were not designed to demonstrate clinical benefits. This is perhaps unsurprising since at this development stage the research focus has been on innovation rather than clinical validation.

Twenty-four articles in this review published quantitative data on navigation accuracy. The methodology of navigation accuracy assessment varies between research groups and therefore it is difficult to compare results directly [61]. Despite these disparities there appears to be some evidence that studies using retrospective registration [24,43] and studies with only one subject [29,66] tend to report better navigation accuracy which may point towards associated bias. Recently, the proportion of publications stating accuracy data is increasing, which perhaps reflects the recognition by scientists that quantifiable data is paramount to advance the field (Fig. 6).

The advent of AR has been an important development. Whereas earlier systems relied on two separate screens, AR offers more intuitive visualisation. Utilisation of AR may cause information overload [70] which can be addressed by allowing surgeons to switch between full AR, limited AR (e.g. area of interest, limited opacity) and no AR [70,74]. Enhanced rendering has been proposed as another potential solution [78]. This technology employs a variety of graphics processing methods such as plane clipping, distance fogging and shape outlining to focus the surgeons attention on relevant anatomical details (Fig. 7).

Judging by the number of publications, Video-IGS have seen the

most attention by the research community. This popularity can perhaps be explained by advantages such as user friendliness, low costs, portability, high image acquisition speed, and compatibility with existing surgical equipment [6,23,24]. Its main disadvantage is a lack of depth penetration which means that the position of deep lying structures can only be inferred from a 3D model whereas LUS-, CT- and MRI-IGS may offer direct visualisation of deep structures. Attempts at developing deformable 3D liver models have been promising [24,44,47] but so far no group was able to demonstrate real-time functionality during surgery. A previous study estimated that under optimal circumstances a rigid 3D model could yield a TRE of 8–10 mm. One-off deformation to adapt to relatively constant changes in liver shape (e.g. after liver mobilisation) may achieve TRE's of 5–6 mm whereas real-time soft tissue deformation may further improve the TRE to 2–3 mm [25]. Up to date, deformation research in LLR has not formally addressed the impact of liver transection. In open liver surgery it was observed that liver transection causes up to 8.7 mm displacement of intrahepatic blood vessels [79]. How this phenomenon will be incorporated into deformable 3D liver models for LLR remains to be seen. That deformable 3D models have so far remained elusive, can perhaps explain why some data points towards better navigation accuracy for CT and LUS-IGS [53,55, 56,59].

SSR which requires expensive 3D laparoscopes is currently the most

Table 2
Clinical studies.

Author & Journal & Date and Country	Imaging modality & No. of subjects	Study design & Type of surgery	Methodology	Important findings	Important limitations
Volonté et al. [35] J Hepatobil Pancreat Sci April 2011, Switzerland	Video-AR (OsiriX) n = not stated	Exploratory Robotic	- Manual registration to external landmarks. - Projection of 3D model on patient skin.	- External projection aided in laparoscopic port placement.	- 3D model distorted by instruments and ports. - No accuracy data.
Nicolau et al. [37] Surgical Oncology September 2011, France	Video-AR n = 5	Exploratory LLR	- Manual registration. - Estimated portal vein position AR vs. surgeon assessment vs. LUS (control).	- Registration more precise with small field of view. - Repeat registration if field of view changes. - AR superior to surgeon assessment in 2/5 cases.	- No accuracy data. - IGS technology not described.
Kingham et al. [8] Journal of gastrointestinal surgery July 2013, USA	Video (Explorer™) n = 32	Exploratory Laparoscopy	- Manual registration and additional laser surface scanning registration in some open cases. - Comparison open surgery vs. laparoscopy at 7mmHg & 14 mmHg.	- Navigation accuracy = 4.9 ± 1.3 mm (laparoscopic at 14 mmHg) vs. 5.4 ± 2.1 mm (open). - Accuracy comparable at 7 mmHg vs. 14 mmHg. - Registration time app. 3min.	- No performance metrics for laparoscopic group - No surgeon feedback.
Buchs et al. [17] J Surg Res October 2013, Switzerland	Video (CAS-One Surgery™) n = 2	Exploratory Robotic	- Manual registration. - AR integrated into robotic console.	- IGS useful for localising lesions. - Potentially faster manual registration due to robotic tremor elimination.	- No accuracy data.
Kennigott et al. [56] Surgical Endoscopy March 2014, Germany	CT-AR n = 1	Exploratory LLR	- CBCT registration using liver volume reconstruction. - 3D model constructed from MRI since tumour not visible on CT.	- Feasible to determine optimal liver transection plane.	- No <i>in vivo</i> accuracy data. - No respiratory gating. - One subject only.
Satou et al. [26] Hepatology Int. March 2014, Japan	Video-AR n = 7	Exploratory LLR	- Manual registration.	- Intraoperative tumour location correlated with AR.	- No accuracy data. - Technology not described.
Hammill et al. [63] Surgical Innovation August 2014, USA	Video (Explorer™) n = 27	Clin. study Lap. ablation	- Manual registration - Comparison LUS vs. IGS ablation probe placement.	- Navigation accuracy = 19.56 mm. - Comparable accuracy IGS vs. LUS (13.15 mm).	- Additional error introduced by optical tracking of flexible ablation probe.
Sindram et al. [52] HPB January 2015, USA	LUS n = 13	Exploratory Lap. ablation	- EM tracked LUS. - Ablation probe position and needle trajectory visualised. - Clinical evaluation.	- 34 lesions ablated in 13 patients. - Incomplete ablation n = 1. - Re-ablation in 7 % (same sitting). - Clin. Outcomes: complications n = 3; no mortality.	- No accuracy data. - No data on early recurrence. - No control group.
Pessaux et al. [27] Langenbeck's Archives of Surgery April 2015, France	Video-AR n = 3	Exploratory Robotic	- Manual registration. - One-off deformation to adjust to pneumoperitoneum. - External beam projection of 3D model.	- AR aided in the identification of tumour and other structures.	- No accuracy data. - No surgeon feedback.
Haouchine et al. [43] IEEE Trans Vis Comput Graph May 2015, France	Video-AR n = 1	Exploratory Laparoscopy	- Semi-automatic registration with SSR. - Deformable, biochemical 3D model. - Individual deformation modelling for liver parenchym and blood vessels.	- Navigation accuracy app. 4 mm. - Frame rate of 25 fps. - Increasing number of 3D model elements improves accuracy.	- Retrospective registration. - Functionality depends on good initial manual registration. - One subject only.
Murakami et al. [58] Surgery Today September 2015, Japan	MRI n = 6	Exploratory Lap. ablation	- Designed MR-compatible, weakly ferromagnetic laparoscope.	- Clinical feasibility demonstrated. - No significant complications. - Mean procedure time 275 min.	- Long procedure time. - No control group.
Plantefeve et al. [24] Annals of Biomedical Engineering January 2016, France	Video-AR n = 2	Exploratory Laparoscopy	- Deformable, biomechanical 3D model. - Individual deformation modelling of parenchym, blood vessels and Glissonian capsule. - Landmarks used in addition to surface registration.	- Navigation accuracy < 1.1 mm. - Only feasible if 30–40 % of liver surface is visible. - Use of landmarks creates deformation boundaries that improves registration and 3D modelling.	- Retrospective registration. - Further development from Ref. [43] but reports new findings.
Huber et al. [64] Zeitschrift für Gastroenterologie January 2016, Germany	Video (CAS-One Surgery™) n = 1	Case report LLR	- Manual registration. - 3D model based on CT prior to neoadjuvant chemotherapy	- Vanished liver lesion (i.e. not visible on LUS or inspection) localised by IGS.	- No accuracy data. - One subject only.
Schneider et al. [65] HPB April 2016, UK	Video-AR (SmartLiver) n = 11	Exploratory Lap. and LLR	- Manual and semi-automatic registration with SSR. - Evaluation of usability. - Structured surgeon feedback.	- Setup time app. 21 min. - Feedback suggests the setup process is too complex.	- No accuracy data - Part retrospective analysis.
Conrad et al. [66] Journal of the American College of	Video-AR (CAS-One Surgery™) n = 1	Case report LLR	- Manual registration. - Two-stage hepatectomy.	- Navigation accuracy app. 5 mm.	- One subject only. - Not compared to LUS.

(continued on next page)

Table 2 (continued)

Author & Journal & Date and Country	Imaging modality & No. of subjects	Study design & Type of surgery	Methodology	Important findings	Important limitations
Surgeons October 2016, USA			- AR used to guide liver transection during 1st stage.	- IGS useful for orientation but is unable to identify all relevant anatomical structures. - Registration time app. 1 min.	
Aoki et al. [51] The American Surgeon December 2016, Japan	LUS n = 1	Exploratory LLR	- EM tracked LUS. - Co-registration of LUS and CT scan. - Intrahepatic structures manually highlighted on CT.	- Able to visualise spatial relationship between surgical instruments and anatomical structures. - Navigation accuracy = 4.7 mm - Method improved TRE from 17.5 mm to 4.7 mm. - Identified 4 optimal surface patches for registration	- No accuracy data. - IGS technology not described. - One subject only. - Further development from Ref. [65] but reports new findings. - One subject only.
Robu et al. [29] IJCARS July 2017, UK	Video-AR (SmartLiver) n = 1	Exploratory LLR	- Semi-automatic registration with SSR. - Systematic scoring to evaluate optimal laparoscope positions for facilitating SSR.	- Navigation accuracy = 8.1 mm. - Successful registration in all patients. - Calibration time = 1 min; Registration time = 4 min. - Early recurrence n = 16.	- No control group. - Concomitant bowel or liver resection in some patients.
Tinguely et al. [67] Surgical Endoscopy October 2017, Switzerland	Video (CAS-One Surgery™) n = 51	Clin. study Lap. ablation	- Manual registration. - IGS guided liver ablation. - Evaluation of IGS performance and clinical outcomes.	- AR aided identification of transection plane, middle hepatic vein and tumour. - AR less useful during transection due to organ deformation.	- No accuracy data. - Only one case described although 8 cases performed. - IGS technology not described.
Phutane et al. [68] Surgical Endoscopy January 2018, France	Video-AR n = 1	Video pres. LLR	- Manual registration. - Empiric evaluation during major hepatectomy.	- Navigation accuracy = 14.7 mm (rigid model) vs. 7.9 mm (Rucker method) vs. 6.4 mm (deformable 3D model). - Registration time 140–320s. - Deformation modelling can be done preoperatively.	- Frame rate not stated. - Further development from Ref. [8] but reports new findings.
Heiselman et al. [49] Journal of Medical Imaging April 2018, USA	Video (Explorer™) n = 25	Exploratory Laparoscopy	- Manual registration. - Deformable, biomechanical 3D model. - Liver ligaments and posterior liver used as fixed points around which liver deformation is modelled. - Comparison of deformable and rigid 3D modelling.	- Feasibility of 2 step registration demonstrated. - Method may form basis for fully automatic registration without initial manual alignment.	- No accuracy data. - Further development from Ref. [65] but reports new results. - One subject only.
Robu et al. [69] IJCARS June 2018, UK	Video-AR (SmartLiver) n = 1	Exploratory LLR	- Semi-automatic registration with SSR. - Two step ICP matching - 1st step coarse registration to landmark. - 2nd step fine tuning registration by SSR.	- Navigation accuracy app. 12 mm. - Surface landmarks are reliable predictors of TRE and suitable substitutes for intrahepatic structure localisation.	- Mixed real-time and retrospective registration. - Further development from Ref. [25] but reports new results. - Retrospective registration. - No <i>in vivo</i> accuracy data. - One subject only.
Thompson et al. [70] IJCARS June 2018, UK	Video-AR (SmartLiver) n = 9	Exploratory Laparoscopy and LLR	- Manual registration. - Real-time visual feedback on navigation accuracy. - Assessing correlation between surface landmarks, intrahepatic structures and navigation accuracy.	- Clinical feasibility of SLAM demonstrated. - IGS can adapt to minor deformation (e.g. respiratory motion).	- High frequency jet ventilation reduces undesired respiratory liver motion. - IGS improved user confidence compared to LUS guidance.
Mahmoud et al. [41] IEEE Trans Med Imaging July 2018, France	Video-AR n = 1	Exploratory Laparoscopy	- Dense SLAM for registration and tracking. - IGS works with monocular laparoscopes.	- IGS localised liver lesion which was not visible on LUS due to artefact. - Standard monocular laparoscope used.	- No accuracy data. - Number of laparoscopic cases not stated. - No control group.
Beerman et al. [71] European journal of radiology open December 2018, Sweden	Video (CAS-One Surgery™) n = not stated	Clin. study Lap. ablation	- Manual registration. - Retrospective analysis of IGS ablation.	- Navigation accuracy = 8.8 mm (LLR) vs. 7.5 mm (open), (p = 0.68). - Repeat registration improved deformation error. - Surgically exposed liver vessels used as landmarks. - Adding more landmarks did not improve accuracy. - Registration time ≤2 min.	- Accuracy not stated for individual patients. - Not clear how additional landmarks were registered.
Le Roy et al. [72] J. of Visceral Surgery February 2019, France	Video-AR n = 1	Video pres. LLR	- Semi-automatic registration. - One-off deformation to adjust 3D model to intraoperative <i>in vivo</i> liver shape.	- IGS has potential to adapt deformation to patient specific factors (e.g. liver consistency).	- No <i>in vivo</i> accuracy data. - Retrospective registration. - One subject only.
Yasuda et al. [73] Asian Journal of Endoscopic Surgery April 2019, Japan	Video-AR n = 4	Clin. study LLR	- Manual registration. - CT cholangiography incorporated into 3D model. - Landmarks measured with tape and marked with diathermy. - IGS performance compared LLR vs. open surgery.		
Pfeiffer et al. [44] IJCARS April 2019, Germany	Video n = 1	Exploratory Laparoscopy	- Deformable, data driven 3D model based on a convolutional neural network.		

(continued on next page)

Table 2 (continued)

Author & Journal & Date and Country	Imaging modality & No. of subjects	Study design & Type of surgery	Methodology	Important findings	Important limitations
			- Model trained by synthetic data using multiple organ like meshes.	- Data driven modelling runs at 50 fps. - No deformation modelling of surgical manipulation.	
Prevost et al. [74] Journal of gastrointestinal surgery September 2019, Switzerland	Video-AR (CAS-One AR™) n = 10	Clinical study LLR	- Manual registration. - Further development from Ref. [17]. - AR overlaid onto 3D video. - Hepato-caval confluence and porta hepatis used as preferred landmarks due to stable position.	- Navigation accuracy = 9.2 mm. - Selective visualisation of area of interest. - Calibration time 43s; Registration time 8,50 min. - IGS aids in localising difficult to identify liver lesions but lacks precision to fully navigate resection.	- Not stated how TRE was calculated in 3D video space.
Schneider et al. [75] Surgical Endoscopy July 2020, UK	Video-AR (SmartLiver) n = 18	Clin. study LLR	- Semi-automatic registration with SSR - Comparison of navigation accuracy manual vs semi-automatic registration. - Training of CNN to recognise liver surface on video. - Surgeon feedback forms.	- Navigation accuracy = 10.9 mm (manual) vs. 13.9 mm (semi-automatic) (p = 0.158) - Registration successful in n = 16/18. - Automatic liver segmentation using CNN. - Setup time (10–15 min) needs improvement.	- Mixed real-time and retrospective registration. - Further development from Ref. [70] but reports new results.
Zhang et al. [42] Surgical Endoscopy August 2020, China	Video-AR n = 64 (30 IGS vs. 34 no IGS)	Clin. study LLR	- SLAM for surface reconstruction and tracking. - Semi-automatic registration with SLAM. - Simultaneous visualisation of AR and near infrared imaging with ICG. - Clinical outcome comparison IGS vs. no IGS.	- Reduced length of stay and blood loss in IGS group. - IGS visualisation of tumour margin 27/30. - IGS aided in identifying intrahepatic structures and liver transection line. - Setup time 30s.	- No accuracy data. - IGS technology not described.
Aoki et al. [76] Journal of Gastrointestinal Surgery September 2020, Japan	LUS n = 27	Clin. study LLR	- EM tracked LUS to CT registration. - Anatomical colour coding of structures in CT.	- Navigation accuracy = 12 mm. - Successful image guidance in 26/27 cases. - IGS identified 3 lesions not visible on LUS. - Registration time <2min; -Setup time 7min.	- Patient needs to remain in neutral table position. - 3D model available but not registered to patient.
Bertrand et al. [48] Surgical Endoscopy December 2020, France	Video-AR (Hepataug) n = 17	Clin. study LLR	- Deformable, biomechanical 3D model. - Semi-automatic registration. - Further development from Ref. [72].	- No interruption to workflow - Good correlation between LUS and IGS - Two lesions identified that were not visible on LUS.	- No data on accuracy or workflow interruption. - IGS technology not described.
Aoki et al. [77] Surgical Oncology December 2020, Japan	Video-AR n = 1	Case report LLR	- Manual registration. - AR-guided needle puncture of portal vein branch. - Positive ICG staining technique of liver segments. - Headset visualisation.	- Portal vein branch accurately targeted. - Operative time 285 min.	- No accuracy data - Registered 3D model available but not utilised - Very long procedure time.

Table 2. Summary of included clinical articles. Published navigation accuracy data is highlighted in bold. Journal abbreviations: IJCARS - International Journal of Computer Assisted Radiology and Surgery; J Hepatobil Pancreat Sci - Journal of Hepato-Biliary-Pancreatic Sciences; J Surg Res - Journal of Surgical Research; Hepatology Int. - Hepatology International; J. of Visceral Surgery – Journal of Visceral Surgery; IEEE Trans Vis Comput Graph - IEEE Transactions on Visualisation and Computer Graphics; IEEE Trans Med Imaging - IEEE Transactions on Medical Imaging.

popular solution for semi-automatic registration. Semi-automatic registration could be expanded to cheaper monocular laparoscopes if registration through shading and motion or SLAM becomes feasible in the future [33,41,44,80]. CNN have been successfully used to estimate position and orientation of objects in a 2D image. At 50–94 frames per second this method is faster and more accurate than biomechanical approaches [81]. Since no 3D laparoscopes are required, CNN could potentially facilitate ICP tracking and semi-automatic registration in conjunction with monocular laparoscopes.

There are two main applications for LUS-IGS. Firstly it can be employed as a registration tool to identify subsurface liver structures (e. g. vessels) which are subsequently registered to a 3D model or CT scan [51,53]. Secondly it can facilitate integration of LUS images into an AR display [36,51,53]. Advantages of LUS are wide availability, portability, low costs, high image acquisition speed and an excellent resolution and depth penetration. Disadvantages are its inherent 2D nature and user

dependent accuracy. Co-registration of LUS and CT images as standalone visualisation may offer some advantages over routine LUS but in our opinion this is unlikely to provide the same benefit as AR with a 3D model.

There were only three eligible articles on CT-IGS. Two articles demonstrated CBCT based registration [54,56] whereas the third article purported low dose spiral CT as a feasible alternative to CBCT [55]. CT-IGS offer good navigation accuracy, visualisation of intrahepatic structures and the ability to generate volumetric rather than just surface data. Disadvantages are low resolution (CBCT), ionising radiation, high costs and lack of portability [56,82]. At this stage, CT-IGS have the best published navigation accuracy [55,56] which may make them useful as a benchmarking tool.

Only two publications reported on MRI-IGS, one on liver resection and liver ablation, respectively. Advantages of this modality are excellent imaging quality and the ability to generate volumetric data.

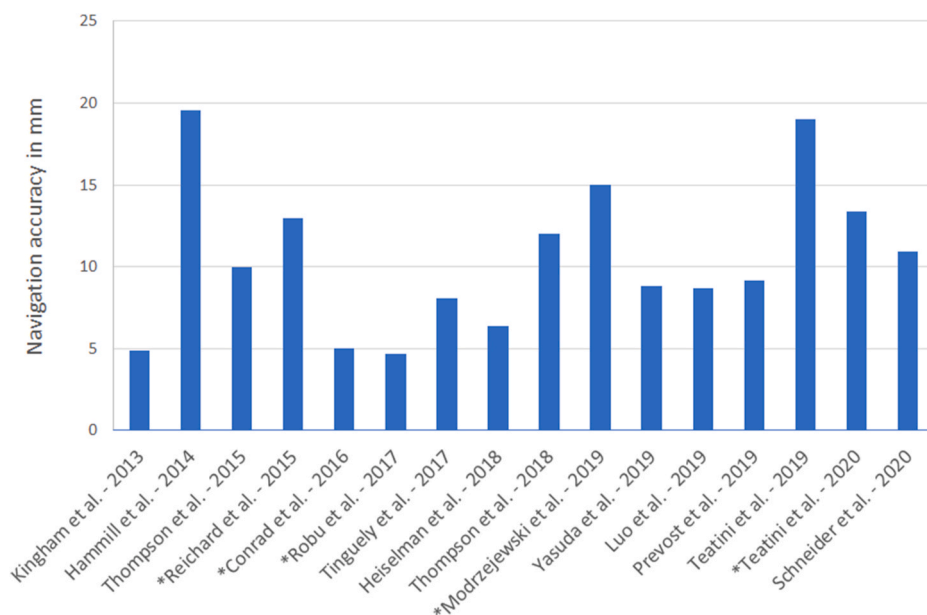


Fig. 6. Graphic showing published navigation accuracy of Video-IGS which demonstrates that reporting of navigation accuracy is becoming increasingly common. Although different evaluation methods are used there appears to be less discrepancy between the results of different groups in recent years. Studies where no intraoperative registration was carried out have been excluded. If accuracy values between different groups were compared then only the best value is stated. *Study with only one subject.

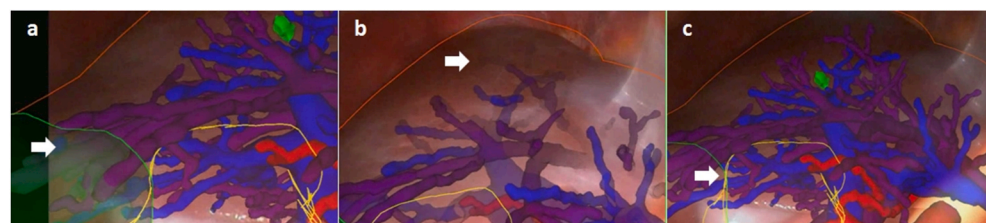


Fig. 7. Different methods of enhanced rendering are showcased on the same video sequence showing the right liver with overlaid hepatic veins (purple), portal veins (blue), hepatic arteries (red), liver tumours (green) and gallbladder (yellow). a) Plane clipping can show what is inside a structure – arrow pointing out hepatic vein branch draining the tumour (purple with green hazy outline) b) Distance fogging enhances perception of distance by shading objects

differently – arrow pointing at a segmental portal vein branch whose greater transparency indicates an increased distance from the surgeons viewpoint c) Traditionally anatomical structures are shown completely filled with colour which makes it impossible to see what is behind a structure. Shape outlining enhances edges that surround structures to improve 3D scene perception and interpretation – arrow indicating border between tumour and gallbladder. (original images by Ref. [70] licensed under CC-BY 4.0). (For interpretation of the references to colour in this figure legend, the reader is referred to the Web version of this article.)

Table 3
Characteristics of different IGS modalities.

IGS modality	Navigation accuracy	Availability	Transportability	Costs	Main limitation
Video	+	+++	+++	+	Rigid 3D model
LUS	+	+++	+++	+	2D imaging
CT	++	++	+	++	Ionising radiation exposure & Rigid 3D model
MRI	+++(#)	+	+	+++	Incompatibility with surgical instruments

Table 3. Shown are practical considerations for each IGS modality discussed in this article. # Navigation accuracy not stated but in principle MRI images visualise the actual intraoperative situation and therefore account for organ deformation and movement.

Disadvantages are incompatibility with standard surgical equipment, long image acquisition time, very high costs and limited availability. Surgical freedom of movement is restricted by the size and shape of the MRI scanner (Fig. 5).

Four articles, all based on Video-IGS, investigated IGS in robotic assisted surgery [17,24,27,43]. The feasibility of translating IGS methodology from a laparoscopic [27] or open [17] setting to robotic assisted surgery has been demonstrated. Compared to robotic assisted surgery, laparoscopic surgery is more widely disseminated and cheaper [83,84]. Therefore it is probable that most IGS innovations will be developed for LLR initially and subsequently transferred to a robotic platform if clinical benefit is sufficiently incentivising.

A number of limitations have to be taken into account. A meta-analysis of navigation accuracy would have been useful but since a

variety of TRE calculation methods is used by different groups this was technically not possible. Because this review exclusively focused on *in vivo* studies it is possible that recent developments that were only evaluated *ex vivo* are not included. In our experience however the translation process from *ex vivo* to clinically relevant IGS research is long and we found that many *ex vivo* studies have limited surgical relevance.

In conclusion it is the author’s opinion that due to aforementioned advantages Video and LUS -IGS have the best potential to be developed into useful tools for LLR. The navigation accuracy of CT-IGS is user independent and hence it may prove valuable as a benchmark control for new IGS technology. A generalised summary for practical considerations of different IGS modalities is shown in Table 3.

Current IGS technology requires further advances to evolve into a fully dependable navigation tool [42,64]. To allow effective comparison

of clinical benefits a standardised approach in the evaluation of navigation accuracy would be beneficial [46,70]. An essential step to facilitate this is to encourage interdisciplinary collaboration between imaging scientists and hepatobiliary surgeons and it is hoped that this review will contribute to this process.

Funder statement

This publication presents independent research commissioned by the Health Innovation Challenge Fund (HICF-T4-317), a parallel funding partnership between the Wellcome Trust and the Department of Health. The views expressed in this publication are those of the author(s) and not necessarily those of the Wellcome Trust or the Department of Health. In addition this work was supported by the Wellcome/EPSRC [203145Z/16/Z].

Declaration of competing interest

Professor Hawkes is a co-founder of IXICO Ltd. Drs. Schneider and Allam as well as Profs. Davidson, Gurusamy and Stoyanov have no conflict of interest to declare.

Appendix A. Supplementary data

Supplementary data to this article can be found online at <https://doi.org/10.1016/j.suronc.2021.101637>.

Author statement

Crispin Schneider: Data curation, Writing manuscript; Moustafa Allam: Data curation, Revision of manuscript; Danail Stoyanov: Computer science expertise, Review & Editing; Kurinchi Gurusamy: Systematic review expertise, Methodology; David Hawkes: Medical physics expertise, Validation, Funding; Brian Davidson: Conceptualization, Supervision, Funding.

References

- [1] R. Ciria, D. Cherqui, D.A. Geller, J. Briceno, G. Wakabayashi, Comparative short-term benefits of laparoscopic liver resection: 9000 cases and climbing, *Ann. Surg.* 263 (4) (2016 Apr) 761–777.
- [2] D. Fuks, F. Cauchy, S. F eriche, T. Nomi, L. Schwarz, S. Dokmak, et al., Laparoscopy decreases pulmonary complications in patients undergoing major liver resection, *Ann. Surg.* (2015) 1.
- [3] G. Wakabayashi, D. Cherqui, D.A. Geller, J.F. Buell, H. Kaneko, H.S. Han, et al., Recommendations for laparoscopic liver resection, *Ann. Surg.* 261 (4) (2015) 619–629.
- [4] A. El-Gendi, M. El-Shafei, S. El-Gendi, A. Shawky, Laparoscopic versus open hepatic resection for solitary hepatocellular carcinoma less than 5 cm in cirrhotic patients: a randomized controlled study, *J. Laparoendosc. Adv. Surg. Tech.* 28 (3) (2018 Mar) 302–310.
- [5]  .A. Fretland, V.J. Dagenborg, G.M.W. Bj ornelv, A.M. Kazaryan, R. Kristiansen, M. W. Fagerland, et al., Laparoscopic versus open resection for colorectal liver metastases, *Ann. Surg.* 267 (2) (2017) 1.
- [6] I. Dagher, N. O'Rourke, D.A. Geller, D. Cherqui, G. Belli, T.C. Gamblin, et al., Laparoscopic major hepatectomy: an evolution in standard of care, *Ann Surg* 250 (5) (2009) 856–860, 2009/10/07.
- [7] J. Kirchberg, C. Reiffelder, J. Weitz, M. Koch, Laparoscopic surgery of liver tumors, *Langenbeck's Arch. Surg.* 398 (2013) 931–938.
- [8] T.P. Kingham, S. Jayaraman, L.W. Clements, M.A. Scherer, J.D. Stefansic, W. R. Jarnagin, et al., Evolution of image-guided liver surgery: transition from open to laparoscopic procedures, *J. Gastrointest. Surg.* 17 (7) (2013 Jul) 1274–1282.
- [9] X. Cai, Z. Li, Y. Zhang, H. Yu, X. Liang, R. Jin, et al., Laparoscopic liver resection and the learning curve: a 14-year, single-center experience, *Surg. Endosc.* (2014) 1–8.
- [10] F. Cauchy, D. Fuks, T. Nomi, L. Schwarz, L. Barbier, S. Dokmak, et al., Risk factors and consequences of conversion in laparoscopic major liver resection, *Br. J. Surg.* 102 (7) (2015 Jun 1) 785–795.
- [11] T. Nomi, D. Fuks, Y. Kawaguchi, F. Mal, Y. Nakajima, B. Gayet, Learning curve for laparoscopic major hepatectomy, *Br. J. Surg.* 102 (7) (2015 Jun) 796–804.
- [12] T. Ishizawa, A.A. Gumbs, N. Kokudo, B. Gayet, Laparoscopic segmentectomy of the liver: from segment I to VIII, *Ann Surg* 256 (6) (2012 Dec) 959–964.
- [13] M. Abu Hilal, F. Di Fabio, M. Abu Salameh, N.W. Pearce, Oncological efficiency analysis of laparoscopic liver resection for primary and metastatic cancer: a single-center UK experience, *Arch. Surg.* 147 (1) (2012 Jan) 42–48.
- [14] K.T. Nguyen, T.C. Gamblin, D.A. Geller, World review of laparoscopic liver resection-2,804 patients, *Ann Surg* 250 (5) (2009 Nov) 831–841, 2009/10/06.
- [15] H. Topal, J. Tiek, R. Aerts, B. Topal, Outcome of laparoscopic major liver resection for colorectal metastases, *Surg. Endosc.* 26 (9) (2012) 2451–2455.
- [16] T.P. Kingham, M.A. Scherer, B.W. Neese, L.W. Clements, J.D. Stefansic, W. R. Jarnagin, Image-guided liver surgery: intraoperative projection of computed tomography images utilizing tracked ultrasound, *HPB (Oxford)* 14 (9) (2012 Sep) 594–603.
- [17] N.C. Buchs, F. Volonte, F. Pugin, C. Toso, M. Fusaglia, K. Gavaghan, et al., Augmented environments for the targeting of hepatic lesions during image-guided robotic liver surgery, *J. Surg. Res.* 184 (2) (2013 Oct) 825–831.
- [18] Q.R.J.G. Tummers, F.P.R. Verbeek, J.M. Prevoo H a, A.E. Braat, C.I.M. Baeten, J. V. Frangioni, et al., First experience on laparoscopic near-infrared fluorescence imaging of hepatic uveal melanoma metastases using indocyanine green, *Surg. Innovat.* 22 (1) (2014 Feb) 20–25.
- [19] L. Vigano, A. Ferrero, M. Amisano, N. Russolillo, L. Capussotti, Comparison of laparoscopic and open intraoperative ultrasonography for staging liver tumours, *Br J Surg* 100 (4) (2013) 535–542, 2013/01/23.
- [20] R. Montalti, G. Berardi, A. Patrini, M. Vivarelli, R.I. Troisi, Outcomes of robotic vs laparoscopic hepatectomy: a systematic review and meta-analysis, *World J. Gastroenterol.* 21 (27) (2015 Jul) 8441–8451.
- [21] N.C. Buchs, F. Volonte, F. Pugin, C. Toso, P. Morel, Three-dimensional laparoscopy: a step toward advanced surgical navigation, *Surg Endosc Other Interv Tech* 27 (2) (2013) 692–693.
- [22] D.E. Azagury, M.M. Dua, J.C. Barrese, J.M. Henderson, N.C. Buchs, F. Ris, et al., Image-guided surgery, *Curr. Probl. Surg.* 52 (2015) 476–520.
- [23] T. Okamoto, S. Onda, K. Yanaga, N. Suzuki, A. Hattori, Clinical application of navigation surgery using augmented reality in hepatobiliary pancreatic surgery, *Surg. Today* 45 (4) (2015) 397–406.
- [24] R. Plantef eve, I. Peterlik, N. Haouchine, S. Cotin, Patient-specific biomechanical modeling for guidance during minimally-invasive hepatic surgery, *Ann. Biomed. Eng.* 44 (1) (2016 Jan) 139–153, 22.
- [25] S. Thompson, J. Totz, Y.Y. Song, S. Johnsen, D. Stoyanov, K. Gurusamy, et al., Accuracy validation of an image guided laparoscopy system for liver resection, *SPIE Proc* (7) (2015) 9415.
- [26] S. Satou, T. Mitsui, R. Ninomiya, M. Komagome, N. Akamatsu, F. Ozawa, et al., Image overlay navigation of laparoscopic liver resection, *Hepatol Int* 8 (2014) 1–405.
- [27] P. Pessaux, M. Diana, L. Soler, T. Piardi, D. Mutter, J. Marescaux, Towards cybernetic surgery: robotic and augmented reality-assisted liver segmentectomy, *Langenbeck's Arch. Surg.* 400 (3) (2014 Apr) 381–385.
- [28] C. Schneider, S. Thompson, M.J. Clarkson, D.J. Hawkes, B.R. Davidson, A novel approach to image guidance in laparoscopic liver surgery, *Surg. Endosc.* 20 (2015). Suppl 1.
- [29] M.R. Robu, P. Edwards, J. Ramalhinho, S. Thompson, B. Davidson, D. Hawkes, et al., Intelligent viewpoint selection for efficient CT to video registration in laparoscopic liver surgery, *Int J Comput Assist Radiol Surg* 12 (7) (2017 Jul) 1079–1088.
- [30] M. Fusaglia, M. Peterhans, D. Wallach, G. Beldi, D. Candinas, S. Weber, Validation of image overlay accuracy in a instrument guidance system for laparoscopic liver surgery, *Hpb (HPBA)* 2012) 14 (2012) 520.
- [31] M. Hayashibe, N. Suzuki, Y. Nakamura, Laser-scan endoscope system for intraoperative geometry acquisition and surgical robot safety management, *Med. Image Anal.* 10 (4) (2006 Aug) 509–519.
- [32] D. Stoyanov, Surgical vision, *Ann. Biomed. Eng.* 40 (2) (2012 Feb) 332–345.
- [33] D. Reichard, S. Bodenstedt, S. Suwelack, B. Mayer, A. Preukschas, M. Wagner, et al., Intraoperative on-the-fly organ-mosaicking for laparoscopic surgery, *J. Med. Imaging* 2 (4) (2015 Oct 10), 45001.
- [34] V.M. Banz, M. Baechtold, S. Weber, M. Peterhans, D. Inderbitzin, D. Candinas, Computer planned, image-guided combined resection and ablation for bilobar colorectal liver metastases, *World J. Gastroenterol.* 20 (40) (2014 Oct) 14992–14996, 28.
- [35] F. Volont e, F. Pugin, P. Bucher, M. Sugimoto, O. Ratib, P. Morel, Augmented reality and image overlay navigation with OsiriX in laparoscopic and robotic surgery: not only a matter of fashion, *J Hepatobiliary Pancreat Sci.* 18 (4) (2011 Jul) 506–509.
- [36] X. Kang, M. Azizian, E. Wilson, K. Wu, A.D. Martin, T.D. Kane, et al., Stereoscopic augmented reality for laparoscopic surgery, *Surg. Endosc.* 28 (7) (2014 Jul) 2227–2235.
- [37] S. Nicolau, L. Soler, D. Mutter, J. Marescaux, Augmented reality in laparoscopic surgical oncology, *Surg Oncol* 20 (3) (2011) 189–201.
- [38] A. Teatini, E. Pelanis, D.L. Aghayan, R.P. Kumar, R. Palomar,  .A. Fretland, et al., The effect of intraoperative imaging on surgical navigation for laparoscopic liver resection surgery, *Sci. Rep.* 9 (1) (2019 Dec) 18687, 10.
- [39] A. Teatini, J. P erez de Frutos, B. Eigel, E. Pelanis, D.L. Aghayan, M. Lai, et al., Influence of sampling accuracy on augmented reality for laparoscopic image-guided surgery, *Minim Invasive Ther. Allied Technol.* (2020) 1–10.
- [40] E. Gibson, M.R. Robu, S. Thompson, P.E. Edwards, C. Schneider, K. Gurusamy, et al., Deep residual networks for automatic segmentation of laparoscopic videos of the liver, in: R.J. Webster, B. Fei (Eds.), *Prog Biomed Opt Imaging - Proc SPIE*, vol. 10135, 2017 Mar, p. 101351M, 3.
- [41] N. Mahmoud, T. Collins, A. Hostettler, L. Soler, C. Doignon, J.M.M. Montiel, Live tracking and dense reconstruction for hand-held monocular endoscopy, *IEEE Trans. Med. Imag.* 38 (1) (2019 Jul) 79–89, 13.

- [42] P. Zhang, H. Luo, W. Zhu, J. Yang, N. Zeng, Y. Fan, et al., Real-time navigation for laparoscopic hepatectomy using image fusion of preoperative 3D surgical plan and intraoperative indocyanine green fluorescence imaging, *Surg. Endosc.* 34 (8) (2020) 3449–3459.
- [43] N. Haouchine, S. Cotin, I. Peterlik, J. Dequidt, E. Kerrien, M. Berger, et al., Impact of soft tissue heterogeneity on augmented reality for liver surgery, *IEEE Trans. Visual. Comput. Graph.* 21 (5) (2015 May) 584–597, 1.
- [44] M. Pfeiffer, C. Riediger, J. Weitz, S. Speidel, Learning soft tissue behavior of organs for surgical navigation with convolutional neural networks, *Int J Comput Assist Radiol Surg* (2019 Apr) 1–9, 16.
- [45] J.S. Heiselman, L.W. Clements, J.A. Collins, J.A. Weis, A.L. Simpson, S. K. Geevarghese, et al., Characterization and correction of intraoperative soft tissue deformation in image-guided laparoscopic liver surgery, *J. Med. Imaging* (2) (2018 Apr) 5, 021203.
- [46] R. Modrzejewski, T. Collins, B. Seeliger, A. Bartoli, A. Hostettler, J. Marescaux, An in vivo porcine dataset and evaluation methodology to measure soft-body laparoscopic liver registration accuracy with an extended algorithm that handles collisions, *Int J Comput Assist Radiol Surg* 14 (7) (2019 May) 1237–1245, <https://doi.org/10.1007/s11548-019-02001-4>.
- [47] D. Reichard, D. Häntsch, S. Bodenstedt, S. Suwelack, M. Wagner, H. Kenngott, et al., Projective biomechanical depth matching for soft tissue registration in laparoscopic surgery, *Int J Comput Assist Radiol Surg* 12 (7) (2017) 1101–1110.
- [48] L.R. Bertrand, M. Abdallah, Y. Espinel, L. Calvet, B. Pereira, E. Ozgur, et al., A case series study of augmented reality in laparoscopic liver resection with a deformable preoperative model, *Surg. Endosc.* 34 (12) (2020) 5642–5648.
- [49] J.S. Heiselman, L.W. Clements, J.A. Collins, J.A. Weis, A.L. Simpson, S. K. Geevarghese, et al., Characterization and correction of intraoperative soft tissue deformation in image-guided laparoscopic liver surgery, *J. Med. Imaging* (Bellingham, Wash) (2) (2018 Apr) 5, 021203.
- [50] L.W. Lau, X. Liu, W. Plishker, K. Sharma, R. Shekhar, T.D. Kane, Laparoscopic liver resection with augmented reality: a preclinical experience, *J. Laparoendosc. Adv. Surg. Tech.* 29 (1) (2019 Jan) 88–93.
- [51] T. Aoki, M. Murakami, T. Koizumi, A. Fujimori, Y. Enami, T. Kusano, et al., Ultrasound with electromagnetic tracking navigation and image fusion system in laparoscopic liver surgery: an initial clinical experience, *Am. Surg.* 82 (12) (2016 Dec) e366–368, 1.
- [52] D. Sindram, K.A. Simo, R.Z. Swan, S. Razzaque, D.J. Niemeyer, R.M. Seshadri, et al., Laparoscopic microwave ablation of human liver tumours using a novel three-dimensional magnetic guidance system, *HPB* 17 (1) (2015 Jan) 87–93.
- [53] Y. Song, J. Totz, S. Thompson, S. Johnsen, D. Barratt, C. Schneider, et al., Locally rigid, vessel-based registration for laparoscopic liver surgery, *Int J Comput Assist Radiol Surg* 10 (12) (2015 Dec) 1951–1961.
- [54] M. Feuerstein, T. Mussack, S.M. Heining, N. Navab, Intraoperative laparoscope augmentation for port placement and resection planning in minimally invasive liver resection, *IEEE Trans. Med. Imag.* 27 (3) (2008 Mar) 355–369.
- [55] R. Shekhar, O. Dandekar, V. Bhat, M. Philip, P. Lei, C. Godinez, et al., Live augmented reality: a new visualization method for laparoscopic surgery using continuous volumetric computed tomography, *Surg Endosc Other Interv Tech* 24 (8) (2010 Aug) 1976–1985.
- [56] H.G. Kenngott, M. Wagner, M. Gondan, F. Nickel, M. Nolden, A. Fetzer, et al., Real-time image guidance in laparoscopic liver surgery: first clinical experience with a guidance system based on intraoperative CT imaging, *Surg. Endosc.* 28 (3) (2014 Mar) 933–940.
- [57] S.S. Chopra, J. Rump, S.C. Schmidt, F. Streitharth, C. Seebauer, G. Schumacher, et al., Imaging sequences for intraoperative MR-guided laparoscopic liver resection in 1.0-T high field open MRI, *Eur. Radiol.* 19 (9) (2009 Sep) 2191–2196.
- [58] K. Murakami, S. Naka, H. Shiomi, H. Akabori, Y. Kurumi, S. Morikawa, et al., Initial experiences with MR image-guided laparoscopic microwave coagulation therapy for hepatic tumors, *Surg. Today* 45 (9) (2015 Sep) 1173–1178.
- [59] K. Konishi, M. Nakamoto, Y. Kakeji, K. Tanoue, H. Kawanaka, S. Yamaguchi, et al., A real-time navigation system for laparoscopic surgery based on three-dimensional ultrasound using magneto-optic hybrid tracking configuration, *Int J Comput Assist Radiol Surg* 2 (1) (2007) 1–10.
- [60] J. Ramalhinho, M.R. Robu, S. Thompson, K. Gurusamy, B. Davidson, D. Hawkes, et al., A pre-operative planning framework for global registration of laparoscopic ultrasound to CT images, *Int J Comput Assist Radiol Surg* 13 (8) (2018 Aug) 1177–1186, 2.
- [61] H. Luo, D. Yin, S. Zhang, D. Xiao, B. He, F. Meng, et al., Augmented reality navigation for liver resection with a stereoscopic laparoscope, *Comput. Methods Progr. Biomed.* (2019 Oct) 105099, 7.
- [62] X. Liu, W. Plishker, T.D. Kane, D.A. Geller, L.W. Lau, J. Tashiro, et al., Preclinical evaluation of ultrasound-augmented needle navigation for laparoscopic liver ablation, *Int J Comput Assist Radiol Surg* 15 (5) (2020) 803–810.
- [63] C.W. Hammill, L.W. Clements, J.D. Stefansic, R.F. Wolf, P.D. Hansen, D.A. Gerber, Evaluation of a minimally invasive image-guided surgery system for hepatic ablation procedures, *Surg. Innovat.* 21 (4) (2014 Aug) 419–426.
- [64] T. Huber, J. Baumgart, M. Peterhans, S. Weber, S. Heinrich, H. Lang, et al., [Computer-assisted 3D-navigated laparoscopic resection of a vanished colorectal liver metastasis after chemotherapy], *Zeitschrift für Gastroenterol* 54 (1) (2016 Jan) 40–43.
- [65] C. Schneider, S. Thompson, Y. Song, J. Totz, A. Desjardins, K. Gurusamy, et al., Preliminary results from a clinical study evaluating a novel image guidance system for laparoscopic liver surgery, *7, HPB* 18 (2017 Jun) e99. Conference Publication.
- [66] C. Conrad, M. Fusaglia, M. Peterhans, H. Lu, S. Weber, B. Gayet, Augmented reality navigation surgery facilitates laparoscopic rescue of failed portal vein embolization, *J. Am. Coll. Surg.* 223 (4) (2016) e31–e34.
- [67] P. Tinguely, M. Fusaglia, J. Freedman, V. Banz, S. Weber, D. Candinas, et al., Laparoscopic image-based navigation for microwave ablation of liver tumors — a multi-center study, *Surg. Endosc.* 31 (10) (2017) 4315–4324.
- [68] P. Phutane, E. Buc, K. Poirot, E. Ozgur, D. Pezet, A. Bartoli, et al., Preliminary trial of augmented reality performed on a laparoscopic left hepatectomy, *Surg Endosc Other Interv Tech* 32 (1) (2018) 514–515.
- [69] M.R. Robu, J. Ramalhinho, S. Thompson, K. Gurusamy, B. Davidson, D. Hawkes, et al., Global rigid registration of CT to video in laparoscopic liver surgery, *Int J Comput Assist Radiol Surg* 13 (6) (2018 Jun) 947–956.
- [70] S. Thompson, C. Schneider, M. Bosi, K. Gurusamy, S. Ourselin, B. Davidson, et al., In vivo estimation of target registration errors during augmented reality laparoscopic surgery, *Int J Comput Assist Radiol Surg* 13 (6) (2018 Jun) 865–874.
- [71] M. Beermann, J. Lindeberg, J. Engstrand, K. Galmén, S. Karlgren, D. Stillström, et al., 1000 consecutive ablation sessions in the era of computer assisted image guidance - lessons learned, *Eur J Radiol open* 6 (2019) 1–8.
- [72] B. Le Roy, E. Ozgur, B. Koo, E. Buc, A. Bartoli, Augmented reality guidance in laparoscopic hepatectomy with deformable semi-automatic computed tomography alignment (with video), *J. Vis. Surg.* 156 (3) (2019 Feb) 261–262, <https://doi.org/10.1016/j.jvisurg.2019.01.009>.
- [73] J. Yasuda, T. Okamoto, S. Onda, S. Fujioka, K. Yanaga, N. Suzuki, et al., Application of image-guided navigation system for laparoscopic hepatobiliary surgery, *Asian J. Endosc. Surg.* 13 (1) (2019 Apr) 39–45, <https://doi.org/10.1111/ases.12696>.
- [74] G.A. Prevost, B. Eigl, I. Paolucci, T. Rudolph, M. Peterhans, S. Weber, et al., Efficiency, accuracy and clinical applicability of a new image-guided surgery system in 3D laparoscopic liver surgery, *J. Gastrointest. Surg.* 24 (10) (2019 Oct) 2251–2258, <https://doi.org/10.1007/s11605-019-04395-7>.
- [75] C. Schneider, S. Thompson, J. Totz, Y. Song, M. Allam, M.H. Sodergren, et al., Comparison of manual and semi-automatic registration in augmented reality image-guided liver surgery: a clinical feasibility study, *Surg. Endosc.* 34 (10) (2020 Oct) 4702–4711, 1.
- [76] T. Aoki, D.A. Mansour, T. Koizumi, Y. Wada, Y. Enami, A. Fujimori, et al., Laparoscopic liver surgery guided by virtual real-time CT-guided volume navigation, *J. Gastrointest. Surg.* (2020) 1–5.
- [77] T. Aoki, T. Koizumi, M. Sugimoto, M. Murakami, Holography-guided percutaneous puncture technique for selective near-infrared fluorescence-guided laparoscopic liver resection using mixed-reality wearable spatial computer, *Surg Oncol* 35 (October) (2020) 476–477.
- [78] C. Schneider, S. Thompson, K. Gurusamy, M. Clarkson, B. Davidson, Use of enhanced visualisation methods to decrease the effect of organ motion in image guided laparoscopic liver surgery, *Br. J. Surg.* 104 (2017 Jul) 5–243. Suppl(ASGBI Abstracts 2017).
- [79] Y. Uchida, K. Taura, M. Nakao, S. Uemoto, A clinical pilot study of Resection Process Map: a novel virtual hepatocystomy software to visualize the resection process, case series, *Int. J. Surg.* 71 (2019 Nov) 36–40, 1.
- [80] L. Maier-Hein, P. Mounthey, A. Bartoli, H. Elhawary, D. Elson, Groch a, et al., Optical techniques for 3D surface reconstruction in computer-assisted laparoscopic surgery, *Med. Image Anal.* 17 (8) (2013) 974–996.
- [81] B. Tekin, S.N. Sinha, P. Fua, Real-time seamless single shot 6D object pose prediction. In: proceedings of the IEEE computer society conference on computer vision and pattern recognition, IEEE Computer Society (2018) 292–301.
- [82] M. Zijlmans, T. Langø, E.F. Hofstad, C.F.P. Van Swol, A. Rethy, Navigated laparoscopy – liver shift and deformation due to pneumoperitoneum in an animal model, *Minim Invasive Ther. Allied Technol.* 21 (3) (2012 May) 241–248.
- [83] V. Packiam, D.L. Bartlett, S. Tohme, S. Reddy, J.W. Marsh, D.A. Geller, et al., Minimally invasive liver resection: robotic versus laparoscopic left lateral sectionectomy, *J. Gastrointest. Surg.* 16 (12) (2012 Dec) 2233–2238.
- [84] C.M. Ho, G. Wakabayashi, H. Nitta, N. Ito, Y. Hasegawa, T. Takahara, Systematic review of robotic liver resection, *Surg Endosc Other Interv Tech* 27 (3) (2013 Mar) 732–739.
- [85] S.S. Chopra, S.C. Schmidt, R. Eisele, U. Teichgräber, I. Van Der Voort, C. Seebauer, et al., Initial results of MR-guided liver resection in a high-field open MRI, *Surg Endosc Other Interv Tech* 24 (10) (2010) 2506–2512.