

# Journal of Neurology

## Key emerging issues in fronto-temporal dementia

--Manuscript Draft--

<b>Manuscript Number:</b>	JOON-D-15-01086
<b>Full Title:</b>	Key emerging issues in fronto-temporal dementia
<b>Article Type:</b>	Neurological Update
<b>Corresponding Author:</b>	Dennis Chan  UNITED STATES
<b>Corresponding Author Secondary Information:</b>	
<b>Corresponding Author's Institution:</b>	
<b>Corresponding Author's Secondary Institution:</b>	
<b>Corresponding Author E-Mail:</b>	dc598@cam.ac.uk
<b>First Author:</b>	Dennis Chan
<b>First Author Secondary Information:</b>	
<b>Order of Authors:</b>	Dennis Chan  Sarah Hopkins
<b>Order of Authors Secondary Information:</b>	
<b>Funding Information:</b>	
<b>Abstract:</b>	<p>Frontotemporal dementia (FTD) encompasses the syndromes of behavioural variant FTD (bvFTD) and primary progressive aphasia (PPA) and refers to those neurodegenerative diseases characterised by predominant pathological involvement of the frontal and temporal lobes. Recent years have witnessed major advances in the clinical characterisation of FTD, reflected in the publication of updated diagnostic criteria for bvFTD and PPA, and the discovery of new pathogenic mutations has added to the understanding of genotype-phenotype interactions and of disease mechanisms. Emerging results from longitudinal studies of familial FTD show that imaging and cognitive changes occur years before symptom onset and such studies may yield biomarkers of early disease that in turn will facilitate earlier diagnosis. The hope and (guarded) expectation is that these advances may together herald the beginning of the end of the chapter in which FTD is considered an inexorably progressive and untreatable condition.</p>
<b>Suggested Reviewers:</b>	
<b>Author Comments:</b>	

## Key emerging issues in fronto-temporal dementia

Sarah Hopkins<sup>1</sup>, Dennis Chan<sup>2</sup>

<sup>1</sup>Department of Medicine for the Elderly, Addenbrooke's Hospital, Cambridge

<sup>2</sup>Department of Clinical Neurosciences, University of Cambridge

Corresponding Author:

Dr Dennis Chan  
Herchel Smith Building for Brain and Mind Sciences  
University of Cambridge  
Forvie Site, Robinson Way  
Cambridge CB2 0SZ  
Email: [dc598@cam.ac.uk](mailto:dc598@cam.ac.uk)

Conflict of interest: none

Abstract word count: 141

Word count: 2333

Figures: 1

### Summary

Frontotemporal dementia (FTD) encompasses the syndromes of behavioural variant FTD (bvFTD) and primary progressive aphasia (PPA) and refers to those neurodegenerative diseases characterised by predominant pathological involvement of the frontal and temporal lobes. Recent years have witnessed major advances in the clinical characterisation of FTD, reflected in the publication of updated diagnostic criteria for bvFTD and PPA, and the discovery of new pathogenic mutations has added to the understanding of genotype-phenotype interactions and of disease mechanisms. Emerging results from longitudinal studies of familial FTD show that imaging and cognitive changes occur years before symptom onset and such studies may yield biomarkers of early disease that in turn will facilitate earlier diagnosis.

The hope and (guarded) expectation is that these advances may together herald the beginning of the end of the chapter in which FTD is considered an inexorably progressive and untreatable condition.

**Key words:** Frontotemporal dementia; diagnostic criteria; cognition; biomarkers; genetics

## 1. Introduction

Frontotemporal dementia (FTD) is a term encompassing a variety of clinical syndromes which collectively are characterised by dysfunction, atrophy and/or hypometabolism of the frontal and temporal lobes. The neurodegeneration underlying FTD results from heterogeneous molecular pathologies, unified under the umbrella pathological term “frontotemporal lobar degeneration” (FTLD). This article will review the progress made in the field of FTD over the last few years, such as the publication of new consensus diagnostic criteria and the identification of new pathogenic mutations. Preclinical studies of FTD, such as the recent work on novel mouse models of FTD, will not be covered in this review.

## 2. Nosology and diagnosis

The previous 1998 Neary *et al.* criteria [1] described three syndromic variants associated with FTLD (frontotemporal dementia, progressive non-fluent aphasia and semantic dementia). By comparison, the current clinical classifications which divide FTD into two main syndromes: behavioural variant frontotemporal dementia (bvFTD) and primary progressive aphasia (PPA), with the latter further divided into subtypes on the basis of differences in the nature of the speech and language disorder [2]. In addition to these revised classifications, the clinical diagnostic categorisation has expanded to encompass the idea of an overlap syndrome between FTD and amyotrophic lateral sclerosis (ALS), given the identification of shared pathogenic mutations [3, 4], ALS-type motor abnormalities in 14% of FTD patients [5], and symptoms of FTD in 15-18% of ALS patients [6].

FTD has long been considered primarily a young onset dementia. However, this has recently been cast into question, with 48% of FTD patients found to be aged 65 years or older at presentation [8].

The underlying FTLD pathology can be divided into three main groups based on the predominant intracellular protein aggregate: FTLD-tau, FTLD-TDP and FTLD-FUS [7]. In addition to FTD these pathologies are also found to underlie corticobasal syndrome and progressive supranuclear palsy. The clinicopathological correlation between FTD and FTLD is variable; for example, there is a correlation between FTD with ALS and FTLD-TDP, and between semantic variant PPA and FTLD-TDP, whereas by comparison bvFTD does not correlate with any particular neuropathological subtype [7]. Certain pathogenic mutations are also associated with particular pathologies, notably between MAPT mutations and FTLD-tau pathology, and between C9orf72 hexanucleotide repeat expansions and FTLD-TDP pathology (see section 4 for more details).

### 2.1. Behavioural variant FTD (bvFTD)

The 2011 revised international consensus criteria for bvFTD [9] classify the disease as

possible bvFTD (as diagnosed on the basis of behavioural and cognitive symptoms supported by neuropsychological findings), *probable* bvFTD (possible bvFTD AND functional decline and imaging changes in the form of frontal and/or anterior temporal lobe atrophy/hypometabolism/hypoperfusion), or *definite* bvFTD (possible or probable FTD AND either histopathological evidence of FTLN or a confirmed pathogenic mutation). These criteria are outlined in full in Table 1 (below):

**Table 1:** International consensus criteria for behavioural variant FTD (FTDC) (adapted from Rascovsky et al. [9]).

<p><b>Possible bvFTD</b></p> <p><b>At least three of the following clinical features:</b></p> <p>Early* behavioural disinhibition (socially inappropriate behaviour OR loss of manners or decorum OR impulsive, rash or careless actions)</p> <p>Early apathy or inertia</p> <p>Early loss of sympathy or empathy (diminished response to other people's needs and feelings OR diminished social interest, interrelatedness or personal warmth)</p> <p>Early perseverative, stereotyped or compulsive/ritualistic behaviour (simple repetitive movements OR complex, compulsive or ritualistic behaviours OR stereotypy of speech)</p> <p>Hyperorality and dietary changes (altered food preferences OR binge eating, increased consumption of alcohol or cigarettes OR oral exploration or consumption of inedible objects)</p> <p>Neuropsychological profile: executive/generation deficits with relative sparing of memory and visuospatial functions (deficits in executive tasks AND relative sparing of episodic memory AND relative sparing of visuospatial skills)</p>
<p><b>Probable bvFTD</b></p> <p><b>Meets criteria for possible bvFTD and both of:</b></p> <p>Significant functional decline (by caregiver report or as evidenced by Clinical Dementia Rating Scale or Functional Activities Questionnaire scores)</p> <p>Imaging results consistent with bvFTD (frontal and/or anterior temporal atrophy on MRI or CT OR frontal and/or anterior temporal hypoperfusion or hypometabolism on PET or SPECT)</p>
<p><b>bvFTD with definite FTLN Pathology</b></p> <p><b>Meets criteria for possible or probable bvFTD and one of:</b></p> <p>Histopathological evidence of FTLN on biopsy or at post-mortem</p> <p>Presence of a known pathogenic mutation</p>
<p><b>Exclusionary criteria for bvFTD</b></p> <p><b>The following must be negative for any bvFTD diagnosis:</b></p> <p>Pattern of deficits is better accounted for by other non-degenerative nervous system or medical disorders</p>

Behavioural disturbance is better accounted for by a psychiatric diagnosis

**The following can be positive for possible bvFTD but must be negative for probable bvFTD:**

Biomarkers strongly indicative of Alzheimer's disease or other neurodegenerative process

\*Early refers to symptom presentation within the first 3 years

The validity of these new bvFTD criteria has been assessed with a clinicopathological brain bank-based study of diagnostic sensitivity. Of 137 pathologically confirmed cases, 86% met criteria for possible bvFTD and 76% for probable bvFTD, representing a significant improvement in sensitivity compared to previous criteria [9]. A subsequent retrospective series looking at presenting features of pathologically confirmed cases found high sensitivity and specificity (possible FTD: sensitivity 95% for specificity 92%; probable FTD: sensitivity 85% for specificity 95%)[10].

Despite these revised criteria, accurate clinical diagnosis of bvFTD can remain challenging and can be hard to distinguish from two particular disorders on clinical grounds alone. The first of these is "bvFTD phenocopy syndrome" [11]. Patients with this syndrome exhibit the clinical features of bvFTD (and would thus fulfil criteria for the diagnosis of *possible* bvFTD) but fail to show progressive functional decline, neuroimaging changes or neuropathological changes consistent with FTLD, and have a much better prognosis. The cause of bvFTD phenocopy syndrome is unclear, but this is likely to be heterogeneous and in some instances may be representative of a decompensated personality disorder or subclinical autism spectrum disorder [11]. However, comprehensive neuropsychiatric and neuropsychological profiling may help differentiate bvFTD and bvFTD phenocopy syndrome and the need for caution in attributing the latter diagnosis is underscored by the observation that two (related) cases diagnosed independently with phenocopy syndrome were found to tested positive for c9orf72 [12].

The second diagnosis that can be confused with bvFTD is "frontal" or "behavioural/dysexecutive" variant of Alzheimer's disease (AD), representing one of three non-amnesic variants of AD specified in the updated AD diagnostic criteria [13]. In contrast to the typical AD presentation with memory impairment, the cognitive impairment in this instance is manifest primarily as impaired reasoning, judgment, and problem solving. The difficulty of distinguishing clinically between bvFTD and behavioural/dysexecutive variant AD is illustrated by a study showing that 52% of patients with pathologically- or biomarker-confirmed AD who presented with a behavioural or dysexecutive-predominant presentation met current criteria for possible bvFTD [14]. However, despite clinical similarities, these patients have different patterns of atrophy to bvFTD patients, with marked bilateral temporoparietal atrophy and limited frontal lobe atrophy [14].

## 2.2. Primary progressive aphasia (PPA)

PPA is characterised by the progressive impairment of speech production, naming, syntax and/or word comprehension with initial relative preservation of other cognitive functions,

and current diagnostic criteria are based on those described by Mesulam [15]. In 2011, consensus diagnostic criteria for PPA subtypes were published for the first time and these divide PPA into three groups: semantic variant PPA (svPPA), nonfluent variant PPA (nfvPPA) and logopenic variant PPA (lvPPA) [2]. When compared with the FTD syndromic variants described in the 1998 Neary *et al.* criteria [1], svPPA and nfvPPA are considered to be broadly analogous to “semantic dementia” and “progressive non-fluent aphasia”. However this concordance is not exact, as exemplified by a retrospective case series which found 51% of cases previously diagnosed as progressive non-fluent aphasia were reclassified as lvPPA rather than nfvPPA [16]. Research into clinicopathological correlations has found that the most common pathology in patients clinically diagnosed with lvPPA was AD [16, 17] and lvPPA is now considered an AD, rather than FTD, subtype.

**Table 2:** Diagnostic criteria for nfvPPA and svPPA (adapted from Gorno-Tempini et al. [2]).

nfvPPA	svPPA
<b>Clinical diagnosis</b>	
<b>At least one of the following core features:</b>	<b>Both of the following core features:</b>
Agrammatism in language production	Impaired confrontation naming
Apraxic speech (effortful, halting speech with sound errors)	Impaired single word comprehension
<b>At least 2 of 3 of the following other features:</b>	<b>At least 3 of 4 of the following other features:</b>
Impaired comprehension of syntactically complex sentences	Impaired object knowledge, particularly for low frequency items
Spared single word comprehension	Surface dyslexia or dysgraphia
Spared object knowledge	Spared repetition
Spared speech production (grammar and motor speech)	
<b>Imaging-supported diagnosis clinical diagnosis plus at least one of:</b>	
Predominant left posterior fronto-insular atrophy on MRI	Predominant anterior temporal lobe atrophy
Predominant left posterior fronto-insular hypoperfusion or hypometabolism on SPECT or PET	Predominant anterior temporal lobe hypoperfusion or hypometabolism on SPECT or PET
<b>Definite pathology Clinical diagnosis plus one of:</b>	
Histopathological evidence of a specific neurodegenerative pathology (e.g. FTLD-tau, FTLD-TDP, AD, other)	
Presence of a known pathogenic mutation	

1 Some questions persist about the ability of these proposed PPA subtypes to encompass  
2 all presentations with progressive aphasia, with Sajjadi et al. [18] noting that 41% of 46  
3 patients with PPA did not meet diagnostic criteria for any of the three PPA subtypes.  
4

### 5 **2.3. “Right temporal” FTD**

6 One anatomical variant of FTD not fully captured by the reformulated bvFTD and PPA  
7 clinical classifications is that in which pathology predominantly affects the right temporal  
8 lobe. This has been variously described as “right temporal variant FTD” [19, 20] and “right  
9 temporal lobe atrophy” [21]. Two clinical subtypes of “right temporal FTD” have been  
10 described to date. Patients with “right temporal” bvFTD typically present with behavioural  
11 disorders and personality change, with additional frontal lobe atrophy. In these cases tau is  
12 the predominant pathology. By comparison, patients with “right temporal” semantic  
13 dementia [sic] exhibit topographical disorientation, prosopagnosia and impaired word  
14 comprehension, with minimal frontal lobe atrophy and TDP-43 as the main underlying  
15 pathology [22].  
16

## 17 **3. Cognition**

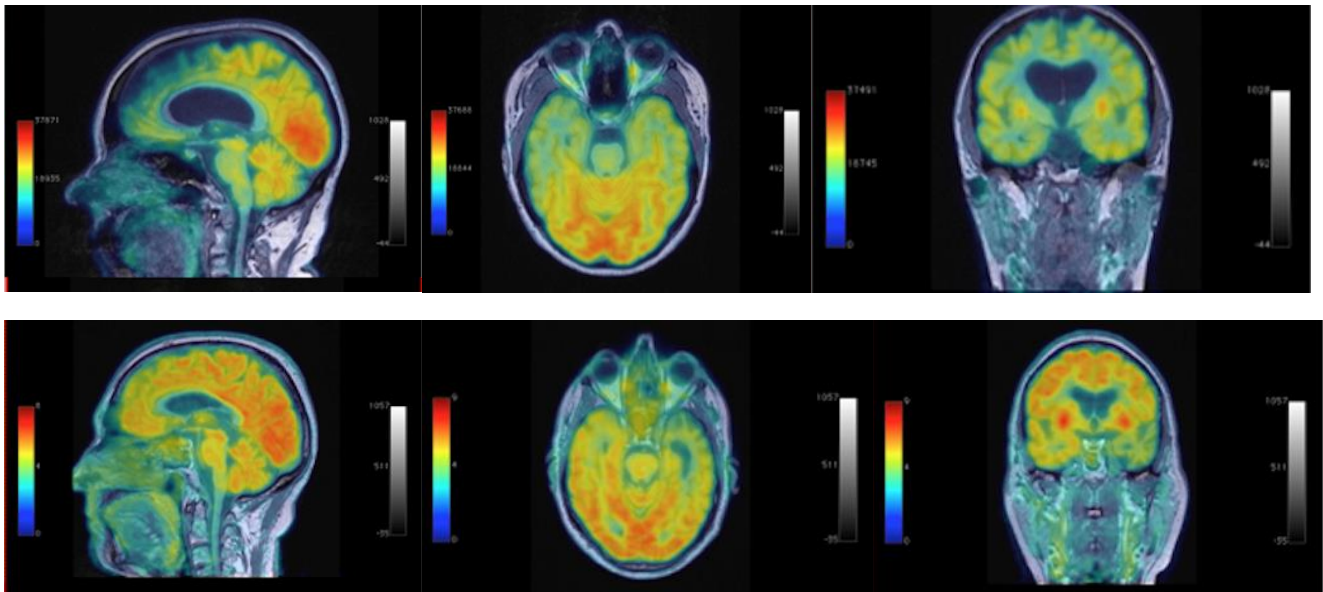
18 Outside of the dysexecutive syndrome and the disruption of speech and language that are  
19 central to the cognitive profiles of bvFTD and PPA respectively, significant recent attention  
20 has been devoted to the nature of memory deficits in these disorders. Episodic memory is  
21 considered to be relatively preserved in bvFTD (and in fact is one of the diagnostic criteria)  
22 but there is evidence to suggest that it is similarly impaired in both AD and bvFTD [23],  
23 possibly as a result of anterior hippocampal involvement in bvFTD, and that the previously  
24 reported preservation of episodic memory may reflect in part the incorrect inclusion of  
25 patients with bvFTD phenocopy [24]. By comparison, allocentric spatial memory and  
26 spatial orientation are relatively preserved in bvFTD but impaired in AD [25, 26], likely  
27 reflecting the sparing of the precuneus and posterior hippocampus in bvFTD, and this  
28 information may help in the differential diagnosis of these disorders.  
29

30 Emerging information on the initial cognitive changes in FTD are being obtained from the  
31 GENFI study (GENetic FTD Initiative) which has shown impairment on tests of executive  
32 function and naming five years prior to anticipated symptom onset [27].  
33

## 34 **4. Imaging**

35 FTD variants are characterised by imaging changes affecting the frontal and/or temporal  
36 lobes in the form of atrophy, hypometabolism and hypoperfusion and such imaging  
37 abnormalities are listed within the diagnostic criteria for both bvFTD and PPA. In familial  
38 FTD, the onset of atrophy significantly predates symptoms, with mutation carriers found to  
39 have significant reduction in insular and temporal lobe volume 10 years prior to anticipated  
40 symptom onset [27].  
41





**Figure 1**

Simultaneously acquired PET-MRI scans in sagittal (left), axial (middle) and coronal (right) sections. Top panel: behavioural variant FTD. Atrophy and hypometabolism are maximal in the frontal and anterior temporal lobes bilaterally. Bottom panel: semantic variant PPA. Atrophy and hypometabolism are maximal in the left temporal lobe.

Much of the more recent imaging research in FTD has focused on determination of changes in brain structural and functional connectivity. Diffusion tensor imaging has shown progressive disruption of white matter tracts in all FTD subtypes [28, 29], with reduced tract integrity correlating with symptom progression [30]. The observation that white matter pathways are impaired in presymptomatic mutation carriers indicates that disruption of structural connectivity is an early feature of FTD [31, 32].

Resting state (“task-free”) functional MRI studies have found that FTD syndromes are associated with disruption of different functional brain networks [33]. In bvFTD there is reduced functional connectivity within the frontal lobe-predominant network considered to underpin emotional salience [34, 35]. Changes in nonfluent variant PPA are found within a predominantly left-hemisphere network encompassing the frontal operculum, supplementary motor cortex and inferior parietal lobule, consistent with the complementary roles of these brain regions in the generation of fluent speech, whereas the functional brain network implicated in semantic variant PPA involves the temporal poles, ventral striatum and amygdala [33].

## 5. CSF biomarkers

Testing of CSF is not currently used in routine clinical practice to diagnose FTD although analysis of CSF AD biomarkers ( $A\beta_{1-42}$  and tau) can help differentiate AD from FTD, with CSF  $A\beta_{1-42}$  associated with a sensitivity of 77% for diagnosing AD against FTD for a specificity of 95% [36].



CSF neurofilament light chain (NfL) levels may represent a possible future biomarker of FTD. These have been found to be significantly higher in FTD than AD or controls and levels correlate with performance on neuropsychological tests and with frontal/temporal atrophy [37], although their sensitivity and specificity remain to be determined. NfL levels have recently been shown to distinguish ALS and controls with a high level of sensitivity and specificity and to be a strong independent predictor of survival [38], and this may have relevance for FTD given the neuropathological overlap between ALS and FTD.

## 6. Genetics and molecular pathology

Approximately 40% of FTD patients have a positive family history of disease [39], and 10-25% of family pedigrees are associated with an autosomal dominant pattern of inheritance [40, 41]. The commonest pathogenic mutations in FTD affect the *C9orf72*, *MAPT* and *GRN* genes, which together account for 10-20% of all FTD cases [42].

Arguably the most important recent advance in the field of FTD genetics is the discovery that an abnormal expansion of a hexanucleotide repeat in the *C9orf72* gene accounts for 25% of familial and 6% of sporadic FTD cases [43–45] and also accounts for 30-50% and 5-7% of familial and sporadic ALS respectively [44]. Other less frequent mutations common to both FTD and ALS have been found, such as mutations in the *VCP* and *CHCHD10* genes (see Table 3). TDP-43 positive inclusions are found in the CNS of patients with both ALS and FTD [46].

**Table 3:** Genes associated with FTD (adapted from Guerreiro et al. [3])

<b>Mendelian genes</b>			
<b>FTD</b>	<b>Possible pathway</b>	<b>FTD/ALS</b>	<b>Possible pathway</b>
MAPT	Toxic aggregation (defect in neuronal cytoskeleton)	C9orf72	Toxic RNA or repeat dipeptides aggregation
GRN	Autophagy; lysosomal pathway; inflammation	SQSTM1	Autophagy
CHMP2B	Autophagy; lysosomal pathway	UBQLN2	Autophagy
TREM2	Inflammation	VCP	Autophagy
PRKAR1B	Regulation of metabolism, ion transport, and gene transcription	OPTN	Autophagy
		CHCHD10	Mitochondrial function
		HNRNPA1	RNA metabolism; direct interaction with TDP-43
		HNRNPA2B1	RNA metabolism; direct interaction with TDP-43
		SIGMAR1	Endoplasmic reticulum lipid rafts
<b>Examples of risk modifier genes</b>			
TMEM106B	Regulation of lysosomal function and progranulin pathways	ATXN2	Modifier of TDP-43 toxicity

Several genetic variants have been shown to modify disease risk or disease phenotype and patients carrying variants in more than one gene have been described. This has led to the oligogenic hypothesis which postulates that the presence of various mutations can modify the phenotype (e.g. presence of motor features/cognitive impairment) and clinical features such as survival and age of onset [4]. This is exemplified by the presence of the *TMEM106B* rs1990622 major allele which, in FTD patients with *C9orf72* mutations, correlates with later age of disease onset and later age of death [47].

## 7. Treatments and current trials

There are no disease-modifying treatments for FTD and the mainstay of management remains non-pharmacological care [48]. However, a small open-label study using citalopram to treat behavioural disturbance did find a significant improvement on measures of disinhibition, irritability and depression [49].

A phase III study of a tau aggregation inhibitor is currently under way and is expected to report results in 2016 [50].

## 8. Conclusions

There have been significant recent advances in understanding the FTD syndromes and these are reflected in the publication of new diagnostic criteria for bvFTD and PPA subtypes. While an improvement on previous criteria, these remain work in progress and future studies will undoubtedly seek to address the current outstanding diagnostic challenges outlined in this review article. Ongoing and future work into molecular genetics and neuroimaging will aid in the phenotyping of FTD, and the planned further study of pre-symptomatic mutation carriers, within programmes such as GENFI2, will hopefully deliver new biomarkers of early disease.

Sadly, progress in developing disease-modifying drugs for the treatment of FTD remains slow. However, these advances in clinical understanding, when combined with developments in systems biology research into disease mechanisms, will provide a more robust framework for experimental medicine and, from there, the delivery of effective treatments for FTD.

## Acknowledgements

Dr Chan is funded by the Cambridge NIHR Biomedical Research Centre and receives grant income from the UK Medical Research Council, sTechnology Strategy Board and the Cambridge Isaac Newton Trust.

The images shown in Figure 1 were acquired by Dr Kuven Moodley, Brighton and Sussex Medical School, on the integrated PET-MRI scanner at the Institute of Nuclear Medicine, University College London, UK.

Table 1 was reproduced with permission of Oxford University Press. Table 3 was reproduced with permission of Elsevier.

## References

1. Neary D, Snowden JS, Gustafson L, et al. (1998) Frontotemporal lobar degeneration: a consensus on clinical diagnostic criteria. *Neurology* 51:1546–1554.
2. Gorno-Tempini ML, Hillis AE, Weintraub S, et al. (2011) Classification of primary progressive aphasia and its variants. *Neurology* 76:1006–1014. doi: 10.1212/WNL.0b013e31821103e6
3. Guerreiro R, Brás J, Hardy J (2015) SnapShot : Genetics of ALS and FTD SnapShot : Genetics of ALS and FTD. *Cell* 160:798–798.e1. doi: 10.1016/j.cell.2015.01.052
4. Lattante S, Ciura S, Rouleau G a., Kabashi E (2015) Defining the genetic connection linking amyotrophic lateral sclerosis (ALS) with frontotemporal dementia (FTD). *Trends Genet* 31:263–273. doi: 10.1016/j.tig.2015.03.005
5. Lomen-Hoerth C, Anderson T, Miller B (2002) The overlap of amyotrophic lateral sclerosis and frontotemporal dementia. *Neurology* 59:1077–1079.
6. Ringholz GM, Appel SH, Bradshaw M, et al. (2005) Prevalence and patterns of cognitive impairment in sporadic ALS. *Neurology* 65:586–590. doi: 10.1212/01.wnl.0000172911.39167.b6
7. Josephs KA, Hodges JR, Snowden JS, et al. (2011) Neuropathological background of phenotypical variability in frontotemporal dementia. *Acta Neuropathol* 122:137–153. doi: 10.1007/s00401-011-0839-6
8. Ye BS, Choi SH, Han S-H, et al. (2015) Clinical and Neuropsychological Comparisons of Early-Onset Versus Late-Onset Frontotemporal Dementia: A CREDOS-FTD Study. *J Alzheimers Dis* 45:599–608. doi: 10.3233/JAD-141044
9. Rascovsky K, Hodges JR, Knopman D, et al. (2011) Sensitivity of revised diagnostic criteria for the behavioural variant of frontotemporal dementia. *Brain* 134:2456–2477. doi: 10.1093/brain/awr179
10. Harris JM, Gall C, Thompson JC, et al. (2013) Sensitivity and specificity of FTDC criteria for behavioral variant frontotemporal dementia. *Neurology* 80:1881–1887. doi: 10.1212/WNL.0b013e318292a342
11. Kipps CM, Hodges JR, Hornberger M (2010) Nonprogressive behavioural frontotemporal dementia: recent developments and clinical implications of the “bvFTD phenocopy syndrome”. *Curr Opin Neurol* 23:628–632. doi: 10.1097/WCO.0b013e3283404309
12. Khan BK, Yokoyama JS, Takada LT, et al. (2012) Atypical, slowly progressive behavioural variant frontotemporal dementia associated with C9ORF72 hexanucleotide expansion. *J Neurol Neurosurg Psychiatry* 83:358–364. doi: 10.1136/jnnp-2011-301883
13. McKhann GM, Knopman DS, Chertkow H, et al. (2011) The diagnosis of dementia due to Alzheimer’s disease: recommendations from the National Institute on Aging-Alzheimer’s Association workgroups on diagnostic guidelines for Alzheimer’s disease. *Alzheimers Dement* 7:263–269. doi: 10.1016/j.jalz.2011.03.005
14. Ossenkoppele R, Pijnenburg YAL, Perry DC, et al. (2015) The behavioural/dysexecutive variant of Alzheimer’s disease: clinical, neuroimaging and pathological features. *Brain*. doi: 10.1093/brain/awv191

15. Mesulam MM (2001) Primary progressive aphasia. *Ann Neurol* 49:425–432.
16. Chare L, Hodges JR, Leyton CE, et al. (2014) New criteria for frontotemporal dementia syndromes: clinical and pathological diagnostic implications. *J Neurol Neurosurg Psychiatry* 85:865–70. doi: 10.1136/jnnp-2013-306948
17. Harris JM, Gall C, Thompson JC, et al. (2013) Classification and pathology of primary progressive aphasia. *Neurology* 81:1832–1839. doi: 10.1212/01.wnl.0000436070.28137.7b
18. Sajjadi SA, Patterson K, Arnold RJ, et al. (2012) Primary progressive aphasia: a tale of two syndromes and the rest. *Neurology* 78:1670–1677. doi: 10.1212/WNL.0b013e3182574f79
19. Edwards-Lee T, Miller BL, Benson DF, et al. (1997) The temporal variant of frontotemporal dementia. *Brain* 120 ( Pt 6):1027–1040.
20. Thompson SA, Patterson K, Hodges JR (2003) Left/right asymmetry of atrophy in semantic dementia: behavioral-cognitive implications. *Neurology* 61:1196–1203.
21. Chan D, Anderson V, Pijnenburg Y, et al. (2009) The clinical profile of right temporal lobe atrophy. *Brain* 132:1287–1298. doi: 10.1093/brain/awp037
22. Josephs KA, Whitwell JL, Knopman DS, et al. (2009) Two distinct subtypes of right temporal variant frontotemporal dementia. *Neurology* 73:1443–1450. doi: 10.1212/WNL.0b013e3181bf9945
23. Pennington C, Hodges JR, Hornberger M (2011) Neural correlates of episodic memory in behavioral variant frontotemporal dementia. *J Alzheimers Dis* 24:261–268. doi: 10.3233/JAD-2011-101668
24. Hornberger M, Piguet O, Graham AJ, et al. (2010) How preserved is episodic memory in behavioral variant frontotemporal dementia? *Neurology* 74:472–479. doi: 10.1212/WNL.0b013e3181cef85d
25. Bird CM, Chan D, Hartley T, et al. (2010) Topographical short-term memory differentiates Alzheimer's disease from frontotemporal lobar degeneration. *Hippocampus* 20:1154–1169. doi: 10.1002/hipo.20715
26. Tu S, Wong S, Hodges JR, et al. (2015) Lost in spatial translation – A novel tool to objectively assess spatial disorientation in Alzheimer's disease and frontotemporal dementia. *Cortex* 67:83–94. doi: 10.1016/j.cortex.2015.03.016
27. Rohrer JD, Nicholas JM, Cash DM, et al. (2015) Presymptomatic cognitive and neuroanatomical changes in genetic frontotemporal dementia in the Genetic Frontotemporal dementia Initiative ( GENFI ) study : a cross-sectional analysis. 4422:1–10. doi: 10.1016/S1474-4422(14)70324-2
28. Lam BYK, Halliday GM, Irish M, et al. (2014) Longitudinal white matter changes in frontotemporal dementia subtypes. *Hum Brain Mapp* 35:3547–3557.
29. Mahoney CJ, Simpson IJA, Nicholas JM, et al. (2015) Longitudinal diffusion tensor imaging in frontotemporal dementia. *Ann Neurol* 77:33–46. doi: 10.1002/ana.24296
30. Hornberger M, Geng J, Hodges JR (2011) Convergent grey and white matter evidence of orbitofrontal cortex changes related to disinhibition in behavioural variant frontotemporal

dementia. *Brain* 134:2502–2512. doi: 10.1093/brain/awr173

31. Borroni B, Alberici A, Premi E, et al. (2008) Brain magnetic resonance imaging structural changes in a pedigree of asymptomatic progranulin mutation carriers. *Rejuvenation Res* 11:585–595. doi: 10.1089/rej.2007.0623
32. Doppert EGP, Rombouts SARB, Jiskoot LC, et al. (2014) Structural and functional brain connectivity in presymptomatic familial frontotemporal dementia. *Neurology* 83:e19–26. doi: 10.1212/WNL.0000000000000583
33. Seeley WW, Crawford RK, Zhou J, et al. (2009) Neurodegenerative diseases target large-scale human brain networks. *Neuron* 62:42–52. doi: 10.1016/j.neuron.2009.03.024
34. Zhou J, Greicius MD, Gennatas ED, et al. (2010) Divergent network connectivity changes in behavioural variant frontotemporal dementia and Alzheimer's disease. *Brain* 133:1352–1367. doi: 10.1093/brain/awq075
35. Filippi M, Agosta F, Scola E, et al. (2013) Functional network connectivity in the behavioral variant of frontotemporal dementia. *Cortex* 49:2389–2401. doi: 10.1016/j.cortex.2012.09.017
36. Ewers M, Mattsson N, Minthon L, et al. (2015) CSF biomarkers for the differential diagnosis of Alzheimer's disease. A large-scale international multicenter study. *Alzheimer's Dement* 1–10. doi: 10.1016/j.jalz.2014.12.006
37. Scherling CS, Hall T, Berisha F, et al. (2014) Cerebrospinal fluid neurofilament concentration reflects disease severity in frontotemporal degeneration. *Ann Neurol* 75:116–126. doi: 10.1002/ana.24052
38. Lu C-H, Macdonald-Wallis C, Gray E, et al. (2015) Neurofilament light chain: A prognostic biomarker in amyotrophic lateral sclerosis. *Neurology* 84:2247–2257. doi: 10.1212/WNL.0000000000001642
39. Rosso SM, Donker Kaat L, Baks T, et al. (2003) Frontotemporal dementia in The Netherlands: patient characteristics and prevalence estimates from a population-based study. *Brain* 126:2016–2022. doi: 10.1093/brain/awg204
40. Goldman JS, Farmer JM, Wood EM, et al. (2005) Comparison of family histories in FTL D subtypes and related tauopathies. *Neurology* 65:1817–1819. doi: 10.1212/01.wnl.0000187068.92184.63
41. Le Ber I, Guedj E, Gabelle A, et al. (2006) Demographic, neurological and behavioural characteristics and brain perfusion SPECT in frontal variant of frontotemporal dementia. *Brain* 129:3051–3065. doi: 10.1093/brain/awl288
42. Warren JD, Rohrer JD, Rossor MN (2013) Clinical review. Frontotemporal dementia. *BMJ* 347:f4827.
43. Vance C, Al-Chalabi A, Ruddy D, et al. (2006) Familial amyotrophic lateral sclerosis with frontotemporal dementia is linked to a locus on chromosome 9p13.2-21.3. *Brain* 129:868–876. doi: 10.1093/brain/awl030
44. Majounie E, Renton AE, Mok K, et al. (2012) Frequency of the C9orf72 hexanucleotide repeat expansion in patients with amyotrophic lateral sclerosis and frontotemporal dementia: a

cross-sectional study. *Lancet Neurol* 11:323–330. doi: 10.1016/S1474-4422(12)70043-1

- 1  
2  
3  
4  
5  
6  
7  
8  
9  
10  
11  
12  
13  
14  
15  
16  
17  
18  
19  
20  
21  
22  
23  
24  
25  
26  
27  
28  
29  
30  
31  
32  
33  
34  
35  
36  
37  
38  
39  
40  
41  
42  
43  
44  
45  
46  
47  
48  
49  
50  
51  
52  
53  
54  
55  
56  
57  
58  
59  
60  
61  
62  
63  
64  
65
45. Van der Zee J, Gijselinck I, Dillen L, et al. (2013) A pan-European study of the C9orf72 repeat associated with FTLN: geographic prevalence, genomic instability, and intermediate repeats. *Hum Mutat* 34:363–373. doi: 10.1002/humu.22244
46. Neumann M, Sampathu DM, Kwong LK, et al. (2006) Ubiquitinated TDP-43 in frontotemporal lobar degeneration and amyotrophic lateral sclerosis. *Science* 314:130–133. doi: 10.1126/science.1134108
47. Gallagher MD, Suh E, Grossman M, et al. (2014) TMEM106B is a genetic modifier of frontotemporal lobar degeneration with C9orf72 hexanucleotide repeat expansions. *Acta Neuropathol* 127:407–418. doi: 10.1007/s00401-013-1239-x
48. Riedl L, Mackenzie IR, Förstl H, et al. (2014) Frontotemporal lobar degeneration: Current perspectives. *Neuropsychiatr Dis Treat* 10:297–310. doi: 10.2147/NDT.S38706
49. Herrmann N, Black SE, Chow T, et al. (2012) Serotonergic function and treatment of behavioral and psychological symptoms of frontotemporal dementia. *Am J Geriatr Psychiatry* 20:789–797. doi: 10.1097/JGP.0b013e31823033f3
50. TauRx Therapeutics Ltd. Safety and Efficacy Study Evaluating TRx0237 in Subjects With Behavioral Variant Frontotemporal Dementia (bvFTD). <http://clinicaltrials.gov/show/NCT01626378>. Accessed 9 Dec 2013