

1 **The Prognostic Value of Right Ventricular Deformation Imaging in Early Arrhythmogenic**
2 **Right Ventricular Cardiomyopathy**

3 Running title: The Prognostic Value of RV Deformation Imaging in Early ARVC

4 Thomas P. Mast, MD, PhD,^{a,b,*} Karim Taha, BSc,^{c,*} Maarten J. Cramer, MD, PhD,^a Joost Lumens, PhD,^d Jeroen F.
5 van der Heijden, MD, PhD,^a Berto J. Bouma, MD, PhD,^e Maarten P. van den Berg, MD, PhD,^f Folkert W.
6 Asselbergs, MD, PhD,^{a,g,h} Pieter A. Doevendans, MD, PhD,^a Arco J. Teske, MD, PhD,^a

7 From the ^aDepartment of Cardiology, Division Heart and Lungs, University Medical Center Utrecht, Utrecht, the Netherlands; ^bDepartment of
8 Cardiology, Catharina Hospital Eindhoven, Eindhoven, the Netherlands; ^cUniversity of Amsterdam, Amsterdam, the Netherlands; ^dDepartment of
9 Biomedical Engineering, Cardiovascular Research Institute Maastricht (CARIM), Maastricht University, Maastricht, the Netherlands; ^eDivision
10 of Cardiology, Academic Medical Center Amsterdam, Amsterdam, the Netherlands; ^fUniversity of Groningen, University Medical Center
11 Groningen, Department of Cardiology, Groningen, the Netherlands; ^gDurrer Center for Cardiovascular Research, ICIN-Netherlands Heart
12 Institute, Utrecht, the Netherlands; ^hInstitute of Cardiovascular Science, Faculty of Population Health Sciences, University College London,
13 London, United Kingdom. *Dr. Mast and Mr. Taha contributed equally to this work.

14 We acknowledge the support from the Netherlands Cardiovascular Research Initiative: an initiative with support of the Dutch Heart Foundation,
15 CVON2015-12 eDETECT. Folkert W. Asselbergs is supported by a Dekker scholarship-Junior Staff Member 2014T001 – Dutch Heart
16 Foundation and UCL Hospitals NIHR Biomedical Research Centre. Dr Lumens received a grant within the framework of the Dr E. Dekker
17 program of the Dutch Heart Foundation (NHS-2015T082).

18
19 Total word count: 4583 words (including references and figure legends)

20
21 **Address for correspondence:**

22 Arco J. Teske, MD, PhD

23 Heidelberglaan 100

24 3584CX Utrecht, The Netherlands

25 A.J.Teske-2@umcutrecht.nl

26 Telephone: +31(0)887555555; Fax: +31(0)887555660

27 **STRUCTURED ABSTRACT**

28 **Background:** Arrhythmogenic right ventricular cardiomyopathy (ARVC) is characterized by variable disease
29 expressivity among family members, which complicates family screening protocols. Previous reports have shown
30 that echocardiographic deformation imaging detects abnormal right ventricular (RV) deformation in the absence of
31 established disease expression in ARVC.

32 **Objectives:** We aimed to investigate the prognostic value of echocardiographic deformation imaging in ARVC to
33 optimize family screening protocols.

34 **Methods:** First-degree relatives of ARVC patients were evaluated according to 2010 Task Force Criteria (TFC),
35 including RV deformation imaging (n=128). Relatives fulfilling structural TFC were excluded for further analysis. At
36 baseline, deformation patterns of the subtricuspid region were scored by *Type-I*: normal deformation, *Type-II*: delayed
37 onset, decreased systolic peak, and post-systolic shortening, or *Type-III*: systolic stretching and large post-systolic
38 shortening. The final study population comprised relatives who underwent a second evaluation during follow-up.
39 Disease progression was defined as the development of a new 2010 TFC during follow-up that was absent at baseline.

40 **Results:** Sixty-five relatives underwent a second evaluation after a mean follow-up of 3.7 ± 2.1 years. At baseline, 28
41 relatives (43%) had normal deformation (Type-I) and 37 relatives (57%) had abnormal deformation (Type-II/Type-
42 III) in the subtricuspid region. Disease progression occurred in 4% of the relatives with normal deformation at baseline
43 and in 43% of the relatives with abnormal deformation at baseline ($P < .001$). Positive and negative predictive values
44 of abnormal deformation were respectively 43% (95CI:27%-61%) and 96% (95CI:82%-100%).

45 **Conclusion:** Normal RV deformation in the subtricuspid region is associated with absence of disease progression
46 during a nearly 4-year follow-up in ARVC relatives. Abnormal RV deformation seems to precede the established
47 signs of ARVC. RV deformation imaging may potentially play an important role in ARVC family screening protocols.

48 **CONDENSED ABSTRACT**

49 Arrhythmogenic right ventricular cardiomyopathy (ARVC) is a disease that is characterized by variable disease
50 expressivity among family members, which complicates family screening protocols. A recent consensus statement by
51 an international Task Force recommends repeated clinical assessment in all relatives every 2-3 years, even in relatives
52 without any morphological or functional abnormalities. The present study was conducted to optimize family screening
53 protocols by evaluating the value of echocardiographic deformation imaging as a predictor of disease progression.
54 The results suggest echocardiographic deformation imaging may potentially play an important role in ARVC family
55 screening protocols.

56

57 **ABBREVIATIONS LIST**

58 *ARVC* = arrhythmogenic right ventricular cardiomyopathy

59 *RV* = right ventricle/ventricular

60 *TFC* = Task Force criteria

61 *ECG* = electrocardiogram

62 *CMR* = cardiac magnetic resonance imaging

63 *PPV* = positive predictive value

64 *NPV* = negative predictive value

65

66 **KEY WORDS**

67 ARVD/C, arrhythmogenic right ventricular cardiomyopathy, deformation imaging, strain imaging, family screening,
68 disease progression

69 **INTRODUCTION**

70 Arrhythmogenic right ventricular cardiomyopathy (ARVC) is an inherited cardiomyopathy clinically characterized by
71 ventricular arrhythmias and predominantly right ventricular (RV) dysfunction (1). Typical genetic features of ARVC
72 are reduced penetrance and variable disease expressivity, which complicates family screening (2-4). Comprehensive
73 cardiac screening of ARVC family members is routinely performed by electrocardiography (ECG), Holter monitoring,
74 and cardiac imaging, and aims to detect typical ARVC related abnormalities (3,5,6). However, early ARVC is
75 characterized by a lack of overt structural abnormalities detected by conventional imaging approaches (3,7). Novel
76 imaging techniques could be of incremental value in optimizing ARVC family screening protocols (8).

77 Echocardiographic deformation imaging is a technique that enables quantification of regional ventricular deformation
78 and provides insight in mechanical synchrony and regional contractility (9,10). Previous reports suggest that this
79 technique is capable to detect subtle functional abnormalities in the absence of structural abnormalities by
80 conventional imaging (11-13). We recently introduced a new approach that combines multiple deformation parameters
81 into three distinct deformation patterns. A clear correlation between abnormal deformation patterns and disease
82 severity among ARVC desmosomal mutation carriers was found (14). In addition, we were able to characterize the
83 underlying electromechanical substrate of these patterns by dedicated computer simulation of deformation patterns.
84 Abnormal deformation was typically seen in the basal area of the RV free wall (or subtricuspid region) which is
85 recognized as one of the earliest affected areas in ARVC (12-15). Importantly, abnormal deformation in this specific
86 area was seen during the earliest subclinical stage in which established phenotypic disease expression according to
87 the 2010 Task Force Criteria (TFC) was absent (5). Therefore, echocardiographic deformation imaging may
88 potentially play a pivotal role in improving ARVC family screening.

89 While all previously published data was obtained in a cross-sectional study design, this longitudinal study was
90 conducted to explore the value of deformation imaging in ARVC family member screening. Our hypothesis is that
91 distinct RV deformation abnormalities precede the conventional signs of disease during the early ARVC stages and
92 can therefore help stratifying relatives at risk for disease progression.

93 **METHODS**

94 *Study population*

95 During a 10-year observational period (2006-2016), we performed echocardiographic examination according to our
96 ARVC protocol in probands (all fulfilling definite diagnosis by 2010 TFC) and their relatives during their clinical
97 work-up for ARVC (9,16). The study participants (n=194, age>18years) were derived from the Dutch National ARVC
98 registry with patients from University Medical Center Utrecht (n=161), Academic Medical Center Amsterdam (n=18),
99 and University Medical Center Groningen (n=15). Altogether, an echocardiographic exam with appropriate RV
100 recordings for RV deformation imaging was available in 66 ARVC probands and 128 first-degree relatives. All
101 participants were genetically tested for known ARVC related pathogenic mutations: plakophilin-2 (*PKP2*),
102 desmoglein-2 (*DSG2*), desmocollin-2 (*DSC2*), desmoplakin (*DSP*) and plakoglobin (*JUP*) (5). Non-desmosomal
103 analysis included transmembrane protein 43 (*TMEM43*) and phospholamban (*PLN*) (5,17).

104 The following participants were eligible for this study: 1) first-degree relatives carrying the identical pathogenic
105 ARVC mutation as identified in the probands, or 2) first-degree relatives of mutation-negative probands. These
106 relatives (n=128) were classified according to the presence of subsets of 2010 TFC during clinical work-up at baseline
107 (5,14):

- 108 • *Structural stage*: Relatives fulfilling 2010 TFC for structural abnormalities detected by echocardiography or
109 cardiac magnetic resonance imaging (CMR).
- 110 • *Electrical stage*: Relatives without structural abnormalities fulfilling 2010 TFC, but with ECG abnormalities
111 (repolarization and/or depolarization) and/or history of ventricular arrhythmias as defined by the 2010 TFC.
- 112 • *Subclinical stage*: Relatives without any electrical or structural TFC.

113 To investigate the value of echocardiographic deformation imaging during the early clinical ARVC stages (i.e.
114 subclinical and electrical stage), relatives fulfilling TFC for structural abnormalities (i.e. structural stage) were
115 excluded for further analysis (n=19). Of the remaining 109 early-staged first-degree relatives, a subset of 65 first-
116 degree relatives (60%) who underwent a second complete cardiac evaluation during follow-up were included in the
117 final study population (Figure 1). The other 44 subjects (40%) did not have a second complete evaluation with all
118 diagnostic modalities during follow-up. Supplementary Table 1 provides a baseline comparison between subjects with
119 follow-up and without complete follow-up. The local medical ethical committees of each participating center approved
120 this study.

121 *Cardiac evaluation*

122 A comprehensive description of the cardiac evaluation is found in the [Supplementary Methods](#). In brief, all subjects
123 underwent standard 12-lead ECG, which was scored for the presence of repolarization and depolarization
124 abnormalities as defined by the 2010 TFC [\(5\)](#). Holter recordings for 24 hours were analyzed for the presence of
125 ventricular tachycardia (VT) and premature ventricular complexes (PVC) [\(5\)](#). Structural abnormalities as defined by
126 2010 TFC were primarily assessed by echocardiography according to standard ARVC protocols [\(5,9,16\)](#).
127 Additionally, left ventricular (LV) involvement was assessed by visual wall motion analysis and measurement of LV
128 ejection fraction (LVEF) using Simpson biplane method. Additional CMR was performed at the discretion of the
129 treating physician (typically in cases where echocardiography was of insufficient quality or to verify new
130 abnormalities seen by echocardiography). CMR studies were analyzed for fulfillment of TFC and LV systolic function
131 was assessed by measurement of LVEF [\(5,18\)](#). Contrast enhanced images after administration of gadolinium were
132 acquired to identify myocardial fibrosis in both the RV and LV. ARVC definite diagnosis was based on the presence
133 of subsets of 2010 TFC, which requires 2 major criteria, 1 major and 2 minor criteria, or 4 minor criteria [\(5\)](#).

134 *Echocardiographic RV deformation imaging*

135 All subjects underwent RV echocardiographic deformation imaging with GE Vivid 7 or GE Vivid E9 (General
136 Electric, Milwaukee, MN) [\(9\)](#). Details on image acquisition and post-processing were extensively described elsewhere
137 [\(9,16\)](#). In brief, a focused modified narrow-angled 2D image in the apical 4 chamber view was recorded to assess the
138 RV. Frame rates between 55-110/s were accepted for RV deformation imaging. GE EchoPac 10.2 – PC software by
139 GE Healthcare was used to perform 2D speckle tracking. After manual tracing, the RV lateral free wall was divided
140 automatically into the basal, mid, and apical segment. Pulmonary valve timing was assessed by Doppler traces in the
141 RV outflow tract obtained in parasternal short axis view. The following deformation parameters were measured in the
142 basal area: time to onset of shortening [\(19\)](#), systolic peak strain value [\(10,20\)](#), and post-systolic index [\(12\)](#) (for
143 definitions see [Supplementary Figure 1](#)). These deformation parameters can be combined into three distinct
144 deformation patterns, as previously published [\(Figure 2\) \(14\)](#).

145 - **Type-I:** defined as normal deformation characterized by onset shortening ≤ 90 ms, systolic peak strain \geq | -
146 20% |, and $\leq 10\%$ post-systolic shortening.

- 147 - **Type-II:** characterized by delayed onset of shortening (>90ms), reduced systolic peak strain (< | -20% | ; > | -
148 10% |), and minor post-systolic shortening (>10%).
- 149 - **Type-III:** characterized by predominantly systolic stretching (systolic peak strain < | -10% | , and major post-
150 systolic shortening.

151 *ARVC disease progression*

152 In the final study population of 65 first-degree relatives who underwent two separate complete cardiac assessments,
153 disease progression was defined as the presence of a new major or minor TFC (structural, depolarization,
154 repolarization, or arrhythmic) that was absent at baseline. RV deformation patterns in the basal area at baseline were
155 evaluated for the predictive value for disease progression.

156 *Statistical analysis*

157 Means were expressed as mean \pm standard deviation or median [inter-quartile range] if appropriate. Normal
158 distribution was tested by the Shapiro-Wilk test. Mean group values were compared independent Student's *t*-test or
159 Mann-Whitney-U test if appropriate. Distributions of proportions were performed by Fischer Exact test. Predictive
160 values were expressed as positive/negative predictive value (PPV/NPV) with the 95% confidence interval (95CI)
161 calculated by the Clopper-Pearson method. For inter-observer analysis a second operator performed RV deformation
162 analysis in 20 random subjects. For determination of intra-observer agreement, this sample was re-analyzed by the
163 first observer 6 weeks after the first analysis. Inter- and intra-observer agreement were determined by linear weighted
164 Kappa statistics. P-values were considered statistically significant if $P < .05$ All statistical analyses were performed in
165 commercially available software: IBM SPSS Statistics for Windows, Version 21.0. Armonk, NY: IBM Corp.

166 **RESULTS**

167 *Clinical evaluation at baseline*

168 The final study population comprised 65 subjects with a mean age of 31.8 ± 16.6 years of which 24 (37%) were male.
169 The majority carried a pathogenic mutation ($n=54$, 83%) which mostly considered a desmosomal mutation ($n=50$,
170 77%). Based on baseline clinical evaluation, 37 subjects were assigned to the subclinical stage and 28 subjects had
171 electrical abnormalities according to the 2010 TFC ([Figure 1](#)). Subjects that showed electrical abnormalities at

172 baseline were significantly older compared to subjects in the subclinical stage (respectively 26.4±13.9 years vs.
173 39.0±17.4 years, P<.001). Gender and the presence of a pathogenic mutation were not significantly different between
174 subjects in the subclinical or electrical stage ([Table 1](#)). At baseline, CMR was available in 23 (62%) subjects in the
175 subclinical stage and 19 (68%) subjects in the electrical stage. All mean values of the structural parameters (by CMR
176 as well as echocardiography) were comparable between subjects in the electrical and subclinical stage ([Table 1](#)). At
177 baseline, none of the subjects had signs of LV involvement by echocardiography or CMR. None of the included
178 subjects had a history of sustained ventricular arrhythmias and none were on anti-arrhythmic medication. Eight (12%)
179 subjects had an implantable cardiac defibrillator (ICD) implanted at baseline for primary prevention (3 in the
180 subclinical stage and 5 in the electrical stage). No baseline differences were seen between subjects that underwent a
181 second evaluation (n=65) and those without (n=44) ([Supplementary table 1](#)).

182 *RV deformation patterns in relatives at baseline*

183 In the final study population, Type-I deformation was seen in 28 (43%) subjects, Type-II deformation was seen in 33
184 (51%) subjects and Type-III deformation was seen in 4 (6%) subjects. Abnormal deformation (Type-II and Type-III)
185 was more frequently seen in older subjects (36.6±7.2 years vs. 25.5±13.7 years, P=.005) and in pathogenic mutation
186 carriers (92% vs. 71%, P=.045). Sex was equally distributed among subjects with normal and abnormal deformation
187 patterns (male: 36% vs. 38%, P=1.00).

188 The 37 subjects in the subclinical stage were mainly characterized by deformation pattern Type-I (n=23, 62%),
189 whereas deformation pattern Type-II was seen in the remaining 14 (38%) subjects. The electrical stage was mainly
190 characterized by deformation pattern Type-II (n=19, 68%). In the remaining subjects in the electrical stage, Type-I
191 was seen in 5 (18%) and Type-III was seen in 4 (14%). The distribution of baseline deformation patterns specified for
192 the presence of ECG abnormalities as defined by TFC is shown in [Supplementary Table 2](#).

193 Inter- and intra-rater reproducibility for RV deformation pattern classification was high, respectively 0.94 (95CI: 0.81-
194 1.00) and 0.93 (95CI: 0.79-1.00).

195 *Disease Progression*

196 The mean follow-up duration was 3.7 ± 2.1 years and was equally distributed between subjects that showed signs of
197 disease progression compared to subjects without signs of disease progression (respectively 4.5 ± 2.0 vs. 3.5 ± 2.1 years,
198 $P=0.09$). Altogether, 17 (26%) relatives showed signs of ARVC disease progression.

199 Electrical progression occurred more frequently compared to structural progression: 11 subjects showed only electrical
200 progression, 4 subjects showed electrical progression along with structural progression, and 2 subjects showed
201 structural progression on top of already pre-existing electrical disease at baseline. None of the subjects suffered from
202 a sustained arrhythmic event or appropriate ICD intervention during follow-up.

203 The progression rates among the carriers of different mutations are shown in [Supplementary figure 2](#).

204 *Predictive value of abnormal deformation in early ARVC*

205 Of the 28 subjects with a normal deformation pattern (Type-I) at baseline, only one subject showed disease
206 progression, expressed as an increased PVC count of $>500/24$ hrs during second evaluation. In the 37 subjects with an
207 abnormal deformation pattern (Type-II and Type-III) at baseline, disease progression was seen in 16 (43%) subjects.
208 The NPV of normal deformation at baseline for disease progression was 96% (95CI:82%-100%). The PPV of
209 abnormal deformation at baseline for disease progression was 43% (95CI:27%-61%). The predictive values were
210 similar in a sub-cohort only consisting of mutation-positive relatives ($n=54$); NPV: 95% (95CI:75%-100%), PPV:
211 44% (95CI:27%-62%).

212 [Figure 3](#) shows a flowchart of the rate of disease progression specified for both deformation pattern and clinical stage
213 at baseline. In the 23 subjects in the subclinical stage with normal deformation at baseline, only one subject showed
214 disease progression; NPV: 96%, (95CI:78%-100%). In the 14 subjects in the subclinical stage with abnormal (Type-
215 II) deformation, 9 (64%) showed disease progression ([Figure 3](#)). This results in a PPV of 64% (95CI: 35%-87%)

216 In the 5 electrical staged subjects with normal deformation at baseline, disease progression occurred in none; NPV:
217 100% (95CI:48%-100%). Of the 19 subjects in the electrical stage with Type-II pattern at baseline, 5 (26%) showed
218 signs of disease progression. Two of the four (50%) subjects in the electrical stage with deformation pattern Type-III
219 showed disease progression. The PPV of abnormal deformation (Type-II or Type-III pattern) on disease progression
220 in the electrical stage is 30% (95CI:13%-53%).

221 **DISCUSSION**

222 The main findings of our study are that, in case of normal findings by conventional echocardiography and
223 CMR, 1) first-degree relatives of ARVC patients with normal deformation in the RV basal area do not show disease
224 progression during a mean follow-up of nearly 4 years and that 2) the presence of abnormal deformation at baseline
225 is associated with unequivocal signs of disease progression during follow-up in early ARVC. The results of this study
226 might have implications for our follow-up strategy of relatives in clinical practice. Relatives with normal RV
227 deformation on top of normal results during standard cardiac screening seem to have an excellent mid-term prognosis
228 and less frequent cardiac screening might be equally effective.

229 *Normal RV deformation imaging in early ARVC*

230 Our study shows that deformation imaging is able to identify relatives at low-risk for disease progression. This
231 particularly holds true for relatives in the earliest stage without any established disease expression as defined by TFC.
232 Normal deformation in the RV basal area in addition to the absence of abnormalities detected by ECG, Holter, and
233 conventional cardiac imaging largely excludes disease progression for at least almost 4 years. Previously, we
234 demonstrated with computer modeling that deformation pattern Type-I represents normal electromechanical
235 properties of the RV myocardium such as seen in healthy individuals (14). We focused on the RV basal area
236 (subtricuspid region) since previous studies have convincingly shown that this area is one of the first affected regions
237 in ARVC (12,15,19). Our results suggest that relatives without any disease expression (including normal deformation
238 in the subtricuspid region) are in a clinical stage that precedes the subclinical stage. Traditionally, a clinical stage
239 without any disease expression in ARVC is often considered as the concealed stage (1). Our data show that
240 deformation imaging helps to discriminate between relatives who are in a true concealed stage and relatives with
241 subtle local RV mechanical dysfunction not detected by conventional approaches (subclinical stage) (Figure 4). A
242 recent consensus statement by an international Task Force recommends repeated clinical assessment in all ARVC
243 family members every 2-3 years, even in individuals without any morphological or functional abnormalities (6). In
244 the present study we observed low progression rates in ARVC relatives in the true concealed stage, i.e. relatives with
245 normal deformation in the subtricuspid region in addition to normal findings by conventional techniques. This allows
246 us to speculate that the follow-up interval in this group might be extended beyond the current recommendations (6).
247 However, further studies with longer follow-up and preferentially larger patient numbers, in which disease progression

248 is accurately assessed by CMR, are needed to further substantiate our findings. Moreover, individual factors (e.g.
249 cardiac symptoms and sports activity) should always be considered when determining individual follow-up intervals.

250 *Abnormal RV deformation imaging in early ARVC*

251 By definition, relatives in the subclinical stage lack any established disease expression as defined by TFC.
252 Interestingly, one third of the included subclinical staged subjects in this study were identified with an abnormal
253 deformation pattern (Type-II). In a recent study, we showed that this abnormal deformation pattern is present in almost
254 half of the desmosomal mutation carriers in the subclinical stage and the underlying electromechanical substrate seems
255 to be regional hypocontractility and mildly increased passive wall stiffness (14). This finding is confirmed in the
256 present study where abnormal deformation patterns were encountered in subclinical staged subjects without any
257 established disease expression, including the absence of ECG abnormalities (Supplementary Table 2). One of our
258 main findings was that the presence of abnormal deformation actually precedes ECG abnormalities since
259 approximately half of the subjects in the subclinical stage with abnormal deformation developed unequivocal signs of
260 disease progression during follow-up, primarily electrical disease progression. The association between the presence
261 of abnormal deformation and the occurrence of established disease expression during follow-up supports our
262 hypothesis that the observed deformation patterns are a functional representation of an underlying pathological
263 electromechanical substrate.

264 The subjects in our cohort did not suffer from any life threatening events such as sudden cardiac death, sustained
265 ventricular arrhythmia, or appropriate ICD intervention during follow-up. This could be explained by the fact that all
266 relatives fulfilling structural TFC were excluded from our study, while especially this form of disease expression is
267 seen in all relatives prior to sustained arrhythmic events (3,4,7). Another explanation could be that this cohort is too
268 small and the lack of events is possibly a matter of chance. Although we were not able to prove any association
269 between abnormal deformation and sustained arrhythmias, we do speculate that abnormal deformation is an early sign
270 of structural changes. Considering the apparent low arrhythmic risk in patients with no structural expression, cardiac
271 screening every 2 years in accordance with the current Task Force consensus statement seems to be sufficient and safe
272 (6). (Figure 4)

273 *Towards optimization of family screening protocols.*

274 To our best knowledge, the present study is the first one to prospectively investigate the prognostic value of RV
275 deformation imaging in early ARVC. A recent retrospective study by Leren *et al.* reported a multi-modality approach
276 in identifying subjects at risk for ventricular arrhythmias during early ARVC and thereby aiming at the use of
277 deformation imaging in addition to conventional techniques (21). Our study is in line with their multi-modality design
278 during family screening, and further highlights the additional value of RV deformation imaging in ARVC.

279 A recent expert consensus document of the European Heart Association supports the additional use of strain
280 echocardiography in the echocardiographic assessment in ARVC, particularly in early ARVC when the diagnosis is
281 challenging (8). We may be entering a new era in which echocardiographic deformation imaging will participate in
282 the field of clinical decision making in ARVC (22).

283 *Limitations:*

284 Based on the rates of disease progression that were observed in our cohort after almost four years, we made suggestions
285 for follow-up intervals for ARVC family members. However, these intervals may not be suitable for all ARVC family
286 members. Firstly, it is known that the disease behaves differently among the carriers of different mutations while our
287 cohort mainly represented *PKP2* and *PLN* mutation carriers (17). Additionally, in our proposed follow-up intervals
288 we did not take into consideration factors such as age, gender, presence of cardiac symptoms and sports activity (4,23).
289 These factors may have a significant influence on disease progression and thus should be taken into consideration in
290 studies aiming to make recommendations for follow-up intervals. Even though the current study includes a relatively
291 large cohort of patients with this relatively rare disease, our study population was too small to correct for genetic
292 profile and additional clinical factors in a multivariate analysis.

293 Forty percent of the baseline cohort could not be included in the study because their second evaluation did not take
294 place during our study period, or because the second evaluation did not include all diagnostic modalities that are
295 needed to adequately assess disease progression. Based on the baseline comparison between subjects with follow-up
296 and without available follow-up (Supplementary table 1), relevant selection bias seems unlikely.

297 Structural disease progression was primarily assessed by conventional echocardiography, and 25 subjects (38%) had
298 additional CMR. However, the sensitivity of conventional echocardiography is known to be inferior to CMR, which

299 could potentially lead to lower detection of structural abnormalities in subjects that did not have CMR (24). In future
300 studies, disease progression should be accurately assessed by both CMR and echocardiography.

301 **CONCLUSION**

302 Echocardiographic deformation imaging is capable to identify relatives who are at low risk of disease progression
303 during the early stages of ARVC. A normal RV deformation pattern at baseline is associated with an absence of disease
304 progression during mid-term follow-up in relatives of ARVC patients, suggesting that a low-frequency follow-up
305 strategy would suffice. Moreover, the presence of abnormal RV deformation in early ARVC is associated with
306 unequivocal signs of disease progression. Therefore, our data suggest that echocardiographic deformation imaging
307 may potentially be implemented in ARVC family screening protocols. Future studies including a larger study
308 population are required to validate our data.

309 **PERSPECTIVES**

310 **Competency in medical knowledge:** The present study demonstrates that in the absence of structural TFC, normal
311 echocardiographic deformation in the subtricuspid region identifies ARVC family members who are at low risk of
312 disease progression. Abnormal echocardiographic deformation in this region is associated with unequivocal signs of
313 disease progression.

314 **Translational outlook:** Future studies including a larger number of ARVC family members and with a longer follow-
315 up are required to validate the predictive value of echocardiographic deformation imaging in risk stratification in early
316 ARVC. Echocardiographic deformation imaging may become an important part of family screening protocols in
317 ARVC. We should be heading in the direction of a predictive model in which a variety of clinical parameters are
318 implemented, to create individual, tailor-made follow-up strategies for ARVC family members.

319 **REFERENCES**

- 320 1. Corrado D, Link MS, Calkins H, et al. Arrhythmogenic right ventricular cardiomyopathy. *N Engl J Med*
321 2017;376:61-72.
- 322 2. Nava A, Bauce B, Basso C, et al. Clinical profile and long-term follow-up of 37 families with
323 arrhythmogenic right ventricular cardiomyopathy. *J Am Coll Cardiol*. 2000;36(7):2226-33.
- 324 3. Te Riele AS, James CA, Rastegar N, et al. Yield of serial evaluation in at-risk family members of patients
325 with ARVD/C. *J Am Coll Cardiol* 2014;64(3):293-301.
- 326 4. Te Riele AS, James CA, Groeneweg JA, et al. Approach to family screening in arrhythmogenic right
327 ventricular dysplasia/cardiomyopathy. *Eur Heart J* 2016;37(9):755-63.
- 328 5. Marcus FI, McKenna WJ, Sherrill D, et al. Diagnosis of arrhythmogenic right ventricular
329 cardiomyopathy/dysplasia: proposed modification of the task force criteria. *Circulation* 2010;121(13):1533-41.
- 330 6. Corrado D, Wichter T, Link MS, et al. Treatment of arrhythmogenic right ventricular
331 cardiomyopathy/dysplasia: an international task force consensus statement. *Eur Heart J* 2015;36(46):3227-37.
- 332 7. Te Riele AS, Bhonsale A, James CA, et al. Incremental value of cardiac magnetic resonance imaging in
333 arrhythmic risk stratification of arrhythmogenic right ventricular dysplasia/cardiomyopathy-associated desmosomal
334 mutation carriers. *J Am Coll Cardiol* 2013;62(19):1761-9.
- 335 8. Haugaa KH, Basso C, Badano LP, et al. Comprehensive multi-modality imaging approach in
336 arrhythmogenic cardiomyopathy-an expert consensus document of the European Association of Cardiovascular
337 Imaging. *Eur Heart J Cardiovasc Imaging* 2017;18(3):237-253.
- 338 9. Teske AJ, De Boeck BW, Melman PG, Sieswerda GT, Doevendans PA, Cramer MJ. Echocardiographic
339 quantification of myocardial function using tissue deformation imaging,a guide to image acquisition and analysis
340 using tissue Doppler and speckle tracking. *Cardiovasc Ultrasound* 2007;5:27.
- 341 10. Teske AJ, Cox MG, De Boeck BW, Doevendans PA, Hauer RN, Cramer MJ. Echocardiographic tissue
342 deformation imaging quantifies abnormal regional right ventricular function in arrhythmogenic right ventricular
343 dysplasia/cardiomyopathy. *J Am Soc Echocardiogr* 2009;22(8):920-7.
- 344 11. Sarvari SI, Haugaa KH, Anfinsen OG, et al. Right ventricular mechanical dispersion is related to malignant
345 arrhythmias: a study of patients with arrhythmogenic right ventricular cardiomyopathy and subclinical right
346 ventricular dysfunction. *Eur Heart J* 2011;32(9):1089-96.

- 347 12. Teske AJ, Cox MG, Te Riele AS, et al. Early detection of regional functional abnormalities in
348 asymptomatic ARVD/C gene carriers. *J Am Soc Echocardiogr* 2012;25(9):997-1006.
- 349 13. Mast TP, Teske AJ, Te Riele AS, Groeneweg JA, et al. Prolonged Electromechanical Interval Unmasks
350 Arrhythmogenic Right Ventricular Dysplasia/Cardiomyopathy in the Subclinical Stage. *J Cardiovasc Electrophysiol*
351 2016;27(3):303-14.
- 352 14. Mast TP, Teske AJ, Walmsley J, et al. Right ventricular deformation imaging and computer simulation for
353 electromechanical substrate characterization in arrhythmogenic right ventricular cardiomyopathy (ARVC). *J Am*
354 *Coll Cardiol* 2016;68(20):2185-2197.
- 355 15. Te Riele AS, James CA, Philips B, et al. Mutation-positive arrhythmogenic right ventricular
356 dysplasia/cardiomyopathy: the triangle of dysplasia displaced. *J Cardiovasc Electrophysiol* 2013;24(12):1311-20.
- 357 16. Mast TP, Teske AJ, Doevendans PA, Cramer MJ. Current and future role of echocardiography in
358 arrhythmogenic right ventricular dysplasia/cardiomyopathy. *Cardiol J* 2015;22(4):362-74.
- 359 17. Groeneweg JA, van der Zwaag PA, Olde Nordkamp LR, et al. Arrhythmogenic right ventricular
360 dysplasia/cardiomyopathy according to revised 2010 task force criteria with inclusion of non-desmosomal
361 phospholamban mutation carriers. *Am J Cardiol* 2013;112(8):1197-206.
- 362 18. Tandri H, Calkins H, Nasir K, et al. Magnetic resonance imaging findings in patients meeting task force
363 criteria for arrhythmogenic right ventricular dysplasia. *J Cardiovasc Electrophysiol* 2003;14(5):476-82.
- 364 19. Mast TP, Teske AJ, Riele AS, et al. Prolonged electromechanical interval unmasks arrhythmogenic right
365 ventricular dysplasia/cardiomyopathy in the subclinical stage. *J Cardiovasc Electrophysiol*. 2016;27(3):303-14.
- 366 20. Prakasa KR, Wang J, Tandri H, et al. Utility of tissue Doppler and strain echocardiography in
367 arrhythmogenic right ventricular dysplasia/cardiomyopathy. *Am J Cardiol* 2007;100(3):507-12.
- 368 21. Leren IS, Saberniak J, Haland TF, Edvardsen T, Haugaa KH. Combination of ECG and Echocardiography
369 for Identification of Arrhythmic Events in Early ARVC. *J Am Coll Cardiol Img* 2017;10(5):503-513.
- 370 22. Teske AJ, Mast TP. Moving From Multimodality Diagnostic Tests Toward Multimodality Risk
371 Stratification in ARVC. *J Am Coll Cardiol Img* 2017;10(5):514-517.
- 372 23. Sawant AC, Calkins H. Relationship between arrhythmogenic right ventricular dysplasia and exercise. *Card*
373 *Electrophysiol Clin* 2015;7(2):195-206.

374 24. Borgquist R, Haugaa KH, Giljam T, et al. The diagnostic performance of imaging methods in ARVC using
375 the 2010 Task Force criteria. *Eur Heart J Cardiovasc Imaging* 2014;15(11):1219-25.
376

377 **Figure Legends:**

378 *Figure 1. Study design;* Relatives with available RV deformation imaging were eligible for this study. The presence
379 of structural abnormalities (as defined by 2010 TFC) resulted in exclusion of the study. Only relatives in the early
380 clinical stages (electrical stage and subclinical stage, n=109) were included. Sixty-five relatives underwent a
381 complete second cardiac evaluation.

382 ARVC=arrhythmogenic right ventricular cardiomyopathy; ECG=electrocardiography; RV=right ventricle;
383 TFC=task force criteria.

384 *Figure 2. Right ventricular deformation patterns;* Three distinct deformation patterns are observed in ARVC. In a
385 previous report by our group, we used a computer model to simulate Type-II (middle panel) pattern by the induction
386 of a mechanical substrate (hypocontractility and increased passive wall stiffness) in the subtricuspid region [\(14\)](#).
387 Type-III (right panel) was simulated by aggravating this substrate. No local pathological electromechanical substrate
388 was present in Type-I (normal deformation) (left panel).

389 ARVC=arrhythmogenic right ventricular cardiomyopathy; PVO/PVC=timing of pulmonary valve opening/closure.

390 *Figure 3. Rate of disease progression specified for deformation patterns and clinical stage at baseline;* These rates
391 result in a NPV of 96% (95CI: 82-100%) and a PPV of 43% (95CI: 27-61%) for abnormal deformation imaging in
392 the subtricuspid region. For relatives in the subclinical stage, the NPV and PPV are respectively 96% (95CI: 78-
393 100%) and 64% (95CI: 35-87%). For relatives in the electrical stage, the NPV and PPV are respectively 100%
394 (95CI: 48-100%) and 30% (95CI: 13-53%).

395 *Figure 4. Central illustration. Suggested follow-up strategies in relatives depends on the clinical ARVC stage;* In the
396 concealed stage, RV deformation imaging shows normal deformation (Type-I), suggesting the absence of
397 electromechanical substrate. In the subclinical stage, RV deformation imaging shows an abnormal pattern, but
398 electrical and structural abnormalities (as defined by the TFC) are not detectable. The electrical stage is
399 characterized by electrical abnormalities, deformation imaging in this stage shows a transition between Type-II and
400 Type-III deformation patterns. In the structural stage there are both electrical and structural abnormalities as defined
401 by the TFC, deformation imaging in this stage shows Type-III deformation, which is associated with a large RV
402 electromechanical substrate. Normal deformation (Type-I) without any other detected abnormalities excludes the

403 presence of an electromechanical substrate and follow-up intervals in this stage might be less frequent compared to
404 the follow-up strategies recommended by current guidelines [\(6\)](#).
405 ECG=electrocardiogram; PVC=premature ventricular complexes; RV-FAC=right ventricular fractional area change;
406 RVOT-PLAX=right ventricular outflow tract – parasternal long axis view; TAD=terminal activation duration;
407 TFC=task force criteria; TWI=T-wave inversion.

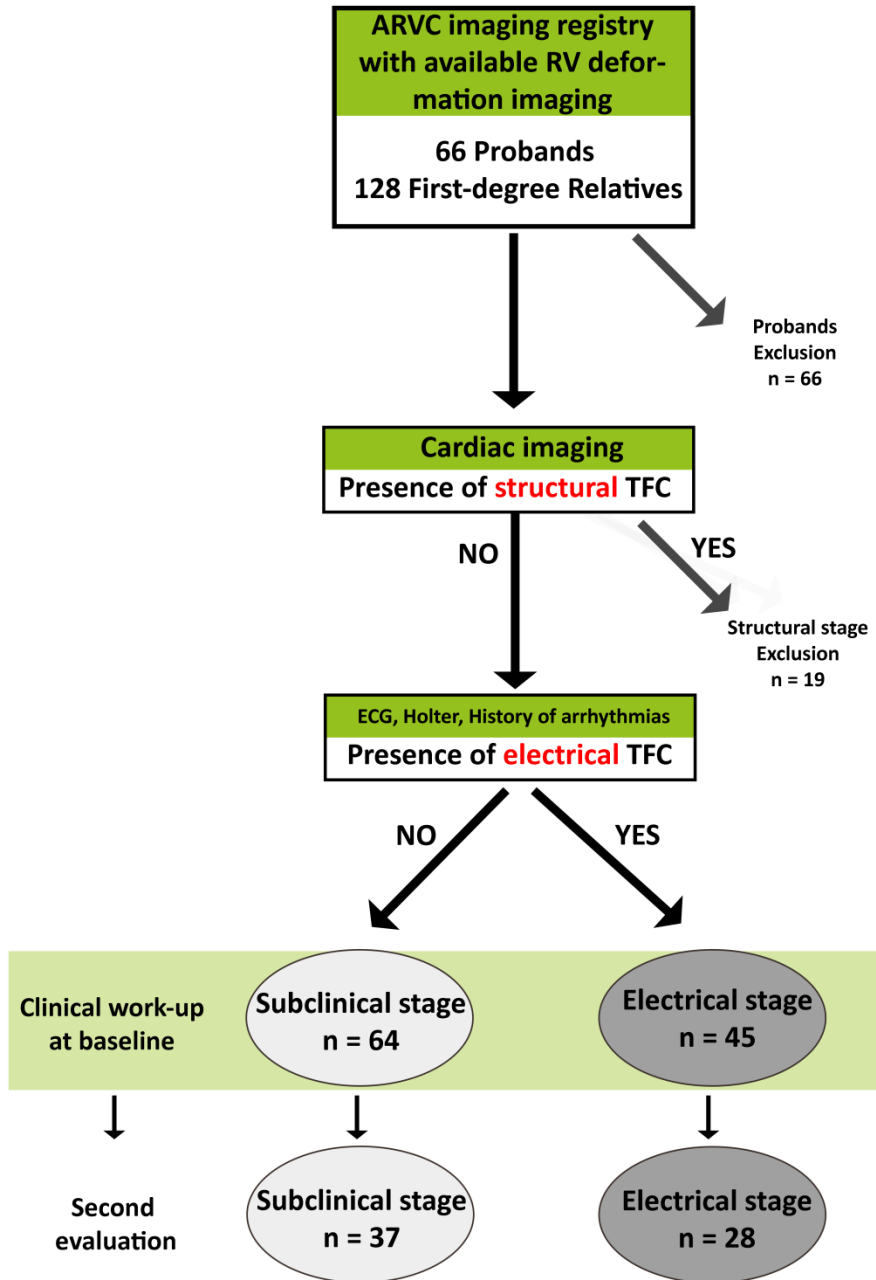
408 **Table 1. Baseline characteristics of 65 first-degree relatives with two complete cardiac evaluations**

Baseline characteristics	Subclinical stage N=37	Electrical stage N=28	P-value
Age (y)	26.4 ± 13.9	39.0 ± 17.4	.003
Male	13 (35)	11 (39)	.798
Pathogenic ARVC mutation	29 (78)	25 (89)	.325
<i>PKP2</i>	24 (65)	21 (75)	.258
<i>DSG2</i>	3 (8)	1 (4)	.637
<i>DSP</i>	0 (0)	1 (4)	.413
<i>PLN</i>	2 (5)	2 (7)	1.00
Symptomatic	4 (11)	4 (14)	.707
Palpitations	3 (8)	4 (14)	.452
Cardiac syncope	1 (3)	0 (0)	1.00
ARVC definite diagnosis	0 (0)	11 (39)	<.001
ARVC borderline diagnosis	0 (0)	17 (61)	<.001
2010 Task Force Criteria			
Structural TFC (major/minor) (%)	0 (0)	0 (0)	1.00
Depolarization TFC (major/minor) (%)	0 (0)	20 (71)	<.001
TAD (%)	0 (0)	20 (71)	<.001
Epsilon wave (%)	0 (0)	0 (0)	1.00
Repolarization TFC (major/minor) (%)	0 (0)	9 (32)	<.001
T-wave inversion: V ₁ -V ₂	0 (0)	3 (11)	.075
T-wave inversion: V ₁ -V ₃	0 (0)	4 (14)	.030
T-wave inversion: V ₄ -V ₆	0 (0)	1 (4)	.431
T-wave inversion: V ₁ -V ₆	0 (0)	1 (4)	.431
T-wave inversion: V ₁ -V ₄ with RBBB	0 (0)	0 (0)	1.00
Arrhythmia TFC (major/minor) (%)	0 (0)	13 (46)	<.001
(Non-)sustained VT with superior axis	0 (0)	0 (0)	1.00
(Non-)sustained VT with inferior or unknown	0 (0)	2 (7)	.182
PVC>500/24h	0 (0)	12 (43)	<.001
Family history TFC (major) (%)	37 (100)	28 (100)	1.00
Echocardiography			
RV-WMA	1 (3)	0 (0)	1.00
PLAX RVOT (mm/m ²)	15.2 ± 2.5	15.3 ± 2.2	.870
PSAX RVOT (mm/m ²)	16.3 ± 2.8	15.7 ± 2.4	.464
RV-FAC (%)	46.4 ± 6.2	45.7 ± 7.1	.691
LVEF (%)	58.7 ± 4.6	59.9 ± 6.2	.432
CMR			
RV-WMA	2 (9)	2 (11)	1.00
RV-EDV (ml/m ²)	95.9 ± 14.9	91.9 ± 8.1	.055
RVEF (%)	53.0 ± 7.2	53.4 ± 7.6	.890
LVEF (%)	56.9 ± 5.7	56.2 ± 8.4	.749
LGE	2 (9)	1 (5)	1.00

409 Values are n (%) or mean \pm standard deviation. Definite ARVC diagnosis is defined as the presence of either two
410 major, one major and two minor, or four minor TFC. Borderline diagnosis of ARVC is defined as the presence of
411 either one major and one minor, or three minor TFC.

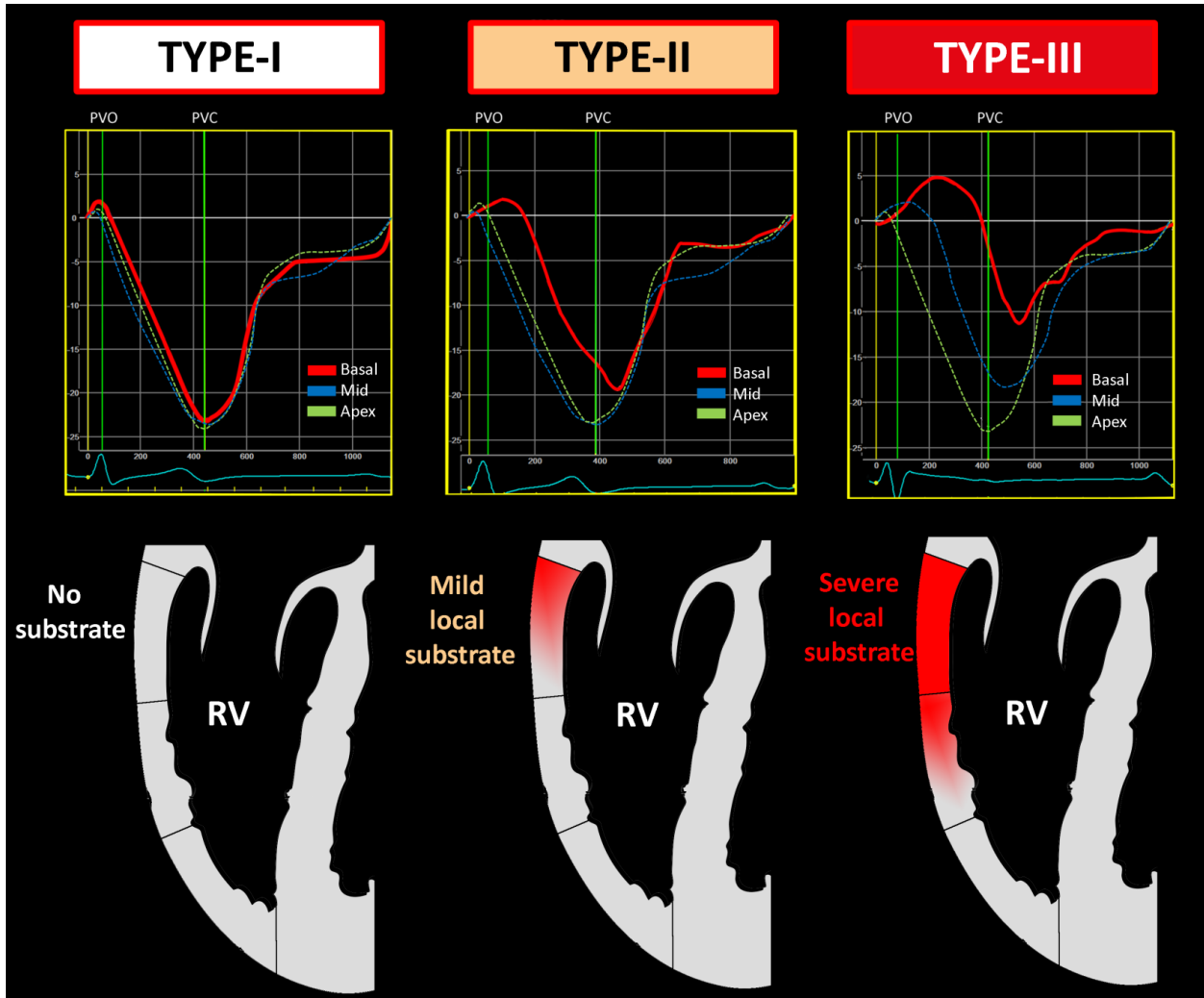
412 ARVC=arrhythmogenic right ventricular cardiomyopathy; CMR=cardiac magnetic resonance imaging;
413 *DSG2*=desmoglein-2; *DSP*=desmoplakin; LGE=late gadolinium enhancement; LVEF/RVEF=left/right ventricular
414 ejection fraction; *PKP2*=plakophilin-2; PLAX/PSAX=parasternal long/short axis view; *PLN*=phospholamban;
415 PVC=premature ventricular complexes; RBBB=right bundle branch block; RV-EDV=right ventricular end-diastolic
416 volume; RV-FAC=right ventricular fractional area change; RVOT=right ventricular outflow tract; TAD=terminal
417 activation duration; TFC=task force criteria; VT=ventricular tachycardia; WMA=wall motion abnormality.

418 Figure 1. Study design



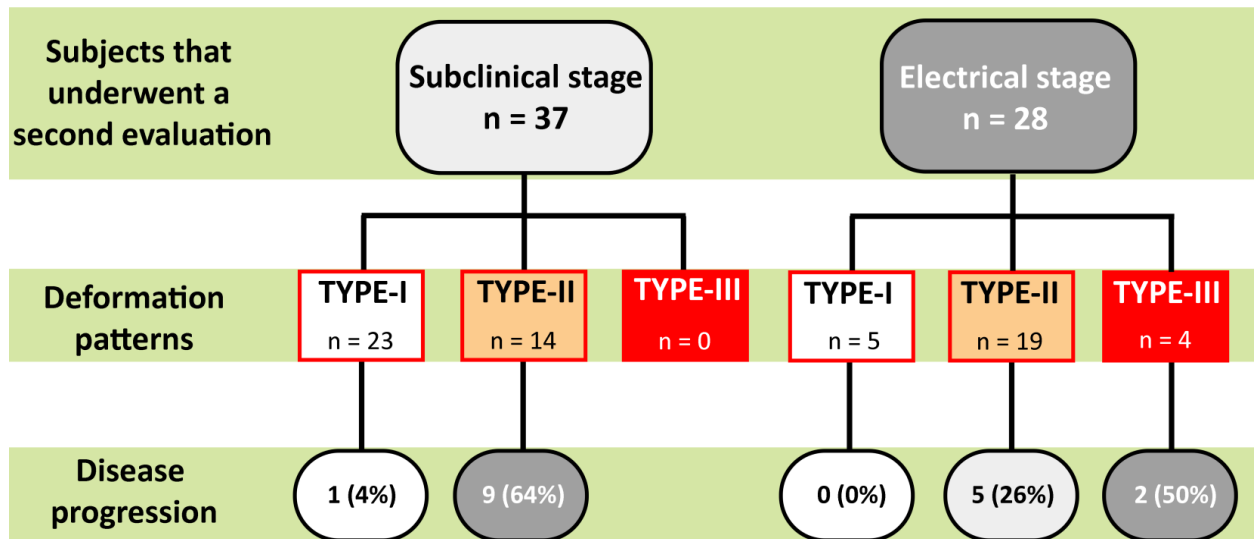
419

420 **Figure 2. Right ventricular deformation patterns**



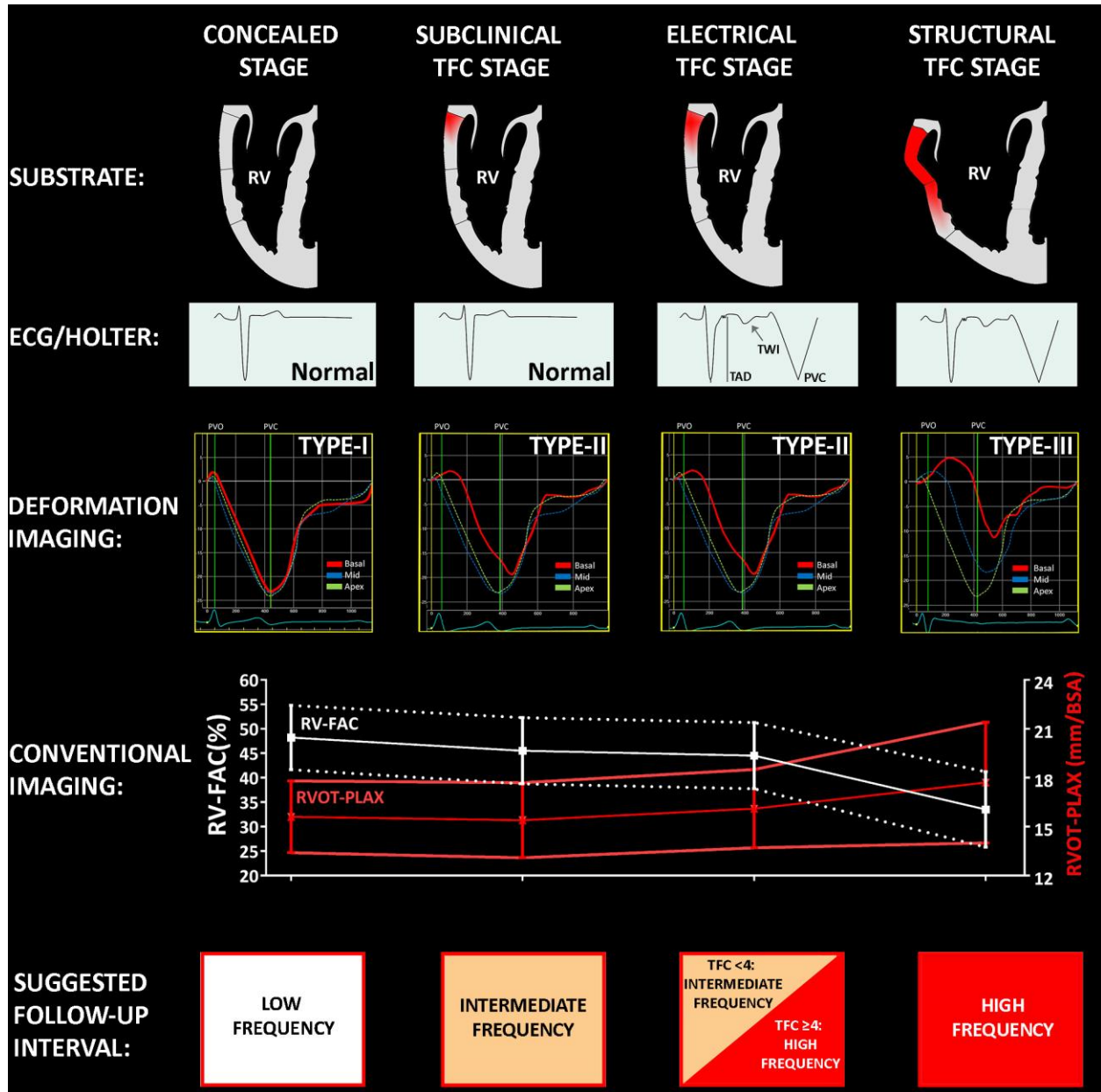
421

422 Figure 3. Rate of disease progression specified for deformation patterns and clinical stage at baseline



423

424 Figure 4. Suggested follow-up strategies in relatives depending on clinical ARVC stages



425