

**The predictive value of the presence of an amniotic sac without a visible embryonic heartbeat in the diagnosis of early embryonic demise**

W M Dooley<sup>1</sup>, L De Braud<sup>1</sup>, N Thanatsis<sup>1</sup>, M Memtsa<sup>1</sup>, E Jauniaux<sup>1</sup>, D Jurkovic<sup>1\*</sup>

<sup>1</sup>Institute for Women's Health, University College Hospital, London, UK

**\*Corresponding author:**

Davor Jurkovic

250 Euston Road, London NW1 6BU

[d.jurkovic@ucl.ac.uk](mailto:d.jurkovic@ucl.ac.uk)

**Short title:** Amniotic sac sign in the diagnosis of miscarriage

**Keywords:** Miscarriage, Spontaneous , Ultrasonography , Pregnancy Trimester, First , Amnion

**What are the novel findings of this work?**

This study is the largest study to show that the finding of an amniotic sac without a live embryo on ultrasound ('amniotic sac sign') is a reliable sign of early pregnancy failure.

**What are the clinical implications of this work?**

This is the first study of its kind to assess the impact that using the amniotic sac sign could have on reducing the need for follow up scans in cases of diagnostic uncertainty in early pregnancy.

This article has been accepted for publication and undergone full peer review but has not been through the copyediting, typesetting, pagination and proofreading process which may lead to differences between this version and the Version of Record. Please cite this article as doi: 10.1002/uog.23533

**Abstract: Objectives**

This study aimed to assess the diagnostic value and impact on management of early embryonic demise of visualising an amniotic sac without a live embryo on ultrasound imaging. We also examined the potential effect this finding would have on the rate of follow up visits in early pregnancy units if incorporated into current diagnostic algorithms.

**Methods**

This was a prospective cohort study assessing all pregnant women who attended a single specialist early pregnancy unit from July 2017 to November 2018 with symptoms of pain and/or bleeding, or with a history of ectopic pregnancy or miscarriage, at less than 14 weeks' gestation. The detailed initial ultrasound findings were documented including whether an amniotic sac was present in normally sited intrauterine pregnancies in the absence of a live embryo. Women were followed-up until a conclusive diagnosis was made.

**Results**

The study included 6012 women attending with early pregnancy complications during the study period. A conclusive diagnosis was reached on the initial scan in 4221 (70.2%), whilst 1135 (18.9%) had pregnancies of uncertain viability and 656 (10.9%) had pregnancies of unknown location. All women with pregnancies

of uncertain viability required follow up ultrasound scans to differentiate between live pregnancies and early embryonic demise. An amniotic sac in the absence of a live embryo was found in 174/1135 (15.3%) of women with pregnancies of uncertain viability at their initial ultrasound scan. In all cases the diagnosis of early embryonic demise was confirmed in all 134 of these women who attended their follow-up scans. The presence of amniotic sac without live embryo at the initial visit had a specificity of 100% (95% CI 98.53-100.00) and positive predictive value of 100% CI 87.37-88.24) in the diagnosis of early embryonic demise.

A total of 1403/6012 (23.3%) women were asked to attend for follow-up ultrasound scans to resolve diagnostic uncertainties. 268/656 (40.9%) women with PUL required follow up scans, so the majority of follow up scans needed to reach a conclusive diagnosis were in women with pregnancies of uncertain viability (1135/1403 (80.1%)). By using the presence of amniotic sac without a live embryo to diagnose miscarriage at the initial visit the number of follow-up scans for pregnancies of uncertain viability would be reduced by 14.4% which accounted for 11% of all follow up scans during the study period.

## Conclusions

Our study showed that the finding of an amniotic sac without a live embryo on ultrasound ('amniotic sac sign') is a reliable marker of early pregnancy failure

and could reduce the number of follow-up scans by 11% in cases of diagnostic uncertainty.

Accepted Article

## Introduction

Miscarriage is one of the most common complications of pregnancy and it has been estimated that 15-20% of clinically recognised pregnancies are lost during the first trimester.<sup>1-3</sup> The rates vary depending on the population characteristics, such as proportion of women older than 35 and other factors including pre-existing gynaecologic abnormalities. It has also been suggested that among symptomatic women attending early pregnancy units (EPUs) the rate of early pregnancy failure could be as high as 46%.<sup>4-6</sup> Clinicians aim to provide women with clear advice and accurate diagnosis of early pregnancy abnormalities. They should also endeavour to avoid delays in reaching an accurate diagnosis and decrease any period of uncertainty, which can have a psychological impact on pregnant women.<sup>7</sup>

Ultrasound, due to its non-invasiveness, safety and wide availability, is the main method for the diagnosis of early pregnancy complications. The location of pregnancy can be usually ascertained by a single ultrasound examination, but the differential diagnosis between a live early intrauterine pregnancy and early pregnancy failure can be difficult. Following several reports of apparently normal pregnancies being misdiagnosed as miscarriages, Abdallah et al<sup>8</sup> proposed new criteria to diagnose an early embryonic demise (EED), which were adopted by National Institute for Health and Care Excellence (NICE)<sup>9</sup> and American Institute for Ultrasound in Medicine<sup>10</sup>. According to these

criteria, an EED cannot be diagnosed unless there is an empty gestational sac measuring  $\geq 25$ mm in the mean diameter or an embryo with no cardiac activity with the crown rump length (CRL)  $\geq 7$ mm. These criteria include a high safety margin, which helps to prevent misdiagnosis, but a significant proportion of women need to attend for follow-up visits until a conclusive diagnosis is made. Additionally, in a number of cases the size of the gestational sac or embryo never reach these defined cut-offs, which could cause uncertainty about the diagnosis and lead to further unnecessary follow-up scans.

In 1995, McKenna et al. published a small series of 15 women who had an ultrasound scan in early pregnancy demonstrating an “empty amnion” – an amniotic sac which did not contain an embryonic pole.<sup>11</sup> Follow-up in all these cases confirmed the diagnosis of EED. Another study by Yegul et al. showed that all pregnancies with a visible amniotic sac containing an embryo without cardiac activity in their study population of 108 women, ended in miscarriage.<sup>12</sup>

The aim of our study was to assess the predictive value of visualising an amniotic sac without a live embryo (‘amniotic sac sign’) for the diagnosis of EED. We also looked to determine whether incorporating the amniotic sac sign into current diagnostic algorithms could have a significant effect on the rate of follow-up visits in EPU.

## Methods

This was a prospective cohort study carried out at a single specialist EPU from July 2017 to November 2018. We included all pregnant women who presented with symptoms of pain and/or bleeding at less than 14 weeks' gestation. In addition, reassurance ultrasound follow-up scans were offered to asymptomatic women with a history of ectopic pregnancy or miscarriage.

All women underwent a transvaginal ultrasound scan (TVS) using high-end ultrasound equipment (Voluson E8, GE Medical Systems, Milwaukee, WI, USA). The majority of the examinations were carried out by clinical fellows, who were all Level II operators, under the supervision of specialist gynecologists, the majority of whom were expert Level III operators.<sup>13</sup> In each case the following early pregnancy structures were examined if present: Gestational sac (spherical structure within the uterine cavity surrounded by echogenic trophoblast), yolk sac (small spherical structure within the gestational sac), embryonic/fetal pole (initially seen as a small hyperechoic structure adjacent to the yolk sac evolving into a recognizable embryo and eventually into a fetus) and amniotic sac (spherical structure within the gestational sac and distinct from the yolk sac, in which the embryonic pole, if present, is situated, Fig. 1). In all pregnancies with a visible embryonic/fetal

pole, the CRL was measured. When heart pulsations were present, the heart rate was routinely measured.



The following different diagnoses were made at the initial ultrasound scan:

- Live normally-sited intrauterine pregnancy – defined as the presence of gestational sac which was located within the uterine cavity and it contained a live embryo/fetus.
- Intrauterine pregnancy of uncertain viability– defined as the absence of an embryo in a gestational sac <25mm in mean diameter or the absence of cardiac activity in an embryo with the CRL <7mm.
- EED – defined as the presence of an empty normally sited gestational sac with a mean diameter  $\geq 25$ mm, or an embryo with a CRL  $\geq 7$ mm.
- Incomplete miscarriage – defined as the presence of solid hyperechoic trophoblastic tissue within the uterine cavity, with no visible gestational sac.
- Pregnancy of unknown location (PUL) – defined as the absence of a normally-sited or ectopic pregnancy in a clinically stable woman, with no evidence of significant hemoperitoneum.
- Ectopic Pregnancy – defined as a pregnancy which is located partially or completely outside the uterine cavity.

The management plan including follow-up ultrasound examination was based on clinical symptoms and the initial ultrasound findings. Women with live normally-sited intrauterine pregnancies were not routinely followed-up. Those who were not known to miscarry and did not follow up, were presumed to have ongoing pregnancies. Those with intrauterine pregnancies of uncertain viability

were offered another scan one to two weeks later. In cases of PUL, follow-up was based on the results of a serum  $\beta$ -hCG and progesterone level using our previously published protocol.<sup>14</sup> A spontaneous resolution of pregnancy was defined as a decrease of serum  $\beta$ -hCG levels to  $<20\text{iu/L}$  with a complete resolution of symptoms, without the need for any therapeutic intervention. The location of these pregnancies therefore remained unknown.

The diagnosis on the follow up scans in cases of pregnancies of uncertain viability were defined as:

- Live normally-sited intrauterine pregnancy – defined as above.
- Early embryonic demise – defined as a pregnancy without a live embryo/fetus which had not progressed as expected over a period of follow up, with a minimum interval between the visits of 7 days.
- Incomplete miscarriage – defined as above.
- Complete miscarriage – defined as an empty uterine cavity in women with conclusive evidence of a normally-sited intrauterine pregnancy on previous ultrasound scan.

Statistical analysis of the data was performed using Statistical Package for Social Sciences (SPSS, version 25, 2017). The baseline variables for normality of distribution were tested using the Shapiro-Wilk test. The averages of values which demonstrated normal distribution were expressed as mean and standard deviation (SD). A p value of  $<0.05$  was considered statistically significant.

We estimated that we would need to recruit a minimum of 520 women with pregnancies of uncertain viability, assuming 15% prevalence<sup>12</sup> of the finding of the amniotic sac with no live embryo and specificity of 90% for the diagnosis early embryonic demise with a 3% margin of error and loss to follow up rate of 15%.<sup>15</sup> We sought advice from the Joint Research Office of University College London and University College London Hospital regarding ethical approval and were advised that formal ethics approval was not needed for this study as the data were collected as a part of routine clinical care, were anonymised, and were analysed within the clinical care team. The study has been registered with the Research Registry (Unique Identifying Number: 5885)

## Results

During the study period, 6012 pregnant women attended the EPU with clinical symptoms suggestive of early pregnancy complications. A flowchart showing the initial scan findings and final diagnoses is shown in Figure 2.

The mean maternal age was 33.2 (SD 6.1) years old and the mean gestational age was 7 weeks and 5 days (SD 21 days). The other demographic data is summarised in Table 1.

A conclusive diagnosis was reached on the initial ultrasound scan in 4221/6012 (70.2%) of cases. There were 656 (10.9%) PUL and 1135 (18.9%) were classified as pregnancies of uncertain viability. The majority of women with PUL, 388/656 (59.1%, 95% CI 55.3-62.9) did not require further follow-up ultrasound scans and their serum  $\beta$ -hCG declined to the pre-pregnancy values without the need for any medical intervention. Out of the remaining women 245/656 (37.3%, 95% CI 33.6-41.2) attended for one, 20 (3.0%, 95% CI 1.9-4.7) for two, 2 (0.3%, 95% CI 0-1.0) for three and one (0.2%, 95% CI 0-0.8) woman required four further ultrasound scans to establish the location of the pregnancy. The total number of follow up scans in this subgroup of women was 295.

The morphological features of the pregnancies of uncertain viability are shown in Table 2. All women with pregnancies of uncertain viability were offered follow-up scans, but only 877/1135 (77%) women attended. In 810/877 (92.4%) a conclusive diagnosis was reached at the first follow up visit; whilst 60/877

(6.8%) had two and 7/877 (0.8%) women required three or more additional ultrasound scans. The total number of follow-up visits required to differentiate between live normally sited pregnancies and early embryonic demise was 951. The list of the final diagnoses for women initially found to have pregnancy of uncertain viability is provided in Table 3.

In the subgroup of women who completed follow-up, 312/877 (35.6%) had an embryo <7mm with no cardiac activity the initial scan. At the completion of follow up there was evidence of cardiac activity in 41/312 (13.1%) cases. The largest embryo with no visible cardiac activity, which progressed to be confirmed as a live pregnancy measured 3.0mm in the CRL on the initial ultrasound scan.

In 134/877 (15.3%) women, a visible amniotic sac and absent embryo or embryo with CRL <7mm with no cardiac activity was seen on the initial scan; the diagnosis of EED was confirmed on follow-up examinations in all of these women. A total of 137 follow-up scans were performed in the follow-up period for these women; with 131 having one additional scan and three women requiring two follow-up ultrasound scans each. The presence of an amniotic sac without live embryo at the initial visit had a sensitivity of 21.34% (95% CI 18.19-24.75), specificity of 100% (95% CI 98.53-100.00), positive predictive value of 100%, negative predictive value of 87.81 (95% CI 87.37-88.24), negative likelihood ratio of 0.79 (95% CI 0.76-0.82) and accuracy of 88.20% (95% CI 85.88-90.26) for the detection of early pregnancy failure.

A total of 1403/6012 (23.3%) women were asked to attend for follow-up ultrasound scans to resolve diagnostic uncertainties. The majority of these [1135/1403 (80.1%)] were for pregnancies of uncertain viability. By using the presence of an amniotic sac without a live embryo to diagnose miscarriage the number of women with pregnancies of uncertain viability needing follow-up scans could be reduced by 15.3% (134/877). The number of follow-up scans for this indication would be reduced by 14.4% (137/951) which accounted for 11% (137/1246) of all follow-up scans during the study period.

## Discussion

Our study showed that the finding of an amniotic sac without a live embryo on ultrasound ('amniotic sac sign') is a reliable sign of early pregnancy failure.

There were no false positive diagnoses of miscarriage in women with this finding, giving a positive predictive value of 100%. We found that almost one in four women attending our EPU were asked to attend for follow-up visits because of inconclusive ultrasound findings. Four fifths of these scans were carried out in women with pregnancies of uncertain viability. The amniotic sac sign was present in 15.3% of these women. If the amniotic sac sign was used as a part of diagnostic algorithm none of these women would need to attend for follow up visits. This would have reduced the total number of follow up scans in our EPU by 11%.

Our findings are concordant with the studies published by McKenna and Yegul, which also demonstrated that detecting an amniotic sac in the absence of a live embryo is accurate in diagnosing miscarriage. However, these previous studies were retrospective in design and were published before the current criteria for diagnosis of miscarriage were in use. Additionally, they did not assess the impact that implementing these findings would have on service provision and on the number of follow-up appointments required to reach a certain diagnosis.

The amnion becomes visible on transvaginal ultrasound from 6.5-7 weeks' gestation<sup>16</sup> as a result of water transfer through the chorionic cavity and then progressively from fetal urine production<sup>17</sup>. In normal pregnancies, when visible on ultrasound, it should contain a live embryo of 7-12 mm in length. This explains why the absence of a live embryo within the amniotic sac is an accurate predictor of miscarriage. One of the causes of misdiagnosis of miscarriage on ultrasound is the misinterpretation of the irregularities of the inner wall of the gestational sac as an early embryonic structure. The presence of amniotic sac prevents such errors as the examiners are guided to search for an embryo within the smooth and well defined boundaries of the amniotic sac. However, in monochorionic twins there is a risk of misinterpreting a second yolk sac as an amniotic sac. The amniotic sac is larger and its membrane is thinner compared to the yolk sac, which helps to avoid such errors.

Measurements of amniotic sac size are not routinely carried out in the majority of EPU's in the UK, which is reflected both in NICE guideline and the original paper by Abdallah.<sup>8,9</sup> This could be explained by the use of transabdominal scans to assess early pregnancy in the past, and this did not always have sufficient resolution to provide a clear image of the amniotic sac in the first trimester i.e. the amniotic membranes during the first trimester resulting in both cavities being measured in a single measurement. It is also possible that the amniotic sac has not been assessed and measured simply because of the



Accepted Article

lack of evidence showing the value of its visualisation for the diagnosis of early pregnancy complications.

The ratio of new to follow-up visits is often used as an indicator to assess the quality and productivity of various health services. In the UK, the National Health Service tariffs for outpatient care provision have been set in a way to award greater tariffs for the first clinical appointment to encourage reduction in the number of unnecessary follow-up visits.<sup>18</sup> In addition to the financial benefits associated with a reduction in follow-up visits, the use of amniotic sac sign could free up capacity in EPU and reduce waiting times for ultrasound scans. A reduction in the number of follow-up visits also decreases the impact of women's social disruption, work absences, child care and travel costs. It has also been shown that diagnostic uncertainty causes significant anxiety to pregnant women.<sup>7</sup> In particular, Richardson et al.<sup>7</sup> demonstrated that anxiety levels decrease over time when a certain diagnosis is reached, even if the outcome is a negative one, whereas anxiety levels increased when women were given an uncertain diagnosis.

The main strengths of our study are its prospective design and the large number of cases included in the analysis. A possible limitation is the fact that our study was carried out in a tertiary referral EPU with a high level of specialist expertise in both early pregnancy care and ultrasound imaging. We have been recording the presence and size of the amniotic sac routinely during early pregnancy scans for a long period of time. This may make our results not

reproducible in units with less expertise in early pregnancy ultrasound, particularly when the operators are not used to assessing the amniotic cavity and membrane. Although our study is the largest of this type published so far, the absolute number of women with positive amniotic sac sign was limited and further work is needed to confirm validity of our findings.

In conclusion, our study has shown that the amniotic sac sign is a reliable ultrasound feature of early pregnancy failure which could be used in clinical practice to improve the accuracy of ultrasound diagnosis of miscarriage and reduce the need for follow up visits. Future work is needed to evaluate whether our findings could be reproduced in other units with different levels of ultrasound expertise and set ups, particularly regarding differing clinical populations and access to services.

## **Acknowledgements**

We would like to acknowledge all the dedication and hard work put in by the whole team at the University College London Hospital EPU.

## References

1. Buss L, Tolstrup J, Munk C, Bergholt T, Ottesen B, Grønbaek M, Kjaer SK. Spontaneous abortion: A prospective cohort study of younger women from the general population in Denmark. Validation, occurrence and risk determinants. *Acta Obstet Gyn Scan* 2006; **85**, 467–475.
2. Avalos LA, Galindo C, Li D. A systematic review to calculate background miscarriage rates using life table analysis. *Birth Defects Res A Clin Mol Teratol* 2012; **94**, 417–423.
3. Elish NJ, Saboda K, O'Connor J, Nasca PC, Stanek EJ, Boyle C. A prospective study of early pregnancy loss. *Hum Reprod* 1996; **11**, 406–412.
4. Bigrigg MA, Read, MD. Management of women referred to early pregnancy assessment unit: care and cost effectiveness. *BMJ* 1991; **302**, 577–579.
5. Schauburger CW, Mathiason MA, Rooney BL. Ultrasound assessment of first-trimester bleeding. *Obstet Gynecol* 2005; **105**, 333–338.
6. Shillito J, Walker JJ. Early pregnancy assessment units. *Br J Hosp Med* 1997; **58**, 505–509.
7. Richardson A, Raine-Fenning N, Deb S, Campbell B, Vedhara K. Anxiety associated with diagnostic uncertainty in early pregnancy. *Ultrasound Obstet Gynecol* 2017; **50**, 247–254.
8. Abdallah Y, Daemen A, Kirk E, Pexsters A, Naji O, Stalder C, Gould D, Ahmed S, Guha S, Syed S, Bottomley C, Timmerman D, Bourne T. Limitations of current definitions of miscarriage using mean gestational sac diameter and crown-rump length measurements: a multicenter observational study. *Ultrasound Obstet Gynecol* 2011; **38**, 497–502.
9. National Institute for Health and Care Excellence (NICE). Ectopic pregnancy and miscarriage: diagnosis and initial management (NG126). 2019. Available from: [www.nice.org.uk/guidance/ng126](http://www.nice.org.uk/guidance/ng126) (viewed 22nd August 2020).
10. Doubilet PM, Benson CB, Bourne T, Blaivas M, Society of Radiologists in Ultrasound Multispecialty Panel on Early First Trimester Diagnosis of Miscarriage and Exclusion of a Viable Intrauterine Pregnancy; Barnhart KT, Benacerraf BR, Brown DL, Filly RA, Fox JC, Goldstein SR, Kendall JL, Lyons

EA, Porter MB, Pretorius DH, Timor-Tritsch IE. Diagnostic criteria for nonviable pregnancy early in the first trimester. *N Engl J* 2013; **369**, 1443–1451.

11. McKenna KM, Feldstein VA, Goldstein RB, Filly RA. The empty amnion: a sign of early pregnancy failure. *J Ultrasound Med* 1995; **14**, 117–121.

12. Yegul NT, Filly RA. The Expanded Amnion Sign. *J Ultrasound Med* 2009; **28**, 1331–1335.

13. Education and Practical Standards Committee, European Federation of Societies for Ultrasound in Medicine and Biology. Minimum training recommendations for the practice of medical ultrasound. *Ultraschall Med* 2006; **27**, 79–105.

14. Cordina M, Schramm-Gajraj K, Ross J, Lautman K, Jurkovic D. Introduction of a single visit protocol in the management of selected patients with pregnancy of unknown location: a prospective study. *BJOG* 2011; **118**, 693–697.

15. Hajian-Tilaki K. Sample size estimation in diagnostic test studies of biomedical informatics. *J Biomed Inform* 2014; **48**, 193–204.

16. Benson C, Doubilet P, Benacerraf B, Beryl R. Atlas of Ultrasound in Obstetrics and Gynecology: A Multimedia Reference. 3<sup>rd</sup> Edition. London: Lippincott Williams & Wilkins, 2019.

17. Gulbis B, Jauniaux E, Jurkovic D, Gervy C, Ooms HA. Biochemical Investigation of Fetal Renal Maturation in Early Pregnancy. *Pediatr Res* 1996; **39**, 731–735.

18. National Health Service England and National Health Service Improvement 2019/20 National Tariff Payment System. March 2019. Accessed: [https://improvement.nhs.uk/documents/4980/1920\\_National\\_Tariff\\_Payment\\_System.pdf](https://improvement.nhs.uk/documents/4980/1920_National_Tariff_Payment_System.pdf)

## Figure Legends

Figure 1 a) Ultrasound image showing a gestational sac (GS), a yolk sac (Y) and an amniotic

sac (A) with a live embryo (E); b) image of an amniotic sac (A) with a small embryonic pole

without cardiac activity (short arrow) and a yolk sac (Y) adjacent to it (long arrow); (c) an

empty amniotic sac (A) and a yolk sac (Y) within a gestational sac (GS)

Figure 2 Chart of the flow of patients through our study with the initial diagnosis of either normally sited IUP, PUL, EED, incomplete miscarriage or EP. Where the

diagnosis was not conclusive on the first scan, women were followed up until one was made.

IUP, intrauterine pregnancy; PUL, pregnancy of unknown location; EED, early embryonic demise; EP, ectopic pregnancy; DNA, did not attend.

**Table 1** Demographic data for 6012 women who attended the Early Pregnancy

	Category/term	n (%)
Parity	0	3350 (55.7)
	1	1592 (26.5)
	2+	1070 (17.8)
Gravidity	1	1909 (31.8)
	2	1656 (27.5)
	3+	2447 (40.7)
History of miscarriage		1876 (31.2)
History of ectopic pregnancy		278 (4.4)
ART		499 (8.3)

Unit with clinical symptoms suggestive of early pregnancy complications.

*ART, Assisted Reproductive Therapy*

**Table 2** Morphological feature of pregnancies of uncertain viability on the initial scan (n=1135)

Morphology	n (%)
Empty gestational sac <25mm	425 (37.4)
Gestational sac <25mm, yolk sac, no visible embryo	324 (28.5)
Gestational sac, yolk sac, embryo <7mm, no visible heartbeat	212 (18.7)
Gestational sac, yolk sac, amniotic sac, embryo <7mm, no visible heartbeat	149 (13.1)
Gestational sac <25mm, yolk sac, empty amniotic sac, no visible embryo	25 (2.2)



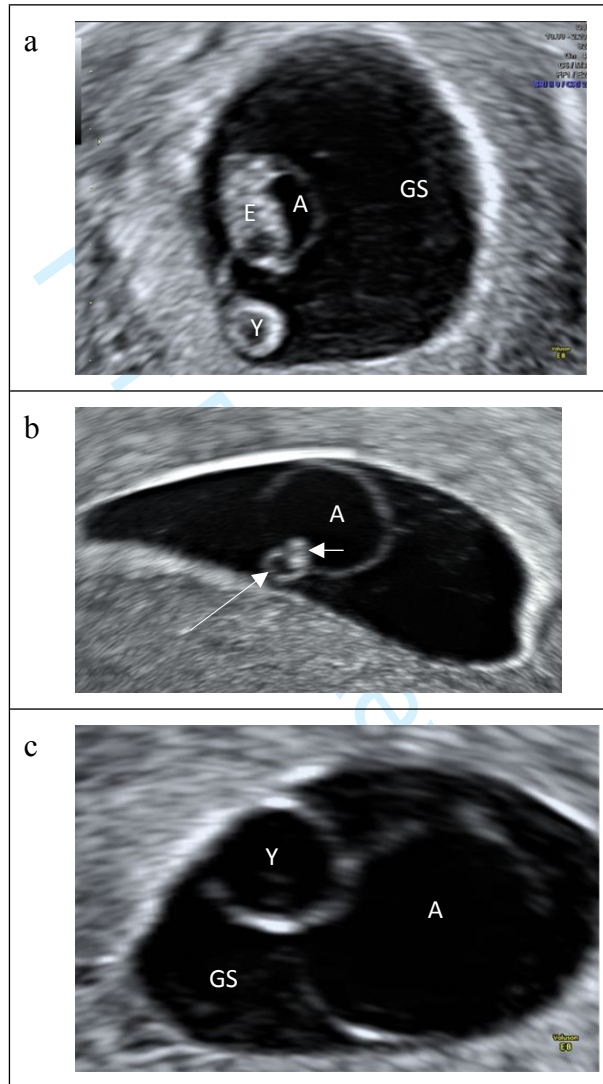
**Table 3** Morphological features of pregnancies of uncertain viability on the initial scan and final diagnosis after completed follow up, n=877.

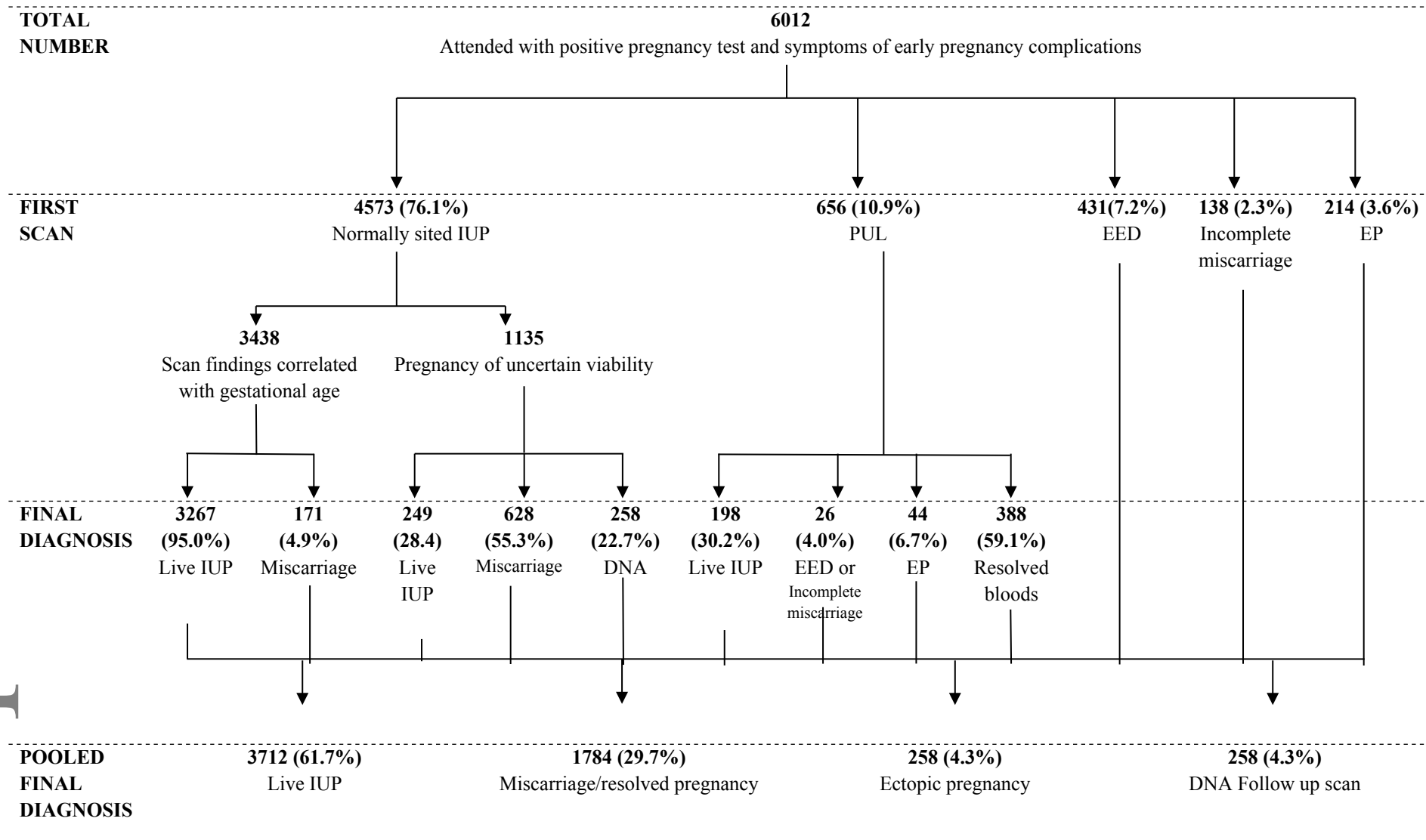
Morphology on initial scan	Live pregnancy, n (%)	Final Diagnosis			Completed follow up
		EED, n (%)	Incomplete miscarriage, n (%)	Complete miscarriage, n (%)	
Empty gestational sac <25mm	80 (25.4)	147 (46.7)	51 (16.2)	37 (11.7)	315
Gestational sac <25mm, yolk sac, no visible embryo	110 (48.0)	76 (33.2)	31 (13.5)	12 (5.2)	229
Gestational sac, yolk sac, embryo <7mm, - no visible heartbeat	41 (20.6)	101 (50.8)	40 (20.1)	17 (8.5)	199
Gestational sac, yolk sac, amniotic sac, embryo <7mm, no visible heartbeat	0 (0)	71 (62.8)	32 (28.3)	10 (8.8)	113
Gestational sac <25mm, yolk sac, empty amniotic sac, no visible embryo	0 (0)	15 (71.4)	5 (23.8)	1 (4.8)	21
<b>Total</b>	<b>410</b>	<b>231</b>	<b>159</b>	<b>77</b>	<b>877</b>

*EED = early embryonic demise;*

Accepted Article

**Figure 1** a) Ultrasound image showing a gestational sac (GS), a yolk sac (Y) and an amniotic sac (A) with a live embryo (E); b) image of an amniotic sac (A) with a small embryonic pole without cardiac activity (short arrow) and a yolk sac (Y) adjacent to it (long arrow); (c) an empty amniotic sac (A) and a yolk sac (Y) within a gestational sac (GS)





**Figure 2** Chart of the flow of patients through our study with the initial diagnosis of either normally sited IUP, PUL, EED, incomplete miscarriage or EP. Where the diagnosis was not conclusive on the first scan, women were followed up until one was made.

*IUP, intrauterine pregnancy; PUL, pregnancy of unknown location; EED, early embryonic demise; EP, ectopic pregnancy; DNA, did not attend.*