

Title: Ultrawide field imaging assessment of small choroidal pigmented lesions using red and green colour channels.

Authors:

1. Vasilios P. Papastefanou¹
2. Rana'a T. Al-Jamal¹
3. Zaria Christine Ali²
4. Victoria ML Cohen¹
5. Jane Gray³
6. Mandeep S. Sagoo^{1,3}
7. Konstantinos Balaskas^{1,2,4}

Affiliated Institutions:

1. Medical Retina Service/ Ocular Oncology Service, Moorfields Eye Hospital, 162 City Road, London. England. United Kingdom. EC1V 2PD
2. Medical Retina Department, Manchester Royal Eye Hospital, Oxford Road, Manchester. England. United Kingdom. M13 9WL
3. Institute of Ophthalmology, University College London, 11-43 Bath Street, London. England. United Kingdom. EC1V 9EL
4. Diagnostics Ophthalmic Angiography and Imaging services, Manchester Royal Eye Hospital, Oxford Road, Manchester. England. United Kingdom. M13 9WL

Corresponding Author: Konstantinos Balaskas, Reading Centre – Medical Retina Service, Moorfields Eye Hospital

E-mail: konstantinos.balaskas@moorfields.nhs.uk

SYNOPSIS

This study demonstrates the utility of red-green channel patterns in ultrawide field imaging in the assessment of small choroidal melanotic tumours. Results prove this is not a reliable approach for early diagnosis of small melanomas.

ABSTRACT

Background

Diagnosis of small choroidal melanoma is mainly based on tumour thickness, subretinal fluid or lipofuscin pigment. Ultra-wide field imaging (UWF) allows depiction of choroidal lesions through a red (RC) and a green channel (GC). Aim of the study was to determine the utility of this tool in the detection of small choroidal melanoma.

Methods

Retrospective cross-sectional study of patients with small choroidal pigmented lesions up to 3 mm in thickness. All patients underwent clinical and imaging assessment including UWF. Lesions were subcategorized based on thickness and lesion type. A qualitative assessment ensued using the red and green channels feature.

Results

A total of 152 patients were included. Melanotic naevi(76/152,50%) and small choroidal melanomas(55/152,36%) were the predominant types. Thickness was <1mm in 30%(46/152), 1-2mm in 46%(70/152) and 2-3mm in 24%(36/152) of cases. Two distinct imaging patterns were noted: dark on RC/undetectable on GC and dark on RC/light on GC.

In melanotic naevi the dark on RC/light on GC pattern was significantly associated with increased tumour thickness($p=0.006$) and the presence of lipofuscin($p<0.001$) suggesting a potential prognostic significance.

In small melanomas such an association was not established. The majority of small melanomas manifested a dark on RC/undetectable on GC pattern despite the presence of subretinal fluid and lipofuscin.

Conclusions

UWF imaging of choroidal pigmented tumours with red-green channels revealed two distinct patterns. The dark on RC/light on GC pattern was more common in suspicious melanotic naevi, but not in small melanomas. The use of red-green channels is not a reliable diagnostic tool in the early detection of small melanomas.

INTRODUCTION

Choroidal naevi are common benign tumours found in 6-7% of the Caucasian population [1,2]. Naevi are often monitored due to the small risk of malignant transformation into life threatening choroidal melanomas [1-6]. Clinical risk factors for malignant transformation of choroidal naevi are well established and ascribe the level of suspicion and hence determine the frequency of monitoring [7].

Identifying naevi with suspicious features has evolved from colour fundus photography and ultrasound B mode scan, to using optical coherence tomography (OCT) to detect subclinical subretinal fluid and/or autofluorescence to confirm lipofuscin. [7] The Optomap (Optos plc, Dunfermline, Scotland) is a digital ultra-widefield retinal imaging system (Scanning Laser Ophthalmoscope), which provides a non-mydratic, 82% view (200°) of the fundus. A single fundus image is captured with two low-powered laser wavelengths: red channel at 633nm (RC) and green channel at 532nm (GC) that scan the retina simultaneously. The single image can be deconstructed to see the individual wavelength views. The GC permits a view from the sensory retina to the retinal pigment epithelium (RPE), and the RC scans the deeper structures from the RPE to the choroid.

The aim of this study is to examine the potential use of the red-green channel feature of ultra-wide field imaging in the early detection of a suspicious choroidal naevus or a small choroidal melanoma through the assessment of a large series of small choroidal pigmented lesions.

METHODS

This is a retrospective study of patients referred for further assessment of pigmented fundus lesions to Manchester Royal Eye Hospital and Moorfields Eye Hospital from January 2016 to January 2018 . As part of their routine care, these patients underwent a series of imaging tests performed by trained imaging technicians including ultrasound B-scan, autofluorescence, OCT and ultra-wide-field imaging (Optos California and 200Tx - Optos plc, Dunfermline, Scotland)

Patient demographics and tumour features (thickness, drusen, orange pigment, subretinal fluid and fibrosis) were recorded. The ultra-wide field images were then reviewed in both the red and green channels by adjusting the blend function of the software.

Lesions were subcategorized based on thickness on B-scan ultrasound (0-1, 1-2 and 2-3mm) and according to lesion type (melanotic choroidal naevi, amelanotic choroidal naevi, halo naevi, suspicious naevi and small melanomas). Detectability was qualitatively characterized as Dark, Light or not detectable following assessment by two experienced ophthalmologists.(VP, CAZ)

Descriptive statistical analysis with the χ^2 and t-test were used to evaluate the findings after prior Kolmogorov-Smirnov testing for normal distribution of the results, A difference of 0.05 was considered statistically significant. Analysis was done with Wizard Pro 1.9.26 (USA)

RESULTS

Patient demographics and tumours

A total of 152 cases were included in this study.. Patient demographics and tumour features are summarized in Table 1. The lesions assessed were melanotic naevi (76/152, 50%), amelanotic naevi (3/152, 2%), halo naevi (3/152, 2%), suspicious naevi (15/152, 10%) and small choroidal melanomas (55/152, 36%). The two predominant categories, namely, melanotic naevi and small melanomas were analysed. All choroidal melanomas were stage I (T10 N0 M0) based on the 8TH Edition of AJCC classification [8].

Red vs green channel analysis on the two predominant tumour types.

Melanotic naevi

There were 76 cases in the melanotic naevus group. The mean tumour thickness on ultrasound was 0.9 ± 0.1 mm. The clinical features of the melanotic naevus group are presented in Table 2A. RC and GC yielded two principal patterns of detectability: (a) Dark on RC / undetectable on GC (57/76, 75%); and (b) Dark on RC / light on GC (15/76, 20%). (Table 2A, Figures 1,2)

Analysis of the clinical features of the lesions with respect to these two patterns showed some differences. The dark on RC/light on GC pattern occurred in slightly thicker tumours (1.2 ± 0.2 mm vs 0.8 ± 0.2 mm, $p=0.006$) and in the presence of orange pigment (27 % vs 2%, $p<0.001$). The presence of subretinal fluid (7% vs 2%, $p=0.3$) did not reach statistical significance. (Table 2A)

Small Choroidal Melanomas

The small melanoma group comprised 55 cases. The mean tumour thickness was 2.7 ± 0.3 mm. The clinical features of the small melanoma group are presented in Table 2B. RC and GC gave the same two patterns of detectability: (a) Dark on RC / undetectable on GC (40/55, 73%) and dark on RC / light on GC (12/55, 22%).

Analysis of the clinical features of small melanomas with respect to these two patterns showed similar differences. The dark on RC/light on GC pattern was associated with increased tumour thickness (2.7 ± 0.3 mm vs 2 ± 0.2 mm, $p < 0.001$), a finding that occurred even in the 2-3 mm in tumour thickness subgroup. Despite this trend with tumour size, the majority of small melanomas displayed the other pattern, dark on RC/undetectable on GC (40/55, 73%). Contrary to the naevus cohort, the presence of orange pigment was associated more commonly in melanomas with the dark on RC/undetectable on GC pattern (93% vs 67%, $p = 0.02$).

RC/GC analysis based on tumour thickness

All lesions were categorized by tumour thickness into 3 groups, namely 0-1mm (n=46, median 0.5 mm, mean 0.5 ± 0.06), 1-2 mm (n=70, median 1.2, mean 1.4 ± 0.07) and 2-3mm (n=36, median 2.5, mean 2.6 ± 0.1). The features of each group are presented in Table 3. The proportion of dark on RC / light on GC pattern increased according to the thickness of the tumour, 8.9 % in the 0-1 mm thickness group, 24.6 % in the 1-2 mm group and 30.6 % in the 2-3 mm group ($p = 0.04$). (Figure 3A-supplemental figure).

We also analysed the RC / GC pattern to determine the association with size. (Figure 3B – supplemental figure) In the dark on RC/light on GC group, 13 % of lesions were 0-1 mm, 52 % were 1-2mm and 36 % were 2-3 mm. In the dark on RC/undetectable on GC group 36 % were 0-1 mm, 43 % were 1-2 mm and 22% were 2-3 mm thickness. By thickness, the 2 patterns differed with statistical significance only in the 0-1 mm group. ($\chi^2=0.015$)

Red vs green channel analysis based on tumour features

Drusen

Drusen were present in 60/152 (39%) tumours. The distribution of drusen was equal for all thickness categories (Table 3A and equivalent between the two channels (Table 3B). There was no correlation with the lesion detectability patterns ($\chi^2=0.65$) (Figure 4A-supplemental figure)

Orange pigment

Orange pigment was present in 62/152 (41%) of tumours. The frequency of orange pigment increased by thickness categories – 7% in 0-1mm tumours, 44% in 1-2mm tumours and 78% in 2-3mm tumours respectively.(Table 3A) Orange pigment detection was equivalently distributed between the two channels (Table 3B) but did not correlate with lesion detectability patterns ($\chi^2=0.66$) (Figure 4B-supplemental figure)

Subretinal fluid

Subretinal fluid was present in 40/152 (26%) tumours. The frequency of subretinal fluid increased with thickness categories – 7% in 0-1mm tumours, 21% in 1-2mm tumours and 61% in 2-3mm tumours respectively. (Table 3A) Subretinal fluid was better detected in the green channel for 20/55 small CMM and 6/15 IML (Table 3B). The lesion detectability patterns did not correlate with the presence of subretinal fluid ($\chi^2=0.8$) (Figure 4C-supplemental figure)

Fibrosis

Overlying fibrosis was present in 52/152 (34%) tumours. Similarly, there was an increase in frequency of fibrosis by thickness groups – 9% in 0-1mm tumours, 34% in 1-2mm tumours and 67% in 2-3mm tumours respectively. (Table 3A) The distribution was identical between channels (Table 3B). The lesion detectability patterns did not correlate with the presence of fibrosis ($\chi^2=0.3$) (Figure 4D-supplemental figure)

DISCUSSION

Choroidal naevi are common benign intraocular tumours with prevalence in large population studies of approximately 7%, though it may be as high as 20-25% [1]. It is therefore important to detect suspicious features at an early stage [1-6]. Melanocytic fundus tumours that have one suspicious feature have a 38% chance for growth at five years, rising to 50% for those with two or more suspicious features. [7].

In recent years, modern imaging modalities have been harnessed in the assessment of choroidal lesions. OCT has improved visibility of the choroid as enhanced depth imaging or swept-source OCT [9-10], autofluorescence scans have confirmed lipofuscin deposition [11] and optical coherence tomography angiography may give information on blood flow. [12]

Ultrawide field imaging has been an important addition in this array of imaging modalities because of the ability to capture a wide area of the fundus. In the assessment of intraocular tumours, it has allowed better depiction of the extent of sizable or very peripheral tumours not easily captured with previously available cameras. [13] In light of this principal advantage ultra-wide field imaging has also been adopted in the community in optometry practices as part of a quick means to assess the fundus and help in the identification of peripherally located disease.

This study examined this feature of the dual laser imaging platform. The blend function allows separation of the fundus through two distinct channels, the green laser (GC) scanning from the sensory retina to the RPE, and the red laser (RC) scanning the deeper structures from the RPE to the choroid. A large cohort of patients with pigmented choroidal lesions was assessed and different categories were included with the predominant ones being benign melanotic choroidal naevi and small choroidal melanomas. The aim of this study was to determine whether RC and GC separation would allow the identification of early signs of transformation from naevus to melanoma. Previous studies [14] suggested that malignant melanomas appeared dark in the red channel and bright in the green channel with the use of this imaging platform. In addition, we subcategorized lesions by thickness in order to identify any distinctive features for growth, including the 2-3 mm size of small melanomas. This is the threshold for small choroidal melanoma based on the 8th edition AJCC classification [8]. Detection of small melanomas is important as early treatment may impact on mortality. [7]

Our RC and GC patterns analysis compared benign melanotic naevi and small choroidal melanomas. Indeterminate melanocytic lesions and suspicious naevi were excluded due to their small numbers in this cohort. The important finding in this first comparison was the presence of two distinct patterns on RC and GC in the vast majority of cases namely that 72/76 cases in the melanotic naevi group and 52/55 cases in the small choroidal melanoma group were either dark on RC / undetectable on GC or dark on RC /light on GC. The remaining 7 cases were not clearly characterized and therefore not included in this analysis.

Analysis of the predominant patterns indicated that dark on RC/ light on GC melanotic naevi were significantly thicker, significantly associated with the presence of orange pigment and there was a trend towards subretinal fluid. In the case of established small melanomas however, the vast majority were dark on RC / undetectable on GC.

Kernt et al. [14] found that dark on RC /light on GC was distinctive of malignant melanoma. Their study compared 29 choroidal melanomas with 20 naevi but there are some differences to our study. Our lesions were smaller compared to sizes ranging from 7 to 20 mm therefore including stage II, III and IV lesions [15]. Apart from size the only other clinical feature evaluated by Kernt et al. [14] was the presence or absence of subretinal fluid, whereas we examined the presence of drusen, orange pigment, subretinal fluid and fibrosis and whether these affect the detectability of the lesion. These differences may affect the disparity of our results. In the choroidal naevi group the presence of the dark on RC/ light on GC pattern indeed increases the index of suspicion for the fraction of tumours falling under this category. These were lesions with greater thickness and higher chance of lipofuscin and subretinal fluid.

Extrapolating from this result in the naevus group, the small melanoma group should also manifest dark on RC/light on GC pattern. This was not the case. Despite a significantly greater tumour thickness, the vast majority of small choroidal melanomas were not detectable with GC and importantly the lipofuscin deposits spotted clinically were not detectable either at a significantly higher rate.

Autofluorescence scans remain important in the assessment of lipofuscin deposits [9]. On the other hand the red channel may be superior to autofluorescence for the follow up of choroidal naevi, due to deeper penetration. [15]

When this cohort was analyzed with tumour thickness as the sole parameter the dark on RC/ light on GC pattern tended to increase significantly from 8.9% in the 0-1mm category to 30.6% in the 2-3mm category (Figure 3A-supplemental figure). However among dark to light lesions falling under the 1-2mm and 2-3 mm categories frequency of dark on RC/ light on GC was higher but not significant. (Figure 3B-supplemental figure)

Would therefore the dark on RC /light on GC pattern be of prognostic significance? As the green channel penetrates through the neurosensory retina up to the RPE layer, it is difficult to claim that it could capture an inherent property of the underlying choroidal lesion, such as a metabolic or vascular feature indicative of growth. A plausible explanation is that the lighter signal corresponds to RPE dysfunction a common event in both chronic naevi of a certain size and in small choroidal melanomas. This event in itself however does not confer prognostic significance. [7]

Examination of individual clinical features showed that drusen, orange pigment and fibrosis were equally distributed between channels. These clinical features do not correlate significantly with a particular RC or GC pattern and therefore one cannot predict their presence from the channel patterns.

In conclusion, despite the promising notion that the use of two separate channels might detect a malignant lesion early and add to its prognosis, our results do not support this. Melanotic naevi and small melanomas appear dark on RC. Benign or malignant melanocytic tumours can appear light on GC possibly due to the chronicity of the lesion but not due to an inherent property related

to prognostic significance. RC has the benefit of assess tumour margins in serial monitoring, but RC and GC patterns are limited in differentiating choroidal naevi from melanomas.

FIGURES

Figure 1: Optos photo of a flat naevus A: Colour photo B Naevus appears dark in red channel C Naevus is not visible in green channel (Dark on red- not detectable on green pattern)

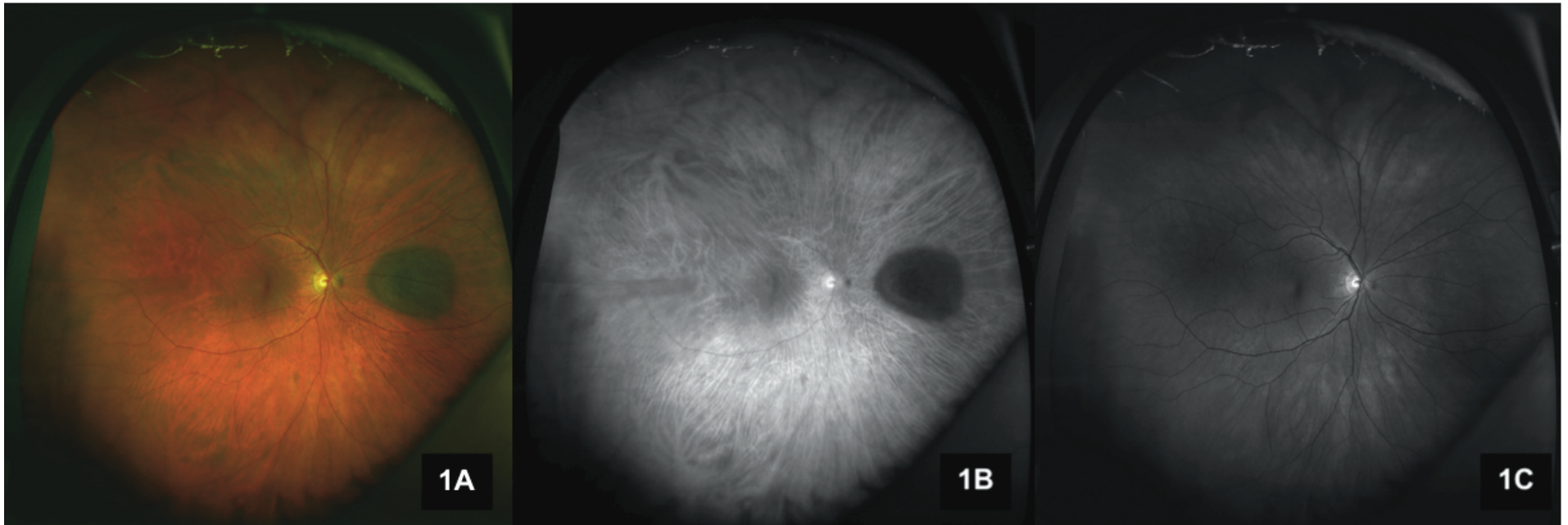


Figure 2: Optos photos of an elevated naevus (1.2mm) A: Colour photo B Naevus appear dark in red channel C Naevus appears bright in green channel (Dark on red – light on green pattern)

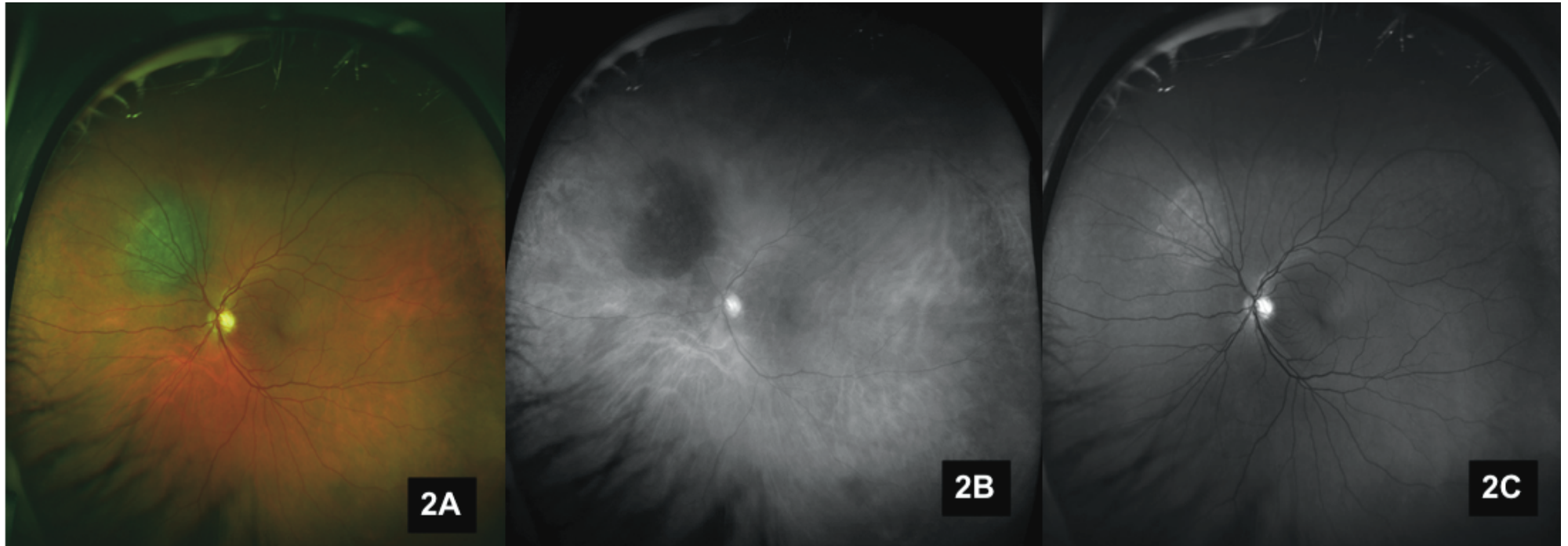


Figure 3. A. Bar graphs show that proportion of dark RC / light GC increases by thickness of the tumour in 152 choroidal pigmented lesions B. Comparison within categories indicates no significant difference between patterns in the 1-2mm and 2-3mm categories.

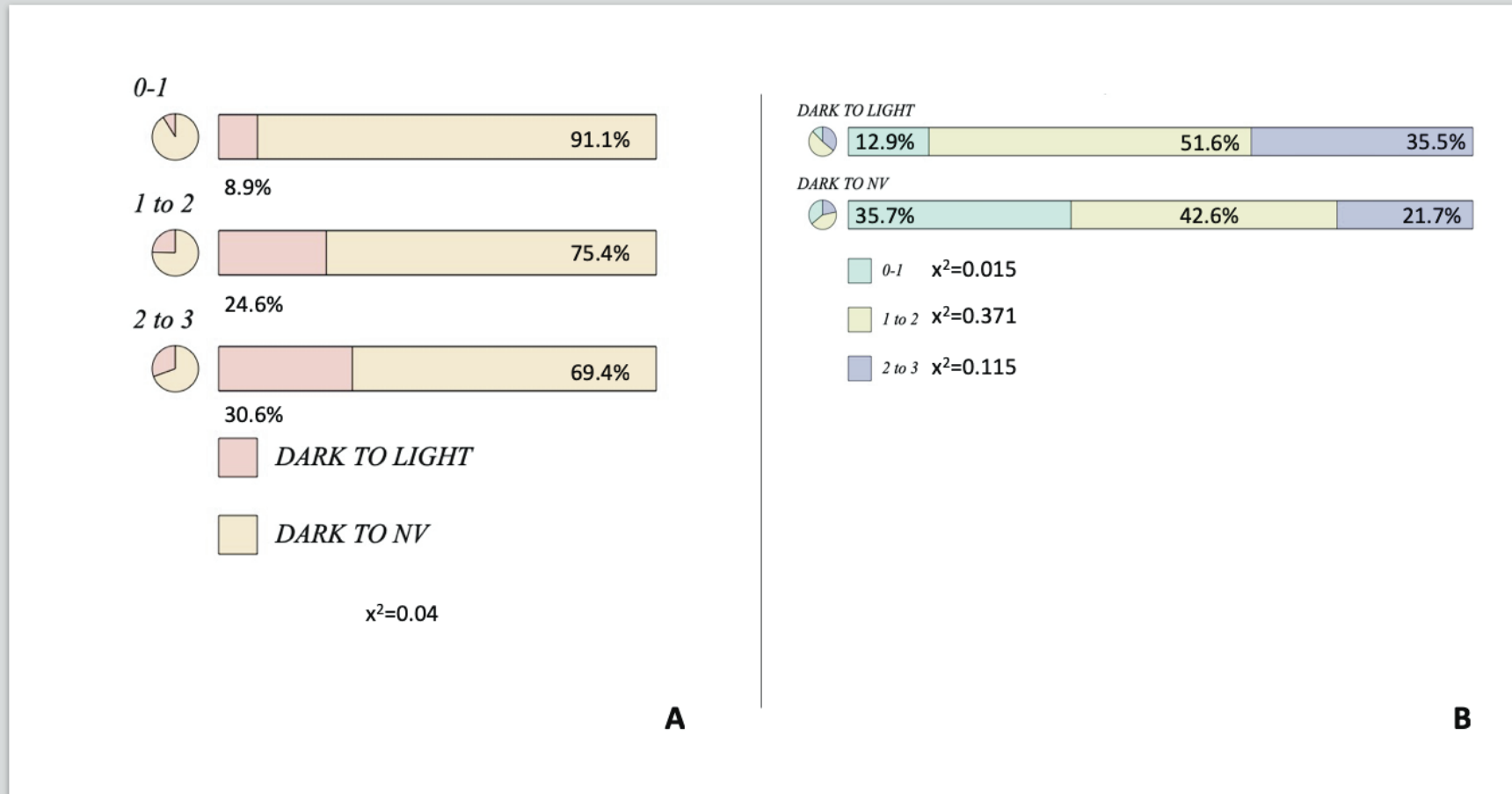
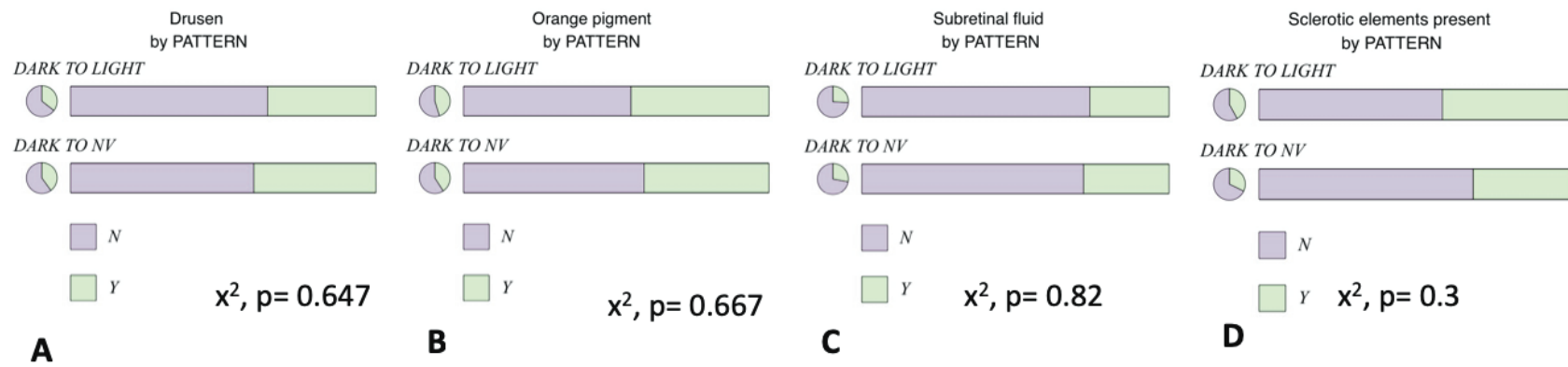


Figure 4(A-D) . Tumour detectability patterns do not significantly correlate with the presence of drusen, orange pigment, subretinal fluid or fibrosis in 152 cases with small choroidal pigmented tumours.



COMPETING INTERESTS

Nil

FUNDING

Nil

PRESENTATIONS

Poster presentation in ARVO 2017

Poster presentation in the Royal Congress of Ophthalmologists in Liverpool 2018

Oral presentation in the European Ocular Oncology Group Meeting in Siena, Italy 2018

REFERENCES

1. Chien JL, Sioufi K, Surakiatchanukul T, Shields JA, Shields CL. Choroidal nevus: a review of prevalence, features, genetics, risks, and outcomes. *Curr Opin Ophthalmol*. 2017;28(3):228-237.
2. Shields CL, Furuta M, Berman EL, Zahler JD, Hoberman DM, Dinh DH, Mashayekhi A, Shields JA. Choroidal nevus transformation into melanoma: analysis of 2514 consecutive cases. *Arch Ophthalmol* 2009;127(8):981-7
3. Mims JL, III, Shields JA. Follow-up Studies of Suspicious Choroidal Nevi. *Ophthalmology*;85(9):929-43
4. Gass JDM. Observation of Suspected Choroidal and Ciliary Body Melanomas for Evidence of Growth Prior to Enucleation. *Ophthalmology*;87(6):523-28 doi: 10.1016/S0161-6420(80)35200-7
5. Butler P, Char DH, Zarbin M, Kroll S.. Natural History of Indeterminate Pigmented Choroidal Tumors. *Ophthalmology*;101(4):710-17
6. Augsburger JJ, Schroeder RP, Territo C, Gamel JW, Shields JA. Clinical parameters predictive of enlargement of melanocytic choroidal lesions. *Br J Ophthalmol* 1989;73(11):911-7
7. Shields CL, Shields JA. Clinical features of small choroidal melanoma. *Curr Opin Ophthalmol* 2002;13(3):135-41
8. Uveal melanoma. In: AJCC Cancer staging manual 8th Edition 2017 Springer pp 805-817
9. Francis JH, Pang CE, Abramson DH, Milman T, Folberg R, Mrejen S, Freund KB. Swept-source optical coherence tomography features of choroidal nevi. *Am J Ophthalmol*. 2015 Jan;159(1):169-76
10. Shields CL, Kaliki S, Rojanaporn D, Ferenczy SR, Shields JA. Enhanced depth imaging optical coherence tomography of small choroidal melanoma: comparison with choroidal nevus. *Arch Ophthalmol*. 2012 Jul;130(7):850-6
11. Albertus DL, Schachar IH, Zahid S, Elnor VM, Demirci H, Jayasundera T. Autofluorescence quantification of benign and malignant choroidal nevi/melanocytic tumors. *JAMA Ophthalmol*. 2013 Aug;131(8):1004-8

12. Ali ZC, Gray J, Balaskas K. Features of choroidal naevi on swept source optical coherence tomography angiography and structural reverse flow optical coherence tomography. *Graefes Arch Clin Exp Ophthalmol*. 2018 Jul;256(7):1319-1323.
13. Coffee RE, Jain A, McCannel TA. Ultra wide-field imaging of choroidal metastasis secondary to primary breast cancer. *Semin Ophthalmol*. 2009 Jan-Feb;24(1):34-6
14. Kernt M, Schaller UC, Stumpf C, Ulbig MW, Kampik A, Neubauer AS. Choroidal pigmented lesions imaged by ultra-wide-field scanning laser ophthalmoscopy with two laser wavelengths (Optomap). *Clin Ophthalmol*. 2010 Jul 30;4:829-36.
15. Zapata MA, Leila M, Teixidor T, Garcia-Arumi J. *Comparative study between fundus autofluorescence and red reflectance imaging of choroidal nevi using ultra-wide-field scanning laser ophthalmoscopy*. *Retina*. 2015 Jun;35(6):1202-10.

Table 1 Ultra wide-field imaging assessment of small choroidal pigmented lesions using red and green colour channels: Demographic and tumour features

Median Age: 66.0 (mean 64.5±2.2, range 26-90 years)

Sex

Female: 81/152 (53%)

Age: 64.0 ±3.2

Male: 71/152 (47%)

Age: 66.0 ±3.0

Lesion type

 melanotic naevi (76/152, 50%)

 amelanotic naevi (3/152, 2%)

 halo naevi (3/152, 2%)

 suspicious naevi (15/152, 10%)

 small choroidal melanomas (55/152, 36%)

Lesion thickness

 0-1 mm: 46/152, 30%

 1-2 mm: 70/152, 46%

 2-3 mm: 36/152, 24%

Drusen present: 60/152, 40%

Orange pigment present: 62/152, 41%

Subretinal fluid present: 40/152, 26%

Fibrosis present: 52/152, 34%

Table 2A Ultra wide-field imaging assessment of small choroidal pigmented lesions using red and green colour channels: Features of Melanotic naevus group

	All melanotic naevi			Dark on RC undetectable in GC		Dark on RC Light on GC		<i>p value*</i> (test)
		Median (Mean±SD) Or n/N (%)	Range	Median (Mean±SD) Or n/N (%)	Range	Median (Mean±SD) Or n/N (%)	Range	
No of patients		76		57/76(75%)		15/76(20%) ¹		
Ultrasound Thickness (mm)		0.9 (0.92±0.1)	0.25-2.2	0.8 ± 0.2	0.1-2.2	1.2 ± 0.2	0.6-2	0.006 (t-test)
Ultrasound thickness distribution (mm)	0-1	64/76 (85%)		36/57 (63%)		3/15 (20%)		
	1-2	39/76 (51%)		20/57 (35%)		12/15 (80%)		
	2-3	2/76 (3%)		1/57 (2%)		0/15 (0%)		
Clinical features								
Drusen		33/76 (43%)		25/57 (44%)		5/15 (33%)		0.2 (x ²)
Orange pigment		6/76 (8%)		1/57 (2%)		4/15 (27%)		<0.001 (x ²)
Subretinal fluid		2/76 (3%)		1/57 (2%)		1/15 (7%)		0.303 (x ²)
Fibrosis		14/76 (19%)		7/57 (12%)		5/15 (33%)		0.052 (x ²)

GC – green channel; RC red channel

**p*<0.05 considered statistically significant, t-test or x²

¹Five cases did not fit in any of the patterns and are not included in the table

Table 2B Ultra wide-field imaging assessment of small choroidal pigmented lesions using red and green colour channels: Small choroidal melanoma group

	All small melanomas			Dark on RC undetectable on GC		Dark on RC Light on GC		<i>p value* (test)</i>
		Median (Mean±SD) Or n/N (%)	Range	Median (Mean±SD) Or n/N (%)	Range	Median (Mean±SD) Or n/N (%)	Range	
No of patients		55/152 (37%)		40/55(73%)		12/55(22%) ¹		
Thickness (mm)		2.1 (2.2±0.1)	1-3.0	2 ± 0.2		2.7 ± 0.3		0.006 (t-test)
Thickness distribution	0-1	1/55(1.8%)		1/40(2.5%)		0/12(0%)		
	1-2	24/55(43.6%)		21/40(52.5%)		1/12(8%)		
	2-3	30/55(54.5%)		18/40(45%)		11/12 (92%)		
Drusen		19/55(34.55%)		12/40(30%)		6/12(50%)		0.2(x ²)
Orange pigment		47/55(85.4%)		37/40(92.5%)		8/12(26.7%)		<0.001(x ²)
Subretinal fluid		30/55(54.5%)		24/40(60%)		6/12(50%)		0.3(x ²)
Fibrosis		32/55(58%)		24/40(60%)		6/12(50%)		0.052(x ²)

GC – green channel; RC red channel

**p*<0.05 considered statistically significant, t-test or x²

¹Three cases did not fit in any of the patterns and are not included in the table

Table 3(A-B) Ultra wide-field imaging assessment of small choroidal pigmented lesions using red and green colour channels:

A. Clinical features by tumour thickness category

Tumour thickness category	0-1 mm	1-2 mm	2-3 mm
No of patients	46	70	36
Thickness (mm) median (mean±SD)	0.5 (0.5±0.06)	1.2 (1.4±0.07)	2.5 (2.6±0.1)
<i>Distribution of tumour type per thickness category</i>			
Melanotic naevus (%)	85	51	2.8
Amelanotic naevus (%)	7		
Halo naevus (%)	0	0	0
Indeterminate melanocytic lesion(%)	4.3	11.4	13.9
Small choroidal melanoma (%)	2.2	34.3	83.3
<i>Tumour features</i>			
Drusen present(%)	41.3	37.1	41.7
Orange pigment present(%)	6.5	44.3	77.8
Subretinal fluid present (%)	6.5	21.4	61.1
Fibrosis present(%)	8.7	34.3	66.7

Table 3B Ultra wide-field imaging assessment of small choroidal pigmented lesions using red and green colour channels:

Detectability of clinical features by red and green channel

Tumour type	Drusen		Orange pigment		Subretinal fluid	
	Red channel	Green Channel	Red channel	Green Channel	Red channel	Green Channel
Melanotic naevus	26/76	25/76	1/76	1/76		1/76
CMM	16/55	18/55	42/55	40/55	11/55	20/55
IML	4/15	5/15	6/15	4/15	1/15	6/15
Halo naevus	2/3	2/3	1/3			
Amelanotic naevus	0	0				