

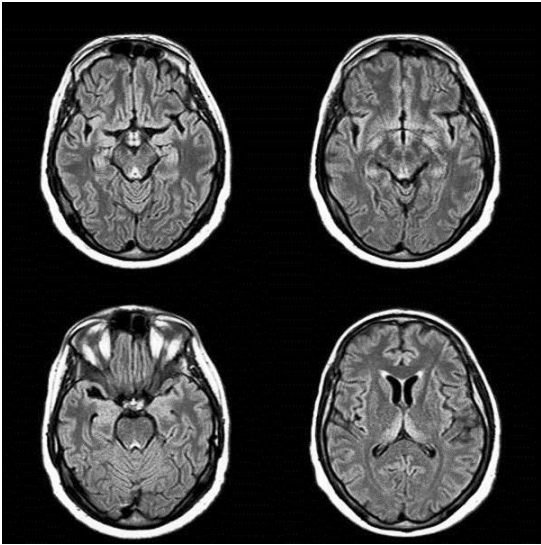Fig1: MRI FLAIR. Hiperintensity of the mammillary bodies, periacqueductal grey matter and the thalami, typical MRI signal of Wernicke's Encephalopathy.

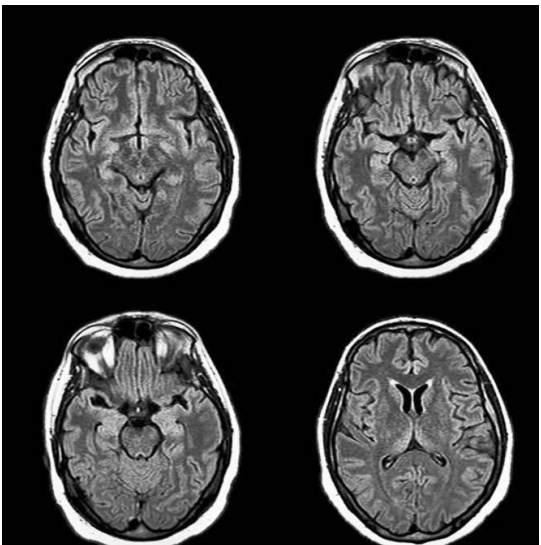


Fig2: MRI Flair Imagines showing an improvement of the neuro-radiological findings.