

TITLE PAGE

Title: Prospective evaluation of treatment response and disease reversibility of paediatric localized scleroderma (morphoea) to steroids and methotrexate using multi-modal imaging.

Key words: localized scleroderma, methotrexate, reversibility, recurrence, laser doppler, ultrasound

Word count: 2998

Table count: 3

Figure count: 4

Authors: L. Weibel^{1*}, M. Theiler^{1*}, K.J. Howell², C.P. Denton³, R. Waelchli¹, D. Atherton⁴, P. Woo⁵, J.I. Harper⁴

¹Division of Pediatric Dermatology, Pediatric Skin Center, University Children's Hospital Zurich, Zurich, Switzerland

²Microvascular Diagnostics, Institute of Immunity and Transplantation, Royal Free Hospital, London, UK

³Centre for Rheumatology and Connective Tissue Disease, UCL Division of Medicine, Royal Free London NHS Foundation Trust, London, United Kingdom

⁴Department of Dermatology, Great Ormond Street Hospital for Children, London, UK

⁵Centre for Adolescent Rheumatology, University College London, 4th Floor, Rayne Building, 5 University Street, London, UK

*shared first authorship

Corresponding Author: Lisa Weibel, MD
University Children's Hospital Zurich
Steinwiesstrasse 75
CH-8032 Zurich
+41 44 266 82 81
+41 44 266 80 30
e-mail: lisa.weibel@kispi.uzh.ch

Funding sources none

Conflicts of interest The authors have indicated that they have no conflicts of interest related to this work

Abbreviations

LS	Localized scleroderma
LDF	Laser Doppler flowmetry
HFU	High-frequency ultrasound (20MHz)
MTX	Methotrexate
IVMP	Intravenous methyl-prednisolone
ANA	Anti-nuclear antibody
ESR	Erythrocyte sedimentation rate

ABSTRACT

Background: Paediatric localized scleroderma is a severe inflammatory disorder associated with tissue atrophy, often leading to disability. Assessing disease activity and response to treatment has always been challenging and remains an important difficulty in clinical practice.

Objectives: To investigate prospectively the efficacy of systemic treatment with corticosteroids and methotrexate in children with localized scleroderma and the validity of infrared thermography, laser Doppler flowmetry, and high-frequency ultrasound in assessing disease activity.

Methods: Children with localized scleroderma were prospectively treated with corticosteroids (IV methylprednisolone 30mg/kg/day and/or oral prednisolone 0.5-1mg/kg/day) and methotrexate (15mg/m² weekly). Treatment response was evaluated using a clinical activity score. Skin temperature, blood-flow, dermal thickness, and dermal echogenicity of clinically active skin lesions were determined in relation to the unaffected contralateral site at baseline and after 3, 6, 12, and 18 months. Patient charts were later reviewed for long-term follow-up.

Results: 22 patients were included (age 6.0 (0.2 – 14.4) years; female-to-male ratio 3.4:1) All responded well to therapy. Disease reversibility was demonstrated in the majority of children with partial resolution of skin sclerosis and re-growth of hair. Laser Doppler flowmetry and high-frequency ultrasound findings correlated with disease activity at baseline. Thermography had no added value in this cohort. The recurrence rate was 36% in the follow-up period.

Conclusions: Corticosteroids and methotrexate are highly effective as first-line therapy in paediatric localized scleroderma, leading to partial reversal of skin manifestations. However, the recurrence rate is substantial and affected children require long-term follow-up. Laser Doppler flowmetry and high-frequency ultrasound correlate with disease activity in the acute phase and may assist decision-making in these patients.

MAIN TEXT

INTRODUCTION

Localized scleroderma (LS) is an inflammatory connective tissue disorder characterized by sclerosis of the skin. Depending on the subtype, underlying subcutaneous tissue, muscles, joints and bone may also be affected¹. The mean age of disease onset is 7-9 years, with an incidence of 0.3 – 3 per 100,000 children^{1,2}.

There is a broad spectrum of presentation. Several subtypes are recognized: linear, plaque-type, generalized, deep, pansclerotic, and mixed LS¹⁻³. The linear variant is the most common type in children (65%) and associated with a progressive course and risk of extracutaneous involvement and complications, especially when occurring early in life⁴. At the more severe end of the spectrum LS may progress over years and result in joint contractures, deformity, and severe functional and cosmetic disability^{1,4-6}. The aim of therapy is to arrest the disease early in order to prevent these complications.

For patients with mild LS, i.e. circumscribed plaque-type LS, topical treatment and UV light therapy may be considered^{2,7-9}. All other forms of LS in children must be regarded as potentially severe, usually requiring systemic immunosuppressive therapy. Several studies have supported the use of methotrexate (MTX), with or without systemic corticosteroids, in the management of severe LS types¹⁰⁻¹³, and MTX has been adopted in treatment guidelines and recommendations as first-line therapy for such patients^{2,7-9}.

Guiding therapy has always been complicated by the lack of reliable and easy-to-use markers of disease activity. Laboratory parameters, clinical scoring methods, infrared thermography, high-frequency ultrasound (HFU), laser-doppler flowmetry (LDF), and MRI among others have been suggested for this purpose¹⁴⁻¹⁶. Currently, no consensus exists regarding the optimal means of assessing disease activity and physicians often solely rely on clinical examination to guide the treatment of their patients.

In this study, we aim to evaluate prospectively the response of childhood LS to systemic treatment with corticosteroids and MTX and to investigate the value of LDF, thermography, and HFU in assessing disease activity in the treatment course. Furthermore, we report on long-term follow-up with regard to the recurrence rate in this cohort.

MATERIALS AND METHODS

Patients and treatment protocol

Patients newly diagnosed with LS seen at the Paediatric Dermatology Department at Great Ormond Street Hospital (GOSH) for Children during two years (2005 until 2007) were included in this study. The diagnosis of LS was established or confirmed by experienced paediatric dermatologists (JIH and DA) and a paediatric rheumatologist (PW), and in some patients additionally by histology.

The patients were treated according to a standardized treatment protocol as previously published¹². Induction therapy included two courses of high-dose intravenous methylprednisolone (IVMP), each consisting of three pulses at 30mg/kg/day (max. 500mg/day), given on two consecutive weeks. Oral prednisolone was started after the first course of IVMP, stopped during the second course of IVMP and then continued on a reducing regimen. Maintenance treatment with weekly methotrexate (MTX) at a dose of 15mg/m² of body surface (max. 25mg/week) was started one week after the second course of IVMP. For patients unable to receive IVMP pulses, treatment with oral prednisolone plus MTX was started. In patients with contraindications to systemic steroids or with less progressive disease, treatment with MTX alone was initiated.

During treatment there were standardized study visits at 0, 3, 6, 12, and 18 months. Long-term follow-up was assessed by evaluating patient charts 8 years after the initiation of the study (in 2013).

Ethical board approval was sought prior to the initiation of this study and informed consent was given by the families for the collection of patient data.

Outcome measures and endpoints

The following outcome measures were employed in this study and assessed at every study visit: disease activity using a clinical activity score (CAS), cutaneous blood flow determined by LDF, skin temperature measured by infrared thermography, and dermal thickness and echogenicity on HFU. Additionally, the treatment response was assessed by standardized photographs and the consistent clinical evaluation by the same consultant dermatologists (JIH and DA).

In every patient the clinically most active LS lesion was investigated. The contralateral unaffected site served as intra-patient control for LDF, thermography and HFU.

Primary endpoints:

The primary endpoints of this study were the response of the clinically most active LS lesion to systemic treatment with steroids and MTX assessed by the CAS and the correlation of the clinical disease activity with the measurements obtained by LDF, thermography and HFU.

Secondary endpoints

Secondary endpoints included: reversibility of the disease characterized by hair regrowth and change of skin sclerosis, the tolerability of the systemic treatment with corticosteroids and MTX and the rate of disease recurrence of treated patients in the extended observation period.

Clinical activity score (CAS)

At the time of the start of this study no validated clinical score for LS was available. A CAS was established that allowed us to monitor disease activity in a localized area of LS. It was not meant to assess the overall clinical status of the patient. The CAS represents a combination of the Modified Skin Score (MSS) and the Dyspigmentation, Induration, Erythema and Telangiectasia (DIET) Score proposed by Dytoc *et al*¹⁷⁻²⁰. For a given lesion erythema, skin tightness and atrophy are each scored from 0 (mild) to 3 (severe). One point is added for spreading of a lesion, summing up to a maximum activity score of 10 (**Table 1**).

Laser Doppler flowmetry (LDF) and thermography

The same protocol for the evaluation of dermal blood-flow and skin surface temperature using LD and thermography, that was published and validated by our group, was employed in this study^{21,22}. In summary, we used an MBF3D laser Doppler monitor with a laser wavelength of 810nm (Moor Instruments, Axminster, Devon, UK). Measurements were performed three times using an optical-fibre probe attached to the skin with a self-adhesive disc. Blood flow was monitored for 10 seconds. The mean flow, in arbitrary flux units, was calculated for each site.

The thermograms were obtained using the same infrared camera (FLIR SC 500 Thermacam; Flir Systems, West Malling, UK) to assess the skin of each patient. Relative differences and

absolute differences between affected and unaffected side were calculated for LDF and thermography measurements respectively.

20 Mhz ultrasound (HFU)

High-frequency ultrasound (Dermascan, Cortex Technology, Hadsund, Denmark) was employed to assess dermal thickness and echogenicity in the most active morphea lesion and compared with the contralateral, unaffected skin. Relative differences for dermal thickness and echogenicity between affected and unaffected side were calculated.

Pretreatment investigations and adverse events

All patients were investigated for extracutaneous manifestations of their disease prior to treatment, including ophthalmology examination, brain MRI as appropriate, and blood tests – full blood count, liver and renal function tests, antinuclear antibody titre (ANA), erythrocyte sedimentation rate (ESR), and C-reactive protein (CRP). Adverse events were noted during the entire treatment period. For the administration of IVMP, the children were admitted and monitored closely. Laboratory monitoring during maintenance treatment included full blood count, electrolytes, urea, creatinine, and liver function tests every 6 to 8 weeks.

Statistical analysis

For the descriptive analysis, median and interquartile range (IQR) were used for continuous variables and number and percentage for categorical variables. Repeated measures for related, nonparametric samples were analysed with the Friedman's test. The null hypothesis was rejected with a two-sided $p < 0.05$. We used boxplots for the visualization of the distributions and line plots to visualize the trajectories of the patients over the course of 18 months. Furthermore, we used the Spearman's rank-order correlation to examine the correlation between the clinical activity assessed by the CAS and the three measurement methods (laser Doppler, thermography, 20Mhz ultrasound).

All analyses were conducted using R 3.4.2 for Windows (R Core Team, 2017).

RESULTS

Patients

24 patients were enrolled. Two patients were excluded from the study. One patient had generalized symmetrical disease with no suitable area of skin to act as an intra-patient control. The other patient was lost to follow-up.

22 patients were included in the analysis. Patient details are given in **Table 2**. All but one patient had linear LS.

Treatment response

Systemic treatment was given according to the above described protocol. Treatment was well tolerated. The most common side-effects were nausea (36%), cushingoid features (27%) while on systemic steroids, and laboratory abnormalities (14%), that responded promptly to short-term discontinuation or dose-reduction of MTX. In 2 patients (9%), MTX had to be stopped due to intractable nausea towards the end of the 18-month study period.

The median Clinical Activity Score (CAS) at treatment initiation was 5 (IQR 5 – 5.75). A statistically significant decrease in the CAS was observed over the study period ($p < 0.001$) (**Figs 1 and 2**). At 18 months, the median CAS was 1 (IQR 1 – 2). The quickest reduction in the CAS occurred within the first 3 months of treatment with slower but continuous further improvement until 18 months.

The mean value of the individual parameters of the CAS including atrophy showed a continuous improvement over the treatment period (**Fig. 3**).

All patients had a treatment response without any disease progression during the 18 month study period.

Reversibility of LS lesion with systemic treatment

In all patients, skin lesions showed remarkable reversibility with systemic treatment (**Figs 2+4**). In particular, skin sclerosis significantly decreased and 17 subjects with an increased score for skin tightness at first presentation had a marked improvement in skin texture.

Sclerosed areas were typically replaced to some extent by hyperpigmentation. Of note, regrowth of scalp hair in previously alopecic areas could be documented in two out of three

patients with scalp involvement paralleling resolution of sclerosis (**Fig. 4**). Additionally, one patient with initial loss of eyelashes showed partial regrowth.

Laser Doppler flowmetry (LDF)

LDF showed a clearly increased relative blood-flow in the LS lesion compared to the contralateral side at treatment initiation. The median increase at treatment initiation was + 55.4 % (IQR 18.9 – 118.7%) which significantly decreased to + 6.7 % (IQR -15.2 – 45.0%) at 18 months ($p=0.002$) (**Fig. 1**) At treatment initiation, a weak correlation with the CAS was noticeable on Spearman's rank-order correlation. However, this correlation was lost during the further study period (**Table 3**).

Infrared thermography

Thermography did not show any significant differences in skin temperature between the affected and contralateral side at any time point in the study, and there was no relevant change over the whole study period (**Fig. 1**). Accordingly, no correlation of the thermography results with the CAS was detectable (**Table 3**).

20 MHz ultrasound (HFU)

At treatment initiation HFU showed a slightly diminished median dermal thickness (-2.9% (IQR -17.1 – 20.5%)) and an increased dermal echogenicity (+6.1% (IQR -38.4 – 40.0%)) of the affected area relative to the unaffected contralateral side. Both parameters did not show any significant change or trend during the study period ($p=0.39$ and $p=0.26$ for the relative difference in dermal thickness and echogenicity respectively) (**Fig. 5**). A weak positive correlation of the CAS with dermal thickness and a weak negative correlation with dermal echogenicity were detected at the first visit. Both were lost in the course of therapy (**Table 3**). We hypothesized that the inclusion of dermal atrophy into the CAS might negatively impact correlation with the ultrasound findings. However, no differences were found when calculating Spearman's rank-order correlations between the ultrasound results and the CAS with or without the inclusion of dermal atrophy as a parameter.

Subgroup analysis

As all but one patient were suffering from linear LS, we were not able to investigate differences in treatment response and other measurements between different subtypes of LS. We did not observe any differences between linear LS of the head as compared to body lesions.

Clinical follow-up in the extended observation period

Patients were clinically followed up outside the 18-month study protocol for a median time of 49.3 months (range 3.5 – 68.2 months, last follow-up included in 2013). The total median treatment duration with MTX including the extended observation period was 27.5 months (range 15.9 – 51.5 months). Seven patients (32%) remained on systemic therapy at the last visit included in this study.

During the extended observation period, 8 patients (36%) presented with a relapse after stopping treatment, requiring re-institution of systemic immunosuppressive therapy. There was an equal risk of recurrence in linear LS involving the head and trunk/extremities respectively.

Three of these patients were treated with IVMP, oral prednisolone and methotrexate, one patient with oral prednisolone and methotrexate and three patients with methotrexate alone. In one patient re-treatment details were not available. All patients responded favorably to re-institution of systemic treatment.

DISCUSSION

In this study, we have prospectively treated a cohort of 22 children with progressive LS. Systemic treatment with MTX, usually in combination with intravenous and/or oral steroids in the initiation phase, reliably led to a rapid cessation of disease progression and significant improvement of the LS lesions. The most rapid improvement in the CAS was noted in the first 3 months of treatment with continuous further improvement thereafter. This is in line with the current literature and clearly supports the use of MTX and steroids as first-line treatment in severe paediatric LS subtypes^{2,5,9,12,13,23}.

Our data emphasize that systemic treatment not only halts disease progression and improves inflammatory skin changes, but also leads to a resolution of dermal sclerosis. Furthermore, regrowth of scalp hair was documented. This observation clearly contradicts the previous concept that sclerosed areas lead to irreversible scarring. In addition, we were even able to document improvement of skin atrophy in the treatment course. This was typically observed in extra-facial locations.

Guiding treatment and particularly recognizing recurrences has always been a challenge in LS. As highlighted, clinical findings correlating with disease activity include erythema, violaceous colour, tactile warmth, abnormal skin texture, and disease extension¹⁵. However, these may be subtle and difficult to ascertain, especially in the linear LS subtype. Therefore, there is an unmet need for more objective parameters, and different laboratory markers and imaging techniques have been investigated for this purpose¹⁴. To date, no single parameter has proven to be a reliable marker for disease activity across all forms of LS. Recently, a group reported CCL18 as a potential biomarker in LS¹⁶.

We were able to detect an increased median relative blood flow by LDF in the LS lesions at the initiation of treatment and a statistically significant decrease over the course of therapy. As with the CAS, the main reduction in relative blood flow occurred within the first 3 months of therapy. These findings are consistent with our previous study and also with the results obtained by laser Doppler imaging^{21,24–26}. A correlation of LDF measures with the CAS could be documented at the initiation visit. However, we were not able to demonstrate a correlation with the disease activity during the further treatment course. Nevertheless, our data suggest that laser Doppler assessment may be a helpful adjunct in guiding treatment decisions at the initial evaluation of LS patients. Of note, increased blood flow on laser Doppler imaging has been found to predict disease progression, warranting active immunosuppressive therapy in such patients²⁶.

Regarding thermography, earlier studies reported a good correlation with active disease^{10-12,24,25,27,28}. However, we were not able to detect any correlation of skin temperature with disease activity. This is in concordance with the findings of our previous study²¹ and the findings of Garcia-Romero *et al*²⁹. It has been acknowledged that subcutaneous atrophy may lead to false-positive thermography results due to increased heat conductance to the superficial skin^{21,28}. Based on our results, we cannot recommend thermography as a tool for guiding treatment in children with linear LS.

Ultrasound has also been suggested to be helpful in the assessment of patients with LS and has the advantage of being more readily available in clinical practice than the methods described above¹⁴. We found only a weak positive correlation of dermal thickness and a weak negative correlation of echogenicity with clinical disease activity at treatment initiation, suggesting that HFU may assist in the initial evaluation of LS patients. In line with these findings, most authors report increased dermal thickness in clinically active LS lesions and several studies report dermal thickness to decrease during treatment, serving as a potential marker for treatment response³⁰⁻³³. In terms of dermal echogenicity, results in the literature are conflicting, reporting increased as well as decreased echogenicity in LS lesions compared to healthy skin, likely depending on disease state^{34,35}. We hypothesize that the decreased echogenicity observed in our patients at initial presentation is due to oedema associated with active inflammation. As opposed to other authors, we did not observe any clear change of the ultrasound parameters over time. These findings suggest that despite clinical improvement, ultrastructural changes of previously affected areas persist for long periods, or even indefinitely.

We witnessed a significant recurrence rate of 36% after stopping MTX. This is consistent with the current literature, reporting recurrence rates of 15.4 up to 48.6%^{11,36-39}. The median treatment duration with MTX in our cohort was 27.5 months. However, one third of patients remained on treatment at the last visit in the extended observation period. This finding highlights that, although LS is a self-limiting disorder in many patients, a significant proportion of affected individuals suffer long-term disease activity requiring longer-term immunosuppressive therapy.

The median time to relapse was 20.3 months in this cohort; however, recurrences were observed up to 51.1 months after stopping therapy.

We found the recurrence rates to be identical in linear LS of the head and extremities respectively, in contrast to other reports³⁷.

The interpretation of these results is limited, as almost exclusively patients with linear LS were included, and thus patients with the most severe and refractory LS subtype were investigated. We cannot exclude that imaging results might be different in another population, especially with plaque-type disease, where the inflammatory changes are more superficial without involving deeper structures. Further limitations of this study include the relatively small number of subjects and the fact that not all patients were able to receive the exact same standardized treatment protocol. As no validated clinical score for LS was available at the conception of this study, we were obliged to use a non-validated CAS.

In conclusion, our data shows that treatment with corticosteroids and MTX not only leads to a halt in disease progression, but also partially reverses sclerosis and dermal atrophy and improves alopecia associated with LS. LDF and HFU findings correlate with disease activity in the active phase and may serve as an important adjunct in treatment decision making. In contrast, we have not found evidence for any added value of thermography. However, these imaging techniques do not replace the importance of clinical evaluation by a physician experienced in treating LS, and standardized photographs. A significant proportion of patients develop disease recurrence and require long-term therapy. As recurrences are observed more than 4 years after treatment cessation, follow-up for at least 5 years after stopping treatment is warranted.

ACKNOWLEDGEMENTS

none

REFERENCES

- 1 Zulian F, Athreya BH, Laxer R, *et al.* Juvenile localized scleroderma: Clinical and epidemiological features in 750 children. An international study. *Rheumatology* 2006; **45**:614–20.
- 2 Constantin T, Foeldvari I, Pain CE, *et al.* Development of minimum standards of care for juvenile localized scleroderma. *Eur. J. Pediatr.* 2018; **177**:961–77.
- 3 Peterson L, Nelson A, Su W. Classification of morphea (localized scleroderma). *May Clin Proc* 1995; **70**:1068–76.
- 4 Pequet MS, Holland KE, Zhao S, *et al.* Risk factors for morphea disease severity: A retrospective review of 114 paediatric patients. *Br J Dermatol* 2014; **170**:895–900.
- 5 Christen-Zaech S, Hakim MD, Afsar FS, Paller AS. Pediatric morphea (localized scleroderma): Review of 136 patients. *J Am Acad Dermatol* 2008; **59**:385–96.
- 6 Zulian F, Vallongo C, Woo P, *et al.* Localized scleroderma in childhood is not just a skin disease. *Arthritis Rheum* 2005; **52**:2873–81.
- 7 Li SC, Torok KS, Pope E, *et al.* Development of consensus treatment plans for juvenile localized scleroderma: A roadmap toward comparative effectiveness studies in juvenile localized scleroderma. *Arthritis Care Res* 2012; **64**:1175–85.
- 8 Knobler R, Moinzadeh P, Hunzelmann N, *et al.* European Dermatology Forum S1-guideline on the diagnosis and treatment of sclerosing diseases of the skin, Part 1: localized scleroderma, systemic sclerosis and overlap syndromes. *J. Eur. Acad. Dermatology Venereol.* 2017; **31**:1401–24.
- 9 Zulian F, Culpo R, Sperotto F, *et al.* Consensus-based recommendations for the management of juvenile localised scleroderma. *Ann Rheum Dis* 2019; :annrheumdis-2018-214697.
- 10 Zulian F, Martini G, Vallongo C, *et al.* Methotrexate treatment in juvenile localized scleroderma: A randomized, double-blind, placebo-controlled trial. *Arthritis Rheum* 2011; **63**:1998–2006.
- 11 Zulian F, Vallongo C, Patrizi A, *et al.* A long-term follow-up study of methotrexate in juvenile localized scleroderma (morphea). *J Am Acad Dermatol* 2012; **67**:1151–6.

- 12 Weibel L, Sampaio MC, Visentin MT, *et al.* Evaluation of methotrexate and corticosteroids for the treatment of localized scleroderma (morphea) in children. *Br J Dermatol* 2006; **155**:1013–20.
- 13 Torok KS, Arkachaisri T. Methotrexate and corticosteroids in the treatment of localized scleroderma: A standardized prospective longitudinal single-center study. *J Rheumatol* 2012; **39**:286–94.
- 14 Lis-Święty A, Janicka I, Skrzypek-Salamon A, Brzezińska-Wcisło L. A systematic review of tools for determining activity of localized scleroderma in paediatric and adult patients. *J. Eur. Acad. Dermatology Venereol.* 2017; **31**:30–7.
- 15 Li SC, Li X, Pope E, *et al.* New features for measuring disease activity in pediatric localized scleroderma. *J Rheumatol* 2018; **45**:1680–8.
- 16 Mertens JS, de Jong EMGJ, van den Hoogen LL, *et al.* The identification of CCL18 as biomarker of disease activity in localized scleroderma. *J Autoimmun* 2019. doi:10.1016/j.jaut.2019.04.008.
- 17 Kreuter A, Gambichler T, Breuckmann F, *et al.* Pulsed High-Dose Corticosteroids Combined With Low-Dose Methotrexate in Severe Localized Scleroderma. *Arch Dermatol* 2005; **141**:847–52.
- 18 Seyger M, van den Hoogen F, de Boo T, de Jong E. Low-dose methotrexate in the treatment of widespread morphea. *J Am Acad Dermatol* 1998; **141**:220–5.
- 19 Dytoc M, Ting PT, Man J, *et al.* First case series on the use of imiquimod for morphea. *Br J Dermatol* 2005; **153**:815–20.
- 20 Dytoc M, Wat H, Cheung-Lee M, *et al.* Evaluation of the Efficacy and Safety of Topical Imiquimod 5% for Plaque-Type Morphea: A Multicenter, Prospective, Vehicle-Controlled Trial. *J Cutan Med Surg* 2015; **19**:132–9.
- 21 Weibel L, Howell KJ, Visentin MT, *et al.* Laser Doppler flowmetry for assessing localized scleroderma in children. *Arthritis Rheum* 2007; **56**:3489–95.
- 22 Howell KJ, Lavorato A, Visentin MT, *et al.* Validation of a protocol for the assessment of skin temperature and blood flow in childhood localised scleroderma. *Ski Res Technol* 2009; **15**:346–56.
- 23 Rattanakaemakorn P, Jorizzo JL. The efficacy of methotrexate in the treatment of en

- coup de sabre (linear morphea subtype). *J Dermatolog Treat* 2018; **29**:197–9.
- 24 Murray AK, Moore TL, Manning JB, *et al.* Non-invasive imaging of localised scleroderma for assessment of skin blood flow and structure. *Acta Derm Venereol* 2016; **96**:641–4.
- 25 Moore TL, Vij S, Murray AK, *et al.* Pilot study of dual-wavelength (532 and 633 nm) laser Doppler imaging and infrared thermography of morphoea. *Br J Dermatol* 2009; **160**:864–7.
- 26 Shaw LJ, Shipley J, Newell EL, *et al.* Scanning laser Doppler imaging may predict disease progression of localized scleroderma in children and young adults. *Br J Dermatol* 2013; **169**:152–5.
- 27 Martini G, Murray K, Howell K, *et al.* Juvenile-onset localized scleroderma activity detection by infrared thermography. *Rheumatology* 2002; **41**:1178–82.
- 28 Ranhosz-Janicka I, Lis-Święty A, Skrzypek-Salamon A, Brzezińska-Wcisło L. Detecting and quantifying activity/inflammation in localized scleroderma with thermal imaging. *Ski Res Technol* 2019; **25**:118–23.
- 29 Garcia-Romero MT, Randhawa HK, Laxer R, Pope E. The role of local temperature and other clinical characteristics of localized scleroderma as markers of disease activity. *Int J Dermatol* 2017; **56**:63–7.
- 30 Szymanska E, Nowicki A, Mlosek K, *et al.* Clinical Science: Original Paper Skin imaging with high frequency ultrasound-preliminary results. *Eur J Ultrasound* 2000; **12**:9–16.
- 31 Porta F, Kaloudi O, Garzitto A, *et al.* High frequency ultrasound can detect improvement of lesions in juvenile localized scleroderma. *Mod Rheumatol* 2014; **24**:869–73.
- 32 Sator PG, Radakovic S, Schulmeister K, *et al.* Medium-dose is more effective than low-dose ultraviolet A1 phototherapy for localized scleroderma as shown by 20-MHz ultrasound assessment. *J Am Acad Dermatol* 2009; **60**:786–91.
- 33 Cosnes A, Anglade M, Revuz J, Radier C. Thirteen-megahertz ultrasound probe: its role in diagnosing localized scleroderma. *Br J Dermatol* 2003; **148**:724–9.
- 34 Li SC, Liebling MS, Haines KA, *et al.* Initial evaluation of an ultrasound measure for

- assessing the activity of skin lesions in juvenile localized scleroderma. *Arthritis Care Res* 2011; **63**:735–42.
- 35 Li SC, Liebling MS, Ramji FG, *et al.* Sonographic evaluation of pediatric localized scleroderma: Preliminary disease assessment measures. *Pediatr Rheumatol* 2010; **8**. doi:10.1186/1546-0096-8-14.
- 36 Koch SB, Cerci FB, Jorizzo JL, Krowchuk DP. Linear morphea: A case series with long-term follow-up of young, methotrexate-treated patients. *J Dermatolog Treat* 2013; **24**:435–8.
- 37 Mertens JS, Seyger MMB, Kievit W, *et al.* Disease recurrence in localized scleroderma: A retrospective analysis of 344 patients with paediatric- or adult-onset disease. *Br J Dermatol* 2015; **172**:722–8.
- 38 Piram M, McCuaig CC, Saint-Cyr C, *et al.* Short- and long-term outcome of linear morphoea in children. *Br J Dermatol* 2013; **169**:1265–71.
- 39 Kurzinski KL, Zigler CK, Torok KS. Prediction of disease relapse in a cohort of paediatric patients with localized scleroderma. *Br J Dermatol* 2019; **180**:1183–9.

TABLES

Table 1. Clinical activity Score (CAS), minimum score = 0, maximum score = 10

Table 2. Patient characteristics at treatment initiation. BSA: body surface area. ANA: antinuclear antibodies. ESR: erythrocyte sedimentation rate.

Table 3. Spearman's rank-order correlation (r_s) between the clinical activity score (CAS) and the three different imaging methods with 95-percent confidence intervals (CI).

FIGURE LEGENDS

Figure 1. Boxplots of the Clinical Activity Score (a), the relative differences in blood-flow determined by laser Doppler flowmetry (b), and absolute differences in skin temperature on infrared thermography (c) of active LS lesions compared to the unaffected corresponding contralateral site over time.

Figure 2. Course of the Clinical Activity Score (CAS) and the relative decrease in dermal blood flow determined by laser Doppler flowmetry over time in two patients (a, 10 year-old girl) and (b, 6 year-old girl).

Figure 3. Course of the mean values of the CAS components (erythema, skin tightness, atrophy, and spreading) over the study period.

Figure 4. Representative example of a 5 year-old boy with reversibility of skin sclerosis and regrowth of scalp hair. (a) before and (b) after 18 months of therapy.

Figure 5. Boxplots of the relative differences in dermal thickness (a) and echogenicity (b) of active LS lesions compared to the unaffected corresponding contralateral site over time.

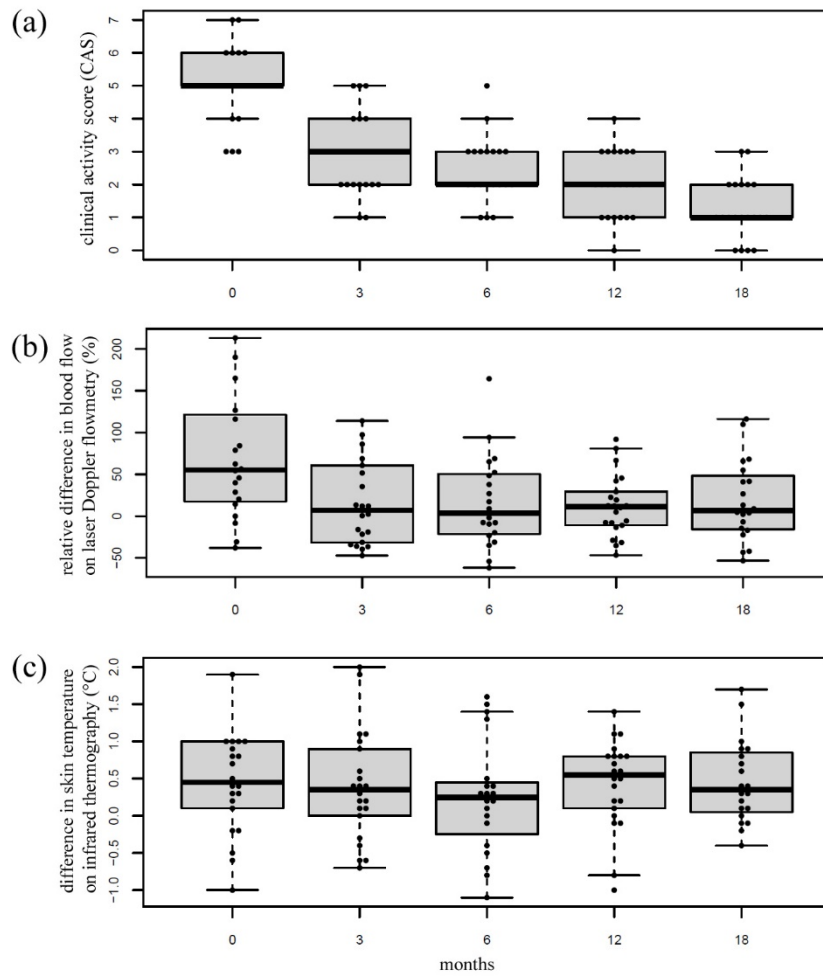


Figure 1. Boxplots of the Clinical Activity Score (a), the relative differences in blood-flow determined by laser Doppler flowmetry (b), and absolute differences in skin temperature on infrared thermography (c) of active LS lesions compared to the unaffected corresponding contralateral site over time.

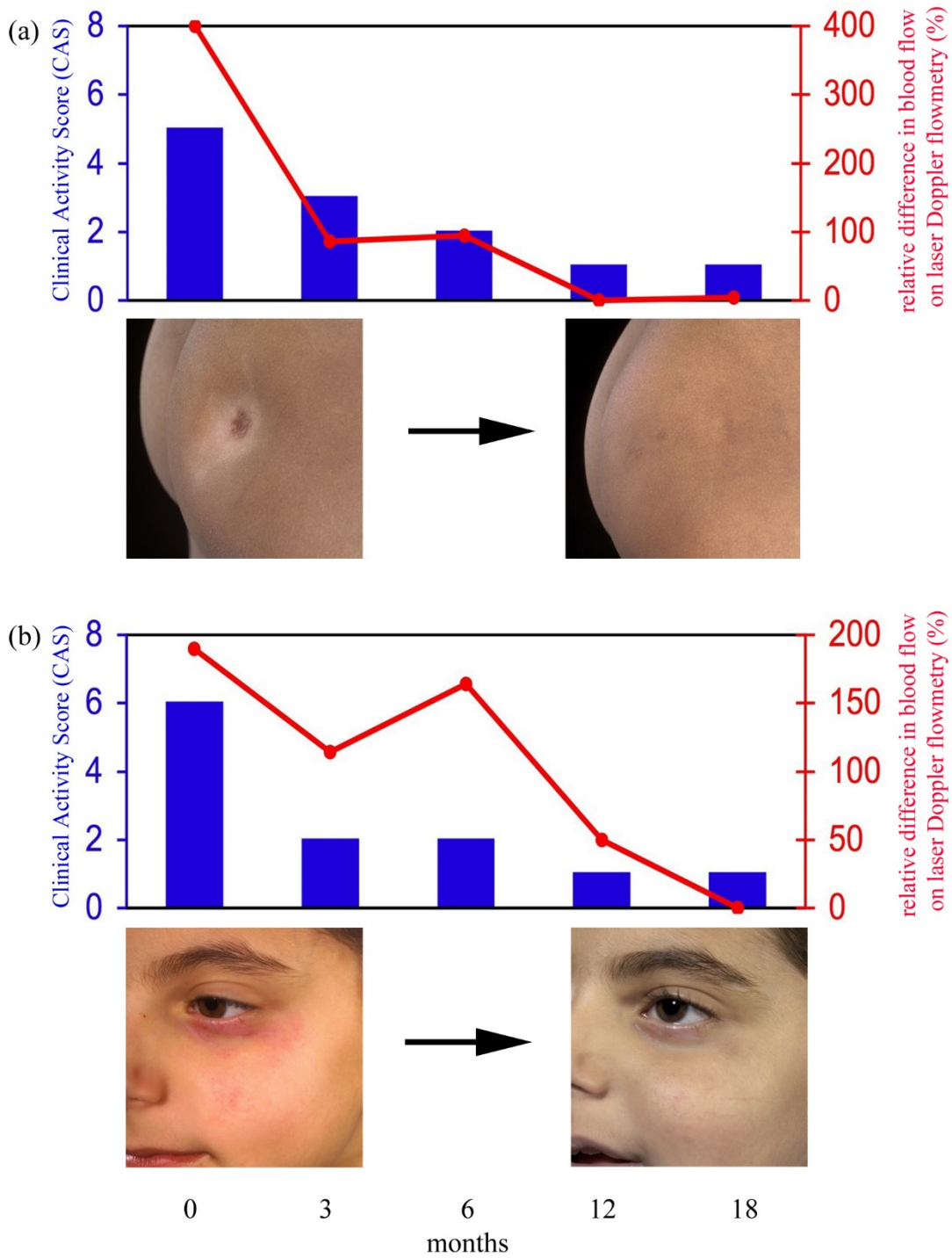


Figure 2. Course of the Clinical Activity Score (CAS) and the relative decrease in dermal blood flow determined by laser Doppler flowmetry over time in two patients (a) and (b).

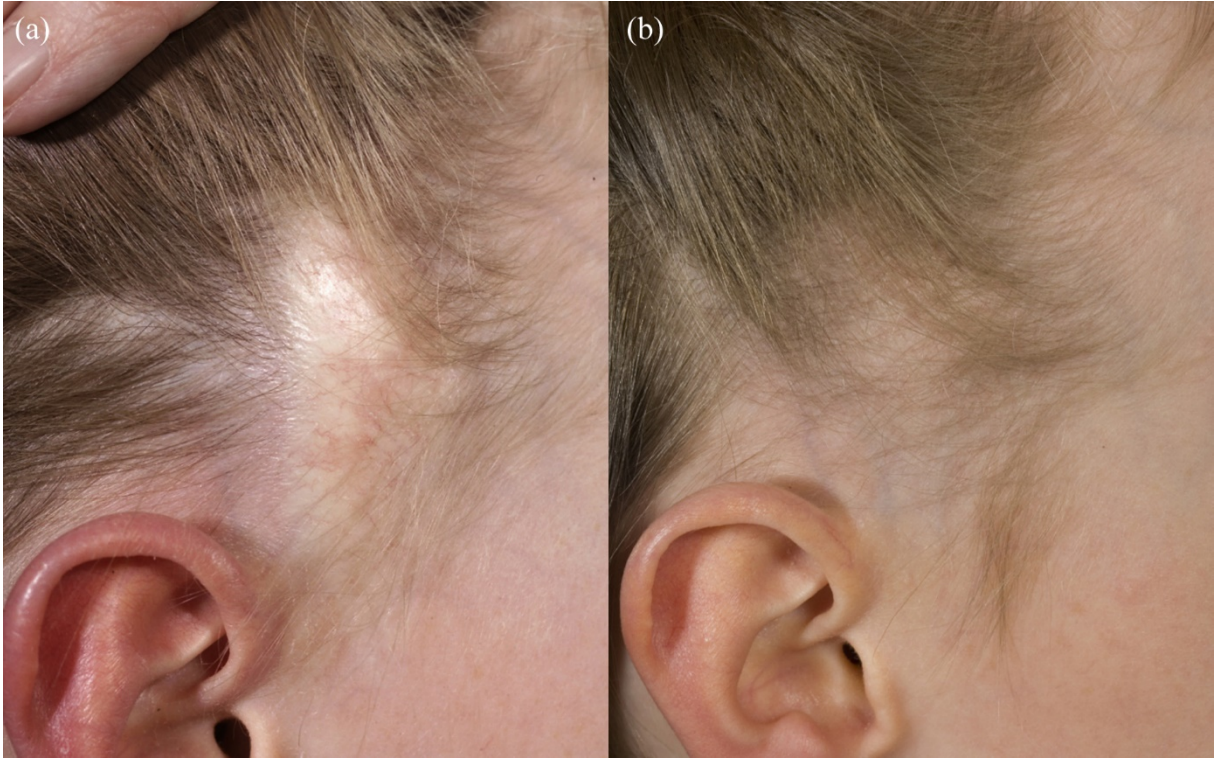


Figure 3. Representative example of the reversibility of skin sclerosis and regrowth of scalp hair. (a) Before and (b) after 18 months of therapy.

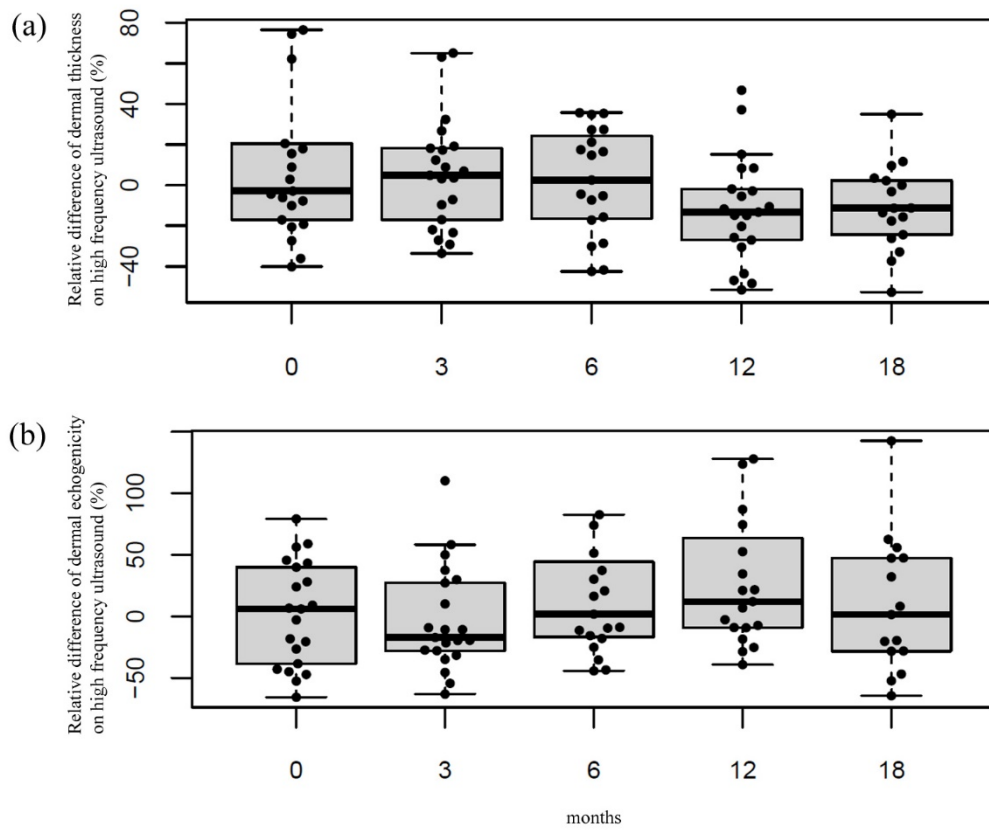


Figure 4. Boxplots of the relative differences in dermal thickness (a) and echogenicity (b) of active LS lesions compared to the unaffected corresponding contralateral site over time.

Change of CAS components over time

