

JAN-GERD RADEMACHER<sup>1</sup>, CHRIS WINCUP<sup>2,3</sup>, BJÖRN TAMPE<sup>1</sup>, PETER KORSTEN<sup>1</sup>

<sup>1</sup>Department of Nephrology and Rheumatology, University Medical Centre Göttingen, Göttingen, Germany <sup>2</sup>Department of Rheumatology, University College London, London, United Kingdom <sup>3</sup>Arthritis Research UK Centre for Adolescent Rheumatology, University College London, London, United Kingdom

## TITLE OF CASE

---

Combination therapy with Bosentan and Sildenafil for refractory digital ulcers and Raynaud's phenomenon in a 30-year-old woman with Systemic Sclerosis

## SUMMARY

---

Systemic sclerosis (SSc) is a rare autoimmune disease characterized by skin and organ fibrosis, as well as vasculopathy. Raynaud's phenomenon (RP) is almost universally present in SSc and can be the most debilitating symptom interfering with daily activities. RP may lead to the development of digital ulcers (DU), potentially complicated by superadded infection, tissue necrosis, and potentially auto-amputation. While there are several recommended treatments, efficacy is often variable. We report the case of a 30-year-old woman with diffuse SSc who suffered from severe RP and DU with digital tissue necrosis. Previous therapy with calcium channel blockers, intravenous iloprost, and bosentan had all failed to control symptoms. We added sildenafil (a phosphodiesterase-5 inhibitor) in combination with bosentan and observed a rapid and sustained treatment effect. RP severity, number of attacks, and attack duration decreased within two weeks of initiating treatment. Furthermore, this resulted in healing of established DU. This suggests that combination therapy targeting different sites of action in the endothelium may be a feasible treatment option for the most severely affected and refractory patients with RP and DU.

## BACKGROUND

---

Systemic sclerosis (SSc) is a chronic autoimmune condition characterized by internal organ fibrosis and vasculopathy (1). Vascular phenomena are almost universally present. The most common manifestation is RP affecting over 95% of patients (2). DU often complicate RP with potential progression to tissue necrosis, superadded bacterial infection, or auto-amputation (3). Whilst interstitial lung disease (ILD) and pulmonary arterial hypertension (PAH) are the leading causes of mortality in patients with SSc, RP and DU remain a significant challenge in clinical practice and impact upon patient activities of daily living and quality of life (4,5).

Although there are several treatment recommendations for RP (including non-pharmacological approaches, such as stress and cold-exposure avoidance), pharmacological treatment is the mainstay of therapy in more advanced disease (5,6). Medical therapy includes calcium-channel blockers (CCB), such as nifedipine and vasodilating agents, such as intravenous iloprost. Bosentan, an endothelin receptor antagonist (ERA), is only approved for the prevention of new DU, but not for treating established DU (6). In PAH, combination therapy with ambrisentan (an ERA) and tadalafil (a PDE5-inhibitor) has been shown to improve survival (7). For RP and DU, combination therapies have rarely been reported.

## CASE PRESENTATION

---

A 30-year-old female patient with diffuse SSc had been followed regularly in our Rheumatology outpatient clinic. SSc had been present for ten years on the basis of clinical and laboratory features of the disease (sclerodactyly, RP/DU, positive anti-nuclear and anti-Scl70 antibodies). Severe RP and DU had complicated her disease with previous episodes of bacterial infection and necrosis reported. Other manifestations of SSc included dysphagia. Past medical history included hypothyroidism and hysterectomy (following complications of bleeding due to placenta previa in a previous pregnancy). Over time, she reported an increasing frequency and intensity of RP attacks lasting for up to 30 minutes and occurring up to 25 times per day. On examination, DUs were present on several fingers and toes with associated tissue necrosis (**Figure 1A**). Current medication included bosentan (125mg twice daily), nifedipine (20mg once daily) and levothyroxine. Previous treatment included hydroxychloroquine, which was discontinued after three months due to headache. Methotrexate had been administered but stopped due to inefficacy. Intermittent iloprost infusions had been used but were also discontinued due to lack of efficacy and poor tolerability (headaches).

In summary this young patient was suffering from severe vasculopathy associated with SSc with impending digital auto-amputation due to tissue necrosis in the context of previous treatment that had been discontinued due to either inefficacy or side effects.

## INVESTIGATIONS

---

Anti-nuclear antibodies were positive with a titer of 1:1000 showing homogeneous pattern and mitotic figures. Anti-Scl70 antibodies were also detected. NT-proBNP was not elevated, electrocardiographic signs of right heart disease were absent and pulmonary function tests were unremarkable. Nailfold video capillaroscopy showed an "active pattern" according to the classification by Cutolo (8).

## DIFFERENTIAL DIAGNOSIS

---

Whilst digital ulcers with tissue necrosis represent a common complication of SSc, other causes were considered. Macrovascular disease (such as thrombotic occlusion of distal arteries) was excluded by ultrasonography and functional vasogram. Comorbidities, such as diabetes mellitus were excluded as contributing factors.

## TREATMENT

---

Considering the refractory DUs and severe attacks of RP, it was decided to initiate combination therapy with both bosentan and sildenafil. An initial dose of 20 mg sildenafil was well tolerated and increased to 20 mg twice daily after the first week. For safety reasons and borderline hypotension, we decided to stop treatment with the CCB.

## OUTCOME AND FOLLOW-UP

---

The patient noted an improvement in RP attack severity and duration after two weeks on combination treatment with marked clinical improvement of DU observed (**Figure 1B**). Ongoing benefits were observed over the following six months, in which the patient reported sustained improvement of RP and DU (**Figure 2A-C**). There were no clinical or laboratory adverse events, and the patient continues therapy without complications.

## **DISCUSSION** *Include a very brief review of similar published cases*

---

We report the case of a young female patient with diffuse SSc who suffered from severe vasculopathy despite maximal medical management. She markedly improved following treatment with combination therapy of bosentan and sildenafil.

A systematic review of the current literature found only four papers in which combination therapy has been used in RP and DU associated with SSc including three case (9–11) and a single retrospective monocentric study investigated the effect of bosentan and sildenafil on nailfold videocapillaroscopy (NVC) and clinical improvement (12). **Table 1** summarises these papers and the respective treatment regimens used in each case. The first description of successful treatment of digital ulcerations with sildenafil and bosentan was published in 2009 (9) and reports the case of a 72-year-old female with diffuse SSc who suffered from refractory DU for ten years. During combination therapy, complete healing of the wounds was observed within a few months. The second case of a 57-year-old woman, also suffering from diffuse SSc, experienced a complete occlusion of her ulcers on fingers and toes who also improved with combination therapy (10). A third case report described the benefit of combination therapy on macrovascular lesions in a 48-year-old woman with limited SSc and lower limb peripheral arterial occlusive disease who was initially treated with sildenafil monotherapy, resulting in digital ulcers healing. However, maximum walking distance increased only moderately. After the addition of bosentan, walking distance improved considerably and limb claudication symptoms were greatly improved (11).

In the most extensive published study, the effect of combined sildenafil and bosentan therapy on the Raynaud Condition Score, changes in NVC and Scleroderma Health Assessment Questionnaire (SHAQ) was retrospectively analyzed in 123 patients with systemic sclerosis (12). Patients were categorized into two groups according to ACR/EULAR criteria. The first group had a modified Rodnan skin score (mRSS) >10, the second group (mRSS ≤10) was characterized by the absence of skin thickening of the fingers of both hands extending proximal to the metacarpophalangeal joints and PAH. These two groups were divided into three subgroups receiving either bosentan, sildenafil or both. Data after three and six months were compared to the baseline. The RCS and SHAQ improved significantly with both bosentan and combination therapy with sildenafil. A change in the pattern of NVC from “active” or “late” pattern to “early” pattern was only observed with combination therapy in the group with early disease onset (ACR/EULAR criteria of ten points or less). The authors therefore suggest a particular benefit and vascular protection with a combination strategy in the early phases of the disease (12). Similar findings have been reported with combination therapy in SSc patients with PAH.

Regarding the pathogenesis of SSc, the current disease model assumes that changes in the vascular matrix already occur in early disease stages. Continued inflammation may lead to a profibrotic milieu, resulting in perivascular tissue modeling and eventually, skin fibrosis (1). An example of the pathophysiological correlate of these changes is increased endothelin-1 levels with consecutive activation of myofibroblasts in the affected organs such as skin or lungs. Endothelin also acts as a vasoactive mediator, causing potent vasoconstriction (13). RP is a typical early symptom of SSc and affects 95 % of patients (2). Approximately half of the patients experience DUs. A chronic recurrent course is not uncommon, which results in a considerable risk of bacterial infection in addition to significant disruption to daily routine. DUs are associated with a severe disease course and organ involvement (5) and tend to occur earlier in patients with anti-Scl-70 positivity (14).

---

In the presented case, we describe a significant improvement of DUs and RP and, probably most importantly, a subjective increase in quality of life with combination therapy. While there is ample published evidence on the use of the two drugs for PAH, comparatively little is reported on their combined use for DU and RP in SSc.

The 2017 revised EULAR recommendations for the treatment of SSc recommend the use of sildenafil for DU. Bosentan is recommended in combination with CCB, iloprost, or PDE-5 inhibitors, especially for refractory DU. Sildenafil is considered useful for the treatment of RP, while the use of bosentan is not recommended (6).

Bosentan is an endothelin A and B receptor antagonist that has been approved for the treatment of PAH in the United States and Europe. Bosentan does not lead to faster healing of ulcerations, but it can prevent the appearance of new DUs. Therefore, it has been approved for this indication in Europe based on results from two randomized clinical trials (15,16). In comparison, Sildenafil exerts its effects via inhibition of the phosphodiesterase 5 (PDE5), which results in an increased cGMP concentration and subsequent vasodilation (17). Small single centre studies showed a positive effect on DU and RP in SSc with an improvement of RP (decrease of attack frequency and duration). In addition, has been shown to result in healing of DU (18–20). Based on these encouraging results, the SEDUCE trial was performed, but could not demonstrate a shorter time to healing of DU; nevertheless, the rate of DU was lower in treated patients versus untreated patients after eight and twelve weeks (21). However, in Germany and the US, the use of sildenafil is restricted to PAH and has not been approved for the treatment of digital ulcers or RP. Since both drugs are metabolized via the cytochrome P450 system 3A4 (CYP3A4), pharmacological inhibition of sildenafil by bosentan may occur. This has been confirmed in a pharmacological study in patients with PAH (22). While we did not observe this effect in our patient, it has to be noted that doses used in this study differed from the doses we used in our patient.

In summary, a combination of sildenafil and bosentan represents a potentially useful treatment option from a pathophysiological point of view. Surprisingly, only small studies and case reports have provided evidence for the positive effect of combination therapy on DU and RP in SSc.

### **LEARNING POINTS/TAKE HOME MESSAGES 3-5 bullet points**

---

- Raynaud's phenomenon is almost universally present in SSc, difficult to treat and may lead to auto-amputation
- Current standard therapies are imperfect and often poorly tolerated, thus there is a need for newer treatment options
- Combination therapy with bosentan and sildenafil is a feasible option for refractory patients

### **REFERENCES**

---

1. Allanore Y, Simms R, Distler O, Trojanowska M, Pope J, Denton CP, et al. Systemic sclerosis. *Nat Rev Dis Primer*. 2015 23;1:15002.
2. Meier FMP, Frommer KW, Dinser R, Walker UA, Czirjak L, Denton CP, et al. Update on the profile of the EUSTAR cohort: an analysis of the EULAR Scleroderma Trials and Research group database. *Ann Rheum Dis*. 2012 Aug;71(8):1355–60.
3. Brand M, Hollaender R, Rosenberg D, Scott M, Hunsche E, Tyndall A, et al. An observational cohort study of patients with newly diagnosed digital ulcer disease secondary to systemic sclerosis registered in the EUSTAR database. *Clin Exp Rheumatol*. 2015 Aug;33(4 Suppl 91):S47-54.

4. Tyndall AJ, Bannert B, Vonk M, Airò P, Cozzi F, Carreira PE, et al. Causes and risk factors for death in systemic sclerosis: a study from the EULAR Scleroderma Trials and Research (EUSTAR) database. *Ann Rheum Dis*. 2010 Oct;69(10):1809–15.
5. Hughes M, Herrick AL. Digital ulcers in systemic sclerosis. *Rheumatology*. 2017 Jan 1;56(1):14–25.
6. Kowal-Bielecka O, Fransen J, Avouac J, Becker M, Kulak A, Allanore Y, et al. Update of EULAR recommendations for the treatment of systemic sclerosis. *Ann Rheum Dis*. 2017 Aug;76(8):1327–39.
7. Coghlan JG, Galiè N, Barberà JA, Frost AE, Ghofrani H-A, Hoeper MM, et al. Initial combination therapy with ambrisentan and tadalafil in connective tissue disease-associated pulmonary arterial hypertension (CTD-PAH): subgroup analysis from the AMBITION trial. *Ann Rheum Dis*. 2017 Jul;76(7):1219–27.
8. Lambova SN, Müller-Ladner U. Nailfold capillaroscopy in systemic sclerosis – state of the art: The evolving knowledge about capillaroscopic abnormalities in systemic sclerosis. *J Scleroderma Relat Disord*. 2019 Apr 15;2397198319833486.
9. Ambach A, Seo W, Bonnekoh B, Gollnick H. Low-dose combination therapy of severe digital ulcers in diffuse progressive systemic sclerosis with the endothelin-1 receptor antagonist bosentan and the phosphodiesterase V inhibitor sildenafil. *J Dtsch Dermatol Ges J Ger Soc Dermatol JDDG*. 2009 Oct;7(10):888–91.
10. Catarsi E, Doveri M, Tavoni A. Bosentan and sildenafil: successful treatment in a sclerodermic patient with refractory ulcers. *Reumatismo*. 2013 May 27;65(2):79–81.
11. Omarjee L, Fontaine C, Mahe G, Jaquinandi V. Improvement of peripheral artery disease with Sildenafil and Bosentan combined therapy in a patient with limited cutaneous systemic sclerosis: A case report. *Medicine (Baltimore)*. 2017 Jun;96(25):e6988.
12. Bellando-Randone S, Lepri G, Bruni C, Blagojevic J, Radicati A, Cometi L, et al. Combination therapy with Bosentan and Sildenafil improves Raynaud’s phenomenon and fosters the recovery of microvascular involvement in systemic sclerosis. *Clin Rheumatol*. 2016 Jan;35(1):127–32.
13. Abraham D, Distler O. How does endothelial cell injury start? The role of endothelin in systemic sclerosis. *Arthritis Res Ther*. 2007;9(Suppl 2):S2.
14. Denton CP, Krieg T, Guillevin L, Schwierin B, Rosenberg D, Silkey M, et al. Demographic, clinical and antibody characteristics of patients with digital ulcers in systemic sclerosis: data from the DUO Registry. *Ann Rheum Dis*. 2012 May;71(5):718–21.
15. Matucci-Cerinic M, Denton CP, Furst DE, Mayes MD, Hsu VM, Carpentier P, et al. Bosentan treatment of digital ulcers related to systemic sclerosis: results from the RAPIDS-2 randomised, double-blind, placebo-controlled trial. *Ann Rheum Dis*. 2011 Jan;70(1):32–8.
16. Korn JH, Mayes M, Matucci Cerinic M, Rainisio M, Pope J, Hachulla E, et al. Digital ulcers in systemic sclerosis: prevention by treatment with bosentan, an oral endothelin receptor antagonist. *Arthritis Rheum*. 2004 Dec;50(12):3985–93.
17. Hemnes AR, Champion HC. Sildenafil, a PDE5 inhibitor, in the treatment of pulmonary hypertension. *Expert Rev Cardiovasc Ther*. 2006 May 1;4(3):293–300.
18. Brueckner CS, Becker MO, Kroencke T, Huscher D, Scherer HU, Worm M, et al. Effect of sildenafil on digital ulcers in systemic sclerosis: analysis from a single centre pilot study. *Ann Rheum Dis*. 2010 Aug;69(8):1475–8.
19. Fries R, Shariat K, von Wilmowsky H, Böhm M. Sildenafil in the treatment of Raynaud’s phenomenon resistant to vasodilatory therapy. *Circulation*. 2005 Nov 8;112(19):2980–5.
20. Gore J, Silver R. Oral sildenafil for the treatment of Raynaud’s phenomenon and digital ulcers secondary to systemic sclerosis. *Ann Rheum Dis*. 2005 Sep;64(9):1387.
21. Hachulla E, Hatron P-Y, Carpentier P, Agard C, Chatelus E, Jegou P, et al. Efficacy of sildenafil on ischaemic digital ulcer healing in systemic sclerosis: the placebo-controlled SEDUCE study. *Ann Rheum Dis*. 2016 Jun;75(6):1009–15.
22. Paul GA, Gibbs JSR, Boobis AR, Abbas A, Wilkins MR. Bosentan decreases the plasma

---

## FIGURE/VIDEO CAPTIONS

---

**Figure 1. Clinical images of the patient's digits.** There is marked tissue necrosis with digital ulcers (A). Twelve weeks following treatment initiation, there is improved DU healing (B).

**Figure 2. Effect of bosentan and sildenafil on Raynaud attack frequency, duration, and intensity.** A. The maximum number of attacks decreased from more than 25 per day to 3 after four weeks of treatment. B. The maximum duration of attacks decreased from 30 minutes to a maximum of 2 minutes within the first weeks of treatment and was sustained. C. The Raynaud Condition Score (RCS), ranging from 0-10 (10 being the most intense score) decreased from 10 to 3 after four weeks.

---

## PATIENT'S PERSPECTIVE

---

“With bosentan therapy alone, there were very frequent Raynaud attacks. Most of them occurred at work, no matter whether I sat still or moved. Even with the slightest difference in temperature, the fingers turned blue. Finger ulcerations were present on both hands but worst on the right middle finger. My hands and feet were always cold and very sensitive to pain. Even the smallest touch was painful. There were hardly any situations in which I did not freeze. I used to wrap myself in a blanket.

As early as the first week of the new sildenafil therapy, I felt a slight improvement of the blood circulation. From the second week on, the effect of Sildenafil was noticeable. The number of daily Raynaud attacks decreased. Also, the strength and duration of the Raynaud attacks decreased. The freezing got better, and I had a slight feeling of warmth in my hands and feet. I do not have any side effects of Sildenafil. After three weeks, the therapy effect became even more intense. My Raynaud attacks continued to decrease from 20-25 per day to 3-4 per day. The attack duration was reduced from about 30 minutes to only 1-2 minutes. The feeling of warmth in the hands and feet has increased. Freezing has also become considerably less. The ulcerations on the fingers began to heal, especially the large ulcer on the right middle finger. Raynaud attacks do not occur so quickly in cold weather. Under psychological stress, it still occurs in certain situations. I have more joy in life and can do something on the outside, which I could do only in a very limited way before. It has an overall positive effect on my private life. All in all, I am doing really well with the therapy at the moment!”

---

## INTELLECTUAL PROPERTY RIGHTS ASSIGNMENT OR LICENCE STATEMENT

---

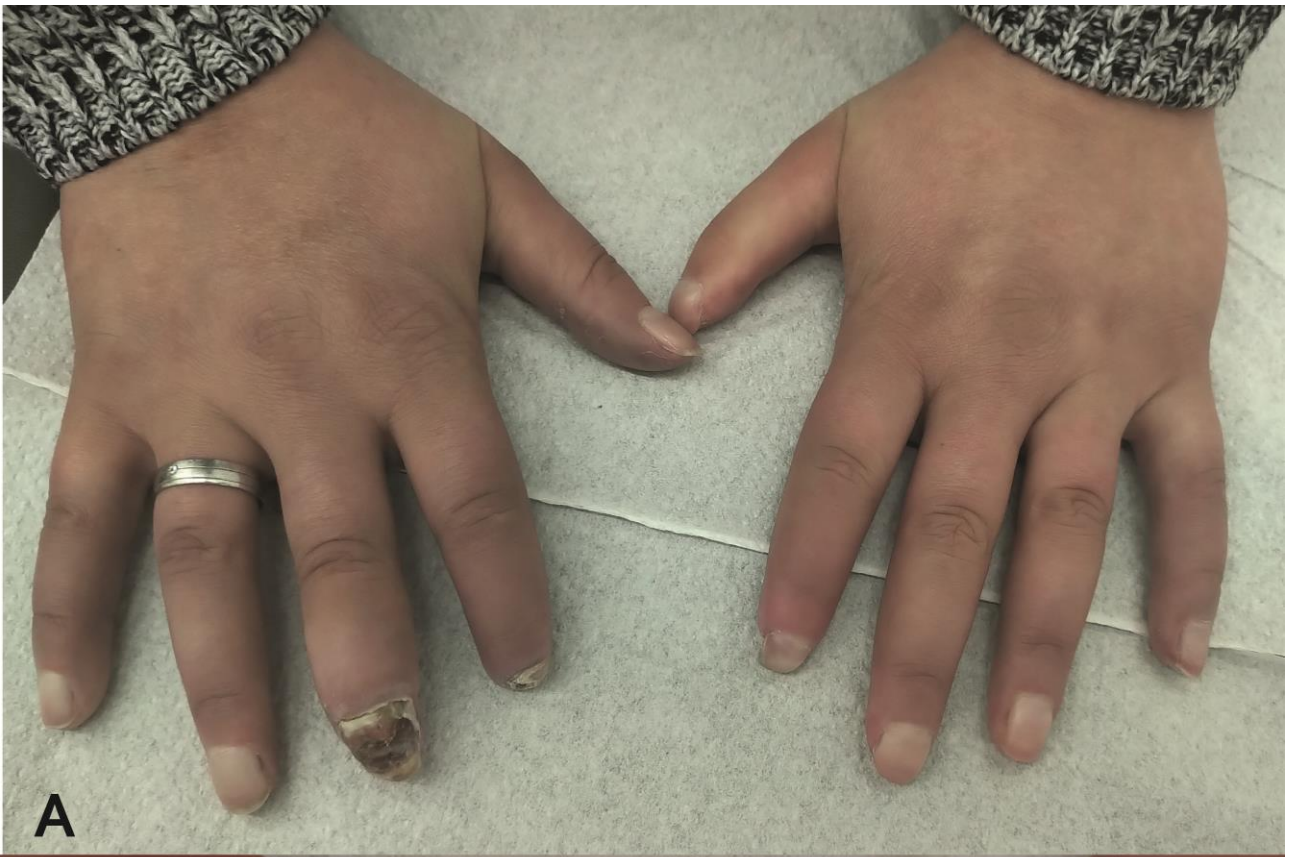
I, **Peter Korsten**, the Author has the right to grant and does grant on behalf of all authors, an exclusive licence and/or a non-exclusive licence for contributions from authors who are: i) UK Crown employees; ii) where BMJ has agreed a CC-BY licence shall apply, and/or iii) in accordance with the relevant stated licence terms for US Federal Government Employees acting in the course of the their employment, on a worldwide basis to the BMJ Publishing Group Ltd (“BMJ”) and its licensees, to permit this Work (as defined in the below licence), if accepted, to be published in BMJ Case Reports and any other BMJ products and to exploit all rights, as set out in our licence [author licence](#).

**Date:**

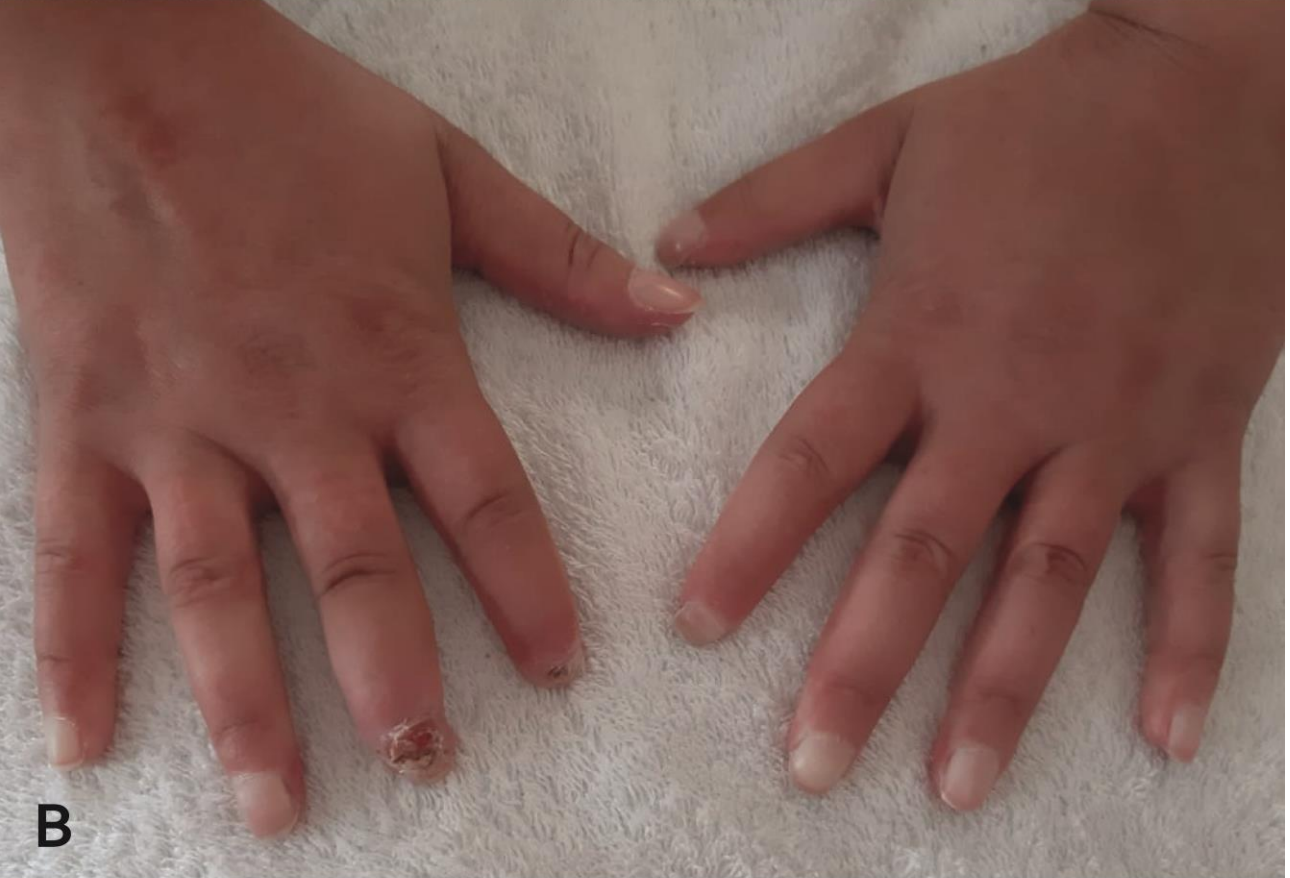## Figures

### Figure 1





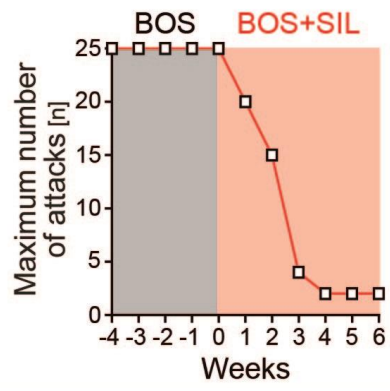
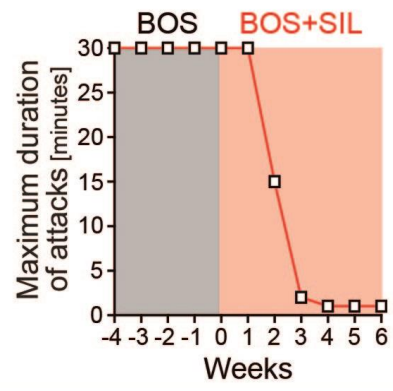
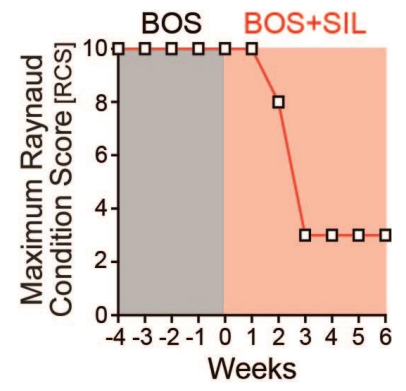
A



B

Figure 2



**A****B****C**

**Table 1.** Overview of published cases and studies of combination therapy with Bosentan and Sildenafil in Systemic Sclerosis.

First author	Year	N	Type	Dose used	Outcome(s)	Adverse events	Reference
Ambach et al.	2009	1	Case Report	BOS 62,5 mg/d, increased to 125 mg/d <i>and</i> SIL 25 mg/d, decreased to 12,5 mg/d	Complete healing of DU and prophylaxis of new lesions	Dose reduction (headache)	(9)
Catarsi et al.	2013	1	Case Report	BOS 62,5 mg/d, increased to 125 mg/d <i>and</i> SIL 25 mg/d, increased to 30 mg/d Concurrent medication with low-dose corticosteroids, CCB, and antiplatelets	Full recovery of skin ulcers on fingers and toes		(10)
Omarjee et al.	2017	1	Case Report	Week 1 – 44: SIL 20 mg/d Week 45-59: SIL 20 mg/d + BOS 62,5 mg/d Concurrent medication with CCB, antiplatelets, and statins	Healing of DU with SIL monotherapy; improvement of PAD and maximal walking distance with combination therapy		(11)
Bellando-Randone et al.	2016	123	Retrospective study	1. BOS (29 patients) 2. SIL (63 patients) 3. BOS + SIL (31 patients)	Group 1: Controversial changes in RCS, SHAQ and NVC pattern Group 2: Reduction in SHAQ, RCS, and “active” pattern in NVC Group 3: Shift from “active”/”late” to “early” pattern in NVC only in early SSc (ACR/EULAR points ≤10); reduction in SHAQ and RCS regardless of ACR/EULAR points		(12)

**Abbreviations used:** ACR/EULAR, American College of Rheumatology/European League against Rheumatism; BOS, bosentan; CCB, calcium channel blocker; DU, digital ulcer; NVC, nailfold videocapillaroscopy; PAD, periphery arterial disease; RCS, Raynaud condition score; SHAQ, Scleroderma Health Assessment Questionnaire; SIL, sildenafil; SSc, systemic sclerosis