


# Journal Pre-proof

Desmoplastic neurotropic melanoma of the buccal sulcus invading the inferior alveolar nerve subjected to interstitial photodynamic therapy

Waseem Jerjes, Zaid Hamdoon, Colin Hopper



PII: S1572-1000(19)30536-8  
DOI: <https://doi.org/10.1016/j.pdpdt.2019.101601>  
Reference: PDPDT 101601

To appear in: *Photodiagnosis and Photodynamic Therapy*

Received Date: 17 August 2019  
Revised Date: 23 October 2019  
Accepted Date: 8 November 2019

Please cite this article as: Jerjes W, Hamdoon Z, Hopper C, Desmoplastic neurotropic melanoma of the buccal sulcus invading the inferior alveolar nerve subjected to interstitial photodynamic therapy, *Photodiagnosis and Photodynamic Therapy* (2019), doi: <https://doi.org/10.1016/j.pdpdt.2019.101601>

This is a PDF file of an article that has undergone enhancements after acceptance, such as the addition of a cover page and metadata, and formatting for readability, but it is not yet the definitive version of record. This version will undergo additional copyediting, typesetting and review before it is published in its final form, but we are providing this version to give early visibility of the article. Please note that, during the production process, errors may be discovered which could affect the content, and all legal disclaimers that apply to the journal pertain.

© 2019 Published by Elsevier.

## **Desmoplastic neurotropic melanoma of the buccal sulcus invading the inferior alveolar nerve subjected to interstitial photodynamic therapy**

Waseem Jerjes<sup>1,2</sup>, Zaid Hamdoon<sup>3,4</sup>, Colin Hopper<sup>1,3</sup>

(1) UCL Medical School, London, UK

(2) North End Medical Centre, London, UK

(3) Unit of OMFS, UCL Eastman Dental Institute, London, UK

(4) College of Dental Medicine, University of Sharjah, UAE

Corresponding author: Waseem Jerjes, North End Medical Centre  
160 North End Rd, Hammersmith, London W14 9PR, UK, Email:  
waseem.jerjes@nhs.net

### **Highlights**

- Desmoplastic neurotropic melanoma (DNM) represents less than 4% of all melanomas
- Surgical resection with/out adjuvant radiotherapy is the main stay intervention.
- Interstitial PDT is a promising new method for managing desmoplastic neurotropic melanomas.

### **Introduction**

In 1971, Conley *et al.*<sup>1</sup> described an uncommon and distinct variant of melanoma that often presents as hard, subcutaneous tumor of fibrous appearance deep to a primary superficial melanotic lesion and this unusual growth was given a title of desmoplastic melanoma (DM). Reed and Leonard<sup>2</sup> later on identified a subgroup of DM with neurotropism and this was named “desmoplastic neurotropic melanoma” (DNM). Since then, numerous DM and DNM cases were described in the literature.

Desmoplastic neurotropic melanoma (DNM) represents less than 4% of all melanomas and is most commonly associated with sun-exposure and found in the head and neck. Often present as a benign-appearing non-pigmented nodule or plaque, which later progresses to nerve invasion (e.g. cranial nerves). The male to female ratio has been reported to be 2:1 with age range at time of diagnosis of 60-70 years.<sup>3-7</sup>

The atypical clinical behavior and presentation of these lesions is associated with the multiple histopathological variants which makes it a real challenge to diagnose. A high index of suspicion is usually employed when dealing with these lesions due to their known aggressive nature, high recurrence rate and metastasizing pattern. Early diagnosis and intervention can significantly improve prognosis and survival<sup>3-7</sup>.

Surgical resection with/without adjuvant radiotherapy is the main stay intervention. A study by Maurichi et al.<sup>8</sup> suggested that a resection margin of 2cm (compared to 1cm) is linked to reduced local recurrence (18.5% compared to 40%). The recurrence rate remains high and associated with increased risk of distant spread of the disease. Many centres around the world apply the cutaneous melanoma treatment guidelines to treat desmoplastic neurotropic melanoma, despite the latter reported to be more aggressive with increased loco-regional spread, recurrence and distant metastasis.<sup>9-11</sup> The application of adjuvant radiotherapy has been linked to significant reduction in local recurrence.<sup>12-13</sup>

The use of photodynamic therapy in the management of a variety of tissue pathologies in the head and neck have been well documented. Our studies showed that it could be used as curative and palliative intervention in the treatment of superficial and deep cutaneous or mucosal disease. The technology depends on light activation of a photosensitizing chemotherapeutic agent in the presence of oxygen, which will lead to tissue death but direct cell death, and/or elimination of oxygen supply to the pathological tissue exposed to a light of a specific wavelength.<sup>14-17</sup>

We report our first experience in managing a very challenging case of desmoplastic neurotropic melanoma arising in the buccal sulcus with extension to the inferior alveolar canal (nerve) in a patient that opted to receive PDT instead of mainstream intervention (i.e. surgery with/without adjuvant radiotherapy).

#### Case report

A 59-year-old Caucasian male presented with a 3mm in diameter non-pigmented nodular lesion of the alveolar sulcus near the lower premolars area. This was managed with simple excision and closure. The histopathological examination showed desmoplastic features with focal inflammation and clear margins. Further investigations did not confirm this to be desmoplastic melanoma or desmoplastic neurotropic melanoma. Radiological investigations were satisfactory and the multidiscipline team decision was made not to undertake any further interventions and to closely monitor the patient due to increased risk of recurrence.

Twenty-six months after the initial excision, the patient reported altered sensation (paraesthesia) of the right chin area, which has been ongoing for two weeks. At the time of assessment, the altered sensation was associated with pain (dysesthesia) and there was a noticeable swelling of the area (right lateral border of mandible and chin) and the patient reported swallowing difficulties on the same side. On close examination, there was atrophy of the muscles of that area causing deviation of the mandible on opening. Dental panoramic radiograph revealed a well-circumscribed radiolucency over the mental foramen. US examination confirmed the presence of the lesion and its growth and at the same time ruled out any nodal involvement (Figure 1).

An incisional biopsy confirmed the appearance desmoplastic and neuroid elements. The tumor cells were ill defined with slightly eosinophilic cytoplasm and pleomorphic oval, vesicular nuclei with small nucleoli. Mitotic activity was inconspicuous. The stroma showed marked desmoplasia and a focal lymphoid inflammatory infiltrate. The diagnosis of desmoplastic neurotropic melanoma (DNM) was confirmed. Computed tomography (CT) of the head and neck was carried out and confirmed the lesion dimensions and with no nodal disease.

Following a multidiscipline team meeting, the patient was offered surgery as the first treatment option with/out adjuvant radiotherapy. The surgical intervention would have included a partial mandibulectomy and reconstruction with prophylactic neck dissection. The patient declined this treatment option. The oncology team did discuss chemotherapeutic treatment but the patient also declined this. After consideration, photodynamic therapy was discussed as an alternative intervention with the patient and he was informed that we have no experience in treating such rare high-risk pathologies. The patient made a decision and given informed consent to undergo interstitial PDT using mTHPC as the photosensitizer.

mTHPC, with a dose of 0.15mg/kg, was used as the photosensitizing agent and was introduced intravenously four days prior to tissue illumination with 652nm diode laser. The tumour volume was measured and found to be 29 cm<sup>3</sup>. Intra-operatively, spinal needles were fed into the tumour under US-guidance in the labial and buccal sulci, as well as through the mental foramen and inferior alveolar canal. Optical fibres were, then, inserted through the needles and allowed to protrude by 2-3mm to deliver maximum light therapy. As the diameter of necrosis post-PDT doesn't exceed 1cm, the needles were pulled back 1cm at a time to allow treatment of the thick tumour (i.e. the tumour involving the inferior alveolar nerve while travelling in the bony canal). The total energy delivered per port was 20 joules per linear cm of fibre (Figure 2).

In the immediate post-PDT phase, light exposure was implemented at an incremental rate of 100lux/day. Pain control was mainly through standard analgesics (i.e. paracetamol and NSAIDs). There was no reported adverse events during the immediate post-PDT phase as well as 1-week and 4-week follow ups.

At 3 months review, the patient reported resolution of all paraesthesia/dysesthesia symptoms. Further assessment took place at 6-month follow-up revealed reduction in the size of the tumour (Figure 3) by 70%. To date (48 months post-PDT), there has been no increase in the size of the tumour and no reported symptoms or disease spread. The most recently histopathology showed desmoplastic features with focal inflammation and clear margins

## Discussion

The application of the photodynamic therapy (PDT) in the head and neck has proved its applicability in the management of carcinomas and sarcomas, as

well as hamartomatous malformations. This was a unique case where interstitial PDT was used to treat a high-risk pathology invading the inferior alveolar nerve inside its bony canal.

The patient in this case elected to receive a treatment that is not routinely offered to treat such pathology. In fact we believe this is the first described case of treating such pathology and also carrying out interstitial PDT treatment in such a challenging anatomical location.

An iso-illumination treatment plan is carefully implemented and supervised by a senior physicist to ensure adequate light delivery to all suspect areas with minimal overlapping between the fields of treatment using a grid system. No measurements are made with regard to the distribution of the light fluence rate, the optical properties, the drug concentration, and the tissue oxygenation for PDT, as these factors had already been quantified in previous studies carried out in our centre. Incomplete tumour response might be a result of inadequate light dose.<sup>18</sup>

The current patient had a lesion causing facial disfigurement with severe pain. PDT led to significant reduction in the lesion size after only one round of treatment. This has led to complete symptoms resolution with no morbidity. It is important to clarify that PDT did not achieve cure at this stage but has led to significant shrinkage in the lesion associated with disease arrest four years post illumination. Successful treatment of these lesions does not require a complete PDT response and the possibility remains that a further round of PDT could be employed, especially in the case of regrowth and recurrence of symptoms.

The only current intervention that will be aimed, as a cure, is right-sided mandibular resection with its related soft tissues and major reconstructive surgery followed by adjuvant radiotherapy. If this to occur, the recurrence rate will remain high (up to 20%) which may mean further surgery followed by chemoradiation.<sup>9-13</sup> This is an option that is potentially curative but not every patient will be willing to sign up for.

It is also worth mentioning that PDT is an intervention that can be applied before or after any of the conventional cancer treatment modalities without compromising them or being compromised by them. It still remains a modality with advantages that will make it appealing to many patients with early, advanced or recurrent disease.

With high rate of recurrences, invasion of adjacent structures (salivary glands and cranial vault) is often seen. A significant number of treatment failures in desmoplastic neurotropic melanomas may result from a failure to appreciate early neural invasion. Intracranial extension has been commonly reported and is assumed to be related to peri-neural or intra-neural invasion. It is important to be aware of this fact when dealing with such locally aggressive disease. The present case showed infiltration of the inferior alveolar nerve, but there was no evidence to date of infiltration of the central nervous system.

Surgical excision is the recommended initial therapy with a locally aggressive resection and thorough evaluation of the surgical margins to assess the possibility of peri-neural infiltration.<sup>11</sup> More success with radiotherapy than chemotherapy has been reported for the control of unresectable cases.<sup>6,10</sup> Radiotherapy for melanoma may have up to a 24% complete response rate.<sup>10</sup> Chemotherapy has been reported to palliate some patients with disseminated DM/DNM without long-term control.<sup>4</sup>

Early observations suggested that patients with desmoplastic melanoma respond better than expected to immunotherapy, prompting a more formal analysis.<sup>19</sup> Eroglu et al. recently performed a retrospective, multi-site review of 60 patients with advanced, unresectable desmoplastic melanoma who received PD-1 or PDL1 blockade therapy. The group reported objective tumor responses rate in 70% of patients, one of the highest response rates to single agent PD-1 blockade therapy in any pathologically defined cancer. In addition, they reported that 32% of patients achieved a complete response.<sup>20</sup> Unfortunately we didn't have access to immunotherapy in our centre at the time of treating this patient. This is an option will be discussed by our multi-discipline meeting when dealing with similar cases in the future.

In conclusion, interstitial PDT is a promising new method for managing desmoplastic neurotropic melanomas. It is minimally invasive, repeatable and a relatively low-risk treatment modality. However before it becomes the standard protocol for the treatment of these rare pathologies, further studies are needed to confirm its efficiency and safety.

## References

1. Conley J, Lattes R, Orr W. Desmoplastic malignant melanoma (a rare variant of spindle cell melanoma). *Cancer*. 1971 Oct;28(4):914-36.
2. Reed JG, Leonard DD. Neurotropic melanoma: a variant of desmoplastic melanoma. *Am J Surg Pathol*. 1979 Aug;3(4):301-11.
3. Quinn MJ, Crotty KA, Thompson JF, Coates AS, O'Brien CJ, McCarthy MH. Desmoplastic and desmoplastic neurotropic melanoma. Experience with 280 patients. *Cancer*. 1998 Sep 15;83(6):1128-35.
4. Smithers BM, Mcleod GR, Little JH. Desmoplastic melanoma patterns of recurrence. *World J Surg* 1992;16:186-90.
5. Gentile RD, Donovan DT. Neurotropic melanoma of the head and neck. *Laryngoscope*. 1985 Oct;95(10):1161-6.
6. Anderson TD, Weber RS, Guerry D, Elder D, Schuchter L, Loevner LA, Rosenthal DI. Desmoplastic neurotropic melanoma of the head and neck: the role of radiation therapy. *Head Neck*. 2002 Dec;24(12):1068-71.
7. Chang PC, Fischbein NJ, McCalmont TH, Kashani-Sabet M, Zettersten EM, Liu AY, Weissman JL. Perineural spread of malignant melanoma of the head and neck: clinical and imaging features. *Am J Neurorad* 2004;25:331-5.
8. Maurichi A, Miceli R, Camerini T, Contiero P, Patuzzo R, Tragni G, Crippa F, Romanidis K, Ruggeri R, Carbone A, Santinami M. Pure desmoplastic melanoma: a melanoma with distinctive clinical behavior. *Ann Surg* 2010 Dec;252(6):1052-7.
9. Chen JY, Hruby G, Scolyer RA, Murali R, Hong A, Fitzgerald P, Pham TT, Quinn MJ, Thompson JF. Desmoplastic neurotropic melanoma: a clinicopathologic analysis of 128 cases. *Cancer* 2008 Nov 15;113(10):2770-8.
10. Strom T, Caudell JJ, Han D, Zager JS, Yu D, Cruse CW, Marzban SS, Messina JL, Trotti AM, Sondak VK, Rao NG. Radiotherapy influences local control in patients with desmoplastic melanoma. *Cancer* 2014 May 1;120(9):1369-78.
11. Han D, Han G, Zhao X, Rao NG, Messina JL, Marzban SS, Sarnaik AA, Cruse CW, Sondak VK, Zager JS. Clinicopathologic predictors of survival in patients with desmoplastic melanoma. *PLoS One* 2015;10(3):e0119716.
12. Guadagnolo BA, Prieto V, Weber R, Ross MI, Zagars GK. The role of adjuvant radiotherapy in the local management of desmoplastic melanoma. *Cancer* 2014 May 1;120(9):1361-8.

13. Oliver DE, Patel KR, Switchenko J, Parker D, Lawson DH, Delman KA, Kudchadkar RR, Khan MK. Roles of adjuvant and salvage radiotherapy for desmoplastic melanoma. *Melanoma Res* 2016 Feb;26(1):35-41.
14. Jerjes W, Upile T, Betz CS, El Maaytah M, Abbas S, Wright A, Hopper C. The application of photodynamic therapy in the head and neck. *Dent Update*. 2007 Oct;34(8):478-80, 483-4, 486.
15. Jerjes W, Upile T, Akram S, Hopper C. The surgical palliation of advanced head and neck cancer using photodynamic therapy. *Clin Oncol (R Coll Radiol)*. 2010 Nov;22(9):785-91.
16. Jerjes W, Upile T, Hamdoon Z, Alexander Mosse C, Morcos M, Hopper C. Photodynamic therapy outcome for T1/T2 N0 oral squamous cell carcinoma. *Lasers Surg Med*. 2011 Aug;43(6):463-9.
17. Jerjes W, Yousif AA, Hamdoon Z, Hopper C. Non-metastatic cutaneous squamous cell carcinoma treated with photodynamic therapy using intravenous mTHPC. *Photodiagnosis Photodyn Ther*. 2019 Aug 5.
18. Jäger HR, Taylor MN, Theodossy T, Hopper C. MR imaging-guided interstitial photodynamic laser therapy for advanced head and neck tumors. *AJNR Am J Neuroradiol* 2005;26 (5):1193-1200.
19. Ochoa CE, Joseph RW. Desmoplastic melanoma: a brief review and the efficacy of immunotherapy. *Expert Rev Anticancer Ther*. 2019 Mar;19(3):205-207.
20. Eroglu Z, Zaretsky JM, Hu-Lieskovan S, Kim DW, Algazi A, Johnson DB, Liniker E, Ben Kong, Munhoz R, Rapisuwon S, Gherardini PF, Chmielowski B, Wang X, Shintaku IP, Wei C, Sosman JA, Joseph RW, Postow MA, Carlino MS, Hwu WJ, Scolyer RA, Messina J, Cochran AJ, Long GV, Ribas A. High response rate to PD-1 blockade in desmoplastic melanomas. *Nature*. 2018 Jan 18;553(7688):347-350.



## Figures

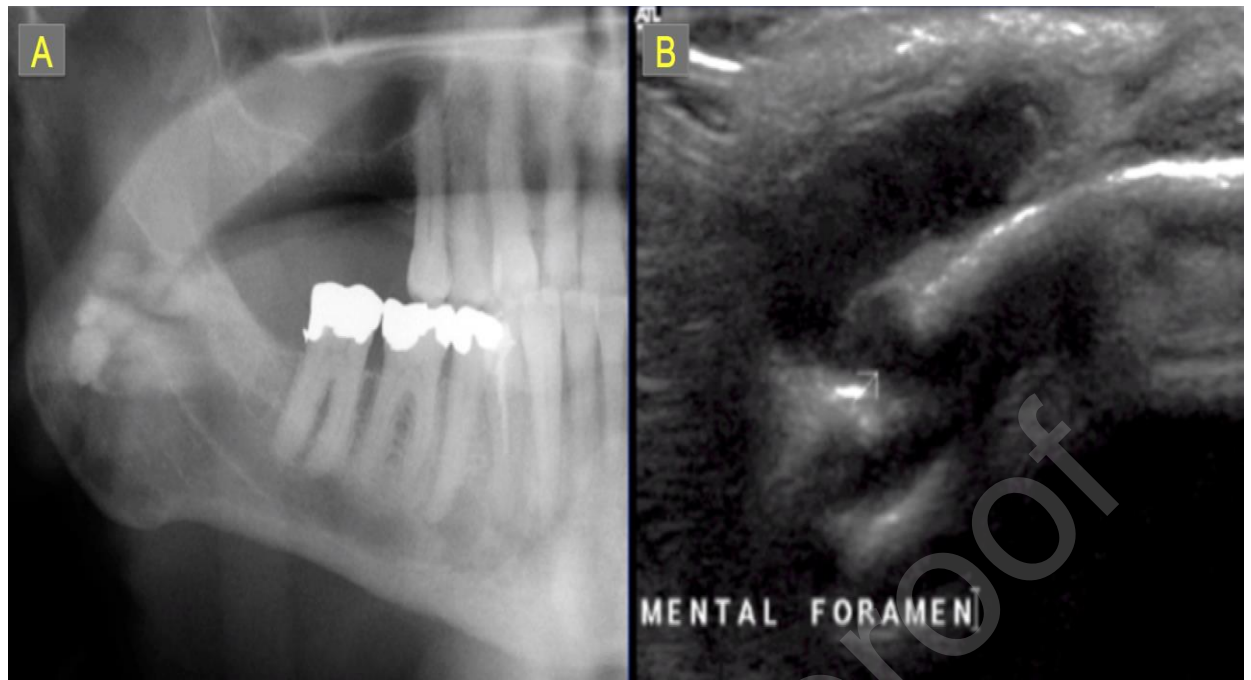

Figure 1: A: partial OPG showing desmoplastic neurotropic melanoma of the buccal sulcus. A diagnosis was confirmed via histopathology. B: US showing the pathology invasion of the right mandibular mental foramen.

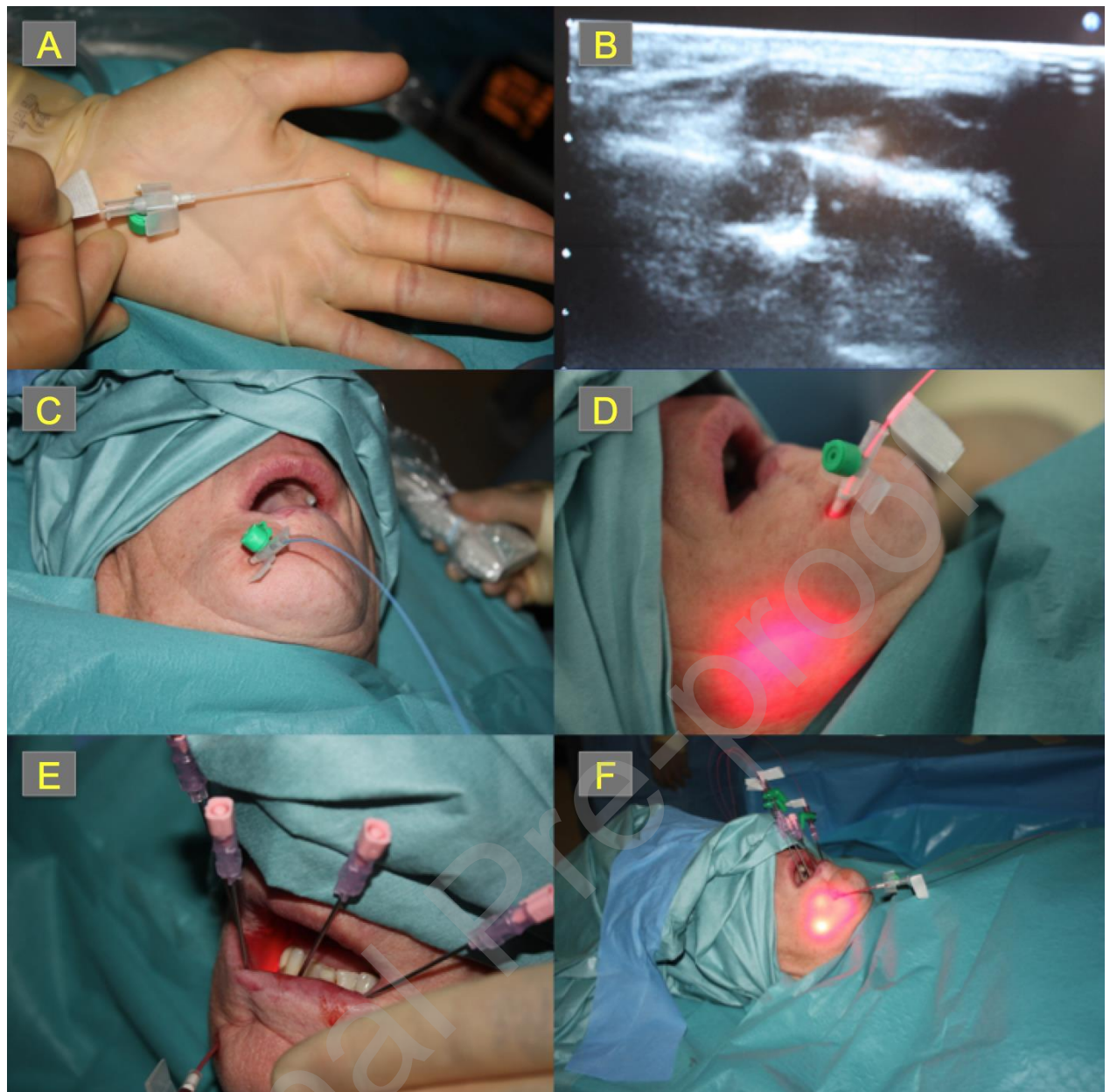


Figure 2: Clinical images of photodynamic management of desmoplastic neurotropic melanoma of the buccal sulcus with extension to the inferior alveolar canal. A: Bare polished tip laser light delivery fibres with a core diameter of 400 $\mu$ m are introduced through the spinal needles into the suspect tissue. B: A head and neck radiologist, using 2D ultrasound (with high resolution), examines the pathological tissue (centre and periphery) with the probe to assess tumour volume, depth, invasion of vascular structures, hollow organs or hard tissue. Then 18 gauge 70mm long spinal needles are inserted under ultrasound guidance into the target tissue. C: The patient is prepped and draped as with any standard surgical procedure. The fibres are allowed to protrude by 2-3 mm from the needle tip into tissue to ensure maximal tissue illumination. Interstitial optical fibre is fed into the mental foramen through the inferior alveolar canal to treat the pathology invasion of the inferior alveolar nerve. D: A four-channel 652nm diode laser is used for illumination. E: Needles are (generally) inserted parallel to each other with 1 cm distance in

between to ensure no overlapping fields. F: Multiple sites are treated simultaneously.

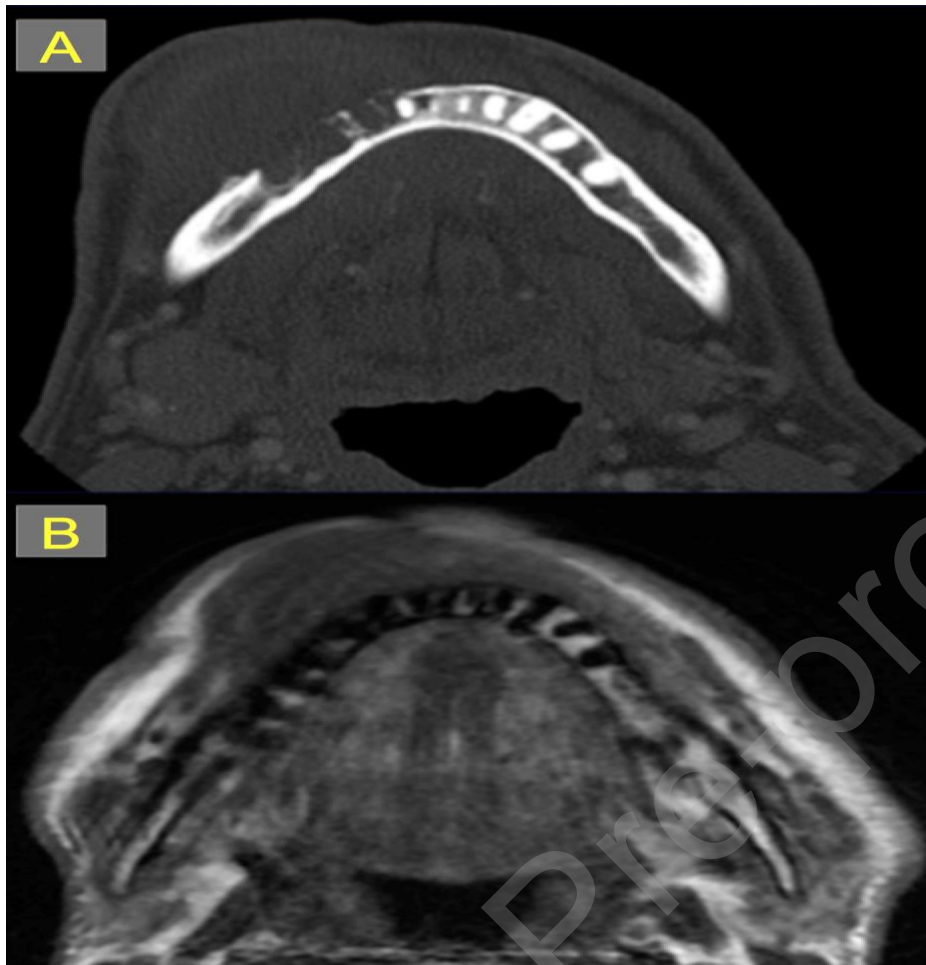


Figure 3: A: Pre- and B: post-PDT (at 6 months) imaging showing pathology shrinkage which was associated with symptom resolution. The tumour volume was measured and found to be 29 cm<sup>3</sup>. At 6-month follow-up a 70% reduction in the size of the tumour was achieved.