



Innovation

ISCFS2019/ABS-445

REVOLUTIONISING DISTRACTION OSTEOGENESIS WITH THREE-DIMENSIONAL MRI AND A NOVEL 3D PRINTED TRANSFER DEVICE AND CARBON-PEEK BONE PINS.

Karen A. Eley¹, Gaspar Delso^{1,2}, Mehran Moazen³, Maryam Javidan³, Joshua Kraggie¹, Stephen R. Watt-Smith⁴

¹Radiology, University of Cambridge, ²GE Healthcare, Cambridge, ³Biomedical Engineering, ⁴Eastman Dental Institute, UCL, London, United Kingdom

Preferred presentation method: ORAL

Introduction & Objectives: Despite the complex anatomy of the craniofacial skeleton, distraction osteogenesis for conditions such as hemifacial microsomia remains reliant upon two-dimensional planning using radiographs. Three-dimensional imaging with CT or MRI would enable improved accuracy in sequential bony movement resulting in more predictable outcomes. However, there are two key limitations (1) distraction devices result in considerable metallic artefact/signal void on CT and MRI respectively, and (2) the use of sequential ionising radiation (with CT and/or radiographs) is of concern in young children. The objectives of this study were to develop an artefact free mandibular distractor device to permit 3D MRI imaging for children with hemifacial microsomia.

Material & Methods: Utilising a standard mandibular distractor as the starting point, we engineered distractor bone pins from carbon-polyetheretherketone (PEEK) and a temporary ex-fix transfer device which was 3D printed in Translucent PolyJet Resin using Selective Laser Sintering. The carbon-PEEK pins were implanted into an animal model (sheep head) and the transfer device attached. Imaging was acquired on both 1.5T and 3T magnets (GE and Siemens). The imaging protocol included “Black Bone,” T1, T2, FLAIR, STIR and ZTE/PETRA imaging. Comparable CT imaging was acquired with bone algorithms. 3D volume rendering was completed using Fovia *High Definition Volume Rendering*® software.

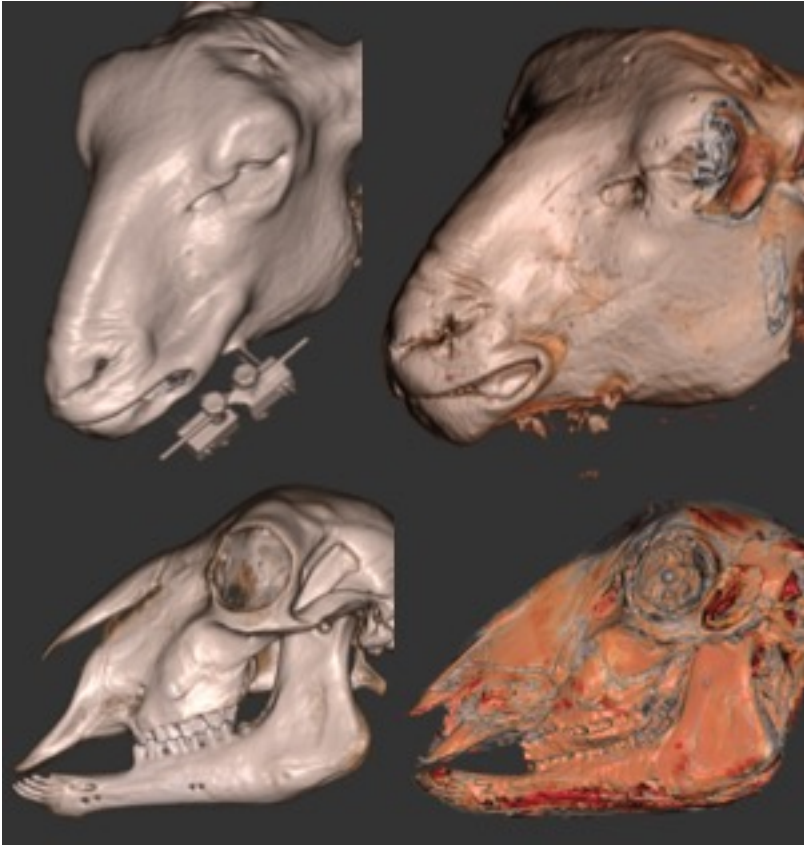
Results: The carbon-PEEK pins resulted in a signal void equivalent to the dimension of the pin (and in some areas a small amount of inadvertently introduced air), with no adjacent areas of MR-signal loss i.e. no artefact. The external transfer device was not visualised at all on MRI, thus resulting in no artefact. 3D MRI acquisition permitted both reconstruction of the imaging datasets in any plane, and volume rendering of the bone. No artefact was seen on CT imaging from the distractor or pins.

Figure 1 shows 3D volume rendered CT imaging with the distractor insitu (top left) and pin sites (bottom left) and BB with non-visualisation of the distractor (top right) and absence of artefact (bottom right).

Conclusion: A 3D printed transfer device could be utilised temporarily during the acquisition of imaging as an artefact-free method of 3D monitoring and planning. Utilising carbon-PEEK pins as an alternative to conventional stainless steel pins would also further minimise any associated imaging artefact. This has the potential to completely revolutionise how we perform distraction osteogenesis in the future by permitting three-dimensional planning, with subsequent improvement in patient outcome.

Would you like to insert pictures?: Yes

Picture 1:



Disclosure of Interest: K. Eley: None Declared, G. Delso Conflict with: GE Healthcare, M. Moazen: None Declared, M. Javidan: None Declared, J. Kraggie: None Declared, S. Watt-Smith: None Declared