

Long Gap Oesophageal Atresia

Long term Outcomes and Future Therapy

Edward Hannon

UCL Great Ormond St Institute of Child Health

UCL

Thesis for MD (Res)

I, Edward Hannon confirm that the work presented in this thesis is my own. Where information has been derived from other sources, I confirm that this has been indicated in the thesis.

Abstract

Introduction

Gastric transposition (GT) is currently the oesophageal replacement of choice for long gap oesophageal atresia (OA). Long-term outcomes of this are poorly understood. Different therapeutic options being explored include tissue engineering.

Aims of the work in this thesis were to explore the long-term outcomes of GT and design animal models for in vivo testing of tissue engineered oesophagi.

Methods

Two long-term follow up studies of OA and GT for OA were completed in collaboration with patient support groups and from a cohort of patients from the author's institution respectively.

Outcomes included morbidity, symptoms and health related quality of life.

Animal model development focussed on rat and rabbit models utilising the long cervical oesophagus to attempt circumferential implantation of tissue engineered oesophagi. Various modifications were made during the study including; gastrostomies, stenting, and variation of anaesthetic and operative technique.

Results

Long-term gastrointestinal and respiratory morbidity are frequently reported after OA repair. Following GT, adulthood morbidity includes strictures, redo surgery, supplementary feeding, anaemia and depression. Quality of life is negatively affected by OA and GT.

A rat model for oesophageal tissue engineering was complicated by scaffold collapse and obstruction. Following seeding of cells and culture, scaffolds were mechanically weaker.

Despite modifications in the rabbit model long term survival was limited by respiratory problems, scaffold obstruction and gastrostomy problems.

Conclusions

Long-term outcomes of OA and more specifically OA treated with GT are associated with significant morbidity including mental health problems and decreased quality of life. This mandates better follow up and transitional care when patients leave paediatric services.

Neither rat nor rabbit models are robust enough to provide reliable outcomes suitable for pre-clinical studies of oesophageal tissue engineering. Nevertheless, lessons learned from these models will be useful in developing other preclinical models of oesophageal replacement and ultimately in clinical practice.

Impact Statement

Currently there are limited data and high quality research describing the adulthood outcomes of OA and GT performed in childhood and therefore these data are important in defining these outcomes for a variety of reasons at a national and international level including:

1. Improving understanding of patients and health care professionals – which in turn helps counselling parents and clinical decision making
2. Mandating long term follow up and quality transitional care for all of these patients from paediatric to adult services – something that at present is poorly organised and delivered across a variety of congenital surgical conditions
3. Facilitate decision making at a national level about provision of such complex services through establishing a British Association of Paediatric Surgeons interest group and through on-going work and discussion with the national patient support group TOFS.

The work has also been presented internationally and published in peer review journals (see list at end of thesis) in efforts to disseminate this knowledge resulting in increased interest in the work and leading to research collaboration with colleagues in a number of different UK centres including a study into transitional care in OA. One key area that has had little focus in the past is health related quality of life and mental health – a previously un-reported morbidity following GT for OA and one which should now be focussed on more clinically as we are aware of it as a long term problem into adulthood.

Animal model development is a key part in the wider strategy of developing a clinically usable tissue engineered option for oesophageal replacement and its wider clinical application. Our group has already published encouraging in vitro results on oesophageal tissue engineering using the same decellularised scaffolds (Urbani, Camilli et al. 2018) and as such the results from this work were relatively

disappointing. However, this model development project has provided essential information for developing the programme further towards pre-clinical studies in terms of consideration of which large animal model to use. Information regarding the need for stenting of scaffolds, gastrostomy use and the need for further mechanical testing of cultured scaffolds to ensure they are strong enough are key to moving towards a model which can reliably deliver longer term outcomes. With this will come the ability to study not only the scaffold in vivo but also to study the fate of seeded cells which will be important for the longer-term function of implanted scaffolds. This work helps moves us closer towards the possibility of an off the shelf tissue engineering solution to the complex condition of OA and to replace the current treatment of GT and its associated long-term morbidity.

These results will be disseminated in peer reviewed journals to help inform the wider tissue engineering community of the advantages and disadvantages of the two models used and at present are leading to international collaboration for the next stage of in vivo testing which may involve a porcine model.

Acknowledgements

I would like to thank the following people for their help and support in completing this MD.

Simon Eaton for being my office buddy, supervisor, friend and great support through my MD and at a difficult time.

Paolo DeCoppi for the amazing opportunity he gave me through this MD, working in his lab and through our clinical work at GOSH.

Federico Scottoni my operating partner and friend for his support and working through the frustration of our animal experiments together.

Luca Urbani, Carlotta Camilli, Ellie Phylactopoulos, Clare Crowley and the other amazing cell scientists in the lab for helping me learn how to do 'proper' research.

TOFS patient support group for their support and all the patients involved in the studies.

Table of Contents

Abstract	2
Impact Statement.....	3
Acknowledgements.....	5
Table of Contents.....	6
Index of figures and tables	8
Abbreviations.....	11
Chapter 1 Introduction	12
Classification.....	12
Surgery for OA	13
Caustic injury.....	13
Oesophageal replacement.....	14
Gastric Transposition	14
Tissue Engineering	17
The Oesophagus	19
Principles of Tissue Engineering.....	20
Cells.....	21
Scaffolds	24
Work to Date	28
Chapter 2 Aims.....	30
Chapter 3 EAT 1. A patient led, international study of long-term outcomes of oesophageal atresia.....	31
Background.....	31
Methods.....	32
Results.....	35
Discussion.....	43
Chapter 4 Long Term Outcomes in Adulthood of Gastric Transposition for oesophageal atresia.....	50
Introduction.....	50
Methods.....	52
Results.....	54
Discussion.....	63
Conclusions.....	70
Chapter 5 Rat Model for Oesophageal Implantation	71

Introduction.....	71
Method	72
Phase 1: Cadaveric dissection	72
Phase 2: Orthotopic circumferential implantation	72
Phase 3: Gastrostomy	75
Phase 4: Two-stage circumferential implantation	78
Phase 5: Cervical Patch implantation – feasibility.....	79
Phase 6: Influence of recellularisation of scaffold on patch integration	81
Discussion.....	89
Conclusions.....	92
Chapter 6 Rabbit Model for Oesophageal Implantation	93
Introduction.....	93
Aims	94
Methods.....	94
Phase 1 – Pilot Study.....	96
Phase 2 – Main study	99
Phase 3 - Two stage model.....	109
Mechanical Testing	112
Mechanical testing was performed alongside the in vivo experiments to formally assess the physical properties of the scaffolds. Figure 6.13 shows there was no significant difference between fresh and decellularised scaffolds in terms of stiffness, strength and strain.	112
This suggests the tissue maintains its mechanical properties through the specific DET protocol used for decellularisation and makes it mechanically equivalent to fresh tissue for surgical implantation.	112
Discussion.....	113
Conclusions.....	118
Chapter 7 Discussion and Conclusions.....	120
Chapter 8 Publications and Presentations	125
Chapter 9 References	127

Index of figures and tables

Figure 1.1 Gross classification of OA.....	12
Figure 1.2 Operative detail of gastric transposition.....	15
Figure 1.3 Experimental Plan.....	18
Figure 1.4 Anatomy of the oesophagus. H&E staining of fresh rat oesophagus.	20
Figure 1.5 Principles of tissue engineering.....	21
Figure 3.1 Respondents by country	35
Figure 3.2 A) Height and weight by age, B) BMI	36
Figure 3.3 Number of dilatations by age	37
Figure 3.4 Frequency of food bolus obstruction by age	38
Figure 3.5 Frequency of respiratory problems by age.....	39
Figure 3.6 Frequency of chest infection by age	39
Figure 3.7 Current care provision by age.. ..	40
Figure 3.8 Frequency of Quality of life problems.	41
Figure 3.9 Effect of OA on education or work	42
Figure 4.1 Recruitment flow chart.....	54
Figure 4.2 Frequency of gastrointestinal and respiratory symptoms.....	59
Figure 4.3 Gastrointestinal symptom rating scale total score after gastric transposition (GT) versus primary repair (PR).	60
Figure 4.4 GSRS Sub Scale Scores for indigestion, constipation, reflux and constipation by group (gastric transposition GT versus primary repair PR).	61
Figure 4.5 <i>Gastro intestinal quality of life index by group</i>	62
Figure 5.1 Rat cervical anatomy.	71
Figure 5.2 Rate cadaveric dissection.....	72
Figure 5.3 Macroscopic appearance of rat oesophagi freshly harvested and post decellularisation.....	73
Figure 5.4 Diagram of rat gastrostomy system.....	76
Figure 5.5 Cervical Oesophageal Patch implantation.....	80
Figure 5.6 Bioreactor set up for culture of decellularised oesophagus injection seeded with hMAB and mFB.	84
Figure 5.7 Operative plan for Phase 6.....	85
Figure 5.8 Phase 6 - Outcomes of seeded patch implantation	87
Figure 5.9 <i>4X H&E slide of animal 6.1</i>	87
Figure 6.1 Macroscopic images of decellularisation of porcine / piglet oesophagi using DET treatment.	95
Figure 6.2 Operative stages of oesophageal implantation.....	97
Figure 6.3 Rabbit tunneled gastrostomy.....	100
Figure 6.4 SX-Ella Bioabsorbable stent.	101
Figure 6.5 Vascularising abdominal wall flap.....	103
Figure 6.6 Tube damage as a result of attempts to unblock gastrostomy.	106
Figure 6.7 Fur bolus obstruction in autopsy specimens.	106
Figure 6.8 Micro CT of en bloc resection of oesophagus and trachea	107

Figure 6.9 Post operative survival in pilot group and main study group	108
Figure 6.10 Histology of porcine scaffolds following implantation in cervical oesophagus of rabbits with vascularising flap	109
Figure 6.11 Two stage model.	110
Figure 6.12 Second stage and histological results	112
Figure 6.13 Biomechanical analysis of native and decellularised samples derived from proximal (circle) or distal (triangle) portions of the oesophagi.	113

Index of Tables

Table 3.1 Member Organisations of EAT	34
Table 4.1 Demographics, type of OA and associated abnormalities.....	57
Table 4.2 Morbidity and medication by group.....	58
Table 5.1 Phase 2 Results	75
Table 5.2 Phase 4 Outcomes of 2 stage implantations	80
Table 6.1 Results of Phase 1	100
Table 6.2 Results of Phase 2	106
Table 6.3 Outcomes of 2 stage model	112

Abbreviations

GT - Gastric Transposition

OA - oesophageal atresia

TOF - Tracheoesophageal atresia

EAT - Esophageal Atresia and
Tracheoesophageal Fistula

H&E - Hematoxylin and Eosin stain

BMI - Body Mass Index

GSRS - Gastrointestinal Symptom
Rating Scale

GIQLI - Gastro Intestinal Quality of
Life Index

hMAB - human Mesangioblasts

mFB - mouse Fibroblast

DET - Detergent Enzymatic Treatment

CI - Colonic Interposition

JI - Jejunal Interposition

LGOA - Long Gap Oesophageal Atresia

IC - Inner Circular Muscle

OL - Outer Longitudinal Muscle

TGF β - Transforming Growth Factor
beta

BMP4 - Bone morphogenic protein 4

eNCC - enteric Neural Crest Cells

ROEC - Rat Oesophageal Epithelial
Cells

SIS - Small Intestine Submucosa

SDC - Sodium Deoxy Cholate

QoL - Quality of Life

SDS - Standard Deviation Score

WHO - World Health Organisation

LoS - Length of Stay

IQR - Interquartile Range

HRQoL - Health Related Quality of Life

M - Molar

EDTA - Ethylenediaminetetraacetic
acid

bFGF - Basic Fibroblast Growth Factor

DMEM - Dulbecco's Modified Eagle
Medium

VEGF - Vascular Endothelial Growth
Factor

PBS - Phosphate Buffer Solution

PDS - Polydioxanone Suture

CT - Computer Tomography

ECM - Extra Cellular Matrix

PROMS - Patient Reported Outcome
Measures

Chapter 1 Introduction

Oesophageal atresia (OA) with or without tracheoesophageal fistula (TOF) occurs in 3000-5000 live births and survival of these patients has improved over the last 30 years (Tennant, Pearce et al. 2010). The aetiology of OA is unknown but it is thought to represent a failure of the normal division of the primitive foregut into the oesophagus and trachea which occurs at week 4-5 of gestation. This results in an 'atresia' or missing segment of oesophagus and a spectrum of different anatomical variations of the trachea. In clinical practice these different variations are seen in the different classifications of OA.

Classification

Oesophageal atresia can be classified according to the variations of anatomy seen with regards the presence of different configurations of TOF. Gross (Gross 1953) classified the different types of OA from A-E (Figure 1.1). The most common type of OA seen in 86% of cases is Gross type C and type A or isolated OA is seen in around 7% of cases (Spitz 2007). The remaining types B, D & E are rarer and only seen in 2%, 1% and 4% of cases respectively.

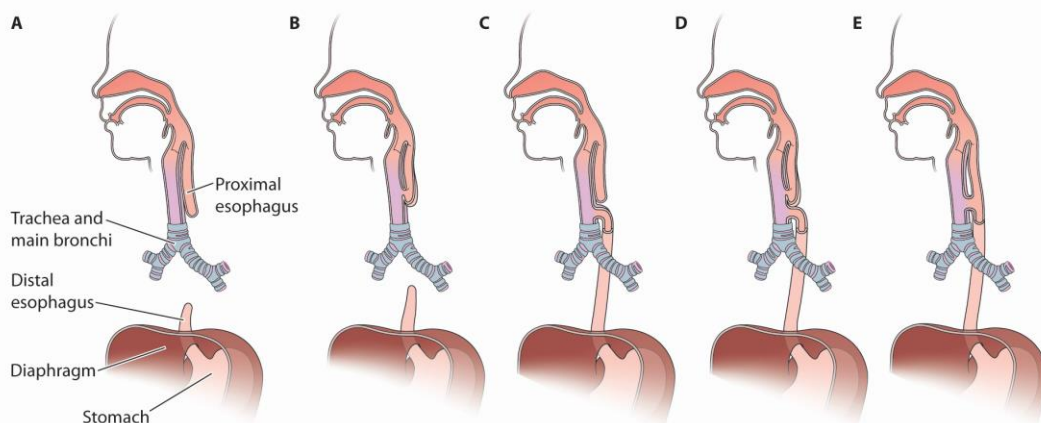


Figure 0.1 Gross classification of OA

Basics of Pediatric Anesthesia (Litman 2016). Type A - isolated OA, Type B - OA with a TOF to the upper oesophagus, Type C - OA with a TOF to the lower oesophagus, Type D - OA with a double TOF and Type E which is an isolated TOF.

Most frequently patients present at birth with an inability to swallow saliva and varying degrees of respiratory distress. Emergency surgery of those with a distal TOF (type C) is required to avoid aspiration in to the lungs or difficulties in ventilation and breathing.

Surgery for OA

Emergency surgery is required in those cases with a distal TOF and involves thoracotomy / thoracoscopy and ligation of the TOF and subsequent repair of the oesophagus which in most cases is achieved by primary anastomosis if the gap between upper and lower oesophagus allows. If not and the gap is considered to be to 'long' for a primary anastomosis any fistula is ligated and a gastrostomy is usually placed to allow for enteral feeding and a delayed attempt to anastomose the oesophagus or if this not possible some form of oesophageal replacement may be performed.

Those patients with Type A anatomy or isolated OA tend to have a 'longer gap' and given the lack of a TOF don't require urgent operation. Traditionally these patients have been treated with early gastrostomy insertion and then delayed (usually at about 3 months old) assessment of the 'gap' +/- delayed repair of the oesophagus. If this was not possible as the gap was too large again oesophageal replacement would be performed.

More recently a variety of techniques to try and induce oesophageal growth / lengthening and permit delayed anastomosis rather than replacement have been described (Foker, Kendall Krosch et al. 2009). These procedures involve application of tension sutures to the two ends of the oesophagus which are subsequently tightened in staged way to bring the ends of the oesophagus tighter. These techniques have yet to gain universal approval. Oesophageal replacement occasionally becomes the only option available for repair of complicated OA where previous surgery has failed – for example with recalcitrant stricturing.

Caustic injury

Another group of patients in whom oesophageal replacement may be considered is those with significant caustic injuries from caustic ingestion or button battery injuries. These patients can lose variable lengths of oesophagus from caustic

injuries and may require urgent life-saving treatment when they first present, especially if there is evidence of oesophageal perforation or fistulation into aorta or trachea. Delayed oesophageal reconstruction or replacement may then be required - especially in cases where long oesophageal resections have been required or in those with long recalcitrant strictures. (Uygun I, Bayram S. 2020).

Oesophageal replacement

The most frequently performed procedures for oesophageal replacement include interposition of either colon (CI) or jejunum (JI) between the proximal oesophagus and the stomach or gastric transposition (GT); bringing the stomach into the chest with direct anastomosis to the proximal oesophagus. The merits of each procedure are the subject of much discussion across the paediatric surgical literature.

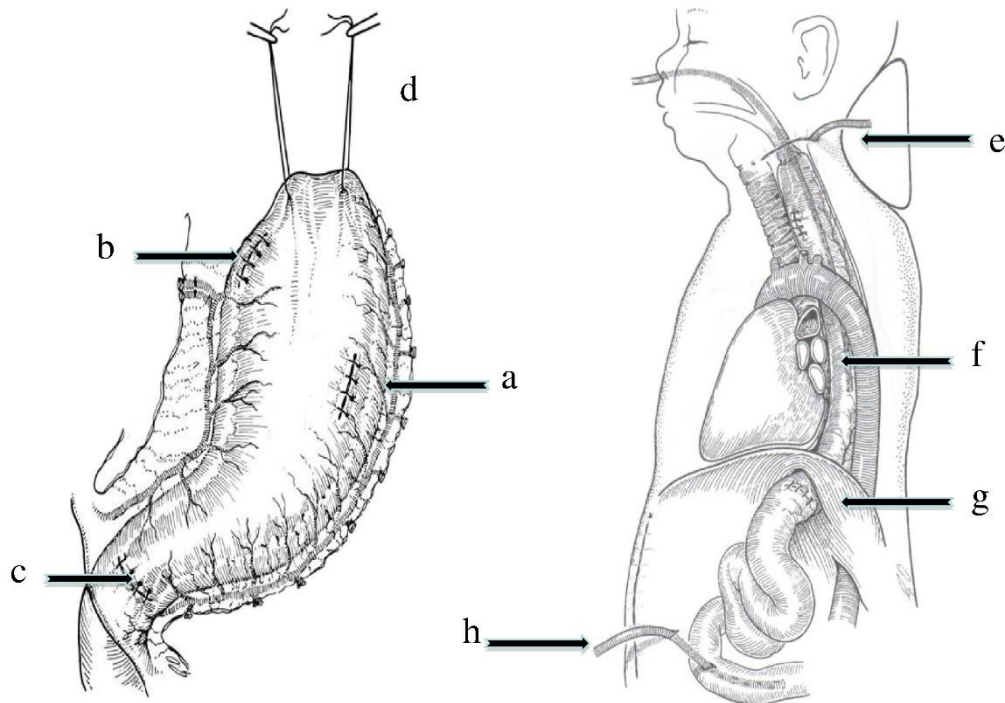
CI is probably the most commonly performed oesophageal replacement globally for OA and was first described in 1948 (Sandblom 1948). The benefit of an easily obtained graft of suitable length which occupies a relatively small space in the chest is balanced by the more precarious blood supply compared the stomach in GT and the presence of two anastomoses increasing the risk of leak and strictures. In the longer term there is concern about the graft becoming baggy and redundant a problem that can be difficult to manage (Loukogeorgakis and Pierro 2013).

JI again has the benefit of an easily obtainable suitably sized graft and its relative size compared the oesophagus is favourable. This is again balanced against the double anastomoses and relatively more precarious blood supply which can if necessary be augmented with microvascular anastomoses in the in the neck. Bax reported good results with the jejunal replacement (Bax and van der Zee 2007) but the concern about the precarious blood supply of the jejunum and risk of leaks have limited its popularity (Cauchi, Buick et al. 2007).

Gastric Transposition

Gastric transposition is the oesophageal replacement of choice in the UK and Europe (Zani, Eaton et al. 2014) and gained popularity through the work of Prof Spitz at Great Ormond Street Hospital after he changed to this technique; adopted from adult surgeons treating malignancy, following poor results when performing CI (Ahmed and Spitz 1986). The procedure involves mobilising the stomach on a

vascular pedicle, taking advantage of its excellent blood supply and performing a pyloroplasty to ensure no delay in gastric emptying. The gastro-oesophageal junction is then over sewn and the fundus of the mobilised stomach delivered through the posterior mediastinum to the neck where it can be anastomosed to the proximal oesophagus (Figure 1.2).



- | | |
|--|----------------------------------|
| a – closure of gastrostomy | e – esophago-gastric anastomosis |
| b – closure of gastro-oesophageal junction | f – transposed stomach |
| c – pyloroplasty / myotomy | g – pyloroplasty below hiatus |
| d – sutures of top of fundus of stomach | h – jejunal feeding tube |

Figure 0.2 Operative detail of gastric transposition.

Operative details of Gastric Transposition from Spitz, L – Oesophageal replacement overcoming the need (Spitz 2014)

The short term outcomes from GT are relatively well reported – the biggest series from Spitz (Spitz 2009), which did include some patients with caustic injuries rather than OA suggest an early post-operative complication rate of 3%, a leak rate of 12% and a stricture rate of 20%. A subset analysis of this cohort of patients with type A atresia suggest that complication rates are higher (58%) in this group. Other

authors report similar short term outcomes (Gupta, Sharma et al. 2007, Esteves, Silva et al. 2009) although the different inclusion criteria in each study and low numbers make comparison difficult. Longer term outcomes from GT are reported to be 'good' or 'excellent' in 90% of cases from Spitz's series although the specific description of what reflects good or excellent outcomes is not clear.

In summary the type of oesophageal replacement remains a point of much discussion and decision making around this is weakened by the limited evidence available which includes mainly individual case series and reviews or metaanalyses of these series. This is especially true for longer term outcomes as these patients become adults and leave paediatric care making follow up more challenging. It is essential however that we understand the long-term outcomes of these congenital conditions that until relatively recently were not routinely survivable conditions. Such data are important for several reasons including; predicting future medical needs of patients, improving transitional care into adult services and also to allow us to compare different techniques for repair of OA to improve care for the next generation of patients.

Tissue Engineering

The variety of oesophageal replacement strategies including gastric transposition (Spitz 2009) and colonic (Burgos et al. 2010) or jejunal interposition (Bax and van der Zee 2007) used around the world serves to demonstrate that currently there is no ideal autologous oesophageal replacement (Gallo et al. 2012, Loukogeorgakis and Pierro 2013). The literature to date and results from our long term follow up study of GT show these procedures carry significant long term morbidity. As a result, there has been increasing interest in finding different and alternative ways to replace the oesophagus. One such option is that of tissue engineering.

At present, clinical application of tissue engineering of whole organs is limited to those organs with less complex function such as the trachea (Elliott, De Coppi et al. 2012). Even with the trachea, only limited numbers of successful implantations are reported, and clinical application is limited to compassionate use where no other alternatives are available. Where more functional grafts are required, such as the need for peristalsis in an engineered oesophagus, the challenge is to not only ensure engraftment and differentiation of cells but for those cells to allow co-ordinated function.

The potential advantage lies in the ability to deliver a complete 'off the shelf' oesophageal scaffold with which to replace the missing native oesophagus which could be seeded and therefore re-populated with the necessary cells to provide a functional graft. The use of decellularised or synthetic scaffolds with autologous cells removes the risk of rejection of the implanted oesophagus as seen with allogenic whole organ transplantation.

The proposed experimental and clinical plan for the use of tissue engineering in LGOA is summarised in Figure 1.3. The process is designed to integrate into the existing standard course for patients with LGOA making it an easily clinically applicable treatment.

Following diagnosis of LGOA, which is usually early after birth, patients would undergo insertion of a gastrostomy. At this point the opportunity would be taken to take a skeletal muscle biopsy from the anterior abdominal wall and an oesophageal epithelial biopsy from the upper blind ending oesophageal pouch. This would facilitate autologous cell isolation, expansion and differentiation during a roughly 3-month period (the usual duration patients are given before assessing the oesophageal ‘gap’) during which the patient would have nutrition maximised. Alongside this, custom sized decellularised porcine scaffolds would be prepared and seeded with the autologous cells and cultured in preparation for implantation.

Assessments of the ‘gap’ during this period would give an indication of the need for oesophageal replacement and then at 3 months if the gap was too wide for anastomosis, the prepared decellularised, seeded and cultured scaffold could be implanted. Implantation would involve right thoracotomy and proximal and distal anastomoses to the native oesophagus with the addition of an omental vascularising flap.

Following implantation, the patient could continue with gastrostomy feeding in the short term whilst the implanted scaffold heals before eventually establishing oral feeding.

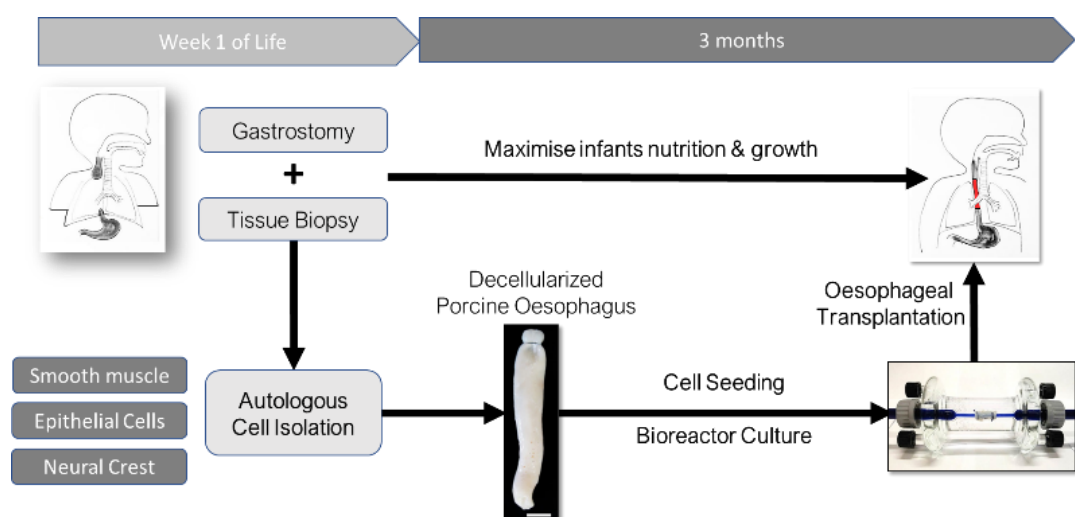


Figure 0.3 Experimental Plan.

The Oesophagus

When considering a tissue or organ for tissue engineering it is important to first understand the normal structure and function of that tissue.

The human oesophagus is a complex muscular tube made of 4 layers which connects the pharynx to the stomach. These layers consist of:

1. Mucosa - containing
 - a. non keratinised squamous epithelium with basement membrane
 - b. lamina propria
 - c. muscularis mucosa
2. Sub mucosa - dense connective tissue containing mucus secreting glands, meissners plexi and bloods vessels and lymphatics
3. Muscularis externa - 2 layers of muscular wall orientated differently with an inner circular layer and outer longitudinal layer. Proximally the muscle is a combination of skeletal and smooth muscle but distally it is just smooth muscle. Between these layers are further nerve plexuses (Aurebachs).
4. Adventitial layer

The complexity of the oesophageal structure is highlighted in the histological slide in Fig 1.4. It shows the intricate 3 dimensional structure of the oesophageal wall layers. There is alongside this the complex neural plexi of Meissner and Auerbach without which the complex neuromuscular function of the oesophagus would fail.

The various different parts of the oesophagus working together contribute to its function in carrying food from the pharynx to the stomach using rhythmic contractions known as peristalsis. These occurs normally in 2 waves to clear any food boluses and swallowing is initiated by the somatic nervous system with peristalsis continued by the autonomic nervous system demonstrating the complexity of oesophageal function needed in any tissue engineered oesophagus.

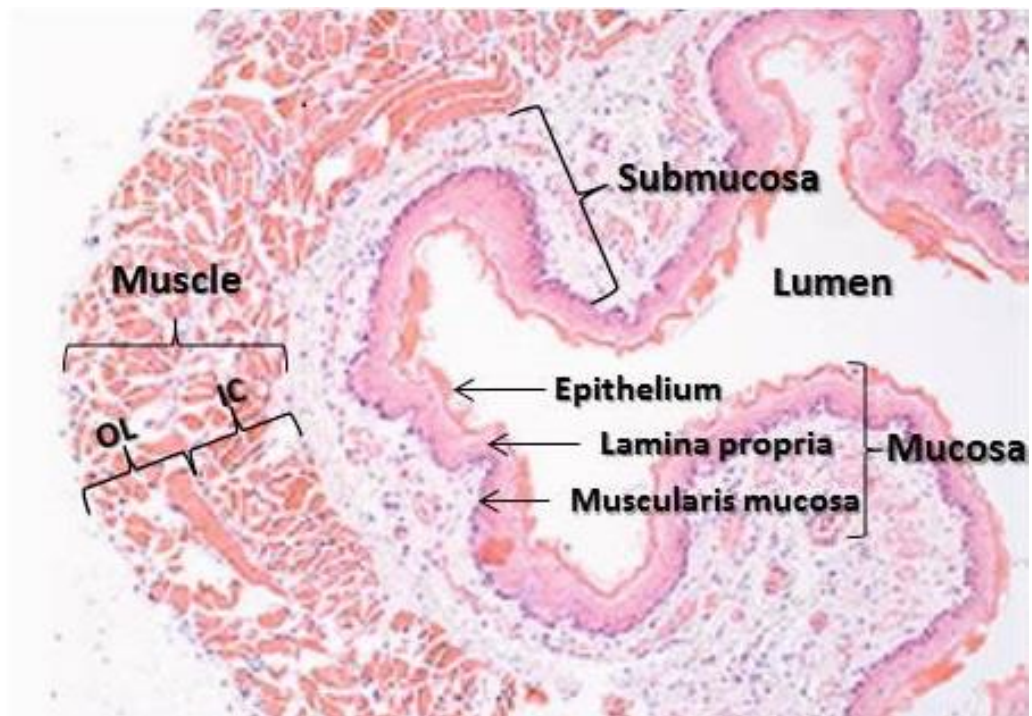


Figure 0.4 Anatomy of the oesophagus. H&E staining of fresh rat oesophagus.

3 principle layers of mucosa, sub mucosa and muscle layer are seen. Within the mucosa are 3 layers - epithelium, lamina propria and muscularis mucosa. The oesophageal outer muscle is made of 2 layer (IC) inner circular muscle and (OL) outer longitudinal muscle.

Principles of Tissue Engineering

The basic principles of tissue engineering are the use of 3 dimensional scaffolds, which can be natural or synthetic, and 'seeding' these with autologous suitable stem or precursor cells and growth factors with the aim of establishing cell engraftment and differentiation to create a functioning and implantable organ.

The ability to use autologous cells should result in non-immunogenic engineered organs negating the need for immunosuppression as in cadaveric organ transplants.

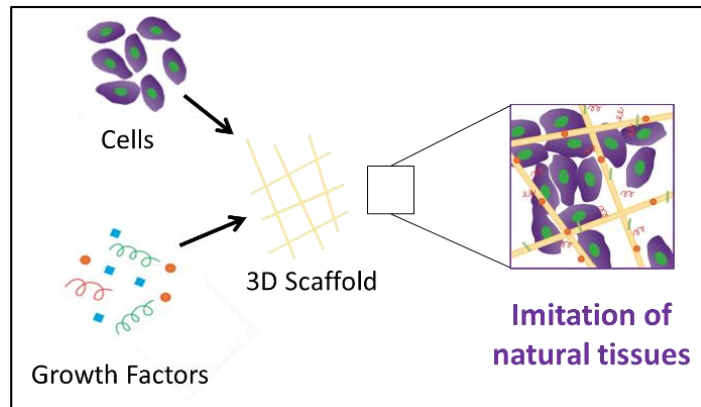


Figure 0.5 Principles of tissue engineering Adapted from Dvir T, Nature Nanotechnology (Dvir, Timko et al. 2011)

Cells

This distribution of different cell types normally seen obviously influences the cells chosen for tissue engineering of the oesophagus and the mechanisms of how these may be seeded onto the scaffold.

The principle cells of the oesophagus are

- Epithelial cells
- Muscle cells - smooth / skeletal
- Neural cells

Isolating and expanding these cells or their precursors in the form of pluripotent stem cells is a challenge and various different cells and methods have been employed to do this.

Epithelial Cells

Given mature epithelial cells have the ability to replicate and be expanded precursors are not needed, obtaining and isolating cells is more straightforward both experimentally and also eventually in a clinical setting.

Epithelial cells have been isolated using several different methods, these include; placing oesophageal specimens face down on culture plates to obtain 'explant' cultures from migration of cells (Zboralske FF, Karasek MA, 1984).

Saxena et al (2009) used overnight dispase incubation and mucosal separation followed by trypsin-EDTA incubation to isolate individual cells and have subsequently developed non enzymatic dissociation of the epithelial layer to improve cell counts and viability (Saxena, 2014) .

Whole mucosal sheets can also be separated using dispase and trypsin and single layer epithelial sheets then engineered. Maghsoudlou P et al (2014) compared 3 different methods and favoured isolating intact mucosal sheets (using dispase and trypsin) followed by two trypsin incubations yielding a single-cell suspension.

These cells can then be expanded to express different cytokeratins – markers of stratified and squamous epithelium as seen in the oesophagus.

Epithelial cell sheets in isolation have shown promising pre-clinical results in terms of managing mucosal defects and reducing stricture rates after endoscopic mucosal resection of early cancers (Takagi R et al, 2012). For whole organ engineering these cells have been seeded on the luminal side of decellularised scaffolds and after 2 weeks of culture show a multi-layered epithelium with each layer appearing to show markers consistent with the native oesophagus (Urbani, Camilli et al. 2018). Bioluminescence imaging also demonstrates the ability of these epithelial cells to migrate across the entire scaffold.

Muscle Cells

The oesophageal muscle is principally smooth with skeletal muscle more proximally. Many different sources of muscle cell sources have been explored for different regenerative applications including autologous smooth muscle cells, adipose derived stem cells and mesangioblasts. Whilst autologous mature oesophageal smooth muscle cells can be used in oesophageal tissue engineering their limited ability to expand, survive and engraft has limited their use (Wang et al, 2008).

Vascular smooth muscle cells have been shown to be able to be maintained for 56 days on collagen scaffolds, fully covering the scaffold in 4 weeks and Saxena et al (2014) propose their use as part of a multi layered 'hybrid construct' for

oesophageal tissue engineering and also highlight the importance of dynamic stress during culture to maximise smooth muscle differentiation and function.

Adipose derived stem cells offer an easily available source of muscle precursors and can be differentiated into smooth muscle cells using TGF β (transforming growth factor) and BMP4 (bone morphogenetic protein 4) and have been used in tissue engineered bladder and blood vessel walls. Wang et al (2008) demonstrated adipose derived stem cell use in oesophageal tissue engineering versus aortic smooth muscle cells and found they could be successfully differentiated, attached and migrated in an oesophageal acellular matrix model. The ease of accessibility make these an attractive option.

Human mesangioblasts (hMAB) are pericytes (multifunctional mural cells of the microcirculation) and have been successfully isolated from skeletal muscle and subsequently expanded *in vivo*. They have the ability to differentiate into smooth muscle under the influence of TGF β (Dellavalle et al 2007, Urbani et al 2018) – essential for the construction of tissue engineered oesophagus but also have the ability to form skeletal muscle and have demonstrated encouraging results in the field of regenerative medicine for muscular dystrophy (Sun et al 2020).

Our group have already demonstrated that co-seeding with fibroblasts also improved the distribution of engrafted cells mesangioblasts in the muscle layer of the decellularised scaffold (Urbani, Camilli et al. 2018).

Neural Cells

Neural cells are also an essential part of the functional oesophagus and are organised into myenteric and sub mucosal plexi. Neural regenerative medicine has many potential therapeutic applications including gastrointestinal neuropathies and also playing a role in other tissue engineered organ development.

The myenteric plexus controls motility and peristalsis and include neuronal and glial cells and alongside these sit the interstitial cells of Cajal which are thought to act as a pacemaker and be the link to the enteric nervous system.

Again there are several different cell types that have been identified as potential sources of cells for neural cell regeneration including skin-derived precursors and those from central nervous system.

Enteric neural crest cells are one such source. Given these cells are only found in the original population of migratory neural crest cells it was originally thought that they could only be harvested from foetal or post natal sources but more recently they have been derived from human intestinal biopsy specimens (Rauch et al, 2006 and Metzger et al 2009). Embryological murine neural crest cells have been isolated and differentiated into both neurons and glia and subsequently can differentiate, proliferate, migrate and retain some when implanted into mouse gut during work focusing on treatment for aganglionosis (Nishikawa et al 2015 and Cooper 2016).

Scaffolds

Alongside cell choice, scaffold material and design are also key for successful tissue engineering.

There is much discussion across all tissue engineering literature about scaffold choice and this principally includes synthetic versus naturally derived scaffolds and some hybrid models.

Factors affecting suitability of a scaffold for use in tissue engineering include scaffold morphology, geometry, thickness and porosity. Alongside this the mechanical and handling properties of a scaffold are important, including the ability to withstand operative implantation and suture retention.

Synthetic Scaffolds

Early attempts at oesophageal circumferential reconstructions were purely synthetic scaffolds without cells and included a variety of different materials

including collagen sponge with silicone tube stents (Natsume T et al 1993, Takimoto et al 1994, 1998), rubber and polyester constructs (Fukushima M et al 1983) and other polymers including polyglactin and polyvinylidene fluoride (Lynen Jansen P et al 2004). Results showed that whilst the expected complications of surgery eg anastomotic leak affected short term survival, the main issue that limited longer term outcomes was that of scaffold stenosis / stricture. In terms of cell regeneration these purely synthetic scaffolds have shown minimal muscle regeneration and limited epithelisation (Saxena et al 2009).

The ability of scaffolds to be successfully 'seeded' with suitable cells is important when trying to develop a functional engineered organ. Synthetic scaffolds have been seeded with some success; Miki et al (1999) seeded polyglycolic acid mesh and collagen scaffolds with human epithelial cells and fibroblasts and achieved epithelialisation when placed in an in vivo heterotopic muscle flaps in athymic rats.

Nakase Y et al report similar good outcomes in a polyglycolic acid felt scaffold seeded with keratinocytes and fibroblasts and implanted in the thoracic oesophagus of dogs with seemingly excellent survival up to 140 days.

However the lack of ability of synthetic scaffolds to 'grow' with the patient may limit their clinical use in the paediatric population.

Natural Scaffolds

Natural scaffolds of decellularised tissue are the alternative to synthetic materials. Whilst these scaffolds are not as easily available as synthetic scaffolds they offer certain advantages. Natural scaffolds have to varying degrees some maintenance of extracellular matrix which in turn gives a better niche for cell engraftment and repopulation and is pleiotropic in nature (Hynes 2009). The decellularisation processes used to create natural scaffolds has been shown to render the graft non-antigenic i.e. results in a graft that does not induce a host antigenic response, negating the need for long term immunosuppression compared to allogenic transplantation (Totonelli, Maghsoudlou et al 2013, Urbani, Camilli et al 2018). It is also expected that natural scaffolds, once repopulated should have the ability to

grow with patients - something important when considering application to paediatric conditions such as OA.

Several different natural scaffolds have been described for use in oesophageal tissue engineering and can be broadly categorised into tissue obtained from other locations versus decellularised whole oesophageal scaffolds.

Those scaffolds created from different organs or tissues take advantage of more widely available tissue sources such as small intestine sub mucosa (SIS) - and are often commercially available making sourcing material more straightforward.

Early studies used SIS scaffolds without seeding (Lopes et al 2006, Doede et al 2009) in a variety of different models with mixed results. More recent studies report seeded SIS scaffolds with different types of cells including autologous skeletal myoblasts (Pogosyan et al 2015) and bone marrow mesenchymal stem cells (MSC) (Tan et al 2013) achieving encouraging results. Heterogeneity of studies in terms of scaffolds, cells and methodology used make comparison very difficult.

Whilst decellularised tissues from other locations are easily available and have the benefits of extra cellular matrix preservation the use of decellularised whole organs should offer the best maintenance of the specific chemical and structural signals for appropriate cell attachment, differentiation, migration and survival. These benefits are balanced against the negative effects of the more aggressive techniques needed for decellularising whole organs.

Various different methods of decellularisation have been described which all mandate sufficient extraction of DNA to ensure graft will not be rejected.

Hybrid scaffolds have also been suggested combining synthetic and decellularised materials in attempts to gain the benefits of both scaffold types. Saxena et al (2014) describes a hybrid model allowing each layer of the oesophageal construct to be made in a cell specific way to maximise re-cellularisation of scaffolds. Some models using natural scaffolds have also used synthetic stents to maintain patency of the lumen and therefore have some 'hybrid element to them.

Bioreactors

The role of bioreactors in whole organ tissue engineering is to mimic the target organ's in vivo cell niche and environment in order to allow cells seeded onto a scaffold to engraft, differentiate and expand eventually yielding a functioning engineered organ.

One way this has been done is using heterotopic in vivo implantation ie a 'natural' bioreactor. This has been utilised for several different tissues such a bone for mandibular reconstruction (Watson E et al 2020) and trachea (Elliott et al, 2012) and also for oesophageal engineering.

Oesophageal engineering has used omentum as the in vivo bioreactor in both a heterotopic position (Saxena et al 2010, Urbani et al 2018) and in the orthotopic position in larger models. Poghosyan et al (2015) used an initial 2 week period of omental maturation of a seeded SIS scaffold before moving it into the orthotopic position with good results. This method has the added benefit of neo-vascularisation of the scaffold - one on of the other challenges in oesophageal engineering.

Whilst in vivo bioreactors provide a well oxygenated, temperature controlled and sterile environment it is at the expense of the ability to manipulate cell specific conditions eg supplying local cells specific growth factors or flow through a lumen. This method also does not allow for regular monitoring of scaffolds as in an in vitro setting.

In vitro bioreactors need to be specifically designed for the target organ, scaffolds used and cells to be seeded. This allows for close control of both mechanical and biochemical and metabolic (chemical) conditions. As a result bioreactor design has become increasingly complex - specifically in relation to 3D organ design and he challenges this brings in mimicking the nature in vivo conditions (Seldon and Fuller 2018).

For oesophageal tissue engineering - like that of many tubular engineered structures there has been a focus on dynamic culture in bioreactors and the positive effect that has on smooth muscle differentiation in both natural and synthetic scaffolds (Saxena 2014, Urbani et al 2018, Kim et al. 2019) . Therefore oesophageal bioreactors are designed to combine luminal flow - containing different media and growth factors with a reservoir of surrounding media.

Work to Date

Our group has demonstrated the ability to decellularize both porcine and rat oesophagi using a detergent enzymatic treatment (DET) involving cell lysis with water, detergent wash with sodium deoxycholate (SDC) followed by DNase enzyme fracture of nucleic material and finally washing with a buffered solution (Totonelli, Maghsoudlou et al. 2013, Urbani et al. 2018)

Subsequently it has been demonstrated that these decellularised rat scaffolds can successfully be seeded with 3 principal cell types using a 2 stage approach, with 7 days in vivo culture of the muscle layer in the omentum of immune incompetent mice, and subsequent application of epithelial cells and a further 7 day cultures in a bioreactor. Scaffolds showed smooth muscle maturation, neo-vascularisation and epithelial cell engraftment, i.e. an in vitro tissue engineered oesophageal graft is feasible (Urbani, Camilli et al. 2018).

With such progress from in vitro scaffold preparation attention has turned to in vivo implantation of such scaffolds to demonstrate clinical plausibility and move towards pre-clinical trials. Across the literature there have been several different in vivo models used to explore the options for orthotopic oesophageal implantations.

Looking across the existing literature other groups have used a variety of different models for oesophageal tissue engineering in vivo studies using decellularised scaffolds. These range from smaller animal models such as rats (Lopes et al. 2006, Uygun et al. 2013) to larger animals such as dogs (Badylak et al. 2000, Badylak et al. 2005) and pigs (Doede et al. 2009, Gaujoux et al. 2010, Poghosyan et al. 2015).

When designing models the following must be taken into account

1. How well does the model represent the clinical problem? – including
 - a. size
 - b. anatomy
 - c. physiology and reaction to surgery

2. How robust is the animal? - will it tolerate the surgical intervention and can this be performed with minimal animal suffering

Most of the previous studies have tried to minimise the morbidity of operating on the thoracic oesophagus utilising either the cervical oesophagus (Badylak Meurling et al. 2000, Badylak et al. 2005, Lopes, Cabrita et al. 2006, Lopes, Cabrita et al. 2006, Doede, et al. 2009, Wei, et al. 2009, Gaujoux et al. 2010, Poghosyan Sfeir et al. 2015) or intra-abdominal oesophagus (Lopes, Cabrita et al. 2006, Urita, Komuro et al. 2007). In larger animals the thoracic oesophagus has been replaced but this has been limited to porcine models (Marzaro et al. 2006).

The other main difference between studies in this area is the use of patches versus full circumferential oesophageal implantations. It appears that as expected, patch procedures are better tolerated in all animal models and demonstrate longer survival and better outcomes in terms of mucosal coverage (Lee, Milan et al. 2017). Those studies that attempted circumferential implantations the majority report problems with stricturing at some point post operatively and in many this was a pre terminal event. (Badylak , Meurling et al. 2000, Gaujoux, Le Balleur et al. 2010, Poghosyan, Sfeir et al. 2015)

Chapter 2 Aims

The aims of this thesis were:

1. Discover the long-term outcomes of patients treated for oesophageal atresia – including morbidity, symptoms and quality of life
2. Discover the long-term outcomes of patients following gastric transposition GT in childhood for complex OA compared to those undergoing primary repair.

Looking at future therapy

3. Design and develop suitable animal models to test tissue engineered oesophagi in vivo demonstrating that tissue engineering may offer a solution to minimising the problems and morbidity encountered after the current options for oesophageal replacement.

Chapter 3 EAT 1. A patient led, international study of long-term outcomes of oesophageal atresia.

Background

Outcomes in oesophageal atresia (OA) have improved in the last 50 years with survival now of more than 90% (Orford, Cass et al. 2004, Lopez, Keys et al. 2006, Burge, Shah et al. 2013) leading to an increasing population of long term survivors. Whilst our understanding of short term outcomes in infants with OA is well researched (McKinnon and Kosloske 1990, Castilloux, Noble et al. 2010, Allin, Knight et al. 2014, Roberts, Karpelowsky et al. 2016) longer term functional outcomes are more poorly understood with a limited research base (Sistonen, Malmberg et al. 2010, Sistonen, Koivusalo et al. 2010, Connor, Springford et al. 2015). There is increasing interest therefore in longer term outcome studies and the impact the results of such studies may have on current practice in OA management and the important area of transitional care as patients leave the care of the paediatric surgeon for the adult world. The current literature tend to be limited to small national (Sistonen, Koivusalo et al. 2010, Allin, Knight et al. 2014) and institutional datasets or metanalysis of such studies (Connor, Springford et al. 2015).

The Federation of Esophageal Atresia and Tracheo-Esophageal Fistula support groups (EAT) is an international federation of patient support groups, led by patients and parents aiming to share the international knowledge and experience of OA, promote awareness of the condition across the world and support worldwide research and collation of information concerning the treatment and care of people born with esophageal atresia. EAT therefore have a keen interest in the short- and long-term outcomes of OA and have first-hand experience of the difficulties faced by many patients and carers at all times in their journey from diagnosis through transition and on into adult care.

The aim was therefore to conduct a patient and carer designed and led study to assess short- and long-term outcomes of OA in a large international cohort of patients with OA.

Methods

This study was conceptualised and designed by EAT board with support from a paediatric surgeon (MvD). It was designed to be a patient / carer focussed study looking at outcomes of specific interest to those groups. The questionnaire was therefore designed to assess the following keys areas of interest:

1. Demographics and types of OA – ie OA with or without fistula, long gap OA, fistula alone
2. Operative details
3. Current symptomatology
4. Patient / carer satisfaction
5. Quality of life (QoL)

A questionnaire was designed and piloted within the EAT board. It was then prepared in multiple languages (English, Dutch, German, French and Italian) and put in an electronic format using SurveyMonkey®. Invitations to participate were sent electronically to all members of 7 different European patient support groups (table 3.1). This included patients and carers in 24 different countries.

Organisation		Country
AFAO	Association Francaise de l'Atresie de l'Oesophage	France
ABeFAO	Belgium Association Belge Francophone de l'Atrésie de l'Oesophage	Belgium
FATE	Famiglie con ATresia dell'Esofago	Italy
KEKS	Kinder und Erwachsene mit kranker Speiseröhre	Germany, Austria, Switzerland
OARA	Oesophageal Atresia Research Association	Switzerland
OA-Switzerland	OA-Switzerland	
TOFS	Tracheo-Oesophageal Fistula Support	United Kingdom
TROAD	Türkiye Özofagus Atrezisi Çocuk ve Aile Destek Derneği	Turkey
VOKS	Vereniging voor Ouderen en Kinderen met een Slokdarmafluiting	Netherlands

Table 3.1 Member organisations of EAT.

Where possible patients completed the questionnaire otherwise this was performed by carers. Completed questionnaire were collected centrally, collated and analysed anonymously.

Initial data was presented by EAT's Chairman at British Association of Paediatric Surgeons Congress (Cardiff, 2015). Following this the organisation approached UCL Institute of Child Health for assistance in data analysis and interpretation.

Formal ethics approval was not initially sought as this was a patient group led study. Retrospective approval was obtained for data analysis from ICH / GOSH Research & Development office at (project number 16DS21).

Initial data was cleaned and responses excluded if duplicate or date of birth was not included. Responses with missing or duplicate data for individual questions were included for those questions answered and percentages calculated from only completed answers.

Patient height and weight were analysed using standard deviation scores (SDS) using LMS Growth Excel Plug In ver 2.69 and UK-WHO Growth Charts in respondents under 18 years old. Body mass index was calculated for those 18 years and over and compared to the WHO International Classification.

Data were compared by Fisher's exact test or Mann-Whitney, regarding $p=0.05$ as the cut-off for significance.

Results

Demographics

1100 responses were received via SurveyMonkey®. Following exclusions 928 responses (56% male and 44% female) were analysed with an age range of 1 month to 60 years of age. For ease of analysis patients were split into the following age groups, <5 years (42%), 5-10 years (26%), 11-17 years (16%) and 18 years and over (16%).

Responses were received from 25 different countries, the most common of which are seen in Figure 3.1. Smaller numbers of responses were also received from Canada, USA, Ireland, South Africa, New Zealand, Spain, Guardeloupe, Tunisia, Sweden, Malta, Lithuania, Israel, Hungary, Hong Kong, Greece and Denmark in decreasing order of number of responses. 18% of responses were completed by patients and 82% by a parent or carer.

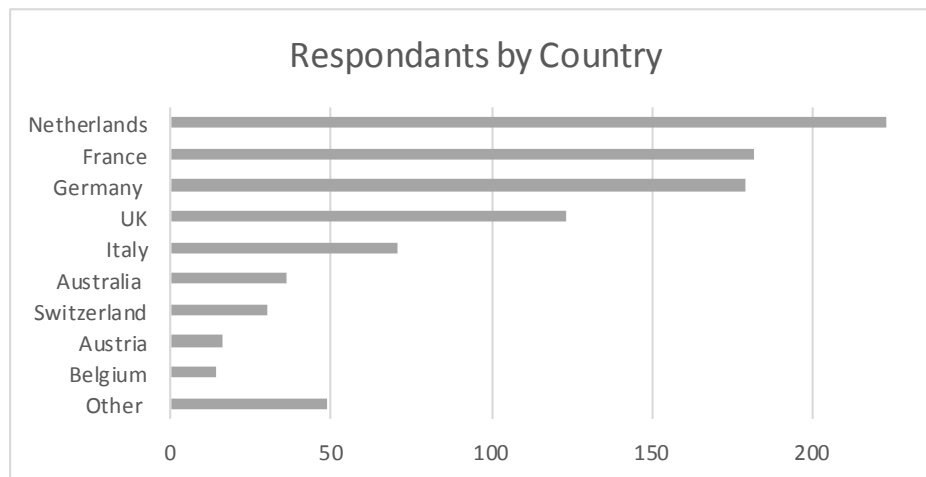


Figure 3.1 Respondents by country

Height and weight assessed by SDS for respondents under 18 years showed median scores of -0.41 (IQR -1.4 to +0.67) for height and -0.63 (IQR -1.6 to 0.17) for weight. (Figure 3.2 A)

BMI in respondents 18 years and over is shown in Figure 3.2B. 2% were obese, 15% were overweight, 62% were normal and 21% were underweight. The mean BMI was 21.5.

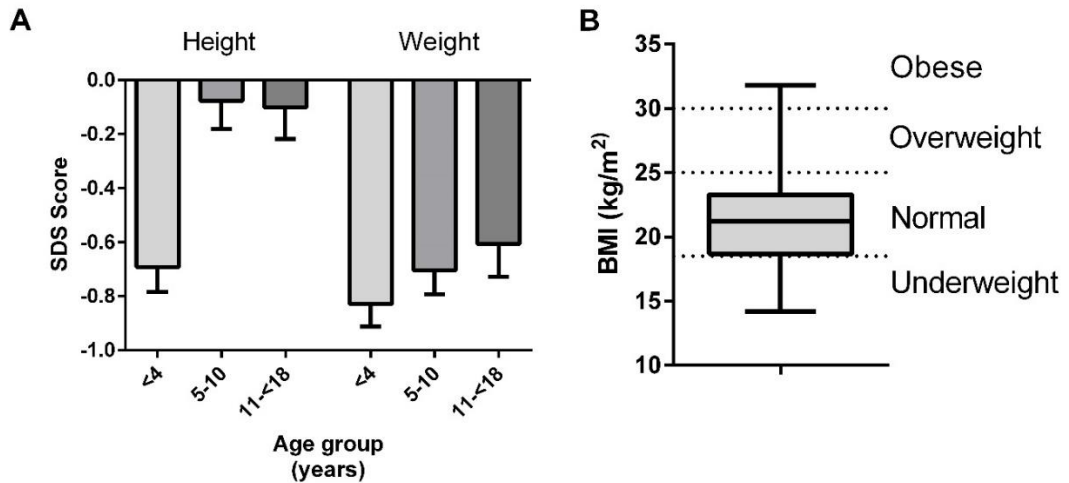


Figure 3.2 A) Height and weight by age, B) BMI

OA with TOF was the most common defect reported in 80% of cases, 19 % were pure OA and 1% an H type fistula. Participants reported their defect as ‘long gap’ either as supplementary to reporting the anatomy of their defect or as an isolated diagnosis in 18% of cases. Similar distribution of type of defect was seen in all age groups although there was a significantly higher proportion of pure OA and long gap participants in the adult age group with 13% of cases being pure OA in participants under 18 versus 23% in the adult cohort ($p=0.004$).

Surgical Care

Median length of initial hospital stay was 6 weeks (range 1 to 174 weeks). For adult respondents the median length of stay (LoS) was 8 weeks. When compared by diagnosis those with OA/TOF had a median LoS of 6 weeks versus 8 weeks for those with pure OA. Long gap cases reported median LoS was 18 weeks versus 5 weeks for standard gap OA.

53%, 46% and 52% of participants in the younger age groups respectively only required 1 operation to repair their defect. Whilst in the 18 year and above group only 36% were repaired with a single operation and 45% needed 2-5 procedures.

The proportion of patients requiring dilatation following repair is summarised in Figure 3.3. 49% of all respondents had oesophageal dilatation and the number of dilatations required was broadly similar across each age group. If dilatation was performed the median number was 4 dilatations and was the same for all age groups. The median number of reported dilatations in participants with long gap OA was 2 (IQR 0-10) and was significantly higher ($p=0.00054$) than in those with standard gap who reported a median of 0 dilatations (IQR 0 – 5). Those respondents reporting reflux symptoms had a significantly higher ($p=0.01$) median number of dilatations at 1 (IQR 0-5) than those without symptoms where the median number of dilatations was 0 (IQR 0-3).

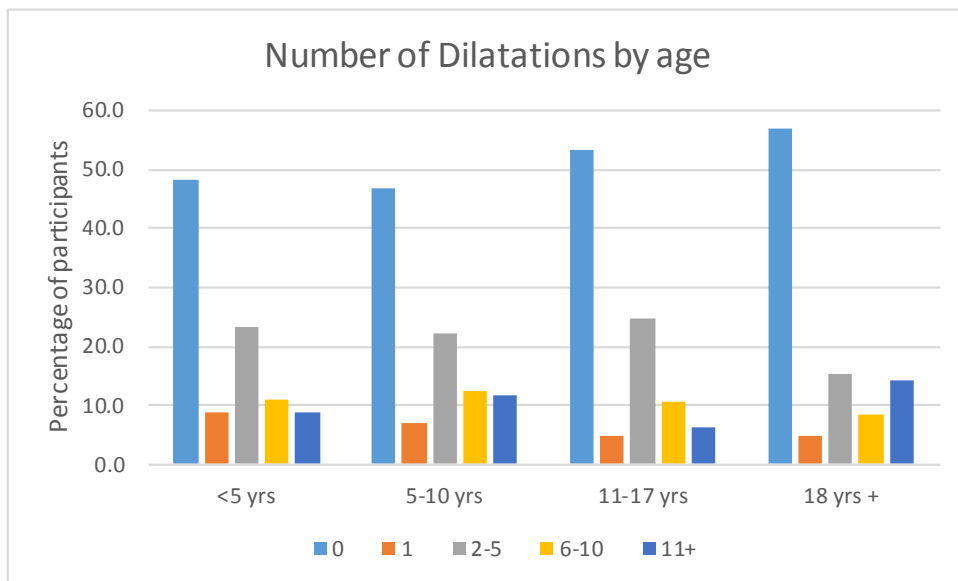


Figure 3.3 Number of dilatations by age

Symptomatology

Across all participants 65% reported that they could ‘eat anything’ ie having no restrictions on them type of food they eat. In those under 5 years this figure was only 50% and this was statistically less than those over 5 years old in which 75% reported they could ‘eat anything’ ($p<0.0005$). In those with long gap defects only 35% of those under 10 could eat without restriction.

Figure 3.4 shows how frequently participants in different age groups reported food getting stuck in the oesophagus. The patterns across age groups are broadly similar with 16% of participants often getting food stuck and only 22% reporting never having food stick. Over 50% of adult patients (18 years and above) report sometimes or often getting food stuck in the oesophagus.

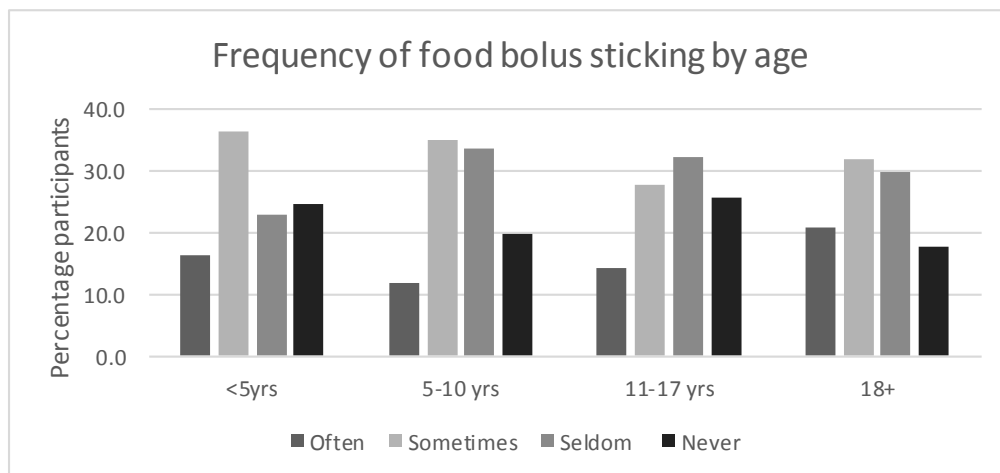


Figure 3.4 Frequency of food bolus obstruction by age

58% of respondents reported gastro oesophageal reflux symptoms and a similar incidence was seen in all age groups; 65% in <5 years, 53% in 5-10 years, 54% in 11-17 years and 60% in adults. When analysed by gap length 78% of those with long gap defects reported suffering from reflux symptoms versus 55% of respondents with standard gap anatomy, this difference was statically significant ($p < 0.005$).

The use of anti-reflux medication showed a decreasing trend with age. Reflux medication was reported being taken by 60% of under 5's but only 30% of adult participants despite a similar proportion in each age group reporting symptoms.

Respiratory problems were commonly reported by participants and show a decreasing trend with age (Figure 3.5). Patients with long gap atresia reported respiratory symptoms more regularly with 42% of under 5's and 24% of 5-10 year old reporting 'often' having symptoms compared to 16% and 7.6% respectively in standard gap patients.

There is a similar decreasing trend with age in the incidence of chest infections (Fig 3.6) with 30% of children under 5 years reporting having more than 3 chest infection per year but only 14% of adults reporting the same frequency of infections. Long gap patients did not report more frequently occurring chest infections than standard gap patients except in the under 5's (34% versus 28%). Regular antibiotic usage has also shown a trend similar decreasing trend in the use of with 16.5% of 0 – 10 year olds regularly needing antibiotics falling to 9% and 5% in the older age groups respectively.

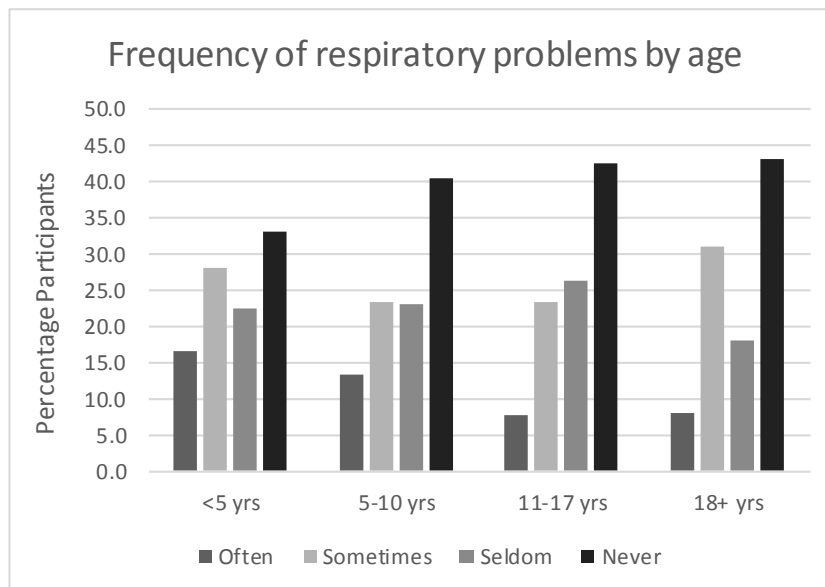


Figure 3.5 Frequency of respiratory problems by age

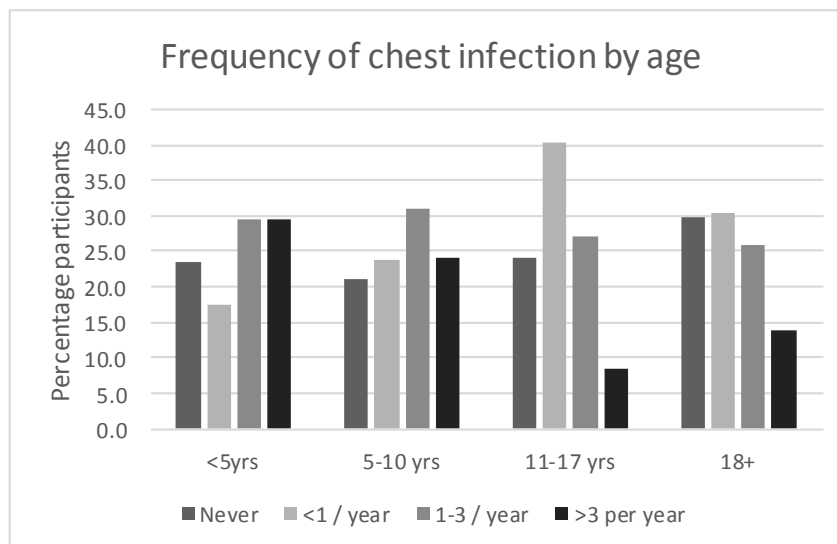


Figure 3.6 Frequency of chest infection by age

Current care provision is demonstrated in Figure 3.7. 22% of children under 5 are not under the care of a paediatric surgeon and there is a decreasing trend of participants being looked after by paediatric surgeons with increasing age. There is also an increasing trend with age in those with no current care provider with 50% of adults not even being looked after by a general practitioner or equivalent primary care physician.

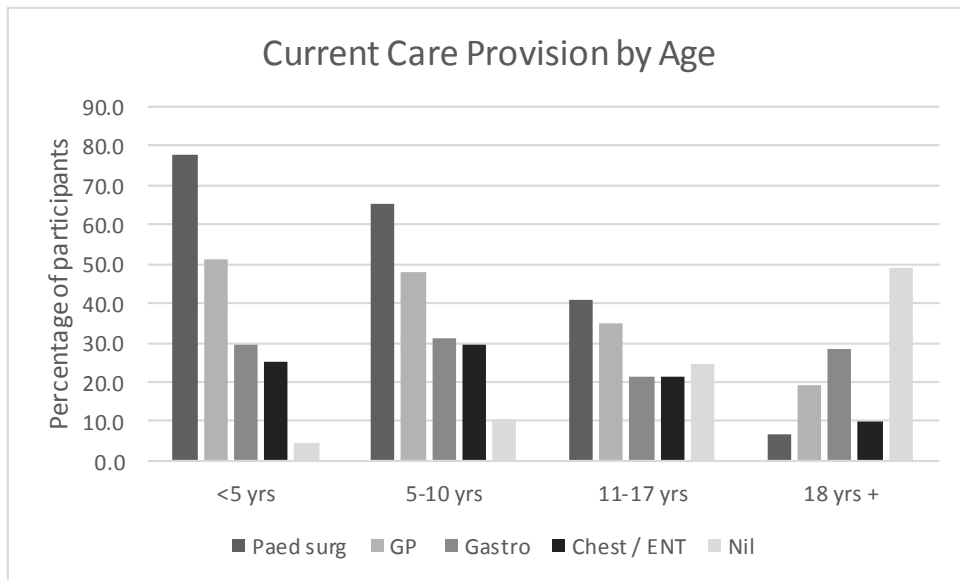


Figure 3.7 Current care provision by age. Current care provision by age. (Paed surg – paediatric surgeon; GP – general practitioner or family doctor; Gastro – gastroenterologist; Chest / ENT – respiratory physician or ear, nose and throat surgeon).

Quality of life

The graphs in Figure 3.8 show responses to the questions related to quality of life in the study. They demonstrate that whilst 20-25 % of respondents report that OA has had no effect on their own or their families QoL a similar proportion of patients suggested their QoL was significantly affected. Over 55% of respondents report ‘some’ or a ‘significant’ effect on their family’s QoL.

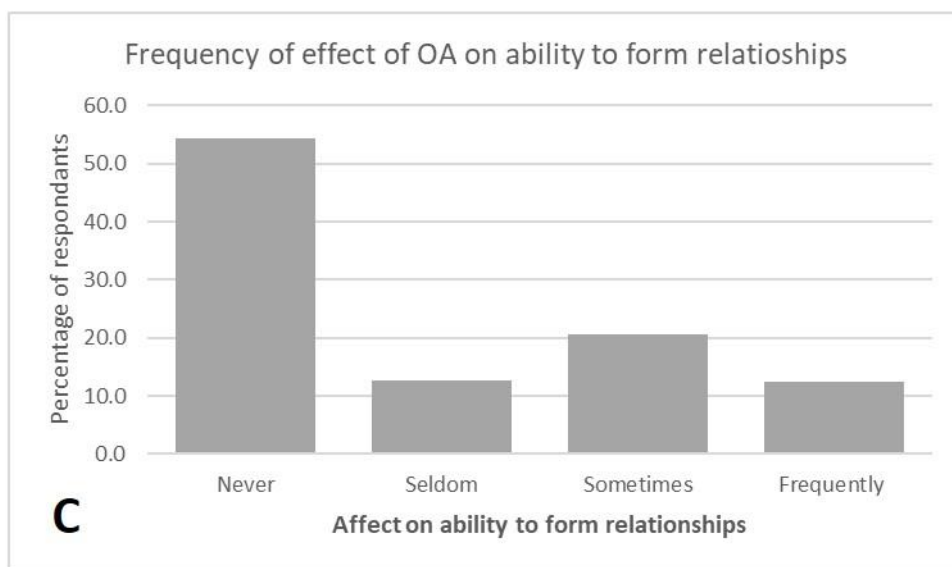
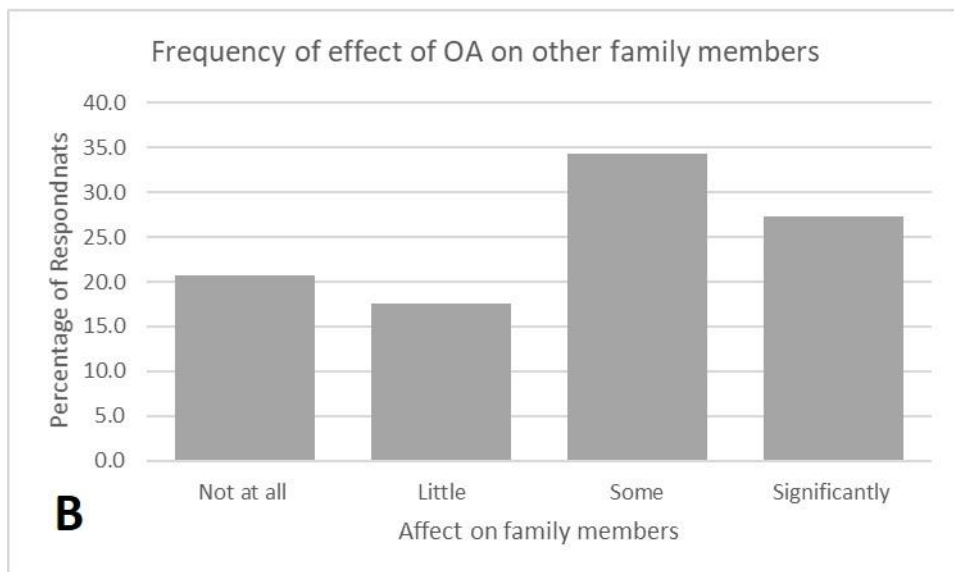
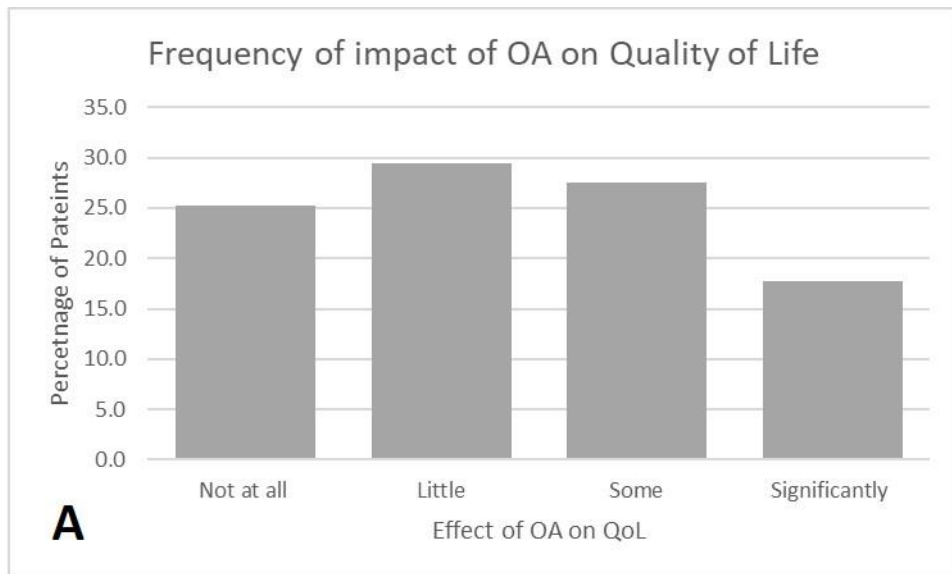


Figure 3.8 Frequency of Quality of life problems. A) Quality of life, B) Effect on family members, C) Effect on ability to form relationships

30-40% of respondents reported no effect of OA on education or work from ages 5 until adult hood. Those under 5 years reported a higher frequency of some or significant effect on education as may be expected when looking at the symptom data from this age group (Figure 3.9).

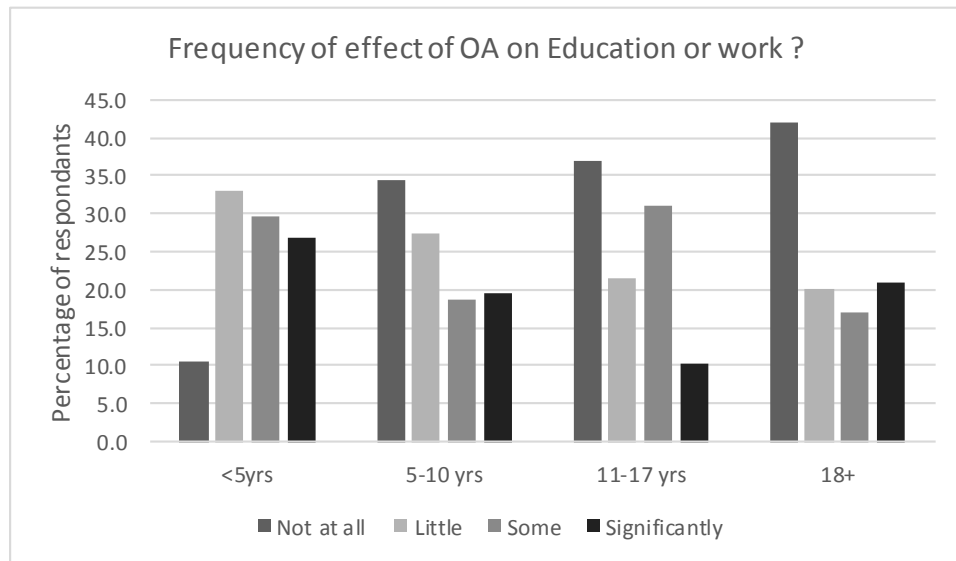


Figure 3.9 Effect of OA on education or work

Discussion

The EAT 1 survey offers unique, international patient directed short, medium and long term follow up data on one the largest cohorts of OA patients in the literature to date. It highlights the clinical long-term morbidity OA patients suffer from and how these may change with age. It also importantly also examines the often-ignored quality of life issues faced by this patient group. The large size of this study group makes it more representative of the wider international population of OA patients than most of the existing literature which is limited to smaller national (Sistonen, Malmberg et al. 2010, Allin, Knight et al. 2014) and institutional data series (Lopez, Keys et al. 2006, Okamoto, Takamizawa et al. 2009, Roberts, Karpelowsky et al. 2016) or metanalysis (Connor, Springford et al. 2015)

Demographics

Based on the frequency of each types of OA in our study the cohort is broadly representative of the wider population based on anatomy of original defect. 80% of participants had OA with TOF and 19% pure OA which are comparable to EUROCAT figures, the largest European disease registry specific to OA (Pedersen, Calzolari et al. 2012). The incidence of pure OA is slightly higher than described in the classification by Gross (Gross 1953) as is the incidence of long gap anatomy. The significantly higher incidence of pure and long gap OA in the adult group probably represents the demographics of adult patients accessing support groups ie those with more complex conditions and a similar pattern of recruitment is seen in the German support groups KEKS quality of life (QoL) study (Dingemann, Meyer et al. 2014).

The age range of participants studied again makes this study unique including infants up to the oldest subject who was 60 years at age of completion of the survey. To make results more comparable to other studies and to draw more specific conclusions results were stratified by age into infants <5 years, primary school aged children 5-10 years, secondary school children and finally adult patients. The decreasing number of patients seen with increasing age may be the result of several factors including the previous limited survival of babies in the early

years of OA surgery, the relatively new development of patient support groups – through which recruitment took place and also the perceived need of such support groups in older patients. The geographic spread of participants represents the principle patient support groups involved in the study and membership in each of those countries.

Anthropomorphic Data

The anthropomorphic data and SDS collected in this study is consistent with existing literature (Chetcuti and Phelan 1993, Little, Rescorla et al. 2003, Spoel, Meeussen et al. 2012) suggesting that as children, patients with OA tend toward being underweight and to a less extent shorter than the normal population. Spoel et al also reported SDS score but only until 24 months of age when SDS for height was -0.54 and for weight -0.78 similar to our scores -0.41 and -0.63 respectively. Interestingly we showed a significantly lower mean score for height in under 5's than older children. It may represent a sampling weakness as these were self-recorded and reported outcomes in an age group in which it may be difficult to get accurate height measurements. Chetcuti et al reported that there is 'catch up' growth as children become adolescents and then adults and the size of our adult cohort is well placed to agree with this finding as the median BMI is within the normal range at 21.5. There are still however 21% of adults with OA in our study who are classed as underweight by BMI and a much lower than average level of obesity (2%) in this patient population than in the normal European population (15-30%).

The operative management of OA has improved over the last 2 decades and this may explain the shorter length of stay seen in the younger participants. However the groups are not evenly matched for type of defect and gap length and the higher incidence of long gap and pure OA in the adult group may account for the increased median length of stay and number of operation required.

Symptoms

With increasing clinical and research interest in the long term follow up of OA patients our results of patient directed and reported outcomes relating to

symptomatology and quality of life in such a large patient cohort are important additions to the literature. Dysphagia and reflux are well reported in the short and long term after OA repair and we see a high reported incidence of food 'getting stuck' a surrogate patient reported outcome for dysphagia. Overall 47% of patients reported sometimes or often getting food stuck including just over 50 % in adult participants which agrees with Connor et al's (Connor, Springford et al. 2015) findings of 50% of patients reporting dysphagia in a detailed metanalysis. In the younger age groups Little et al (Little, Rescorla et al. 2003) grouped patients in the same age categories as our study and describe a similar incidence of dysphagia. Interestingly they report reflux symptoms decreasing from 48% in <5 year old to 25% in 5-10 year old and 31 % in 10 years and above. We found higher reported incidence of reflux and this did not decrease significantly with age with 60% of adults reporting symptoms. Connor et al reports a lower 40% (range 18-64%) of patients suffering from gastro-oesophageal reflux symptoms but recognises the variation in definition of GOR across studies analysed. We are also limited in our analysis by the lack of definition of our patient reported outcomes but our findings add to the increasing body of literature highlighting long term morbidity in adult OA patients. The limited use of reflux medication in our adult cohort (30%), despite the high reported incidence of symptoms was interesting and is similar to that reported by Schneider et al (Schneider, Michaud et al. 2016) who went on to endoscope a cohort of adult OA patients and concerningly also found 67% of patients had histological evidence of oesophagitis and 43% Barrett's oesophagus. Several other studies report an increased risk of Barrett's (Krug, Bergmeijer et al. 1999, Sistonen, Koivusalo et al. 2010, Schneider, Michaud et al. 2013) in OA and whilst a definitive increased risk of oesophageal cancer in OA patients has yet to be proven (Sistonen, Koivusalo et al. 2008, Connor, Springford et al. 2015) the frequency of reflux symptoms in this patient group and histological changes mean more attention needs to be paid to the consideration of surveillance endoscopy in the adult aged OA population.

Respiratory symptoms are the other main morbidity following OA repair. This is confirmed in our study with over a third of patients (38%) reporting sometimes or

often suffering from respiratory symptoms a figure which is maintained at 39% when looking at the adult patients in isolation. Respiratory infections however do appear to be less frequent in the older patients with nearly 30% of under 5 year olds having >3 chest infections per year a number that falls to 8% and 13% in the older age groups. Connors et al suggested a pooled prevalence of 24% for respiratory tract infections but with a range of 9.5 – 51%. It is difficult to accurately compare the data from our study and to calculate the prevalence but there is a similar message that whilst respiratory tract infections may decrease in frequency with age a third of patients with OA report ongoing respiratory symptoms through school years and into adult hood.

These ongoing gastroenteric and respiratory disorders in OA patients lead to the question of who provides care for this patient group. Whilst there is international variation in the way care is provided to these patients what is clear is that whilst only 5 – 10% of children under 10 years have no documented care provider which is of concern, this increases to 49% in the adults. The response to these findings may be to suggest that a large proportion of adult patients have no medical input because they are asymptomatic and don't 'need' regular medical input. Whilst this is maybe true that the majority of OA patients have good functional outcomes, the high incidence of reflux and respiratory symptoms seen in this and other studies may suggest more patients should have a regular care provider with experience in OA / TOF.

This ongoing need for medical input in adult life also highlights the issue of transitional care of patients from paediatric to adult services, a concern raised by many patient support groups over recent years (personal correspondence). As expected in our study there is a decrease with age in the number of patients looked after by paediatric surgeons. This may be a result of differences in practice across the countries in the study, where the longer term care of OA is led by gastroenterologists as opposed to surgeons or that if children are well they may be referred back to primary care. Adult patients appear to be discharged or transitioned to the gastroenterologist who provide the care to 28% of those over 18 years in our study. How transition is managed in the future is an important issue for

OA care and other chronic paediatric conditions, as the population of long term survivors continues to increase. International studies such as this alongside work from Australia(Chetcuti F 1993), Finland(Sistonen, Malmberg et al. 2010, Sistonen, Koivusalo et al. 2010) Holland (Deurloo, Ekkelkamp et al. 2003, Deurloo, Ekkelkamp et al. 2005) and more recently the USA (Gibreel, Zendejas et al. 2016) are key in highlighting the need for careful planning of patient centred transitional and adult care. Forward thinking centres are already looking at ways to improve this process with a German centres offering education sessions for OA patients coming up to transition (Dingemann, Szczepanski et al. 2016) and there is an increasing research effort examining what improves transition across all conditions (Campbell, Biggs et al. 2016).

Quality of life

Quality of life in OA patients is an outcome that had limited attention from surgeons in the past but is of increasing interest. Our figures of 17% of patients / parents reporting a 'significantly' affected QoL demonstrate more attention needs to be paid in this area – especially as 21% and 27% also report 'significant' effects on education or work and other family members respectively. QoL in OA has been reported as being 'comparable' with the normal population by the German support group (KEKS)(Dingemann, Meyer et al. 2014). They did however also find that health related quality of life (HRQoL) in adults is negatively affected by disease specific symptoms such as reflux and respiratory symptoms a result also seen in other QoL studies (Deurloo, Ekkelkamp et al. 2005, Peetsold, Heij et al. 2010). It is difficult to make direct comparisons between this and other QoL studies due to the lack of validated questions used in this study. However one of the studies strengths is that the QoL questions were designed by parents / patients therefore highlighting issue important to them; for example looking at the impact of OA on schooling and work with nearly 90% of parents of under 5 year olds reporting an effect on their child's education.

Limitations

Comparison of our results to that of the KEKS study is useful as we are comparing outcomes in similar populations ie patient support groups. This also highlights the inherent selection bias of using patients support groups to recruit participants as it may be hypothesised that support groups are made up of those who need more 'support' and have a higher severity of disease. The patient support group populations are self-selecting and therefore form very variable groups. There is a lack of standardisation of definitions such as 'long gap OA' which makes detailed sub group analysis difficult. Any further study will need to address this and would need to try and stratify patients better. The questionnaire used in this study was specifically patient designed and easy to understand and complete and whilst this maximised recruitment it did lead to data being limited in detail for example of comorbidities and specific surgical detail. Surgical technique and medical support will also have changed over the wide age range of patients in the study - again something that needs controlling for in any future study.

As a pilot study however its strengths lie in the numbers of participants recruited across over 20 countries and firmly establishing the scale and types of morbidity seen across all ages of the OA population.

Another important message from this work is that of collaboration, which has been the key to this project as the patient support groups of Europe all worked together towards a common goal. In the literature to date collaboration has been limited in OA research as centres published their own limited series. More recently larger national and international collaborations have led to more representative studies and clinicians and researchers can all learn from the example set by this project in how useful and important collaboration can be. The EAT study is testimony to the commitment and drive of the OA patient community and support groups to collaborate and produce clinically relevant and effective research in attempts to improve clinical care. Now that the EAT 1 study has given a broad baseline of the scale of gastro, respiratory and QoL morbidity seen in OA patients, a more detailed and focussed study of a smaller cohort of these patients is being designed - EAT 2.

EAT 2 will involve a patient led but clinician and researcher designed study to look at these outcomes in more details using validated scoring systems an helping

establish core outcome sets for OA so that results of this type of work can be more readily comparable.

Chapter 4 Long Term Outcomes in Adulthood of Gastric Transposition for oesophageal atresia.

Introduction

Oesophageal replacement may be required in cases of oesophageal atresia (OA) where a 'long gap' is present or following complicated primary surgery. Gastric transposition (GT) is one such method for replacing the oesophagus and was popularised in the paediatric population by Spitz (Spitz 1984) at our institution in the 1980s and has become the operation of choice in the UK and Europe (Zani, Eaton et al. 2014).

As with many of the congenital conditions we have good understanding of the short and medium-term outcomes in childhood following GT. Perioperative morbidity such as leak, reoperation and stricture rates are well reported and acceptable in comparison to other forms of oesophageal replacement (Spitz, Kiely et al. 2004, Tannuri, Maksoud-Filho et al. 2007, Gallo, Zwaveling et al. 2012, Loukogeorgakis and Pierro 2013). Longer term morbidity such as delayed gastric emptying, dumping syndrome and poor weight gain are also well reported and despite this most authors report good functional outcomes following GT in childhood (Hirschl, Yardeni et al. 2002, Spitz, Kiely et al. 2004, Loukogeorgakis and Pierro 2013, Angotti, Molinaro et al. 2016).

However as increasing numbers of patients who had GT for OA move into adulthood our knowledge of their truly long-term outcomes is poor. GT is used in adults principally as a conduit after oesophagectomy for cancer in a more elderly population. Morbidity such as reflux, dysphagia and dumping syndrome are reported but quality long term outcome data are limited making extrapolation of this limited data to the very different congenital OA population of limited value (Irina, Tsekrekos et al. 2017).

Whilst detailed follow-up into adulthood of uncomplicated OA has is being increasingly reported (Chetcuti, Myers et al. 1988, Deurloo, Ekkelkamp et al. 2005, Deurloo, Ekkelkamp et al. 2005, Connor, Springford et al. 2015), similar work for GT,

or other oesophageal replacement methods such as colonic or jejunal interposition, remains limited due to the rarity of oesophageal replacement, poor long term clinical follow up and inconsistent transition of care to adult services. Those few studies that do include adult outcomes of GT are limited to single outcomes such as quality of life (Dingemann, Meyer et al. 2014), or report outcomes of mixed cohorts of children plus small numbers of adults (Tannuri, Maksoud-Filho et al. 2007).

My aim was therefore to perform a comprehensive long term follow up study of adult patients who had been treated with GT for OA as children, including morbidity, symptoms, functional outcomes and quality of life. I also aimed to study an aged matched group of uncomplicated OA who underwent primary repair (PR) in order to have a reference point, other than the normal population to compare results with.

Methods

The study was given National Research Ethics Service approval (REC reference: 15/LO/1325). Existing hospital oesophageal atresia databases were used to identify consecutive patients who had undergone GT for OA and were over 18 years of age at the time of the study. Only UK based patients were included. A comparative age matched group of patients who had undergone primary repair (PR) of uncomplicated OA was also identified. These patients were aged matched by selecting patients from existing databases who had repair over the same time period as the GT cohort. More formal individual patient matching was considered but felt not possible due to the limited number of cases available and large numbers of co-morbidities in both groups which would make matching very difficult to control.

Telephone interviews were all conducted by myself and involved: confirmation of demographics and detail of type of OA and associated anomalies, full medical and surgical history – in childhood and adulthood, current symptoms and morbidity, and completion of questionnaires. Details of OA, operative history, associated anomalies and paediatric history were confirmed from available clinical notes and hospital databases.

The two validated questionnaires used were the gastrointestinal symptom rating scale (GSRS) and gastro intestinal quality of life index (GIQLI). GSRS is a tool validated for the assessment of disease specific gastrointestinal symptoms. It is made up of 15 questions, answered using a 7 point Likert scale (Svedlund, Sjodin et al. 1988). Questions can be grouped into sub-scales for abdominal pain, reflux, indigestion, constipation and diarrhoea. Total scores are calculated from the mean scores across each scale and the higher the score the more symptomatic the patient. The GSRS has been validated for use in English, in interview or written format and has been shown to be reliable and valid when assessing adults with upper gastrointestinal and reflux symptoms hence its selection for this study (Adams, Esser et al. 1998). Normal values have also been published in a European adult population (Dimenas, Carlsson et al. 1996). GIQLI is a 36-question health related quality of life score specifically designed for adult gastrointestinal disease

(Eypasch, Williams et al. 1995). Whilst designed and validated in Germany it was also translated and tested in English language. It has been used for many different types of upper gastro-intestinal conditions including benign disease such as following cholecystectomy and in malignancy, including assessment of patients with oesophageal cancer after gastric conduit reconstruction. It has also been used to assess medium and long term HRQoL in oesophageal atresia patients including those with complex disease requiring replacement surgery.

Statistical analysis was performed using GraphPad Prism® v7.03. Data are presented as median and IQR unless otherwise stated as most data did not follow a normal distribution.

Results

Recruitment

Over the time period 231 patients underwent GT in our centre, of which 117 had undergone GT for oesophageal atresia. Of these, 61 were international/private patients who we did not have ethical approval to contact. Fifty-six NHS patients are now adults over 18 years, of whom UK contact details could be traced for 44 who were sent postal invitations. Thirty-two of these were interviewed, representing 73% of those sent invitations, and 57% of the entire UK cohort. Of the 12 that declined there was a variety of reasons given for this including patients not feeling they still had any problems, unavailability and also failure to attend interviews. A recruitment flow chart for GT patients is shown in Figure 4.1. Thirty-two adults who had undergone

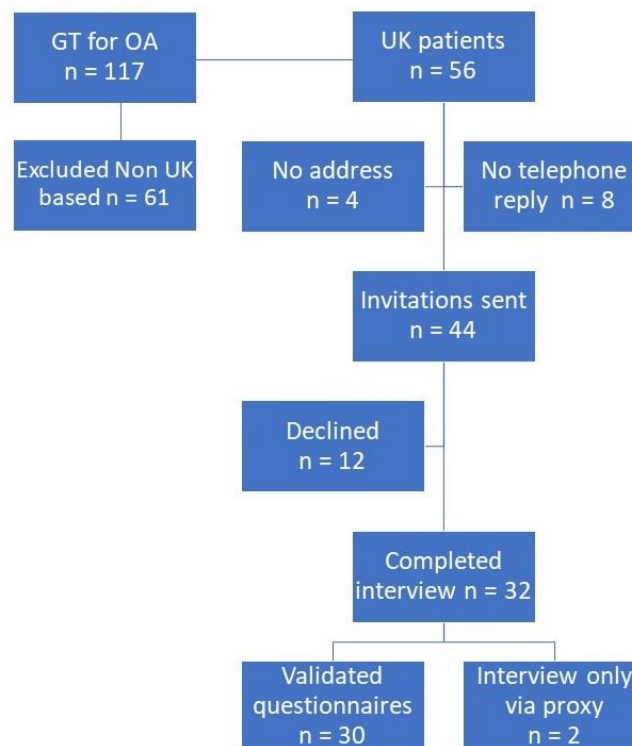


Figure 4.1 Recruitment flow chart.

PR were also recruited. Two individuals in each group suffering from learning and/or communication difficulties had interviews performed via a proxy or carer. These individuals could not complete the validated questionnaires, but the

interviews were included to minimise selection bias. Therefore, data from 32 GT and 32 PR interviews were analysed and 30 in each group for validated questionnaires. 61 overseas patients were not included in the study due to the practical difficulty and language limitation of contacting these patients and as such ethical approval was only sought for UK patients. Paediatric mortality in complete cohort of 117 was 5 cases (3.8%).

Demographics and patient characteristics

Demographics, type of OA and associated abnormalities are shown in Table 4.1. GT and PR participants had a similar age and gender distribution. The presence of any associated congenital abnormality was the same in each group, although renal anomalies were more frequent in GT. One PR and 2 GT participants had required renal transplants as a result of renal anomalies.

56% of GT patients had primary surgery – defined as the gastric transposition being performed as the first definitive repair of long gap OA, whereas secondary surgery was performed as rescue surgery following failed primary repair or in 2 patients following failed colonic interposition. 81% of both groups were employed (this included mothers at home caring for children independently) although more GT participants were employed on a part time basis.

	Gastric Transposition (GT) n = 32	Primary Repair (PR) n = 32	P value
Childhood Demographics			
Gender	50% male	56% male	0.79
Type of OA	Type A = 40%, Type C = 47%, Type B = 3%, Type D = 10%	Type A = 3%, Type C = 94%, Type D = 3%	
Associated abnormalities	21 (66%)	19 (60%)	0.7
Vertebral	5 (16%)	4 (13%)	
Anorectal	8 (25%)	7 (22%)	
Cardiac	9 (28%)	7 (22%)	
Renal	10 (32%)	4 (13%)	
Limb	3 (9%)	2 (6%)	
Duodenal atresia	3 (9%)	0 (0%)	
Other	3 (9%)	2 (6%)	
Primary versus Secondary	56% Primary versus 44% Secondary		
Adulthood Demographics			
Mean age (SD) years	29 ± 5	29 ± 5	
Mean BMI (SD)	19.9 ± 3.5	24.2 ± 4.9	0.0006
In relationship (married/partner)	10 (31%)	18 (56%)	0.07
Employed	26 (81%)	26 (81%)	
Full time	20	25	
Part time	6	1	

Table 4.1 Demographics, type of OA and associated abnormalities

Morbidity in Adulthood

GT participants experienced more morbidity and chronic disease in adulthood than PR participants (Table 4.2). BMI was significantly lower in GT participants than in those who had PR ($p < 0.0006$). Accordingly, supplementary jejunostomy feeding was still required in adulthood in six (13%) participants. Of these, one participant had an unsafe swallow following a road traffic accident mandating jejunal feeding. Three participants needed a jejunostomy due to significant respiratory disease limiting oral intake; one had a history of laryngeal cleft limiting oral intake, and two

recurrent aspiration and lung disease. The other two participants were jejunally fed due to severe dumping syndrome and recalcitrant poor gastric emptying.

	Gastric Transposition n = 32	Primary Repair n = 32	P value
Morbidity in Adulthood			
Supplementary feeding	6 (19%)	0 (0%)	0.02
Dumping symptoms	8 (25%)	0 (0%)	0.004
Revision surgery	3 (9%)	0 (0%)	0.2
Anastomotic Dilatations	11 (34%)	4 (13%)	0.07
Chronic respiratory	9 (28%)	8 (25%)	0.9
Anaemia	15 (47%)	3 (9%)	0.001
Upper GI bleeds	3 (9%)	0 (0%)	0.2
Depression	6 (19%)	3 (9%)	0.4
Medication			
Anti-reflux	11 (34%)	8 (25%)	0.58
Inhalers	9 (27%)	7 (22%)	0.57

Table 4.2 Morbidity and medication by group and statistical comparison between groups (Mann Whitney U).

Although symptoms suggestive of dumping syndrome were described by 8 (25%) GT participants, only 6 (16%) reported having a formal diagnosis of dumping syndrome. Major revision surgery was reported by 3 GT participants. Detailed notes of the revision surgery were not available but were reported to include a partial gastrectomy and jejunostomy, and replacement of gastric transposition with a colonic interposition. The third revision surgery participant could not recall the procedure but involved a Roux-en-Y reconstruction.

Anastomotic dilatations were reported in more than a third of GT participants (34%) versus 13% of PR participants. This included one participant who performs regular bougie self-dilatation of a complex anastomotic stricture at home. Although numbers of participants with chronic respiratory disease was similar between the two groups, 3 GT patients had severe chronic respiratory disease such as bronchiectasis and were under the care of respiratory hospital physicians.

Anaemia was the most commonly reported morbidity. Whilst most participants did not know specific details of their anaemia, 3 reported upper gastrointestinal bleeding and ulceration requiring endoscopy.

Depression in adulthood was reported in nearly 1 in 5 (19%) GT patients, with only 3% of PR patients reporting suffering from depression.

The frequency of gastrointestinal and respiratory symptoms is shown in Figure 4.2. These data suggest that both groups suffer from regular gastrointestinal and respiratory symptoms in adulthood. Following GT it appears that reflux is the most frequently reported gastrointestinal symptoms whilst dysphagia is the most frequent problem after PR. The frequency of cough and wheeze is similar in both groups but regular shortness of breath is more common after GT.

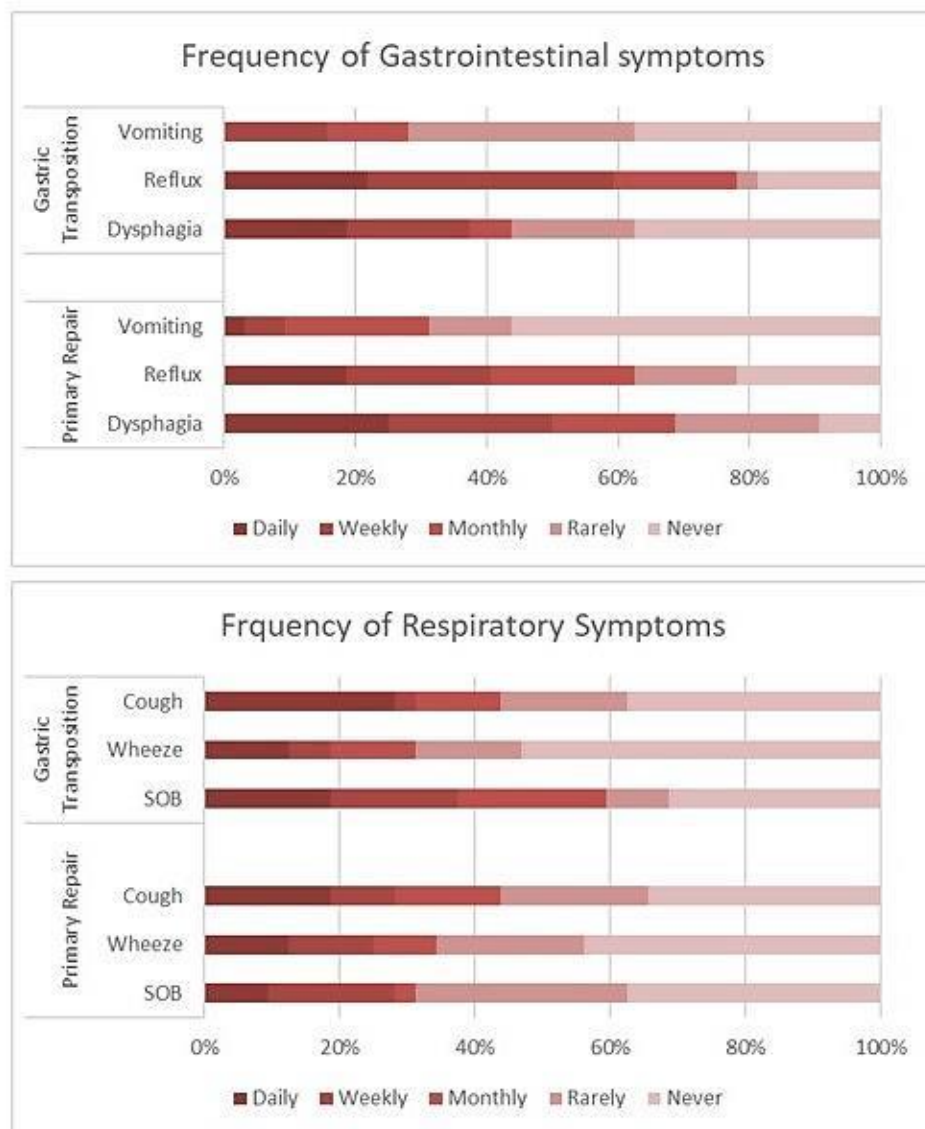


Figure 4.2 Frequency of gastrointestinal and respiratory symptoms. Heat bars represent the different frequency of symptoms from Daily (darkest red) to Never (pale pink).

GSRS and GIQLI scores

The total GSRS score appeared to be higher (i.e. worse) than age matched normal controls (Dimenas, Carlsson et al. 1996) in both the GT and PR groups (Figure 4.3) with the median and 95% CI of participants above the 95% CI of the mean of the normal controls, although this could not be formally statistically evaluated without the raw data for the controls.

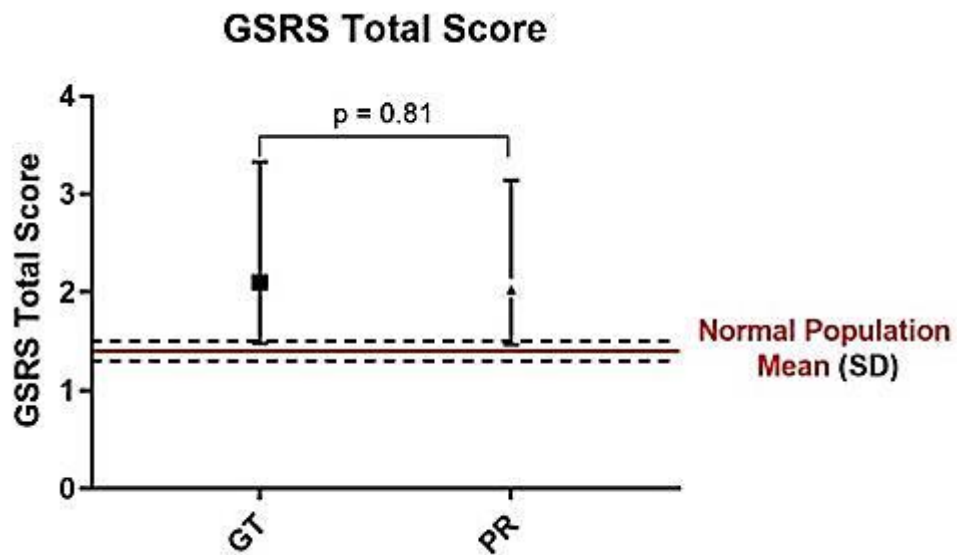


Figure 4.3 Gastrointestinal symptom rating scale total score after gastric transposition (GT) versus primary repair (PR).

P value is the statistical comparison between the 2 groups (Mann Whitney U Test). Black dotted line and red lines show the normal population mean scores and standard deviation (SD) (Dimenas, Carlsson et al 1996).

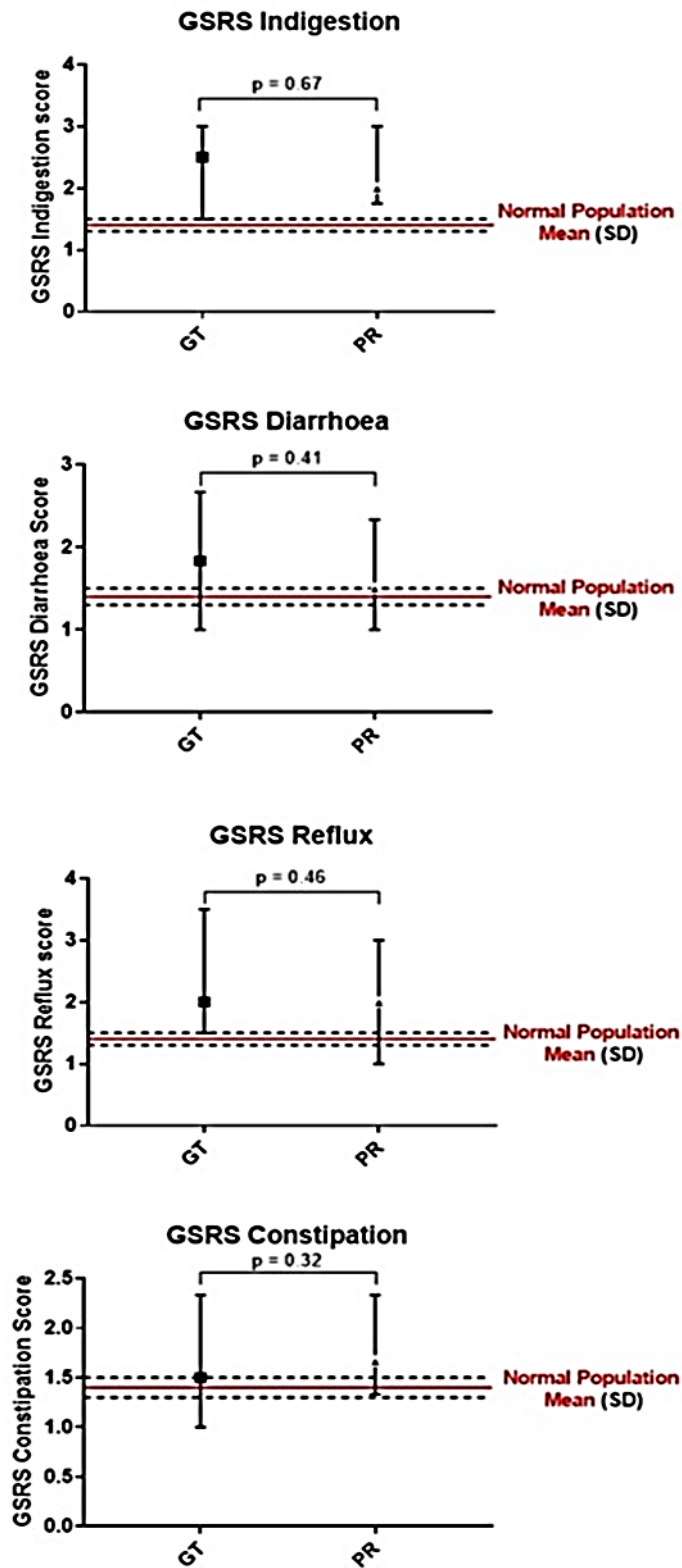


Figure 4.4 GRSRS Sub Scale Scores for indigestion, constipation, reflux and constipation by group (gastric transposition GT versus primary repair PR). P value is the statistical comparison between the 2 groups (Mann Whitney U Test). Black dotted line and red lines show the normal population mean scores and standard deviation (SD) (Dimenas, Carlsson et al 1996).

For the sub-scales (Figure 4.4), median scores for indigestion and reflux were above the 95% CI for the controls in both the GT and the PR groups, above the 95% CI for the controls for diarrhoea in the GT group but not the PR group, and above the 95% CI for the controls for constipation in the PR group but not the GT group; there was no significant difference between the GT and PR group for any of the subscales.

Gastrointestinal quality of life (GIQLI) scores are shown in Figure 4.5. The GT group had lower median quality of life with median GIQLI score of 113 (95% CI 102-122) compared with the PR group with a score of 122 (101-128) which was similar to the normal population figure of 125 (Eypasch, Williams et al. 1995). Although the quality of life score was higher in the PR participants, this was not significantly different from the GT group ($p=0.29$). Statistical comparison to normal population data was not possible due to a lack of the normal population raw data. Despite the median score being lower than the normal population mean, 7 (23%) GT participants had a higher ie better quality of life score than the normal population mean.

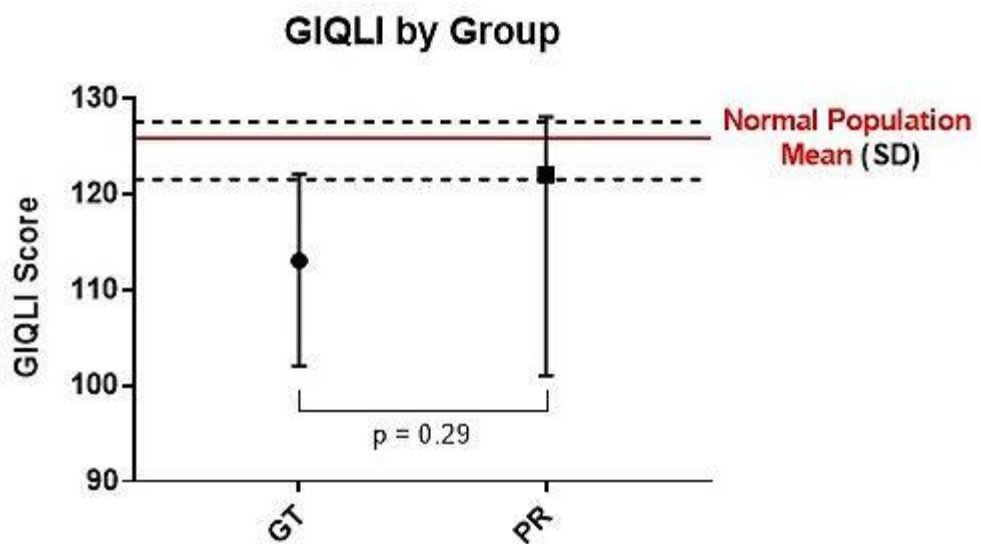


Figure 4.5 Gastro intestinal quality of life index by group. P value is the statistical comparison between the 2 groups (Mann Whitney U Test). Black dotted line and red lines show the normal population mean scores and standard deviation (SD)

(Dimenas, Carlsson et al 1996). P value suggests no significant difference in score between the 2 groups.

Discussion

Gastric transposition is the most commonly performed oesophageal replacement operation for patients with OA in Europe (Zani, Eaton et al. 2014). The data on long term outcomes of GT are sparse, especially in adulthood, and this study goes some way to fill that gap in understanding. We demonstrate an important burden of symptoms, morbidity and low gastrointestinal quality of life score suffered by these patients as adults. Results from the PR group also allow us to see how these complex GT patients compare to the less complicated 'standard' OA patient who have been shown in the existing literature to suffer from long term gastrointestinal and respiratory morbidity in to adulthood (Chetcuti, Myers et al. 1988, Koivusalo, Pakarinen et al. 2005, Connor, Springford et al. 2015). Whilst we recognise the two groups are not strictly comparable the PR participants provide some context within which the results of GT can be considered.

The patients in this study are a cohort operated on at GOSH early in the experience of GT. Half were performed as the primary operative repair of long gap cases and the others were secondary procedures i.e. salvage surgery after failed oesophageal anastomoses which explains the distribution of OA type seen in the GT group. Our comparative group were patients who had primary oesophageal anastomoses in the same time period and have the expected distribution of type of OA with type C predominating.

Comparison to literature

Due to the rare nature of paediatric GT current literature is limited to retrospective series (Hirschl, Yardeni et al. 2002, Spitz, Kiely et al. 2004, Sharma and Gupta 2011, Angotti, Molinaro et al. 2016, Awad and Jaffray 2017) and reviews or metanalysis (Gallo, Zwaveling et al. 2012, Loukogeorgakis and Pierro 2013, Awad and Jaffray 2017) of such series. The detail, quality and duration of follow up in these papers is variable and the definition of 'long term' follow up in some needs questioning. Loukogeorgakis et al's (Loukogeorgakis and Pierro 2013) comparative review of

oesophageal replacement methods in OA used 1 year as representing 'long term' follow up and Gallo et al's (Gallo, Zwaveling et al. 2012) meta-analysis of the same topic did not specify the median duration of follow up but quoted a range of 0.5 – 41 years. The same groups comparative study of GT and jejunal interposition (JI) had a median follow up of 14 years (Gallo, Zwaveling et al. 2015). More recently Awad et al presented the morbidity experienced in a small series of GT patients with a median follow up of only 8.5 years (Awad and Jaffray 2017). Alongside this they performed a detailed review of literature covering outcomes of GT in OA, their inclusion criteria for 'long term' follow up papers was 5 years. The mean follow up of this study (29 years) is one of the longest in the literature and given the coverage of morbidity, symptoms and health related quality life makes it the most comprehensive.

The most frequently reported outcomes of oesophageal replacement for OA are peri-operative e.g anastomotic leak, surgical complications and strictures (Gallo, Zwaveling et al. 2012, Loukogeorgakis and Pierro 2013). Longer term GT outcomes which have been commonly reported include feeding issues such as reflux, dumping syndrome, delayed gastric emptying and jejunostomy problems (Gallo, Zwaveling et al. 2012, Gallo, Zwaveling et al. 2015, Awad and Jaffray 2017). Other reported morbidity in childhood includes poor weight gain and anaemia (Davenport, Hosie et al. 1996, Jain, Sharma et al. 2012, Awad and Jaffray 2017). Our results confirm that much of the morbidity reported is not isolated to childhood.

Body Mass Index

GT affects nutritional status into adulthood. Whilst the mean BMI for GT participants was 'normal' at 21 (+/- 3.5) it was significantly lower than in PR participants. It is also concerning that 12/32 were classed as underweight (BMI <18.5). There are poor comparative data for nutritional outcomes after GT. Davenport et al looked at 16 early patients (including some patients from the same cohort as this study) who had GT in infancy and found at a median age of 9 years 11/16 patients had weight between the 3rd and 97th centile for age (Davenport, Hosie et al. 1996)

Gallo et al found 44% of GT patients to have an SDS weight/age of less than -2 and Spitz described mean BMI being around the 25th centile for age after reviewing his series in 2009 (Revicki 1998, Spitz 2009, Gallo, Zwaveling et al. 2015). Long term outcomes in larger OA population studies including all OA types have shown normal mean BMIs (Svoboda, Fruithof et al. 2017) – in agreement with early work of Chetcuti et al describing catch up growth in OA patients through infancy and childhood (Chetcuti, Myers et al. 1988).

There are several reasons identified that potentially explain why GT participants have a lower BMI than the PR group. Supplementary feeding was still required into adulthood in 6 (19%) participants for a variety of reasons. Ng et al (Ng, Loukogeorgakis et al. 2014) report 37% of children at a mean follow up of 28 months after minimally invasive GT still required jejunal feeding and Gallo et al found 33% needed jejunal feeding up to a median of 14 years of age (Gallo, Zwaveling et al. 2015). There are no comparative data in the literature for the longer-term use of jejunal feeding into adulthood, but our data suggests jejunostomy use might decrease into adulthood.

Dumping syndrome

Dumping syndrome is well-recognised after GT and may contribute to poor nutrition. Spitz has previously reported an incidence of 4% on reviewing 192 GTs (including the patients in this cohort)(Spitz 2009). We found in adulthood 4 participants (12%) had a formal diagnosis of dumping syndrome whilst 8 (25%) participants reported dumping symptoms without a diagnosis and in 4 participants without an understanding of the condition and its association to GT. Dingemann et al (Dingemann, Meyer et al. 2014) found even higher numbers of patients reporting dumping symptoms in adulthood (52%) suggesting this has been previously under reported. All but one of the participants interviewed managed their dumping symptoms by simply eating smaller meals more often and usually with good effect.

Re-operation

The reported need for early reoperation after oesophageal replacement, and incidence of strictures have been used as a comparator between GT and other

types of oesophageal replacement (Tannuri, Maksoud-Filho et al. 2007, Gallo, Zwaveling et al. 2012, Loukogeorgakis and Pierro 2013). However, the longer term need for surgical intervention is poorly reported. We found 3 participants required major revision surgery after leaving paediatric care, two of these cases were reportedly performed to overcome poor gastric emptying. Anastomotic dilatation in adulthood was necessary in 11/32 (34%) of GT participants compared with 13 % of the PR participants; meta-analysis suggest that strictures occur in 22% of children undergoing GT (Awad and Jaffray 2017). In our series, 8 (72%) of our participants who needed dilatation as adults had required dilatation as children. Secondary GT participants were more likely to need dilatations which may reflect their more complex surgical course.

In those participants (13/32) who had undergone gastroscopy in adulthood one reported a diagnosis of Barrett's oesophagus in the proximal oesophageal remnant. This has previously been reported following OA repair (Connor, Springford et al. 2015) and GT for achalasia in the adult population (da Rocha, Ribeiro et al. 2008). The incidence of Barrett's changes may be higher but data is limited to participant recall not from clinical notes. Our understanding of the incidence of Barrett's oesophagus in the general OA population remains an area that requires further attention.

Symptoms

Gastrointestinal morbidity was also assessed using the GSRS scoring system, in which gastrointestinal symptoms are allocated a score. In GT participants the predominant reported symptom was gastro-oesophageal reflux with nearly 60% of participants reporting weekly symptoms. PR participants also frequently reported reflux but only 40% on a weekly basis. However, half of PR participants report dysphagia versus 38% of GT participants.

Both GT and PR participants reported a higher GSRS reflux score and indigestion score than that reported for the normal population (Dimenas, Carlsson et al. 1996). There is no doubt that upper gastrointestinal symptoms continue into adulthood in OA patients (Little, Rescorla et al. 2003, Deurloo, Ekkelkamp et al. 2005, Deurloo,

Ekkelkamp et al. 2005, Connor, Springford et al. 2015) although the severity of these symptoms and effect on QoL is poorly reported. Spitz has previously reported early swallowing problems being universal after GT and severe in around 30% of patients (Spitz 2009) and our latest data suggests a similar number of patients have regular dysphagia in adulthood. Dingemann et al (Dingemann, Meyer et al. 2014) suggest a higher incidence of dysphagia in adulthood after complex OA repair and oesophageal replacement but give no indication of severity.

Medical Morbidity

Whilst surgical morbidity is often reported, I found the medical morbidity of anaemia to be reported in nearly half of the GT participants interviewed and only 3(9%) of the PR group. Most were unaware of the type of anaemia they suffered from, although 3 participants reported it being attributed to upper gastrointestinal bleeding (UGI) from ulcers or gastritis. Anaemia after GT was first reported by Spitz's group who found a third of patients who had GT as infants were anaemic at a mean age of 9 years and all had a low ferritin suggesting iron deficiency. Other authors have found 70% (Jain, Sharma et al. 2012) to 100% (Awad and Jaffray 2017) of children having GT to be anaemic and suggest poor iron absorption is the primary cause with some also suffering UGI bleeding as I experienced. Whilst I recognise the limitations of patient reported anaemia in our study versus documented haemoglobin levels, the apparent prevalence of anaemia in this and other studies suggests that iron deficiency is frequent in adulthood and should be routinely screened for in adult patients following GT.

Chronic respiratory disease in OA (Chetcuti and Phelan 1993, Connor, Springford et al. 2015) is well reported and may be the result of problems such as tracheomalacia and reflux. In GT, the presence of the stomach in the chest brings additional problems that may be related to the mass effect on the lungs themselves and decreased functional lung capacity (Davenport, Hosie et al. 1996, Jain, Sharma et al. 2012). A quarter of our participants reported chronic respiratory disease and described a range of severity from mild reactive airway disease to severe lung disease or bronchiolitis necessitating care by respiratory physicians. Results for current respiratory symptoms reflect the incidence of respiratory disease with

around a third of participants reporting shortness of breath (37%) and cough (30%) at least on a weekly basis. Lung disease associated with OA and GT may receive little attention from surgeons but the frequency and severity I have reported make clear the importance of good early respiratory care and follow-up in these patients.

Quality of life and mental health

Spitz, using a modified GIQLI, reported near-normal quality of life in those who had GT as the primary surgery for repair of long gap OA versus those having GT as a salvage procedure who had significantly lower scores and health related QoL (Ludman and Spitz 2003). More recently Dingemann et al, using the KIDSCREEN-27 questionnaire, have published a comparison of health related QoL in complex OA, comparing delayed primary anastomosis, patients needing multiple dilatations, those who had major revision surgery and oesophageal replacements (Dingemann, Meyer et al. 2014). They suggest that children have an excellent HRQoL after complex OA repair, including in the group under-going oesophageal replacement, in comparison with normal controls. However, adults with complex OA demonstrated reduced quality of life with high incidence of reflux, dysphagia and dumping syndrome. I found similar reduced HRQoL in adult GT participants compared to the normal population. Interestingly, in our study, nearly a quarter of GT participants report higher HRQoL than the normal population. The median GIQLI score in PR participants was just below the normal range suggesting HRQoL may be less affected in this population. There was no statistically significant difference in GIQLI scores between PR and GT groups, as several participants with a complicated course following PR reported a low score.

The decreased HRQoL and high incidence of adulthood morbidity may help explain the high incidence of diagnosed depression in our study (19% in GT participants). Dingemann et al (Dingemann, Meyer et al. 2014) reported that a similar proportion of adults with complex OA reported QoL scores that would put them at risk of depression but did not provide data on clinically diagnosed depression. Obviously, the aetiology of depressive illness is multifactorial and cannot simply be attributed to OA and GT especially in a patient group with significant congenital comorbidities. However, some authors have argued that congenital comorbidities do not influence

long-term QoL in OA, although only four patients with long gap OA were included in their analysis (Deurloo, Ekkelkamp et al. 2005). The interviews conducted in the current study provided subjective evidence that in some participants, congenital comorbidities affect QoL more than OA or GT related morbidity, for example in a participant with renal failure having undergone two renal transplants.

Similarly, poor outcomes from oesophageal replacement can also influence QoL, for example having to self-dilate a recalcitrant upper anastomotic stricture. It is important to recognise that future cohorts of patients with complex OA undergoing GT may have significant comorbidities alongside the morbidity of their OA and oesophageal replacement. This may put them at risk of mental health problems which as paediatric surgeons we are unlikely to recognise, particularly in the adolescent age group. This again highlights the need for close monitoring of mental health alongside the other reported morbidity from childhood through to transition into adult services.

Limitations

Whilst this study gives the most comprehensive and long term follow up of gastric transposition in OA to date, as is often the case with rare disease, the study was limited by the number of participants recruited from a single institution. However, given the historical nature of the cohort the response rate was good, especially in comparison to the existing literature. Larger multi-centre studies would address this issue and bigger numbers may allow multi variate type analysis to identify risk factors for poorer outcomes and QoL. Methodologically I aimed to gain a broad picture of the lives of GT participants and therefore used a wide range of methods including structured telephone interview, validated questionnaires and some open questions. Telephone interviewing as opposed to written questions may bias responses; certain questions in GIQLI and GSRS may be perceived as embarrassing and participant's awareness that me as the interviewer was a surgeon from the publishing institution could have influenced response. Future work would benefit from dedicated non-surgical research staff to deliver interviews. Patient reported outcomes may also be limited in terms of accuracy of data, for example patient reporting of anaemia without haemoglobin results may be prone to inaccuracy.

However, the impracticality of accessing current adult records meant obtaining this data was not possible. One other inevitable consequence of long-term follow up studies is that the data reflect surgical and medical practise initiated historically and results obtained may not reflect current practise.

Although there are clearly alternative surgical options for these patients, we currently do not have similar comprehensive long-term outcome data of these alternatives in adulthood as comparison. Such comparison to other procedures was therefore not the purpose of this study. I recognise there is no perfect oesophageal substitute and the limited data available suggest that patients who have other forms of oesophageal replacement are also likely to suffer from significant morbidity into adulthood which is not well enough reported at present. The morbidity seen in the long term from complex oesophageal atresia must be a reflection of the complexity of the condition and its associated anomalies as opposed to simply the techniques used to correct it.

Conclusions

I have demonstrated the most comprehensive long term follow up of gastric transposition for OA to date and report the broad spectrum of outcomes experienced by these patients. From those with multiple significant morbidities, daily symptoms and low quality of life to over a quarter who have a normal health related quality of life, several of who report living a 'normal life' and working in a variety of full-time professions. The frequency of significant surgical and medical problems across the cohort and associated detriment on mental health mandates long term follow up of all patients undergoing gastric transposition for OA into adulthood and quality transition of care from paediatric to adult services. This transition needs to be of high quality, multi-disciplinary in nature and may involve many teams including surgeons, gastroenterologists, respiratory physicians, general practitioners and mental health teams.

Chapter 5 Rat Model for Oesophageal Implantation

Introduction

Various models have been described and used for oesophageal tissue engineering in rats. Rats have several benefits as an experimental animal, being easy to maintain, tolerant of surgical procedures and having similar anatomy to humans (Figure 5.1) to make it an applicable model. The rat neck is long allowing access to the oesophagus and trachea, and the anatomy below the diaphragm is also similar to that of the human, but with a relatively longer intra-abdominal oesophagus that makes this a site that has been successfully used for scaffold implantation (Lopes, Cabrita et al. 2006, Urita, Komuro et al. 2007). Rats can also tolerate well a wide variety of modified diets without morbidity, unlike the rabbit which requires large volumes of fibre.

The aim was therefore to determine whether circumferential oesophageal implantation is feasible in a rat model as proof of concept.

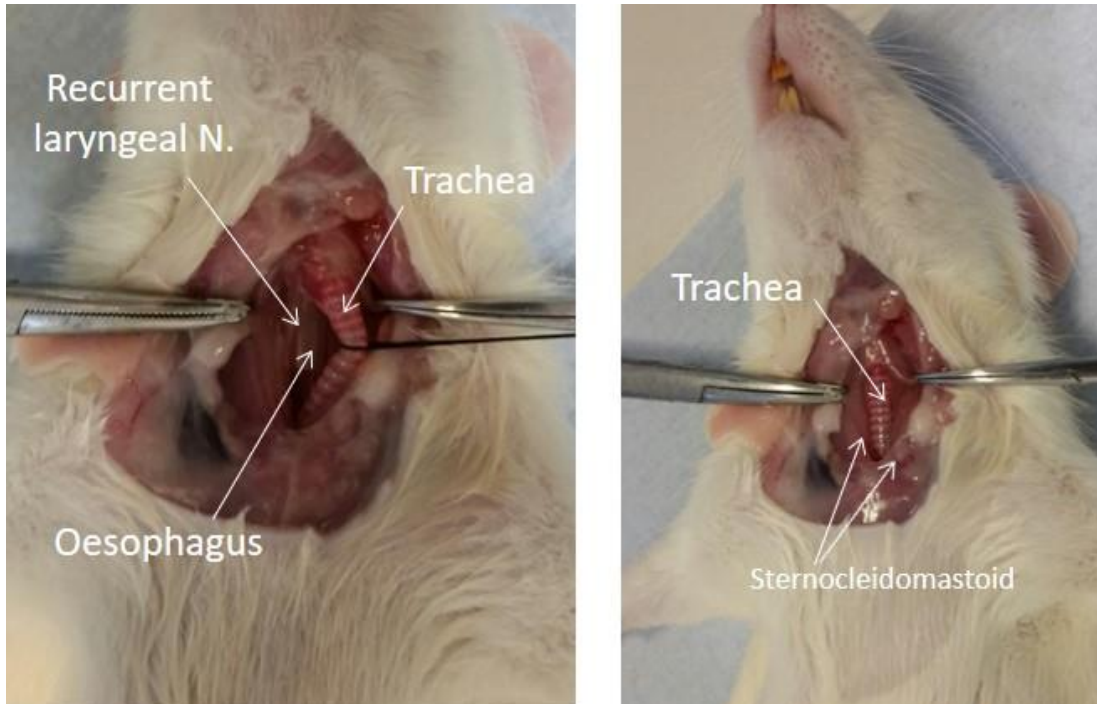


Figure 5.1 Rat cervical anatomy.

Following a longitudinal incision and traction on strap muscles and sternocleidomastoid the trachea is mobilised laterally. Recurrent laryngeal nerves are attempted to be identified and preserved. The oesophagus is then visible and can be controlled.

Method

The project was registered and licence granted (70/7504) by the Home Office in accordance with Animals (Scientific Procedures) Act 1986.

Phase 1: Cadaveric dissection

Aim: To understand the anatomy of the cervical region of the rat in order to develop a model for cervical implantation of decellularised oesophageal scaffolds.

Methods:

4 Sprague Dawley rats were euthanised and underwent neck dissection. Nasogastric tubes were passed to facilitate identification of the oesophagus. Attention was paid to understand the anatomy of the recurrent laryngeal nerve and its relationship with the trachea and oesophagus as *in vivo* damage to the recurrent laryngeal nerve will lead to paralysis of the vocal cords and result in respiratory complications. The oesophagus was then divided and then re-anastomosed using 6.0 monofilament sutures. The dissection and anatomy demonstrated are seen in Figure 5.2.

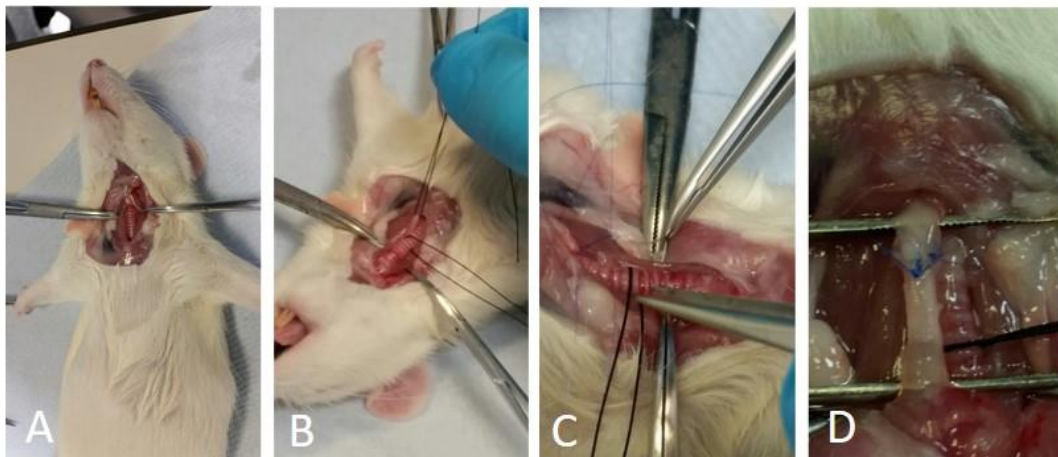


Figure 5.2 Rat cadaveric dissection. A) longitudinal incision in the neck; B) mobilisation of the trachea; C) control of the oesophagus; D) completed re-anastomosis

Phase 2: Orthotopic circumferential implantation

Aims: To assess the feasibility of implantation of circumferential decellularised scaffolds into the cervical oesophagus.

Methods:

Scaffold preparation

Oesophagi were harvested from euthanised Sprague Dawley rats. These were decellularised according to the previously described DET protocol (Totenelli et al, 2014). This involved washing with Phosphate Buffered Saline containing 1% antibiotic/antimycotic (PBS/AA; Sigma) and then cannulation. Oesophageal lumen was then perfused with continuous fluid delivery (iPumps) at 1ml/min for 2 cycles. Each DET cycle was composed of deionised water at 4 °C for 24 h, 4% sodium deoxycholate (SDC; Sigma) at room temperature for 4 hours and 2000 Kunitz units/ml DNase-I (Sigma) in 1M NaCl for 3 hours. Scaffolds were subsequently sterilized with gamma irradiation. Macroscopic appearance of oesophagi are shown in Figure 5.3.




Figure 5.3 Macroscopic appearance of rat oesophagi freshly harvested and post decellularisation

Sprague Dawley Rats weighing >350g were anaesthetised using a combination of inhaled isoflurane (4%) and oxygen via nose cone plus subcutaneous buprenorphine (Vetergesic 0.05mg/kg). Prophylactic antibiotic enrofloxacin 10mg/kg was given subcutaneously at induction of anaesthesia. An oro-gastric tube was placed and, after shaving the fur, a longitudinal approach to was performed (as in Figure 5.2). The strap muscles were moved laterally and trachea controlled with sloops. Care

was taken again to preserve the recurrent laryngeal nerves. A 0.5cm segment of native cervical oesophagus was then resected and a 0.5cm section of decellularised rat oesophagus was inserted and anastomosed with 6.0 monofilament sutures.

Post-operative analgesia included Carprofen 5 mg/kg repeated once daily and buprenorphine 0.05mg/kg subcutaneously. Rats were excluded from diet for the first night post-operatively but given free access to water. Enrofloxacin prophylaxis was continued in drinking water. From day 1 post-operatively, rats were given free access to standard liquid rodent diet. Animals were euthanised if symptoms approached 'moderate severity' in accordance with the Home Office licence.

Results:

The results from this phase of the study can be seen in full in Table 5.1 and in summary demonstrated 3 reasons for poor outcomes from the surgery.

1. Intra operative respiratory distress
2. Post operative respiratory distress
3. Anastomotic leaks

Animal Study Number	Survival (days)	Reason for euthanasia
2.1	2	Respiratory distress
2.2	5	Anastomotic leak
2.3	0	Intra-operative (respiratory)
2.4	3	Necrotic section of oesophagus & obstructed
2.5	0	Intra-operative (respiratory)
2.6	3	Respiratory distress
2.7	3	Respiratory distress & obstruction
2.8	0	Intra operative death (respiratory)
2.9	4	Anastomotic leak

Table 5.1 Phase 2 Results - Survival post-circumferential implantation and reason of euthanasia. Animal study number is the unique number for each animal used.

Autopsy was performed in all animals. The causes for intraoperative respiratory problems were difficult to establish and might be attributable to anaesthetic complications, manipulation of the trachea or damage to recurrent laryngeal nerves. Steps were therefore taken to minimise these risks going forward. Attempts were made following training at the Royal Veterinary College to attempt endotracheal intubation but this was not technically possible with the equipment available.

Post-operative respiratory distress was thought to be due to poor function of the oesophageal graft – i.e. poor peristalsis leading to increased respiratory secretions and respiratory compromise. Anastomotic leaks, as would be expected, were observed at later time points post operatively (Day 4 / 5) and could have resulted from poor technique or failure of the scaffold to heal / attach to the native oesophagus. Both of these problems were thought to be exacerbated by the need to feed animals early post-operatively. It was therefore felt that attempts to minimise the need for oral fluid and diet intake immediately post operatively might minimise these complications. Animals could obviously not be starved for prolonged periods, and therefore it was felt gastrostomy insertion, as would happen in clinical practice, may help minimise these complications.

Phase 3: Gastrostomy

Aim: To develop a gastrostomy technique to avoid the need for early oral post-operative feeding

Methods:

Consideration was made regarding the best way to perform gastrostomy insertion in the rat. The animal technicians felt that rats would tend to bite at easily accessible gastrostomies i.e. with an exit site in the standard position on the abdominal wall (as in humans). Discussion with the departmental veterinary surgeon led us to approach the Department of Neuroscience Psychology & Behaviour, University of Leicester who were successfully utilising a rat gastrostomy

system as part of their neuropsychology work. We visited their department to learn the technique.

The technique shown in Figure 5.4 involved implanting a 'mount' on the back of the neck of the rat with a subcutaneous tube tunnelled to the abdomen where the gastrostomy tube is inserted and secured in the stomach via laparotomy.

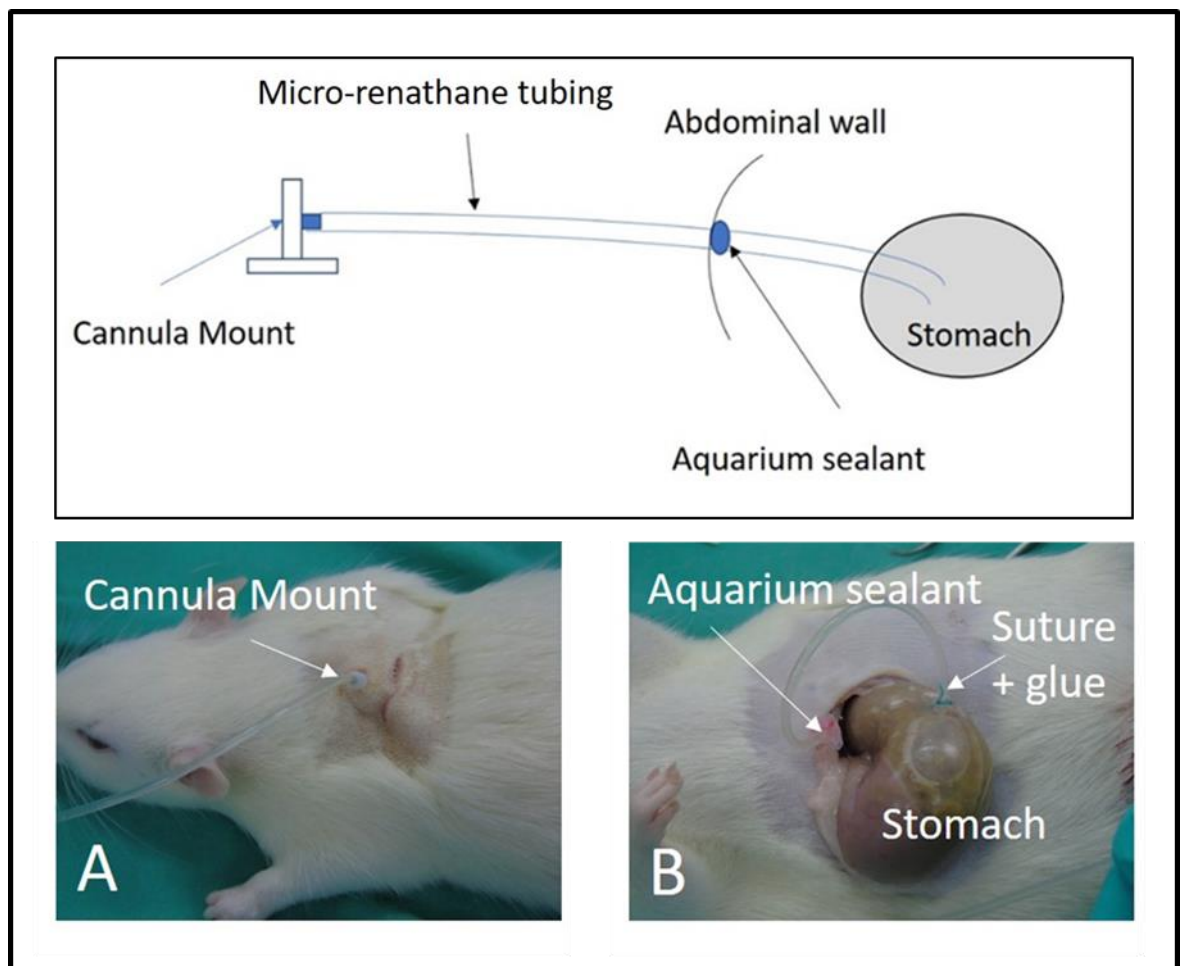


Figure 5.4 Diagram of rat gastrostomy system.

Micro-Renathane tubing forms the gastrostomy and is tunnelled subcutaneously to connect the external cannula mount on the back of the neck (A) to the tube tip which is secured in the stomach with sutures and glue (B). Aquarium sealant was used at the peritoneal exit site to avoid it being accidentally pulled out.

Two Sprague Dawley rats were anaesthetised as previously described and given prophylactic antibiotics. Initially in a supine position, a midline laparotomy was performed, a purse string suture was placed in the stomach and then a length of MRE-065-CL-50 Micro-Renathane (.065" x .030") tubing was tunnelled through the

abdominal wall and 1 cm was inserted into the stomach and the purse string tied to secure the tube. Cyanoacrylate glue was also used on the stomach to secure the tube. A small blob of aquarium sealant was applied to the tube in advance at the level of the abdominal wall to prevent it being pulled out with traction.

Rats were then turned prone and a small transverse incision on the neck of the rat behind the ears was made and a small pocket created to allow a Bilaney Back-Mount Cannula (15mm Pedestal – side port 4mm) to be inserted. The micro-renathane tubing was then tunnelled from the abdominal incision round to the neck and attached to the back mount. All wounds were closed with absorbable polyfilament sutures. The cannula mount / gastrostomy tubing was flushed with saline.

Post-operative analgesia and antibiotics were given as previously described. Cannulas were flushed every 48 hours with saline to maintain patency. Due to the narrow gauge of this gastrostomy feeding system, liquid rat food had to be obtained that would easily flow through the micro-renathane tubing. For this, BioServ® F6112SP Rodent liquid diet, Ain 76 Modified, Casein Hydrolysate was used and made up according to the manufacturer's instructions. This was given by syringe via a short segment of micro-renathane tubing attached onto the catheter mount. Rats were individually housed to avoid biting others catheter mounts.

Results

Both rats tolerated the procedure well. One was euthanised at the end of the procedure due to gastro-oesophageal reflux aspiration following flushing of the gastrostomy with 10 ml of saline. The second gastrostomy was flushed with 5ml of saline and the animal recovered well and tolerated a trial of gastrostomy feeding to ensure the system worked. This animal was entered into the next set of 2 stage experiments.

Phase 4: Two-stage circumferential implantation

Aim:

Having demonstrated the ability to safely implant and use gastrostomies for early post-operative feeding the aim of the next phase was determine feasibility of circumferential oesophageal implantation with a gastrostomy in place. It was decided this was best achieved with a staged procedure, with initial gastrostomy insertion, followed 2 weeks later with cervical implantation of the decellularised oesophageal scaffold.

Methods:

Four Sprague-Dawley rats underwent gastrostomy insertion followed by circumferential scaffold implantation with a minimum of 2 weeks between procedures. Both procedures were performed as described above.

Post-operative care following the second stage was as follows:

- 3 ml saline flush of gastrostomy at end of procedure
- Nil by mouth and nil by gastrostomy for the first night post operatively
- Day 1 post operatively – 5 x 3 ml feeds (BioServ® F6112SP Rodent liquid diet, Ain 76 Modified, Casein Hydrolysate) via gastrostomy with 2 ml water flushes
- This regimen would be continued until day 7 post operatively or the animal showed symptoms of moderate severity when the animal was euthanised according to the project licence
- Autopsy performed on all animals

Results:

Outcomes from this phase of the study are outlined in Table 5.2. Again, problems persisted with animals surviving the perioperative period. The first may have been the result of the gastrostomy tubing being too long in the stomach leading to reflux and aspiration of feed following feeding. Animal 4.4 survived the post-operative procedure but was euthanised on day 4 as a result of obstruction of the implanted scaffold.

Study number	Gastrostomy insertion	Scaffold insertion	Date euthanised	Survival day	Reason for euthanasia
4.1	16/12/15	04/01/16	Post op	0	Aspiration
4.2	16/12/15	04/01/16	05/01/16	1	Haematoma
4.3	01/02/16	08/02/16	08/02/16	0	Respiratory
4.4	01/02/16	08/02/16	12/02/16	4	Obstruction

Table 5.2 Phase 4 - Outcomes from 2 stage implantations

These poor results led to abandoning further attempts at full circumferential implantation. Attention therefore turned to implantation of patches of scaffolds – as described in other studies (Lopes, Cabrita et al. 2006, Urita, Komuro et al. 2007). Although a circumferential implantation would have been ideal to mimic the clinical application of oesophageal replacement, a patch model would have utility for in vivo study of different cell seeding strategies.

Phase 5: Cervical Patch implantation – feasibility

Aim:

The aim of this phase of the study was to assess the feasibility of cervical implantation of a full thickness patch of decellularised oesophageal scaffold.

Method:

Two Sprague-Dawley rats weighing >350g were anaesthetised and had gastrostomies inserted as described above. Two weeks later, rats underwent implantation of a patch of decellularised oesophageal scaffold.

Patches were initially prepared and decellularised as circumferential scaffolds as previously described and subsequently irradiated. At implantation, a 10x5 mm

elliptical patch was cut from the scaffold ensuring the orientation of the mucosa relative to that of the native oesophagus was maintained.

Rats were anaesthetised. A longitudinal incision in the neck was performed and the trachea controlled as for circumferential implantations. At this point, an operative microscope was used to allow a 10 x 5mm elliptical incision to be made in the cervical oesophagus and to ensure accuracy of anastomosis of the patch to the native oesophagus which was performed with 7.0 monofilament suture over a 6F oro-gastric tube which was later removed (Figure 5.5).

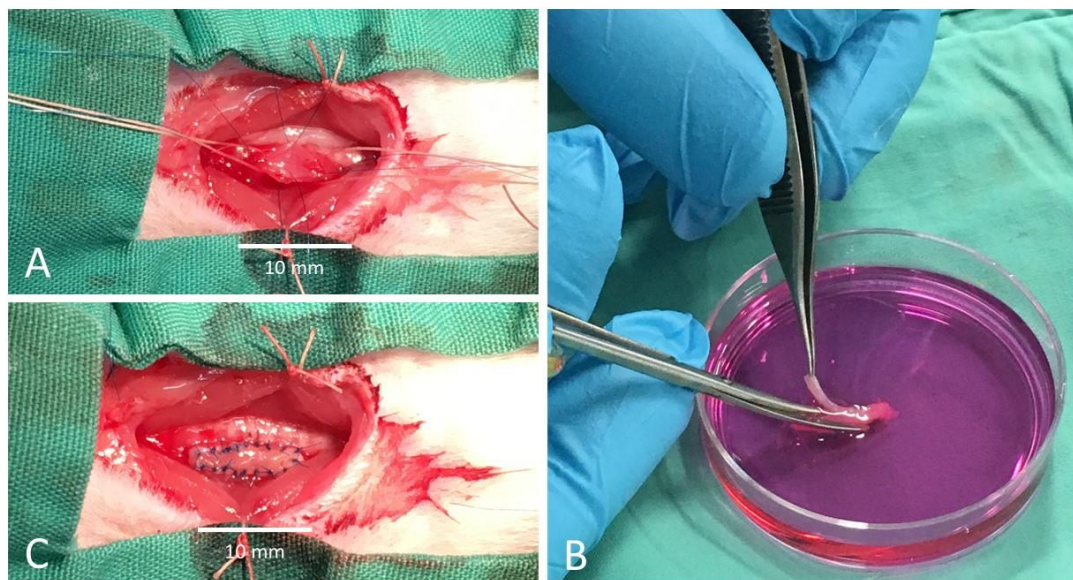


Figure 5.5 Cervical Oesophageal Patch implantation. A) Full thickness incision in cervical oesophagus, B) ellipse of scaffold (10x5mm) cut from decellularised scaffold, C) patch implantation and anastomosis (7.0 monofilament suture)

Post-operatively, rats were given a 3ml saline flush into the gastrostomy at the end of the procedure. Analgesia was given as previously described. Animals were left nil by mouth and by gastrostomy for the first night post operatively.

Day 1 post-operatively, animals were given gastrostomy feeds as previously described (5 x 3 ml feeds with 2 ml water flushes per day). This was continued until day 3 post operatively. Following this, if the rat was well, it would be offered water and then the same liquid diet orally. If oral liquid diet was tolerated, gastrostomy

feeds were discontinued. Animals were again euthanised when symptoms reached a level of moderate severity according to the study licence.

Results:

Both rats survived gastrostomy insertion without complication. At the second stage (patch implantation), one animal was euthanised due to respiratory complications at the end of surgery, the second tolerated the procedure well and was converted to oral feeds on day 3 post operatively. This animal survived for 3 months before being euthanised at the end of the study period.

This demonstrated the feasibility of cervical patch scaffold implantation as a model. Whilst the aim was initially to develop a circumferential model to mimic the clinical application this patch model can be usefully used in the interim to examine the influence seeded cells may have on the integrity of tissue engineered oesophageal scaffolds.

[Phase 6: Influence of recellularisation of scaffold on patch integration](#)

Aim: The aim of this phase was to assess the effect of seeding different cell types on decellularised oesophageal scaffolds on patch integration and cell differentiation *in vivo*.

As *in vitro* work from the laboratory had now developed a method for recellularisation of decellularised scaffolds and I had developed a model of patch implantation with gastrostomy feeding, the next stage was to test the integration of a tissue engineered patch in the animal model, and to examine the effect of different seeding strategies on scaffold integration and cell engraftment.

Methods:

The initial stages (decellularisation, recellularisation) in this study were performed by the cells scientists in the group. Rat oesophagi were decellularised and irradiated as described in Phase 1.

Three experimental groups were studied:

1. Control group, with a decellularised patch that had not been seeded with cells and had not been maintained in culture.
2. ROEC group - decellularised scaffolds surface seeded with rat oesophageal epithelial cells (ROEC).

Rat oesophageal epithelial cells (ROEC) were isolated from the oesophagus of Sprague Dawley male rats. The muscle layer was carefully removed and the submucosa and mucosa layers were enzymatically dissociated using 0.25% Trypsin/ EDTA (Sigma) at 37 °C, until a single cell suspension was obtained.

For epithelial cell seeding scaffolds were slit open and the mucosa layer was removed. Flat oesophageal scaffolds were cut into pieces (~0.5–1.0 cm²) and placed over a transparent cell culture insert (PET membrane, 0.4µm pore, Greiner Bio-One) in a 6-well culture plate. After cell seeding, the scaffolds were incubated at 37 °C for approximately 1 hour. Then cFAD medium was added in the plate, enough to touch the membrane, and on top to cover scaffolds. Fresh medium was added daily to ensure that the scaffolds were continuously covered. After 7 days, the level of the medium was reduced to promote stratification of seeded cells. Seeded scaffolds were kept in culture up to 2 weeks. Cell density for ROEC seeding was $1.3 \times 10^5 - 2.6 \times 10^5$ cells / cm².

3. hMAB group - decellularised scaffolds injection seeded with human mesangioblasts (hMAB) and mouse fibroblasts (mFB) as described in vitro by our group (Urbani, Camilli et al. 2018).

hMAB were isolated from paediatric skeletal muscle biopsies from patients aged from 1 week to 8 years old, with informed consent, during surgeries at the Great Ormond Street Hospital, London, in accordance with ethical approval by the NHS Research Ethics Committee, REC Ref: 11/LO/1522. Biopsies were rinsed in sterile PBS, dissected into small pieces (~ 2 mm), removing possible adipose tissue, and seeded on petri dishes coated with Matrigel diluted 1:100 to favour attachment and cell outgrowth. Muscle fragments were covered with proliferation medium [Megacell medium (Sigma), 5% Fetal Bovine Serum (FBS,

Gibco), 1% non-essential aminoacids (Gibco), 1% L-Glutamine (Gibco), 1% Penicillin-Streptomycin (Gibco), 0.1mM β -mercaptoethanol (Sigma) and 5 ng/ml bFGF (Sigma)] and incubated at 37 °C, 5% O₂ and 5% CO₂. Outgrowths with high cell density were collected through trypsinization and transferred to flasks. Muscle fragments were re-plated up to 4 times until complete depletion occurred. Mesoangioblasts were passaged at 60–70% confluence for up to 10 passages and analysed for expression of pericyte-like markers and differentiation potential. For smooth muscle differentiation, hMAB were incubated in High Glucose DMEM (Gibco) supplemented with 1% L-Glutamine, 1% Pen-Strep, 2% Horse Serum (Gibco) and 5 ngml⁻¹ TGF β 1 (Sigma) for 7 or 14 days, with fresh TGF β 1 provided daily.

Mouse fibroblasts (mFB) were isolated from hindlimb skeletal muscles (extensor digitorum longus) by enzymatic digestion with 0.1% Collagenase type I (Sigma) for 80 min at 37 °C, plated onto 100mm dishes pre-coated with 2% Horse Serum and incubated at 37 °C, 20% O₂ and 5% CO₂. After removal of floating cells and fragments, cells were maintained in culture until confluent using growth medium consisting of High Glucose DMEM, 20% FBS, 1% L-Glutamine and 1% Pen-Strep.

hMAB and mFB at a ratio of 85:15 respectively were trypsinised and re-suspended in a solution of PBS, 0.5 ng ml⁻¹ Collagen type I (Sigma) and 0.1 ng ml⁻¹ Fibronectin (Sigma) and kept on ice till seeding. The volume of cell suspension was calculated to inject 1×10^6 cells every 5 mm length of scaffold. 3–3.5 cm of rat oesophageal decellularized tubular scaffolds was seeded. Cells were microinjected every 3 – 4 mm with an insulin syringe (MyJector) /27 G needle at multiple sites along 3 distinct longitudinal lines. Multiple microinjections were performed manually under a stereomicroscope to ensure cell delivery to the muscle layer. For easy handling and ensuring constant tight tension whilst microinjecting, a 6 F nasogastric tube (Enteral) was inserted into the scaffold first. The intrusion of the plastic tube also removed the mucosal layer from the luminal side of the scaffold.

These were then cultured in a dynamic bioreactor for 2 weeks (Fig 5.6). Scaffolds were sutured to glass rods with 3.0 silk sutures and these were placed in the custom dual glass chamber. This chamber allows physical separation between lumen and external surface of the scaffold. The bioreactor was designed to allow medium flow inside the lumen whereas an inlet and outlet present in the external chamber allowed medium flow around the scaffold. Lumen and external flows were controlled with an Applikon® bioreactor, connected to a reservoir of medium. The external chamber was filled up with medium and connected to the Applikon bioreactor. Medium flow was activated 6 hours after seeding. Medium flow was 5ml/min. Glass chambers and medium reservoirs were maintained in a humidified incubator at 37 °C and 5% CO₂. Medium was changed entirely every 2–3 days. Scaffolds were cultured for 2 days in proliferation medium and 9 days in smooth muscle differentiation medium, with TGFβ added daily through an injection point of the bioreactor.




Figure 5.6 Bioreactor set up for culture of decellularised oesophagus injection seeded with hMAB and mFB.

A) oesophageal scaffold in situ in bioreactor and secured to pump system , B) culture medium surrounding and pumped through scaffold, C) Scaffold before seeding and culture

as described above. Subsequently, 0.5 cm long elliptical patches from each of the three groups were inserted into the cervical oesophagus as described above. The study outline is shown in Figure 5.7

As allo- and xeno- transplanted cells were utilised, it was necessary to immunosuppress recipient rats using intra-muscular tacrolimus (1mg/kg/day). Dosing was decided following discussion with the veterinarian and review of available literature (Uysal and Dokur 2017, Kim, Hundepool et al. 2018, Spunda, Hruby et al. 2018); given the short-term timescale of the study (i.e. 14 days) it was decided that toxicity would not be likely, so a relatively high dose compared to other studies was used.

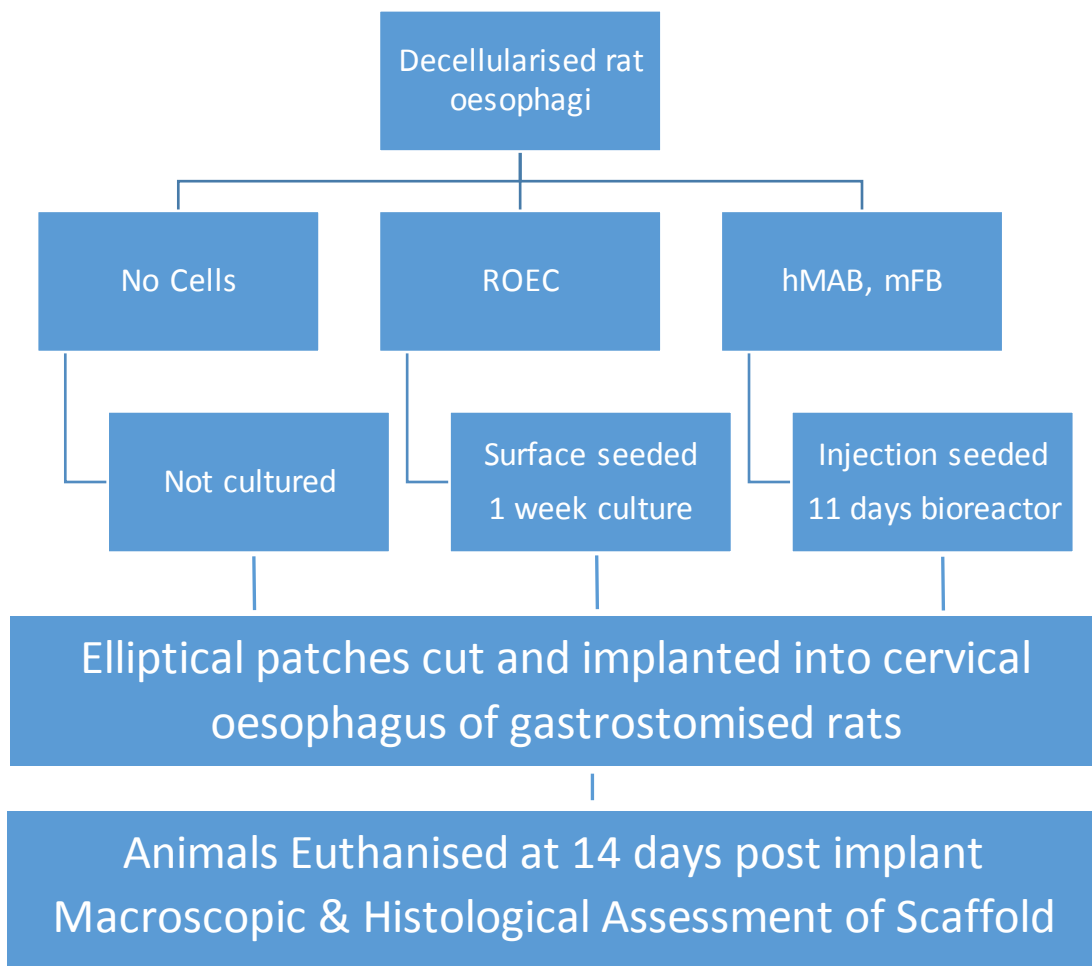


Figure 5.7 Experimental plan for Phase 6

Seeded Patch Study. ROEC – rat oesophageal epithelial cells, hMAB – human mesangioblasts, mFB mouse fibroblasts

Results:



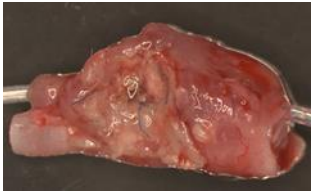
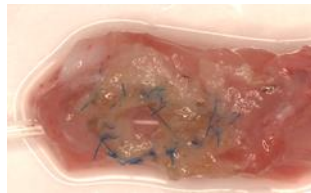


Group	Study number	Survival (days)	Notes	Macroscopic section
Control	6.1	14	Fed well. Scaffold well-integrated at 14 days – 2 sutures dislodged	
	6.2	14	Fed well. Scaffold intact and well-integrated at 14 days – all sutures intact	
ROEC	6.3	4	Scaffold handled poorly Large perforation centre of scaffold with contamination	
	6.4	6	Scaffold handled poorly Large perforation centre of scaffold with contamination	
hMAB, mFB	6.5	6	Scaffold handled poorly Large perforation centre of scaffold with contamination	
	6.6	14	Some delayed swelling, oral feeding delayed Contained leak found at day 14	

Figure 5.8 Phase 6 - Outcomes of seeded patch implantation - including length of survival, notes on autopsy and images of autopsy specimen.

Figure 5.8 shows the results from Phase 6. All animals survived both gastrostomy and patch implantation surgery suggesting the model was readily reproducible – something that had been limited with the earlier models. During the implantation surgery, however, it became apparent that the seeded scaffolds were markedly mechanically weaker than those without cells. The mechanical handling properties of the scaffolds were poor and suture placement more difficult because of this. As a result of this, patches in the recellularised cells groups failed, not at the site of patch anastomosis, but centrally in the middle of the scaffold, thus suggesting an inherent problem with the recellularised patches rather than surgical technique.

All animals were successfully transitioned from gastrostomy to oral feeds on day 3 post operatively. This was uncomplicated in control animals, but in both recellularised patch groups, animals were slow to feed and swelling of the neck subsequently developed suggestive of a leak. All animals lost weight during the study period. In control animals, weight loss did not exceed 10%, the nadir weight plateaued was at day 10, and then started to increase again.

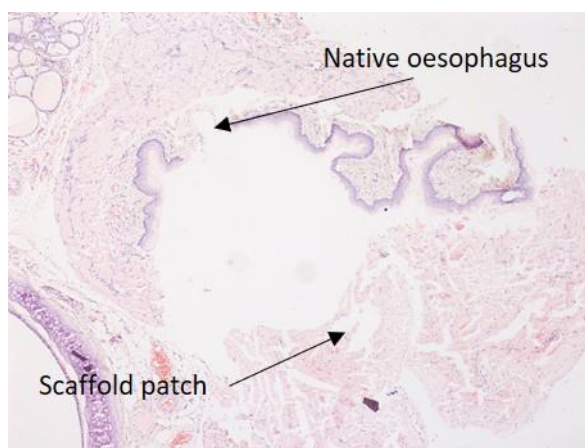


Figure 5.9 4X H&E slide of animal 6.1 – un-seeded control patch scaffold euthanised at 14 days post implantation. Some disruption of the anastomosis is observed due to the need to remove suture material to allow for cutting of blocks for histology. No mucosal ingrowth in over the patch was observed at this time point.

Histological analysis of the implanted scaffolds was planned, in order to examine the survival, engraftment and differentiation of the seeded cells. Unfortunately, due to the poor mechanical properties of the scaffolds and disruption that resulted during the time in vivo this analysis was not possible. Baseline histology of the unseeded scaffolds is shown in Figure 5.9. There is disruption of the anastomosis due to the difficulty in slicing specimens for slides where suture material was still present. Perhaps as expected the early time point of 2 weeks was not enough to see mucosal creep and coverage of the scaffold. However, histology does demonstrate that the scaffold and ECM structure is permeable allowing cells to migrate through all layers of the scaffold – even though at this early time point most of the cells within it appear to be inflammatory in nature.

Discussion

The aim of this study was to develop a reliable and reproducible small animal model for *in vivo* implantation and study of the circumferential tissue engineered oesophagus. This aim was not achievable for a circumferential model but was achieved for a patch implantation. The problems around engineered circumferential oesophageal scaffolds are well reported in larger animals with problems of strictures at later time points (Doede, Bondartschuk et al. 2009, Gaujoux, Le Balleur et al. 2010, Poghosyan, Sfeir et al. 2015). Rats, however, struggled did not appear to tolerate circumferential implantation, and those that did tended to have problems with early respiratory complications, caused by either surgical trauma, including damage to recurrent laryngeal nerve or as the result of scaffold obstruction and subsequent aspiration. As it was impossible to achieve survival with circumferential implants, it was therefore impossible to assess stricture formation, which would be expected to occur in the longer term.

Other reported studies that have used a rat model for oesophageal tissue engineering have successfully used patches to test a variety of different scaffolds including porcine SIS (Lopes, Cabrita et al. 2006) and rat gastric acellular matrix (Urita, Komuro et al. 2007). What is not clear from these studies is whether circumferential implantation was initially attempted. Both report minimal operative morbidity and neither report any stages in model development stages of the model.

The experience reported in this chapter demonstrates that care needs to be taken to minimise operative injury to surrounding structures and the need for decreased tracheal mobilisation and shorter operative times in the patch group probably helped with this. The change from using operating loupes in phases 1 – 4 to using an operating microscope in phase 5 and 6 also helped as a technique refinement.

The frequent early respiratory complications may partially be due to operative injury but also resulted from failure of the graft to act as a conduit, initially for oral feeds and later (with gastrostomy *in situ*) saliva. Consideration was given to use of a stent to support and maintain patency of the scaffold, as is described in many studies in larger animals, but given the small size of the rat oesophagus a suitable

stent could not be found, and the use of a nasogastric tube as a stent was presumed by the veterinarian would not be tolerated.

Having established the feasibility of a patch model, phase 6 was designed to assess the role of cell seeding on patch integration and as the first in vivo study of seeded scaffolds. Disappointingly, the effects of decellularization and subsequent seeding and culture led to deterioration in the mechanical structure and strength of the scaffold. Maintenance of the mechanical properties of a scaffold during all stages of decellularization, through seeding and subsequent culture are a key factor to the success of whole organ tissue engineering, especially one which is circumferential in nature such as the oesophagus. Mechanical strength appears to be maintained during decellularization with control animals in phase 6 surviving with an intact patch of scaffold implanted in the cervical oesophagus. There are several different groups that support the use of decellularised scaffolds and report adequate mechanical strength (Ozeki, Narita et al. 2006, Annor, Tang et al. 2012, Lee, Milan et al. 2017, Neethling, Puls et al. 2018) but few describe the effects of subsequent recellularization and/or culture on mechanical strength. Others have reported the deleterious effect of decellularization on mechanical properties of scaffolds compared to fresh tissue and have made attempts to re-enforce scaffolds with collagen cross linking. This is well reported in cardiac (Lehmann, Christ et al. 2017, Neethling, Puls et al. 2018), tracheal (Baiguera, Del Gaudio et al. 2014) and also oesophageal scaffolds (Bhrany, Lien et al. 2008) and improves mechanical stability. Scale is also important to take into account in that the rats scaffolds being utilised are already small in size and following the mechanical trauma of decellularization, followed by injection or surface seeding and bioreactor culture for 1 week it is not surprising that mechanical properties are altered. Handling of the recellularised patches was much more difficult than the decellularised scaffold alone.

A larger scaffold, such as the porcine oesophagus suggested for use in the clinical model for oesophageal atresia should be more robust and withstand the decellularization, seeding and culture process better than the rat scaffolds.

The second type of mechanical failure noted in the rat model is the well-reported phenomenon of collapse or obstruction of a circumferential graft or scaffold. In the majority of *in vivo* studies of oesophageal tissue engineering in larger animal models, stents have been utilised for two reasons. Firstly, a stent may help to avoid early scaffold collapse – allowing it to initially function as a conduit whilst cells are allowed to migrate across the scaffold and engraft with the hope of forming a functional graft. The second purpose for stenting is to try and prevent luminal stricturing – something that all the animal models reported with longer survival and outcomes (Badylak, Meurling et al. 2000, Doede, Bondartschuk et al. 2009, Gaujoux, Le Balleur et al. 2010, Poghosyan, Sfeir et al. 2015). Stents small enough to successfully stent the small rat oesophagus were not available or practically possible.

This model and the methods we used to try and develop it have weaknesses. Initially difficulty was experienced with getting rats to tolerate the procedure, mainly due to dissection and mobilising the trachea and hence recurrent laryngeal nerves. The option of endotracheal intubation was explored to attempt to have consistent anaesthesia and safer mobilisation of the trachea safer but following consultation and training with veterinarians it was felt the morbidity and practical difficulties of endotracheal intubation outweighed the possible benefits. Initial procedures were undertaken with 2.5x operating loupes as in clinical practice, however subsequent use of the operating microscope gave the benefits of greater magnification to improve identification of finer anatomy and on tissue handling and suture placement.

In practice, the scaffolds proved to be very fragile upon handling, and so it would have been useful to perform some form of mechanical / strength testing of the scaffolds at different stages during the decellularization, seeding and culture process before proceeding to Phase 6. This testing should focus on tensile strength testing (both axial and circumferential) and suture retention, using methods well documented across other tubular engineered tissues (Den Hondt, Vanaudenaerde et al. 2017, Aldridge, Desai et al. 2018).

Conclusions

A rat cervical implantation model, including post-operative gastrostomy feeding, for *in vivo* testing of tissue engineered oesophagus is feasible for patch insertion but challenges remain before circumferential implantation is achievable. Further attention needs to be paid to the mechanical strength and characteristic of scaffolds not just after decellularization but also importantly following seeding and culture which also affects scaffold integrity.

Chapter 6 Rabbit Model for Oesophageal Implantation

Introduction

There are several different larger animal models described for orthotopic oesophageal tissue engineering including dog (Badylak, Vorp et al. 2005), pig (Poghosyan, Sfeir et al. 2015) and rabbit (Saito, Sakamoto et al. 2000) models. In deciding which model to use, there are several factors to be considered. These including scale and size compared to planned clinical application, anatomical and physiological similarity to humans, robustness of animals, cost and animal legislation/ethical issues, such as UK Home Office requirements to replace, reduce and refine the models being used.

Dogs were used in one of the earliest models for oesophageal implantation and appear to have been a robust model with good results in terms of survival – up to 45 days following circumferential implantation (Badylak, Meurling et al. 2000, Badylak, Vorp et al. 2005). However, limited availability, cost and ethical barriers mean that use of dogs for studies such as these is more difficult if there are alternatives.

More recently, porcine models have been the most commonly used large animal model. They are more widely available in facilities in the UK and are robust. More specifically, for oesophageal replacement, pigs have the advantage of long cervical oesophagi allowing for implantations in the neck rather than requiring a thoracotomy. A recent study has demonstrated how robust the porcine model is with good survival results in pigs following circumferential cervical implantations alongside an omental patch delivered through a mid-line sternotomy (Poghosyan, Sfeir et al. 2015). Pigs, however, remain very expensive in terms of housing and post-operative care, and so their use is often restricted to the late stages (i.e. immediate pre-clinical) of a translational programme as they remain classified as a large animal.

As the clinical aim of the translational programme of work is to produce a tissue engineered oesophagus for implantation in infants with oesophageal atresia at

about 3 months of age consideration was given to use of animal model with an adult weight comparable to a human infant of that age. The rabbit, family Leporidae, order Lagomorpha, is potentially suitable, with the New Zealand white rabbit commonly used in the UK with a weight of approximately 3.5kg at 20 weeks of age. Rabbits are relatively inexpensive, easily sourced and relatively easily housed and cared for in many animal facilities. Again, the rabbit has a long neck allowing relatively easy access to the cervical trachea and oesophagus. Rabbits are the largest animal to be classified as a small animal, which from a regulatory perspective make them much easier to care for.

Rabbits are however a prey animal making them prone to being less robust than porcine or dog models. They also have specific dietary requirements (Mapara, Thomas et al. 2012), needing large amounts of fibre in their food to prevent gastrointestinal upset and potentially fatal colitis. They also routinely practice coprophagy and often groom vigorously – important to consider when planning replacing segments of the proximal oesophagus.

Aims

The aim of this study was to design a clinically translatable animal model of oesophageal replacement at a clinically relevant oesophageal diameter, suitable to test a decellularised porcine oesophageal scaffold *in vivo* and move towards its testing in a pre-clinical setting.

Methods

The project was registered, and licence granted (70/7504) by the Home Office in accordance with Animals (Scientific Procedure) Act 1986.

Scaffold Preparation

Week old piglets weighing 2.5-3.5 kg were sacrificed and fresh oesophagi were harvested and decellularised using the previously published detergent enzymatic treatment (Figure 6.1). This protocol is designed to remove immunogenic DNA from the tissue whilst maintaining extra cellular matrix.

Decellularised oesophagi were subsequently irradiated to sterilise the scaffold and were then used for implantation into the cervical oesophagus of New Zealand white rabbits.

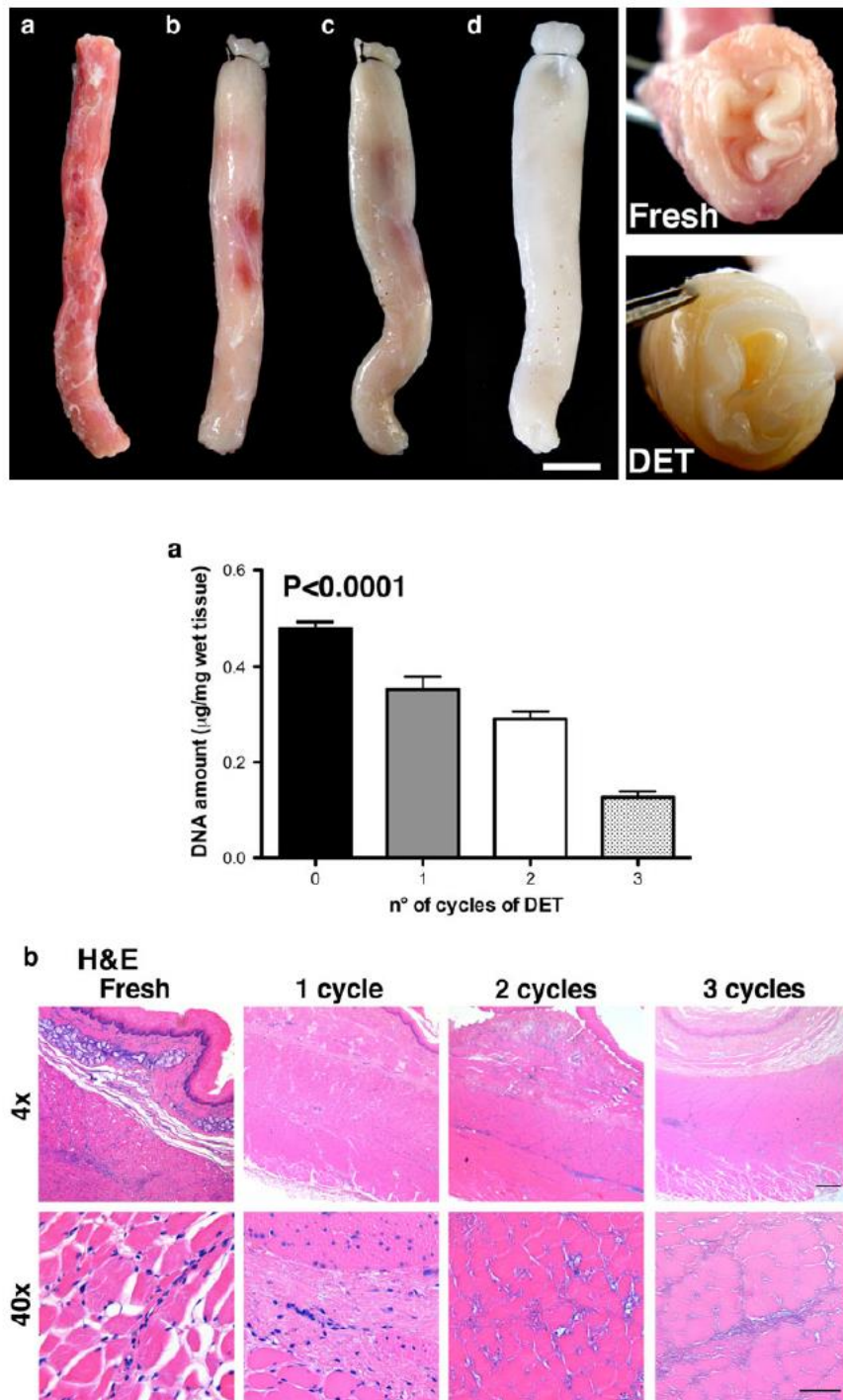


Figure 6.1 Macroscopic images of decellularisation of porcine / piglet oesophagi using DET treatment. a) DNA extraction b) H&E from Totonelli et al (2000). Scale bar 300 µm for 4x, 50 µm for 40x

,Mechanical testing

Mechanical testing of fresh native oesophagus versus decellularised oesophagi was performed alongside the in vivo experiments by a colleague.

Native samples were assayed less than 12 hours after sacrifice of donor animals. Decellularised tissue was assayed between 1 and 4 weeks after DET treatment. All samples were stored in sterile PBS at 4 °C.

Longitudinal and circumferentially oriented samples were cut to provide flat specimens, 5 mm by ≥ 15 mm, before measuring thickness in triplicate using a dial thickness gauge (Mitutoyo). Samples were inserted into a zwickiLine testing machine (Zwick/Roell) with 10.00 mm grip separation and submerged in 35-37 °C water. Samples were preconditioned with 8 cycles of loading-unloading up to 40% strain at a constant rate of 20 mm/min, before a failure test was performed with the same constant rate. Young's modulus was interpolated from the loading ramp of the failure test, as in equation below. Stress and strain at break provided the ultimate tensile stress and ultimate strain.

$$E = \frac{\sigma_{0.04} - \sigma_{0.02}}{\epsilon_{0.04} - \epsilon_{0.02}}$$

Implantation

Implantations of the scaffolds were performed in 3 phases:

1. Pilot study of single-stage implantation designs to assess feasibility of oesophageal replacement in the rabbit model
2. Modified single stage implantations
3. Two-stage implantations

Phase 1 – Pilot Study

Male New Zealand white rabbits (*Oryctolagus cuniculus*) weighing 3.0-3.5 kg; equivalent in weight to a term human baby, were anaesthetised using a combination of intramuscular ketamine and xylazine and inhaled isoflurane.

Anesthesia was maintained with isoflurane either via an anesthetic nose cone or laryngeal mask airway (v-gel®).

Rabbits were positioned prone and fur shaved. A longitudinal incision was made in the neck of the rabbit and the strap muscles spread laterally. The trachea was exposed and dissected ensuring preservation of the recurrent laryngeal nerves (Figure 6.2 A). The cervical oesophagus was then mobilised (Figure 6.2B) and controlled and a 1.6 cm circumferential segment of native oesophagus was resected.

A similar sized circumferential segment of decellularised porcine scaffold was then implanted (Figure 6.2C) and anastomosed to the native oesophagus with monofilament sutures (Figure 6.4D). The wound was closed and infiltrated with lignocaine.

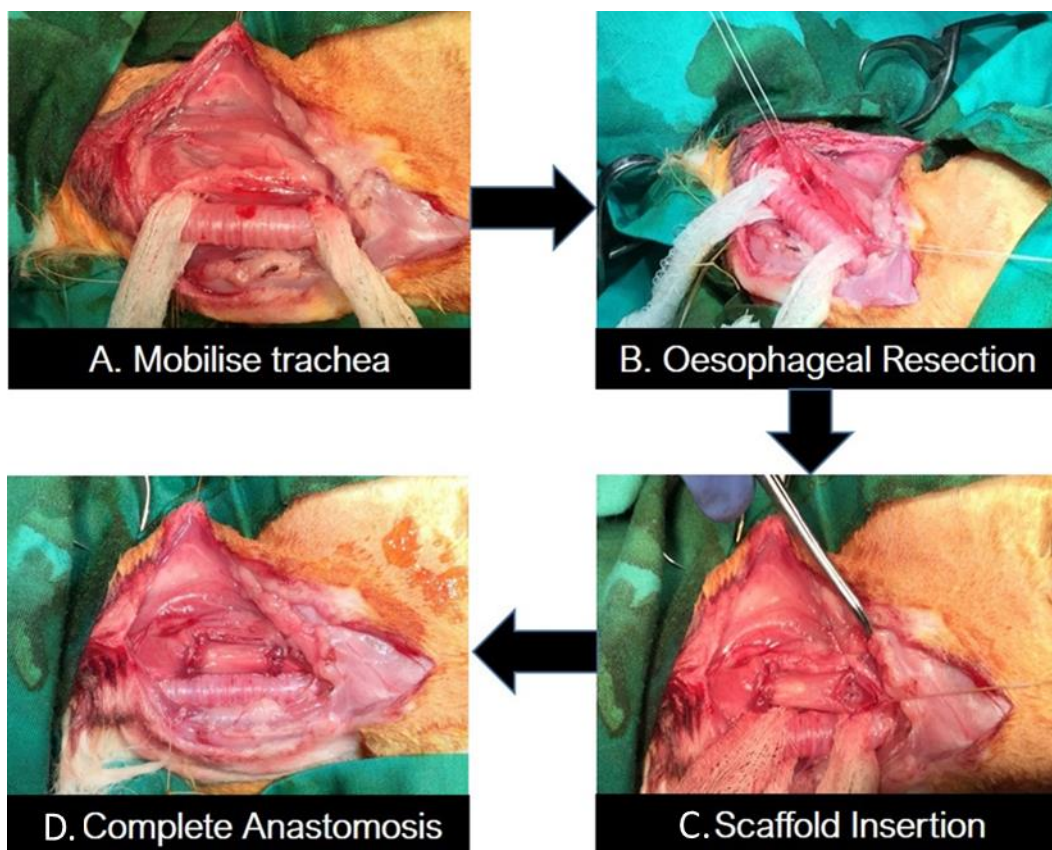


Figure 6.2 Operative stages of oesophageal implantation.

Initial longitudinal incision in the neck. A) mobilisation of the trachea, preserving the recurrent laryngeal nerves. B) Resection of 1.6m of native oesophagus. C) Insertion of decellularised scaffold. D) Completed anastomosis

Post-operatively rabbits were administered enrofloxacin antibiotic prophylaxis and carprofen and buprenorphine analgesia. Rabbits were offered a blended diet from day 1 post operatively (Oxbow[®] Critical Care Fine Grind) and were euthanised at humane endpoints according to license requirements.

Results

Early in this pilot phase, 2 animals were euthanised due to anaesthetic problems; subsequently changes were made including the addition of a laryngeal mask airway (v-gel) which gave the advantage that rabbits could be hand ventilated if there was any suggestion of respiratory distress during the procedure – especially during mobilisation of the trachea. This change led to a decrease in the number of anaesthetic problems in later phases of the study.

Two animals were euthanised early in the post-operative period due to respiratory distress. It was not possible to determine the specific cause, but it is thought to be the result of recurrent laryngeal damage or aspiration due to early obstruction of the unsupported scaffold. In those rabbits surviving the initial post-operative period, obstruction of the scaffold with food or fur was the reason for euthanasia.

In all animals surviving surgery, feeding was a problem post-operatively. Most were disinterested in feeding orally, and in those attempting to eat it was apparent that there were difficulties in swallowing. In one animal that survived to 7 days post-operatively, weight loss (>10% body weight), as a result of poor oral intake was the reason for euthanasia in line with the humane endpoint in the project license.

Following this pilot phase, a variety of modifications was implemented to address the problems encountered.

	Procedures	Survival (Days)	Reason for euthanasia
Phase 1 n = 8	<ul style="list-style-type: none"> Primary anastomosis 	0, 0 3, 9 9 7	Anaesthetic n = 2 Respiratory distress n=2 Oesophageal obstruction n =1 Weight loss n = 1

Table 6.1 Results of phase 1

Phase 2 – Main study

Gastrostomy feeding

The early problems with poor oral intake and the later issues around bolus obstruction of the scaffold lead to use designing and using a tunneled Stamm type gastrostomy. This was designed to improve post-operative nutrition by removing the requirement for early oral feeding and allowed early post-operative feeding without the risk of poor swallowing or obstruction. This also reflects what would happen in clinical practice in babies with long gap oesophageal atresia.

Following oesophageal implantation, a limited upper midline laparotomy was performed, a double ‘purse string’ suture was placed on the stomach and a 14F Pezzer catheter was tunneled through the abdominal wall, inserted into the stomach, and suture-closed securing the tube (Figure 6.3A). This catheter was chosen due to experience with its use clinically, and it is wide bore which is important given the requirement for rabbits to receive a high fibre viscous diet via the tube. The tube was then sutured to the abdominal wall before the abdomen

was closed. Early feeding immediately post operatively was then possible using a powdered diet (OxBow® Critical Care Fine Grind) that was reconstituted into a thick liquid for administration down the gastrostomy tube by syringed boluses of 20mls 4-5 times per day with 10 ml water flushes,

Alongside the gastrostomy, in order to minimise obstruction of the oesophageal scaffold, a veterinarian type collar was implemented, in order to reduce the amount of grooming and coprophagia the rabbit could perform.

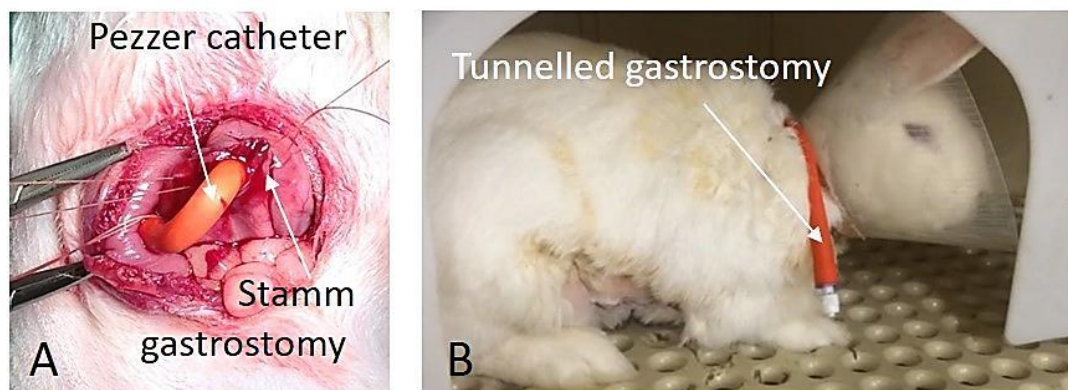

Figure 6.3 Rabbit tunnelled gastrostomy.

A) Catheter entering Stamm gastrostomy on stomach. B) Post-operative image of rabbit with gastrostomy tube visible. The animal is also wearing a collar to attempt to minimise coprophagia.

Oesophageal luminal stent

Due to the early problems that had been encountered with scaffold collapse, and the known risk of longer term strictures observed in other engineered oesophageal models, stenting of the scaffold was attempted. It was necessary to select a stent with enough rigidity to hold the scaffold open, but the stent also needed to be soft enough to avoid damage from excess pressure on the graft and healing tissues and graft. It was therefore decided to use SX-Ella bioabsorbable stents (20mm x 4 or 5mm) which we have had experience of using in clinical practice. These are hand woven from PDS suture material and slightly flared at each end to reduce

movement once in situ and maximise luminal flow through the stent (Figure 6.4). Clinically, these stents are used with an introducer to allow insertion into a narrow lumen and subsequent expansion to stent the defect. In order to avoid the difficult procedure of passing the stent via the rabbit oropharynx, oesophagus and anastomosis, the scaffolds were pre-mounted on to the stent before anastomosis was performed.

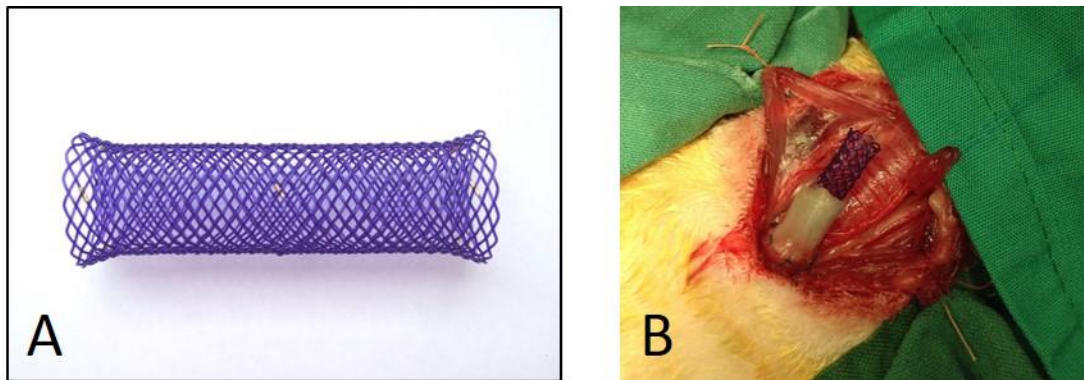


Figure 6.4 SX-Ella Bioabsorbable stent.

A) Stent demonstrating helical woven suture design and flaring. B) In vivo use – scaffold pre-mounted on stent being anastomosed across a cervical oesophageal defect

Vascularisation of muscle flap

Vascularisation of any tissue engineered organ is essential if seeded cell survival, engraftment and eventually graft function is to be achieved. However, the segmental vascular anatomy of the oesophagus make this an additional challenge. Previous studies involving patches of scaffolds implanted into the oesophagus have relied on local invasion of capillaries and angiogenesis with some success. However, those attempting full circumferential implantations have chosen different approaches to vascularise the scaffold. Badylak et al (Badylak, Meurling et al. 2000) and Gaujoux et al (Gaujoux, Le Balleur et al. 2010) both performed seeded circumferential implantations in dogs and mini pigs respectively, with no specific vascularisation strategy, and both reported some degree of neo-vascularisation of

the scaffolds. Poghosyan et al (Poghosyan, Sfeir et al. 2015) used a pig model with an omental pedicle brought through a sub-cutaneous sternal channel and although they did not specifically comment on the degree of vascularisation achieved they had good outcomes in terms of survival.

It was therefore decided to use a vascularising flap, and several options were considered including omental and sternocleidomastoid flaps, but eventually it was decided to use an anterior abdominal wall flap based on branches of the superior epigastric vessels – a technique learnt from our colleagues, in which it has been used to vascularise engineered tracheal grafts (Maughan, Butler et al. 2017). Figure 6.5 outlines the operative steps involved in mobilising the abdominal wall flap and subsequently tunneling to the neck.

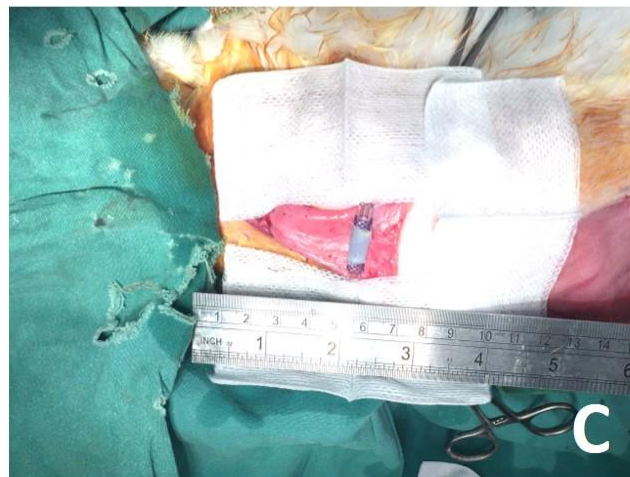
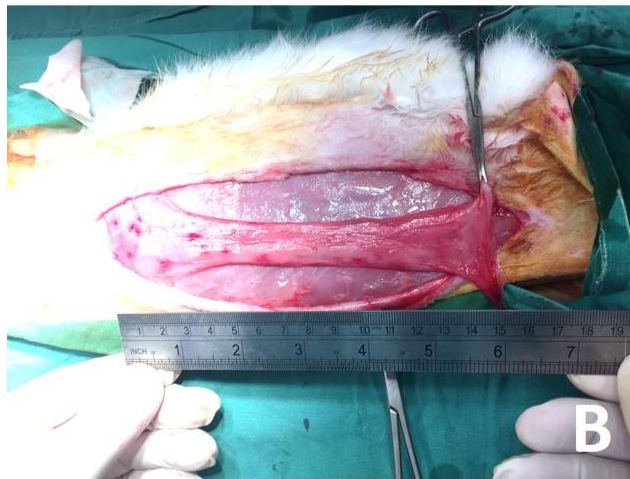
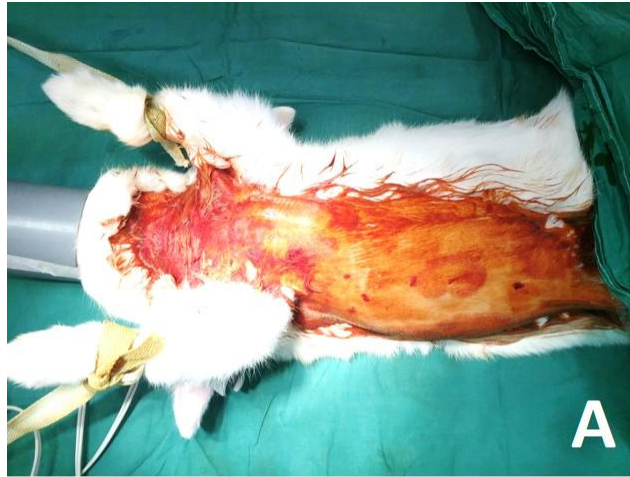
Figure 6.5 Vascularising abdominal wall flap.

A) Rabbit is shaved and prepped from neck and down the right side of the abdomen. B) A long single layer, anterior abdominal wall flap is raised taking care to avoid damage to the vascular pedicle. C) The flap is then flipped cranially and tunneled subcutaneously to the neck where the stented scaffold can be wrapped in the flap.

Micro CT

Micro CT was used in order to demonstrate the macroscopic appearance of the scaffold without the need to dissect and remove the stent - which had to be removed when cutting specimens for histology.

Micro CT methodology involved the specimen being immersed at room temperature in a solution of 10% formalin (to prevent tissue degradation) and potassium triiodide (I₂KI / Lugol's iodine, to impart tissue contrast), with a total iodine content of 63.25 mg / mL), in a 1:1 ratio for 72h prior to imaging. Before scanning, the specimen was removed from the iodine solution, rinsed in water to remove excess surface iodine and dried using gauze. The specimen was secured using foam supports, Parafilm M (Bemis) and carbon fibre rods to ensure mechanical stability during micro-CT examination. Micro-CT images of the specimen were acquired using an XT H 225 ST microfocus CT scanner (Nikon Metrology) with the multi-metal target set to Tungsten. X-ray energy and beam current settings were 80 kV and 88 μ A respectively. Exposure time was 500 ms, with the number of projections optimized for the size of the specimen (number of pixels covered within area of interest x 1.5) and one X-ray frame per projection. Projection images were reconstructed using modified Feldkamp filtered backprojection algorithms with proprietary software (CTPro3D; Nikon Metrology) and post-processed using VG Studio MAX 2.2 (Volume Graphics GmbH). Isotropic voxel size was 17.6 μ m.

Results

With the addition of new modifications to the operative approach, results in the second phase of the study were influenced by the new procedures (Table 6.2)

	Procedures	Survival (Days)	Reason for euthanasia
Phase 2 n = 15	• Oesophageal stent	0	Anaesthetic (n=1)
	• Gastrostomy		
	• Vascularising wrap (n=13)	7, 6, 4, 5, 12	Gastrostomy problems (n=5)
	• Primary anastomosis	2, 2, 16, 10, 4	Scaffold obstruction (n=5)
		11, 10	Failed wrap (n=2)
		1, 2	Unclear at autopsy (n=2)

Table 6.2 *Results from Phase 2.*

The gastrostomy was uncomplicated to place and surgery well tolerated, however multiple problems with gastrostomy tubes were experienced in the post-operative period. The main problem was around tube obstruction which was caused by the position on the animal, soft silicone nature of the tubing and also the thickness and high fibre content of the diet being given. The soft tube was well tolerated as it was comfortable for the animal but it did lead to problems if the tube became blocked as efforts to unblock it caused damage to the tube or on one occasion displacement of the tube.



Figure 6.6 Tube damage as a result of attempts to unblock gastrostomy. Whilst the silicone catheter used for the gastrostomy was soft and hence well tolerated it was prone to damage when trying to unblock.

The new vascularising wrap was again well tolerated despite the need for the long additional incision in the abdomen. The graft was relatively uncomplicated to mobilise but given it was very thin and on a narrow pedicle 2 animals suffered from necrosis of the flap leading to collections around the scaffold.

Those animals with uncomplicated recovery from surgery tended to have survival limited by bolus obstruction; a recurring problem from the initial pilot study despite the addition of gastrostomy feeding– in these animals survival ranged from 2–16 days with a median survival of 7 days. In one of these animals bolus obstruction was noted at day 5, and following discussion with the veterinarian, endoscopy was performed and a fur bolus removed. The animal survived until day 10 when aspiration pneumonia was suspected.

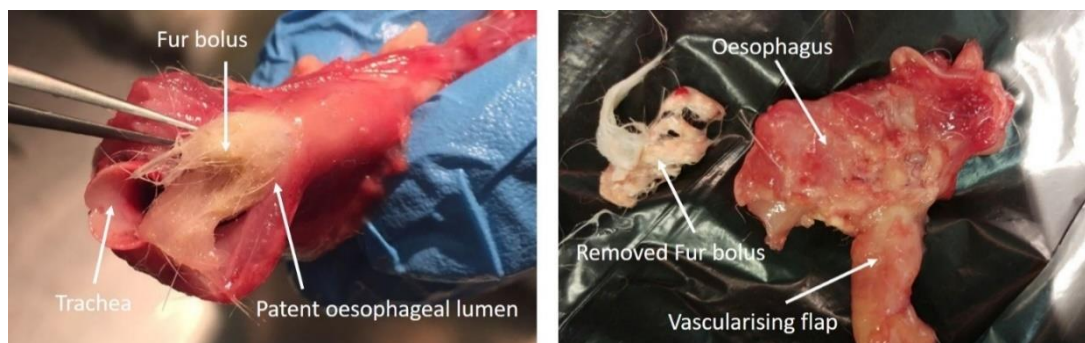


Figure 6.7 Fur bolus obstruction in autopsy specimens. It can be seen that whilst the oesophageal lumen was preserved fur from grooming led to obstruction.

Stenting appeared to make a difference in the early post-operative period, as it prevented early collapse of the scaffold, but may also have contributed to fur bolus obstruction due to its woven structure meaning fur got stuck within the stent and due to the relative decrease in luminal diameter by the presence of the stent.

The repeated bolus obstruction raised concern that strictures could be the cause or scaffold collapse. Macroscopically this did not appear to be the case at autopsy with excellent maintenance of luminal patency and micro CT scan was also demonstrated this without the need to dissect the scaffold during autopsy.

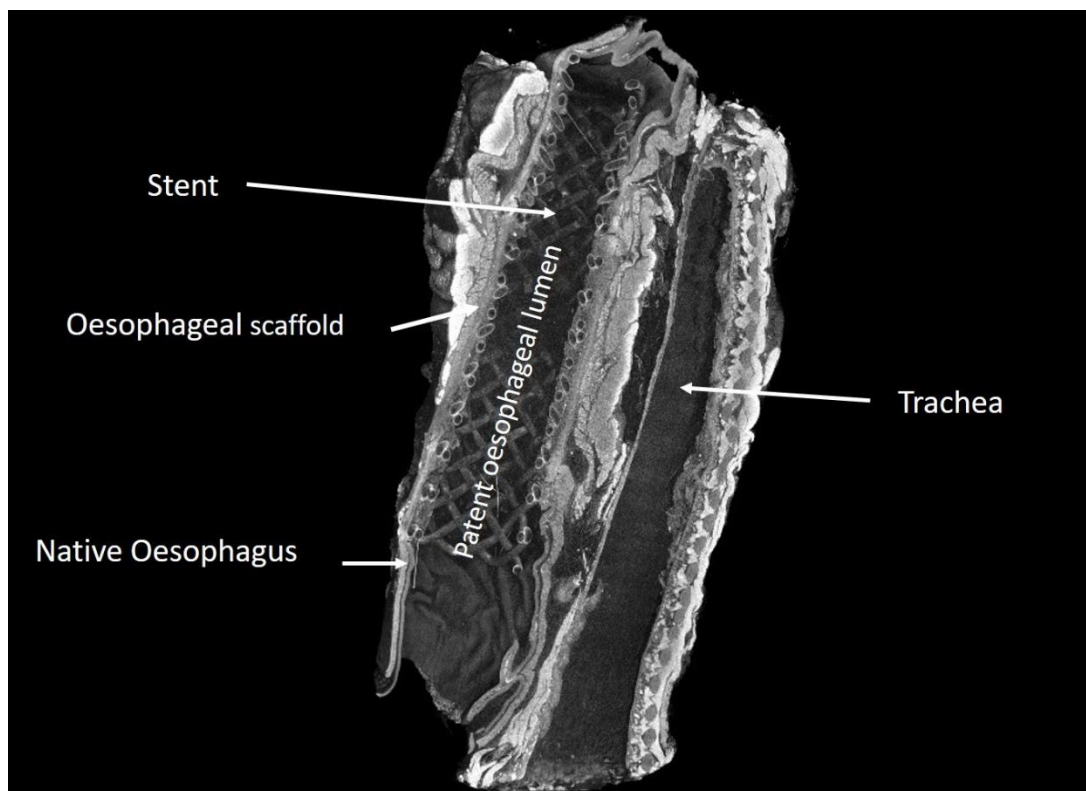


Figure 6.8 Micro CT of en bloc resection of oesophagus and trachea after 10 days in vivo demonstrating excellent luminal patency and anastomosis to native oesophagus.

Overall survival improved in phase 2, through a combination of the modifications made to the procedures and probably the increased experience in performing the procedure and post-operative management. This improved survival is demonstrated in the Kaplan Meier survival curve below.

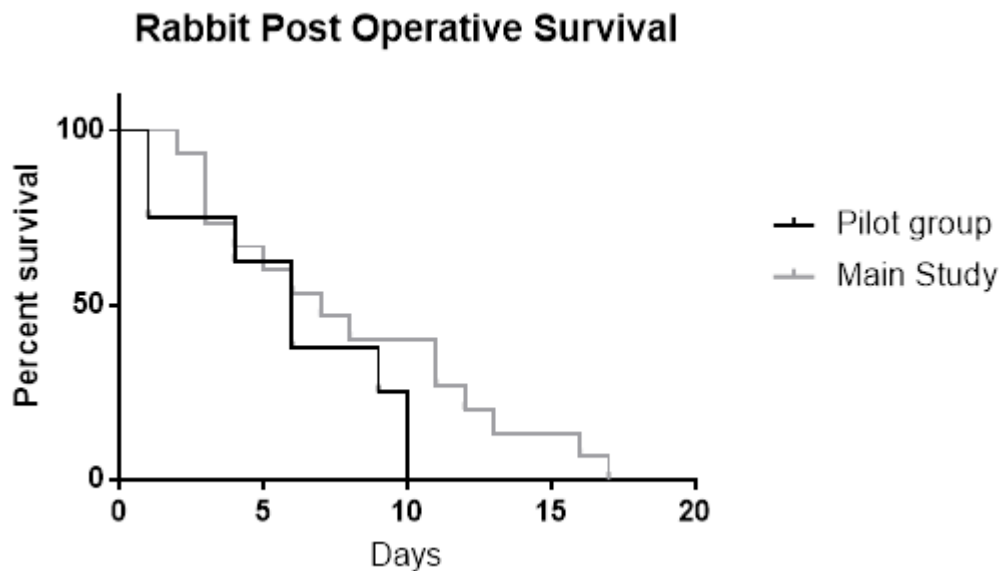


Figure 6.9 Post operative survival in pilot group and main study group

Whilst the main focus of the study was model development, histological examination was useful to assess the ability for cells to infiltrate the scaffold and to look for evidence of neovascularisation. Figure 6.10 shows histology from rabbits at various different endpoints. Transverse sections show preservation of the ECM of the oesophageal scaffolds and infiltration of mainly inflammatory cells. The middle panel shows the anastomosis intact after 16 days and integration with the native oesophagus.

Endpoints in term of survival were, as in the rat study, disappointing and this obviously has an impact on the histological results. However, it is again evident that the decellularised scaffolds do allow integration of cells across the ECM as can be seen in figure 6.10 A and B and evidence of good integration of the scaffold at the anastomosis site as seen in 6.10C.

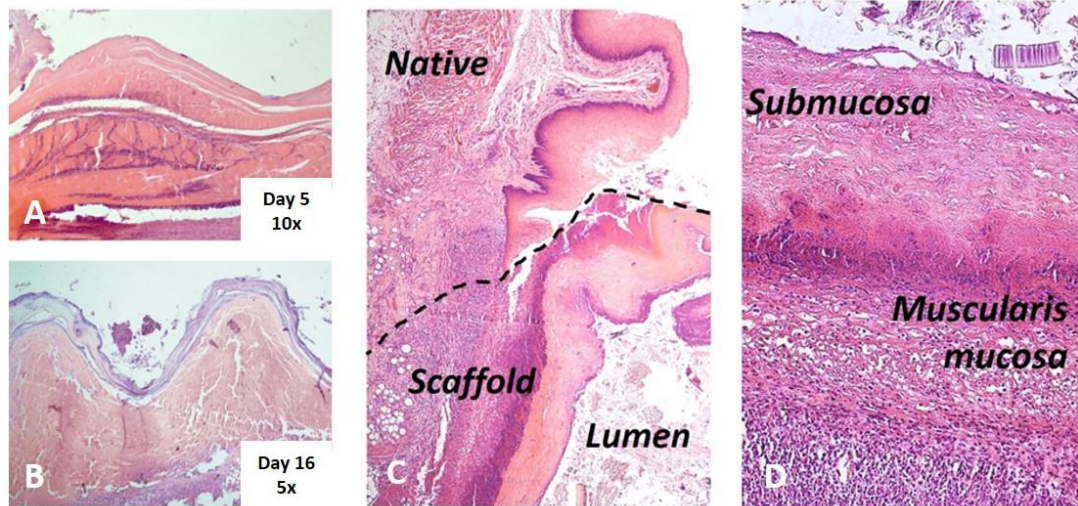


Figure 6.10 Histology of porcine scaffolds following implantation in cervical oesophagus of rabbits with vascularising flap.

Longitudinal sections from animals euthanised at different time points. A) Day 5 10X showing inflammatory infiltrate across muscularis layer. B) Day 16. C) Day 16 showing anastomosis. D) Day 16 20 X

Phase 3 - Two stage model

In order to try to further increase vascularisation of the scaffold it was decided to test the feasibility of a two stage model. This had been successful for our colleagues working on tissue engineering of the trachea and their approach was therefore adopted and redesigned for use with the oesophageal scaffolds. We also wanted to assess as in the rat model if there was any benefit to seeding the scaffold with epithelial cells.

First decellularised scaffold were irradiated and then surfaced seeded with ROEC and cultured in static conditions for 1 week. Decellularisation and subsequent seeding was performed using the same techniques as in the rat and the two stage model then involved initial implantation of the seeded scaffold in the same muscular vascularising flap as for a single stage operation. This was mobilised similarly, delivered via a subcutaneous tunnel to the neck of the rabbit and secured in place (Figure 6.11 a - c).

Rabbits were immunosuppressed from this point with tacrolimus (0.08mg/kg per day intramuscular). The scaffold was left in the neck for 2 weeks to allow neovascularisation of the scaffold. At this point, the neck was re-opened, the newly vascularised scaffold and wrap were mobilised (Figure 6.10 d) and following resection of a 2 cm segment of cervical oesophagus, the scaffold and wrap were implanted and anastomosed with the native oesophagus in an orthotopic position (Figure 6.11e) and subsequently a gastrostomy was inserted as per the previously described technique.

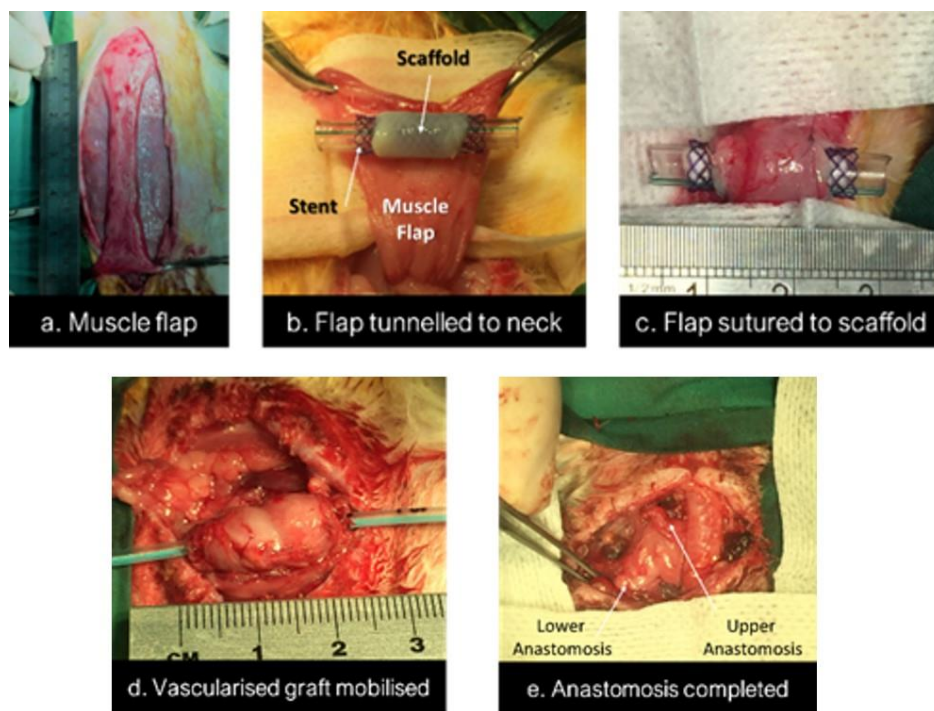


Figure 6.11 Two stage model.

A) Muscle flap prepared on superior epigastric pedicle. B) Flap tunneled to neck and stented scaffold wrapped in flap and C) Sutured in place. D) Stage 2 - vascularised graft mobilised, and implanted in a 1.6 cm defect created in the cervical oesophagus and anastomosed.

Results:

	Procedures	Survival (days)	Reason for euthanasia
Two stage model n = 4	<ul style="list-style-type: none">• Primary insertion of stented scaffold in vascularising wrap• Delayed anastomosis• Gastrostomy	1	Anaesthetic n =1
		1	Poor scaffold n = 1
		4	Infection n = 1
		7	Obstruction n = 1

Table 6.3 Outcomes from the 2 stage model.

One rabbit was lost due to anesthetic complications at the second stage, and survival of one animal was limited due to poor scaffold quality, which prevented a safe anastomosis at the second stage. Two animals that survived both stages had, at the second stage, scaffold and muscle wraps that appeared macroscopically well vascularised (Figure 6.11 A) and this offered the benefit of improved suture retention during the anastomosis. There was however some over granulation in the lumen of the scaffold despite a plastic tube had been left through the scaffold between the two stages (Figure 6.11 B). Survival was again then limited by obstruction. Histology confirmed the presence of micro neovascularisation within the muscularis and also the luminal over granulation without any evidence of survival of the seeded epithelial cells (Figure 6.12 C and D).

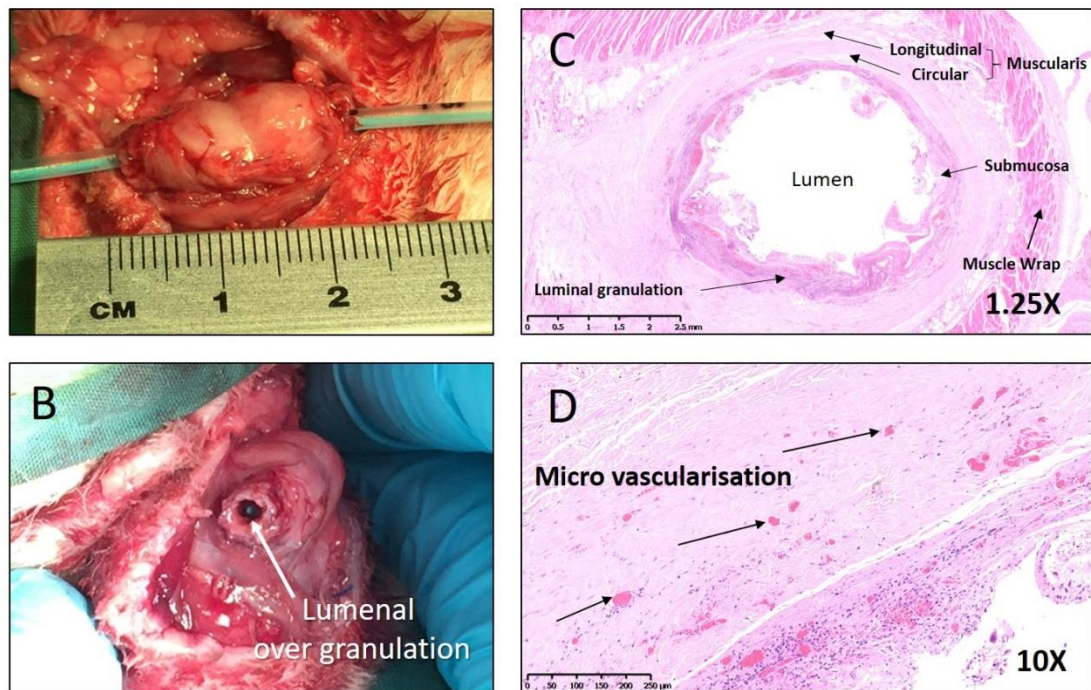


Figure 6.12 Second stage and histological results. A) Mobilised muscle wrapped scaffold showing macroscopically excellent vascularisation, B) Over granulation within the lumen of the scaffold, C) and D) different magnification of H&E slides of scaffold (7 days post 2nd stage) sliced transversely across lumen.

Mechanical Testing

Mechanical testing was performed alongside the in vivo experiments to formally assess the physical properties of the scaffolds. Figure 6.13 shows there was no significant difference between fresh and decellularised scaffolds in terms of stiffness, strength and strain.

This suggests the tissue maintains its mechanical properties through the specific DET protocol used for decellularisation and makes it mechanically equivalent to fresh tissue for surgical implantation.

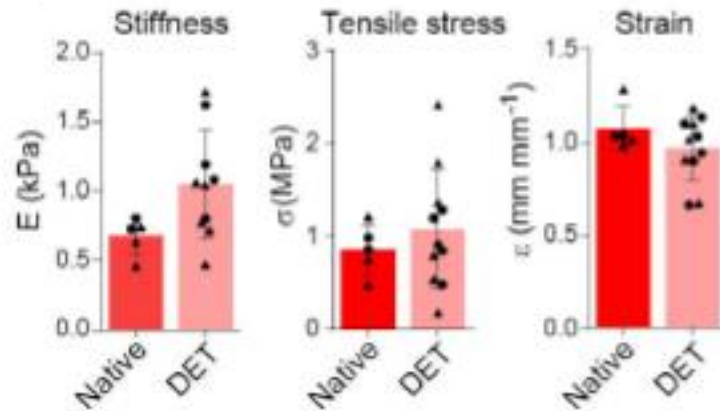


Figure 6.13 Biomechanical analysis of native and decellularised samples derived from proximal (circle) or distal (triangle) portions of the oesophagi.

Stiffness (native n = 5; DET n = 10), ultimate tensile stress (native n = 5; DET n = 11) and ultimate strain (native n = 5; DET n = 11) were evaluated. Bars indicate the mean \pm SD, circles and triangles represent biological replicates.

Discussion

Whole organ tissue engineering may offer a solution for a variety of conditions where organ replacement is required. Encouraging clinical results have been obtained from tissue engineered tracheal replacement (Elliott, De Coppi et al. 2012) but such translation from lab to patient has yet to be possible for the tissue engineered oesophagus.

These results demonstrate that oesophageal replacement with a circumferential decellularised porcine scaffold maybe feasible in a rabbit model but have several limitations which precludes its use for further *in vivo* studies. The innovative process of model design and modifications made has led to an improved understanding of the challenges the tissue engineered oesophagus may bring in different large animal models and eventually in the clinical setting and more importantly how these challenges may or may not be overcome.

Scaffold selection for tissue engineering is the first step in designing a tissue engineered oesophageal replacement and is a much debated subject (Jensen, Blanchette et al. 2015, Poghosyan, Sfeir et al. 2015, Park, Choi et al. 2016, Lee, Milan et al. 2017). Our group favors a decellularised xenogeneic scaffold, and has demonstrated *in vitro* the benefits of this approach including excellent maintenance of ECM structure and the resulting improvement in engraftment of seeded stem cells (Urbani, Camilli et al. 2018). The *in vivo* results obtained also demonstrate that alongside providing an excellent stem cell niche, the physical properties of decellularised porcine oesophageal scaffolds may make them suitable for successful implantation in larger animals.

The mechanical testing results are helpful in suggesting the decellularisation process does not negatively affect the mechanical strength of scaffolds however we do not have the results of mechanical testing after seeding and culture which may have a negative effect initially.

Scaffolds generally handled well during implantation and better than the decellularised rat scaffolds and demonstrated good suture retention. No animals in the main study group were lost due to scaffold failure or rupture, supporting the use of decellularised scaffolds when suitable surgical modifications are applied such as stent usage and vascularizing flaps. This is contrary to our findings in our rats studies. However it is important to note that only scaffolds in the 2 stage rabbit studies had been through both decellularisation and the seeding / culture process and in only one of these cases was there any problem with scaffold quality.

Maintenance of the lumen of tubular oesophageal scaffolds is the most frequently reported complication that limits the long term outcome of *in vivo* models (Doede,

Bondartschuk et al. 2009, Gaujoux, Le Balleur et al. 2010, Poghosyan, Sfeir et al. 2015). This problem was also encountered in the short term with early scaffold collapse in our pilot group which led to the use of bio-degradable stents at implantation. Gaujoux et al used non-absorbable polyester covered stents in a pig model, implanting allogenic aorta as the oesophageal graft and reported several complications from stent migration (Gaujoux, Le Balleur et al. 2010). Therefore, biodegradable PDS stents, which we have clinical experience using after tissue engineered tracheal implantation and tracheal stenosis were used. Pre-mounting the scaffold onto the stent and securing it in place resulted in no early scaffold migration. The benefit of an uncovered stent is that over time it becomes integrated avoiding migration, but this must be balanced in the longer term with the risk of granulation tissue over growing the stent into the lumen – as was seen in the two stage model. Appropriate stent position without migration is well demonstrated in the micro CT images (Figure 6.8).

Stent usage prevented the early collapse of the scaffold maintaining luminal patency. Scaffold obstruction in those animals surviving to later time points was then a result of the coprophagic and fur ingestion behavior typical of rabbits, which adhered to the stent resulting in obstruction. This is an obvious limitation of the model and not something that is expected to be encountered in porcine models or would be seen in clinical practice.

In the longer term, stricturing may also be a problem with our decellularised graft as it is reported with other types of tissue engineered grafts and importantly in clinical practice - almost universally after repair of complex OA. We therefore anticipate the need for a combination of biodegradable stenting and balloon dilatation of grafts and anastomoses in future in vivo models and then in clinical practice. Many factors influence the formation of strictures both in vivo and in clinical practice including scaffold material, anastomotic tension, vascularity, and potentially the survival of any seeded cells.

A 1.6 cm defect in the cervical oesophagus could be replaced without tension on either anastomosis. Whilst this is far from being able to replace a complete neonatal oesophagus, in practice many patients with long gap oesophageal atresia

simply need an extra couple of centimeters of length to facilitate anastomosis which would avoid the need for lengthening procedures with associated tension or oesophageal replacement and its associated morbidity.

Vascularisation of whole tissue engineered organs remains a challenge, especially with the segmental blood supply of the native oesophagus. Various different strategies have been suggested including the use of vascularising pedicles or flaps and also the use of angiogenic factors such as VEGF applied to scaffolds. We chose to use an anterior abdominal wall muscle flap – as has previous been described for tracheal (Delaere, Liu et al. 1995, Den Hondt, Vanaudenaerde et al. 2016) and oesophageal (Saito, Sakamoto et al. 2000) scaffold vascularization. This vascularizing muscle flap is easily harvested from the rabbit anterior abdominal wall and avoids the morbidity of thoracotomy to deliver an omental flap, which would be poorly tolerated in rabbits. The flap also provides mechanical support to the implanted scaffold and both anastomoses. Our single stage implantation showed little neovascularization on histology, presumably as a result of limited survival time, usually as a result of luminal obstruction. The two-stage model with pre-vascularisation in the flap before orthotopic implantation at a second stage demonstrated macroscopically and confirmed histologically evidence of neovascularization after 2 weeks *in vivo*. Larger, more robust, models have used transthoracic omental flap successfully (Poghosyan, Sfeir et al. 2015) and in clinical practice this may be a more useful approach given that anastomoses would need to be intrathoracic rather than cervical, and clinical experience already exists from tracheal replacement (Elliott, De Coppi et al. 2012).

The benefit of pre vascularization in term of developing a new blood supply for scaffolds has been demonstrated *in vivo* for both tracheal and oesophageal tissue engineering (Hamaji, Kojima et al. 2014, Chung, Ju et al. 2018). Our results support this with histological evidence of neovascularisation after 2 weeks in the muscle flap. However, pre-attachment to the vascularising flap did make performing the circumferential anastomosis more difficult in some animals; this was managed with slight modification in anastomotic technique. Pre-vascularization alongside the seeding with epithelial cells also increased deposition of granulation tissue into the

lumen of the scaffold. Attempts were made to minimise this by mounting the stented scaffold on a short section of plastic tube to preserve the lumen. This over granulation however contributed to the early obstruction of the pre vascularized scaffolds after orthotopic implantation. The maintenance of luminal patency seen in this study must be addressed if a two stage approach is to be used but the practicality of two stage surgery in clinical practice may limit its use.

We only used seeded scaffold in our 2 stage model involving 4 animals and therefore it is difficult to draw many conclusions from such a small group – especially when survival was limited. It did not appear that epithelial survival was achieved but a granulation type reaction was seen and needs further investigation when a more robust and longer-term model is achieved and has been described in other circumferential oesophageal models (Poghosyan, Sfeir et al. 2015), by our colleagues looking at tracheal engineering in the similar rabbit model (Maughan, Butler et al. 2017) and we see regularly in clinical practice at sites of anastomoses.

This study of large animal oesophageal tissue engineering, model development and modification has added useful and encouraging data to the existing literature and experience. It has demonstrated that the rabbit model whilst useful in early experimental development is not a robust enough model to move forward with pre-clinical work. Its usefulness as a comparable size to the neonatal patient is limited by its fragility as a surgical model and in the longer term by the unavoidable ingestion of fur and faeces leading to luminal obstruction as seen in a similar Japanese study (Saito, Sakamoto et al. 2000).

The suitability of decellularised porcine scaffolds for oesophageal implantation was confirmed, but the need for early scaffold support with absorbable stenting is recognised. It appears that vascularising flaps will play a role in the future development of further pre-clinical models but probably utilising a single stage approach. It appears the porcine model is the most favorable next stage of development. The larger size of even the mini pig (35-45kg) makes the clinical comparison to neonatal patients more difficult but the benefit of a more robust animal (Gaujoux, Le Balleur et al. 2010, Poghosyan, Sfeir et al. 2015) should lead to

the ability to obtain longer survival, and allow the implantation of recellularised scaffolds.

Conclusions

Whilst a rabbit model for in vivo implantation of tissue engineered oesophagi maybe feasible it is not robust enough to allow suitable long term survival with outcomes limited by obstruction of the scaffold and respiratory complications despite the use of intraluminal stents. A more robust and reproducible large animal model is required.

Discussion and Conclusions

Long gap and complex OA remain a therapeutic challenge. This doctorate aimed to look retrospectively at the long-term outcomes and morbidity of long gap OA treated with GT and then to also look forward working on future therapeutic options to replace the existing strategies in the form of tissue engineering.

The work done collaborating with TOFS the UK patient support group is one of the first studies of its kind – being patient / parent led, focusing on patient reported outcome measures (PROMS) and supported by ourselves as health care researchers. This model of patient involvement in study design, recruitment and delivery is crucial if we are to accurately capture those outcomes that are important to patients not just us as surgeons.

This study adds more data to the increasingly recognised long-term morbidity and symptom burden of oesophageal atresia including both gastrointestinal and respiratory problems. Importantly it also adds to the limited data regarding the quality of life after OA and its effect on different areas of everyday quality of life measures such as education and work of patients and parents. This is an area of increasing interest across the spectrum of congenital conditions (Kyrklund, Pakarinen et al. 2017, Amin, Knezevich et al. 2018) that we as paediatric surgeons treat in infancy and have a poor understanding of the long-term outcomes into adulthood. As we have better data and understanding on the true long term outcomes and morbidity of such conditions – and with it the increasing realisation that these patients will have a ‘life time’ ahead of them, it demands that paediatric surgeons focus on long term morbidity and PROMS as much as the short term outcomes that have been traditionally reported such as leak or stricture rates.

GT for OA appears have significant and previously under reported morbidity including gastrointestinal, respiratory, haematological and mental health problems. This affects quality of life which again are important often previously ignored outcomes for procedures done in infancy that need to last a lifetime. The new findings of adulthood anaemia, mental health problems and need for redo surgery in adulthood were unexpected and make us aware of the lack of long-term

outcome data we have across paediatric surgery and the potential unreported problems our patients suffer from in adulthood.

Unfortunately, the relatively small number of patients needing GT for OA and the lack of good data make comparison between techniques for oesophageal replacement difficult but in terms of predicting outcomes for GT and counselling families, this new data is important. Regarding the different choices for replacement that exist I think at present it is impossible to design and power any form of study to accurately compare the procedures and their long-term outcomes. It is also apparent from our study that outcomes are influenced by so many factors such as primary or secondary procedures, co-morbidities, age at repair etc that any attempts to perform multi variate analysis on such small numbers would be futile. Therefore when considering which replacement to perform in suitable cases of long gap OA, at present a common-sense approach must be taken, taking into account the current 'best evidence' but also practical factors such as surgeon experience, operative reproducibility, and quality of clinic follow up. This then mandates prospective data collection, audit and scrutiny of results by each surgeon performing GT in the UK. These results and their application have been one of the main drivers behind my development of a national British Association of Paediatric Surgeons group, focusing on the discussion of the management of such complex upper gastrointestinal cases. It is hoped this will help improve standards of care, allow for collaborative research and importantly lead to a national registry of such cases into order to facilitate future comparison of outcome data.

The results of both long-term follow up studies also mandate longer term follow up of patients with OA, especially those repaired with GT. Currently the longer term follow up of patients with OA into adulthood is not mandated and is therefore variable between centres. There is debate internationally about how these patients should be followed up (Connor, Springford et al. 2015, H, Gischler et al. 2016, Krishnan, Mousa et al. 2016) with the main focus of attention across the literature being screening for Barrett's oesophagus (Deurloo, Ekkelkamp et al. 2005, Schneider, Michaud et al. 2013, Krishnan, Mousa et al. 2016, Schneider, Gottrand et al. 2016). Our results don't add much to the debate around Barrett's but do lend

weight the mandated follow up of all patients following GT due to the frequency and complexity of their morbidity and do suggest the need for careful planning at transition due to the wide variation of morbidity which may require multidisciplinary input from gastroenterology, surgeons, respiratory physicians and mental health specialist. This process should follow the guidelines from the National Institute of Clinical Excellence on transitional care (NICE guideline NG43 <https://www.nice.org.uk/guidance/ng43>).

What is clear from the first section of the thesis is that GT is still not a perfect choice for oesophageal replacement, and we need on-going efforts to develop options such as tissue engineering to create a less morbid option.

Due to the innovative and relatively new field of oesophageal tissue engineering the literature to date does not support the use of one specific animal model and given the need for a suitably sized animal model to represent the clinical application of oesophageal atresia in the infant we explored different options for such a model.

To date most groups studying oesophageal tissue engineering with a rat model have described success with a patch model rather than a circumferential model (Lopes, Cabrita et al. 2006, Urita, Komuro et al. 2007) and our results demonstrate why patch methods are preferred. The technical difficulty involved in circumferential implantation and resulting morbidity, even with gastrostomy fed animals meant survival would not be long enough to give meaningful results for in vivo studies. Lopes, Cabrita et al (2006) had similar findings using circumferential porcine SIS scaffolds as either a patch or circumferential graft. The circumferential group had limited survival due to oesophageal dysfunction. We hypothesised that the use of decellularised oesophagi with modifications such as gastrostomy use would lead to improved outcomes, but this was not the case.

The rabbit model was also disappointing in terms of its limited survival. We hypothesised that the rabbit would be a good model to mimic infant oesophageal replacement due to the similarities in size and anatomy. The operative procedures performed in the cervical oesophagus of the rabbit did provide an excellent clinically applicable model however it was the after care of the animals that made

the rabbit model unfeasible for longer term studies. The combination of the relatively dysfunctional segment of implanted scaffold, the rabbits need to groom, ingest fur and coprophagia led to unmanageable problems with scaffold obstruction which was not helped by stenting or gastrotomy use which came with its own morbidity.

Moving forward in terms of model development it is important that a more robust and reproducible model is found and this is most likely to be the minipig. The most recent study with best long term outcomes use this model (Poghosyan, Sfeir et al. 2015) but it is important to realise that the term 'mini' pig actually represents animals of 35-45 kg which are less consistent with the clinical application of infant oesophageal replacement. However, in order to demonstrate proof of concept and feasibility there may be benefit of performing *in vivo* studies in a larger model and then scaling it down. This should give the benefit of longer survival and the ability to study the fate of seeded cells.

The proposed porcine model would again involve implantation of circumferential scaffolds into the cervical oesophagus. Decellularised scaffolds would be seeded with epithelial cells and mesangioblasts with fibroblasts as we have described *in vitro*. Scaffolds would be pre mounted on PDS stents before seeding and culture to maximise mechanical support through this process. This would then then be implanted in either one or two stages into a cervical oesophageal defect. In terms of vascularising flaps the literature suggests an omental flap may be the best option and would allow for easy implantation for *in vivo* culture if performing a 2 stage approach.

Gastrotomy insertion at stage 2 could be of benefit as it is well tolerated in pigs (Birck, Vegge et al. 2015, Glenn, Bruns et al. 2017) and gives the benefit of avoiding early post-operative oral feeding thereby giving the anastomosis time to heal and also avoid early disruption of seeded epithelial cells if performing a single stage approach.

The choice of scaffold in tissue engineering remains a point of debate and our group supports the use of decellularised scaffolds due to the excellent properties in

terms of cell engraftment, migration and differentiation which the decellularised scaffold with its preserved ECM delivers (Urbani, Camilli et al. 2018). However, as we move from *in vitro* work to *in vivo* models the operative and post operative practicalities of needing a mechanically robust scaffold become more important. The rat studies raised the issue of the effects not only of decellularisation on mechanical strength but also the effects of seeding and subsequent culture. The rabbit studies only used seeded and cultured scaffold in 4 animal and therefore it is difficult to draw conclusions about mechanical properties from this.

Before moving to a porcine model a further more robust set of mechanical testing must be performed to compare scaffold at decellularisation, after seeding and then after culture as discussed. If this demonstrates there is significant deterioration in scaffold strength during the process then the protocol and timing for these may need to be changed accordingly. The other alternative would be to provide additional support to the scaffold such as cross linkage which has been shown to significantly increase burst pressures of oesophageal acellular scaffolds (Bhrany, Lien et al. 2008) or development of composite scaffolds with decellularised oesophagi centrally and some form of synthetic supportive scaffold around this.

Whilst the results from the tissue engineering studies in this thesis were disappointing the process of developing these models has resulted in important learning for the next stages in the process of moving towards pre-clinical studies and the possible realisation of tissue engineered oesophagus as a therapeutic option for oesophageal replacement in OA. Whilst this exploration for alternative therapeutic options continues it is essential that we continue to focus on identifying and managing the long-term morbidities of current treatments such as gastric transposition, and improving transitional care for paediatric patients as they move into adult services.

Chapter 7 Publications and Presentations

Outcomes in Adulthood of Gastric Transposition for Complex and Long Gap Esophageal Atresia. **Hannon E**, Eaton S, Curry JI, Kiely EM, Spitz L, De Coppi P. *J Pediatr Surg*. 2019 Aug 29

Multi-stage bioengineering of a layered oesophagus with in vitro expanded muscle and epithelial adult progenitors. Urbani L, Camilli C, Phylactopoulos DE, Crowley C, Natarajan D, Scottoni F, Maghsoudlou P, McCann CJ, Pellegata AF, Urciuolo A, Deguchi K, Khalaf S, Aruta SF, Signorelli MC, Kiely D, **Hannon E**, Trevisan M, Wong RR, Baradez MO, Moulding D, Virasami A, Gjinovci A, Loukogeorgakis S, Mantero S, Thapar N, Sebire N, Eaton S, Lowdell M, Cossu G, Bonfanti P, De Coppi P. *Nat Commun*. 2018 Oct 16;9(1):4286

A patient led, international study of long term outcomes of esophageal atresia: EAT1. Svoboda E, Fruithof J, Widenmann-Grolig A, Slater G, Armand F, Warner B, Eaton S, De Coppi P, **Hannon E**. *J Pediatr Surg*. 2018 Apr;53(4):610-615

Outcomes in adulthood of gastric transposition for oesophageal atresia. British Association of Paediatric Surgeons Congress. London, July 2017.

Oesophageal tissue engineering & advantages of staged implantation in a large animal model.

British Association Paediatric Surgeons Prize Session. London, July 2017.

Xenogeneic decellularised oesophageal transplantation is achievable in a large animal model.

American Pediatric Surgical Association. San Diego, USA, May 2016

Received APSA Prize for Innovation

Cell Delivery Optimization in a Tissue Engineered Scaffold for the Reconstruction of Muscle layer of the Gut.

British Association of Paediatric Surgeons Congress. Cardiff, July 2015.

Chapter 8 References

Adams, S. H., V. Esser, N. F. Brown, N. H. Ing, L. Johnson, D. W. Foster and J. D. McGarry (1998). "Expression and possible role of muscle-type carnitine palmitoyltransferase I during sperm development in the rat." Biol Reprod **59**: 1399-1405.

Ahmed, A. and L. Spitz (1986). "The outcome of colonic replacement of the esophagus in children." Prog Pediatr Surg **19**: 37-54.

Aldridge, A., A. Desai, H. Owston, L. M. Jennings, J. Fisher, P. Rooney, J. N. Kearney, E. Ingham and S. P. Wilshaw (2018). "Development and characterisation of a large diameter decellularised vascular allograft." Cell Tissue Bank **19**(3): 287-300.

Allin, B., M. Knight, P. Johnson, D. Burge and C. Baps (2014). "Outcomes at one-year post anastomosis from a national cohort of infants with oesophageal atresia." PLoS One **9**(8): e106149.

Amin, R., M. Knezevich, M. Lingongo, A. Szabo, Z. Yin, K. T. Oldham, C. M. Calkins, T. T. Sato and M. J. Arca (2018). "Long-term Quality of Life in Neonatal Surgical Disease." Ann Surg **268**(3): 497-505.

Angotti, R., F. Molinaro, C. Noviello, G. Cobellis, A. Martino, C. Del Rossi, A. Bianchi and M. Messina (2016). "Gastric transposition as a valid surgical option for esophageal replacement in pediatric patients: experience from three Italian medical centers." Gastroenterol Rep (Oxf).

Annor, A. H., M. E. Tang, C. L. Pui, G. C. Ebersole, M. M. Frisella, B. D. Matthews and C. R. Deeken (2012). "Effect of enzymatic degradation on the mechanical properties of biological scaffold materials." Surg Endosc **26**(10): 2767-2778.

Awad, K. and B. Jaffray (2017). "Oesophageal replacement with stomach: A personal series and review of published experience." J Paediatr Child Health.

Badylak, S., S. Meurling, M. Chen, A. Spievack and A. Simmons-Byrd (2000). "Resorbable bioscaffold for esophageal repair in a dog model." J Pediatr Surg **35**(7): 1097-1103.

Badylak, S. F., D. A. Vorp, A. R. Spievack, A. Simmons-Byrd, J. Hanke, D. O. Freytes, A. Thapa, T. W. Gilbert and A. Nieponice (2005). "Esophageal reconstruction with ECM and muscle tissue in a dog model." J Surg Res **128**(1): 87-97.

Baiguera, S., C. Del Gaudio, E. Kuevda, A. Gonfiotti, A. Bianco and P. Macchiarini (2014). "Dynamic decellularization and cross-linking of rat tracheal matrix." Biomaterials **35**(24): 6344-6350.

Bax, N. M. and D. C. van der Zee (2007). "Jejunal pedicle grafts for reconstruction of the esophagus in children." J Pediatr Surg **42**(2): 363-369.

Bhrany, A. D., C. J. Lien, B. L. Beckstead, N. D. Futran, N. H. Muni, C. M. Giachelli and B. D. Ratner (2008). "Crosslinking of an oesophagus acellular matrix tissue scaffold." J Tissue Eng Regen Med **2**(6): 365-372.

- Birck, M. M., A. Vegge, S. G. Moesgaard and T. Eriksen (2015). "Single port laparoscopic long-term tube gastrostomy in Gottingen minipigs." Lab Anim **49**(3): 220-227.
- Burge, D. M., K. Shah, P. Spark, N. Shenker, M. Pierce, J. J. Kurinczuk, E. S. Draper, P. R. Johnson, M. Knight and S. British Association of Paediatric Surgeons Congenital Anomalies Surveillance (2013). "Contemporary management and outcomes for infants born with oesophageal atresia." Br J Surg **100**(4): 515-521.
- Burgos, L., S. Barrena, A. M. Andres, L. Martinez, F. Hernandez, P. Olivares, L. Lassaletta and J. A. Tovar (2010). "Colonic interposition for esophageal replacement in children remains a good choice: 33-year median follow-up of 65 patients." J Pediatr Surg **45**(2): 341-345.
- Campbell, F., K. Biggs, S. K. Aldiss, P. M. O'Neill, M. Clowes, J. McDonagh, A. While and F. Gibson (2016). "Transition of care for adolescents from paediatric services to adult health services." Cochrane Database Syst Rev **4**: CD009794.
- Castilloux, J., A. J. Noble and C. Faure (2010). "Risk factors for short- and long-term morbidity in children with esophageal atresia." J Pediatr **156**(5): 755-760.
- Cauchi, J. A., R. G. Buick, P. Gornall, M. H. Simms and D. H. Parikh (2007). "Oesophageal substitution with free and pedicled jejunum: short- and long-term outcomes." Pediatr Surg Int **23**(1): 11-19.
- Chetcuti F, P. P. (1993). "Respiratory morbidity after repair of oesophageal atresia and tracheo-oesophageal fistula." Archives of Disease in Childhood **68**: 167-170.
- Chetcuti, P., N. A. Myers, P. D. Phelan and S. W. Beasley (1988). "Adults who survived repair of congenital oesophageal atresia and tracheo-oesophageal fistula." Bmj **297**(6644): 344-346.
- Chetcuti, P. and P. D. Phelan (1993). "Gastrointestinal morbidity and growth after repair of oesophageal atresia and tracheo-oesophageal fistula." Arch Dis Child **68**(2): 163-166.
- Chetcuti, P. and P. D. Phelan (1993). "Respiratory morbidity after repair of oesophageal atresia and tracheo-oesophageal fistula." Arch Dis Child **68**(2): 167-170.
- Chung, E. J., H. W. Ju, Y. K. Yeon, J. S. Lee, Y. J. Lee, Y. B. Seo and P. Chan Hum (2018). "Development of an omentum-cultured oesophageal scaffold reinforced by a 3D-printed ring: feasibility of an in vivo bioreactor." Artif Cells Nanomed Biotechnol: 1-11.
- Connor, M. J., L. R. Springford, V. V. Kapetanakis and S. Giuliani (2015). "Esophageal atresia and transitional care--step 1: a systematic review and meta-analysis of the literature to define the prevalence of chronic long-term problems." Am J Surg **209**(4): 747-759.
- Cooper, J. E., McCann, C. J., Natarajan, D., Choudhury, S., Boesmans, W., Delalande, J. M., Vanden Berghe, P., Burns, A. J., & Thapar, N. (2016). In Vivo Transplantation of Enteric Neural Crest Cells into Mouse Gut; Engraftment, Functional Integration and Long-Term Safety. PloS one **11**(1)
- da Rocha, J. R., U. Ribeiro, Jr., R. A. Sallum, S. Szachnowicz and I. Cecconello (2008). "Barrett's esophagus (BE) and carcinoma in the esophageal stump (ES) after

esophagectomy with gastric pull-up in achalasia patients: a study based on 10 years follow-up." Ann Surg Oncol **15**(10): 2903-2909.

Davenport, M., G. P. Hosie, R. C. Tasker, I. Gordon, E. M. Kiely and L. Spitz (1996). "Long-term effects of gastric transposition in children: a physiological study." J Pediatr Surg **31**(4): 588-593.

Delaere, P. R., Z. Y. Liu, R. Hermans, R. Sciote and L. Feenstra (1995). "Experimental tracheal allograft revascularization and transplantation." The Journal of thoracic and cardiovascular surgery **110**(3): 728-737.

Dellavalle, A., M. Sampaolesi, R. Tonlorenzi, E. Tagliafico, B. Sacchetti, L. Perani, A. Innocenzi, B. G. Galvez, G. Messina, R. Morosetti, S. Li, M. Belicchi, G. Peretti, J. S. Chamberlain, W. E. Wright, Y. Torrente, S. Ferrari, P. Bianco and G. Cossu (2007). "Pericytes of human skeletal muscle are myogenic precursors distinct from satellite cells." Nat Cell Biol **9**(3): 255-267.

Den Hondt, M., B. M. Vanaudenaerde, P. Delaere and J. J. Vranckx (2016). "Twenty years of experience with the rabbit model, a versatile model for tracheal transplantation research." Plast Aesthet Res **3**: 223-230.

Den Hondt, M., B. M. Vanaudenaerde, E. F. Maughan, C. R. Butler, C. Crowley, E. K. Verbeken, S. E. Verleden and J. J. Vranckx (2017). "An optimized non-destructive protocol for testing mechanical properties in decellularised rabbit trachea." Acta Biomater **60**: 291-301.

Deurloo, J. A., S. Ekkelkamp, J. F. Bartelsman, F. J. Ten Kate, M. Schoorl, H. A. Heij and D. C. Aronson (2003). "Gastroesophageal reflux: prevalence in adults older than 28 years after correction of esophageal atresia." Ann Surg **238**(5): 686-689.

Deurloo, J. A., S. Ekkelkamp, E. E. Hartman, M. A. Sprangers and D. C. Aronson (2005). "Quality of life in adult survivors of correction of esophageal atresia." Arch Surg **140**(10): 976-980.

Deurloo, J. A., S. Ekkelkamp, J. A. Taminiau, C. M. Kneepkens, F. W. ten Kate, J. F. Bartelsman, D. A. Legemate and D. C. Aronson (2005). "Esophagitis and Barrett esophagus after correction of esophageal atresia." J Pediatr Surg **40**(8): 1227-1231.

Dimenas, E., G. Carlsson, H. Glise, B. Israelsson and I. Wiklund (1996). "Relevance of norm values as part of the documentation of quality of life instruments for use in upper gastrointestinal disease." Scand J Gastroenterol Suppl **221**: 8-13.

Dingemann, C., A. Meyer, G. Kircher, T. M. Boemers, B. Vaske, H. Till and B. M. Ure (2014). "Long-term health-related quality of life after complex and/or complicated esophageal atresia in adults and children registered in a German patient support group." J Pediatr Surg **49**(4): 631-638.

Dingemann, J., R. Szczepanski, G. Ernst, U. Thyen, B. Ure, M. Goll and I. Menrath (2016). "Transition of Patients with Esophageal Atresia to Adult Care: Results of a Transition-Specific Education Program." Eur J Pediatr Surg.

Doede, T., M. Bondartschuk, C. Joerck, E. Schulze and M. Goernig (2009). "Unsuccessful alloplastic esophageal replacement with porcine small intestinal submucosa." Artif Organs **33**(4): 328-333.

Dvir, T., B. P. Timko, D. S. Kohane and R. Langer (2011). "Nanotechnological strategies for engineering complex tissues." Nat Nanotechnol **6**(1): 13-22.

Elliott, M. J., P. De Coppi, S. Speggorin, D. Roebuck, C. R. Butler, E. Samuel, C. Crowley, C. McLaren, A. Fierens, D. Vondrys, L. Cochrane, C. Jephson, S. Janes, N. J. Beaumont, T. Cogan, A. Bader, A. M. Seifalian, J. J. Hsuan, M. W. Lowdell and M. A. Birchall (2012). "Stem-cell-based, tissue engineered tracheal replacement in a child: a 2-year follow-up study." Lancet **380**(9846): 994-1000.

Esteves, E., M. C. Silva, K. C. Paiva, C. C. Chagas, R. R. Valamie, R. Loiola de Guimaraes and B. B. Modesto (2009). "Laparoscopic gastric pull-up for long gap esophageal atresia." J Laparoendosc Adv Surg Tech A **19 Suppl 1**: S191-195.

Eypasch, E., J. I. Williams, S. Wood-Dauphinee, B. M. Ure, C. Schmulling, E. Neugebauer and H. Troidl (1995). "Gastrointestinal Quality of Life Index: development, validation and application of a new instrument." Br J Surg **82**(2): 216-222.

Fishman, J. M., Tyraskis, A., Maghsoudlou, P., Urbani, L., Totonelli, G., Birchall, M. A., & De Coppi, P. (2013). Skeletal muscle tissue engineering: which cell to use?. Tissue engineering. Part B, Reviews, **19**(6), 503–515.

Foker, J. E., T. C. Kendall Krosch, K. Catton, F. Munro and K. M. Khan (2009). "Long-gap esophageal atresia treated by growth induction: the biological potential and early follow-up results." Semin Pediatr Surg **18**(1): 23-29.

Fukushima, M., Kako, N., Chiba, K., Kawaguchi, T., Kimura, Y., Sato, M., Yamauchi, M., & Koie, H. (1983). Seven-year follow-up study after the replacement of the esophagus with an artificial esophagus in the dog. Surgery **93**(1 Pt 1), 70–77.

Gallo, G., S. Zwaveling, H. Groen, D. Van der Zee and J. Hulscher (2012). "Long-gap esophageal atresia: a meta-analysis of jejunal interposition, colon interposition, and gastric pull-up." Eur J Pediatr Surg **22**(6): 420-425.

Gallo, G., S. Zwaveling, D. C. Van der Zee, K. N. Bax, Z. J. de Langen and J. B. Hulscher (2015). "A two-center comparative study of gastric pull-up and jejunal interposition for long gap esophageal atresia." J Pediatr Surg **50**(4): 535-539.

Gaujoux, S., Y. Le Balleur, P. Bruneval, J. Larghero, S. Lecourt, T. Domet, B. Lambert, S. Zohar, F. Prat and P. Cattani (2010). "Esophageal replacement by allogenic aorta in a porcine model." Surgery **148**(1): 39-47.

Gibreel, W., B. Zendejas, R. M. Antiel, G. Fasen, C. R. Moir and A. E. Zarroug (2016). "Swallowing Dysfunction and Quality of Life in Adults With Surgically Corrected Esophageal Atresia/Tracheoesophageal Fistula as Infants: Forty Years of Follow-up." Ann Surg.

Glenn, I. C., N. E. Bruns, G. Gabarain, D. R. Craner, S. J. Schomisch and T. A. Ponsky (2017). "Creation of an animal model for long gap pure esophageal atresia." Pediatr Surg Int **33**(2): 197-201.

- Gross, E. (1953). "The surgery of infancy and childhood. ." Philadelphia , WB Saunders.
- Gupta, D. K., S. Sharma, M. K. Arora, G. Agarwal, M. Gupta and V. P. Grover (2007). "Esophageal replacement in the neonatal period in infants with esophageal atresia and tracheoesophageal fistula." J Pediatr Surg **42**(9): 1471-1477.
- H, I. J., S. J. Gischler, L. Toussaint, M. Spoel, M. H. Zijp and D. Tibboel (2016). "Growth and development after oesophageal atresia surgery: Need for long-term multidisciplinary follow-up." Paediatr Respir Rev **19**: 34-38.
- Hamaji, M., F. Kojima, S. Koyasu, T. Tsuruyama, T. Komatsu, T. Ikuno, H. Date and T. Nakamura (2014). "Development of a composite and vascularized tracheal scaffold in the omentum for in situ tissue engineering: a canine model." Interact Cardiovasc Thorac Surg **19**(3): 357-362.
- Hirschl, R. B., D. Yardeni, K. Oldham, N. Sherman, L. Siplovich, E. Gross, R. Udassin, Z. Cohen, H. Nagar, J. D. Geiger and A. G. Coran (2002). "Gastric transposition for esophageal replacement in children: experience with 41 consecutive cases with special emphasis on esophageal atresia." Ann Surg **236**(4): 531-539; discussion 539-541.
- Hynes, R. O. (2009). "The extracellular matrix: not just pretty fibrils." Science **326**(5957): 1216-1219.
- Irino, T., A. Tsekrekos, A. Coppola, C. M. Scandavini, A. Shetye, L. Lundell and I. Rouvelas (2017). "Long-term functional outcomes after replacement of the esophagus with gastric, colonic, or jejunal conduits: a systematic literature review." Dis Esophagus **30**(12): 1-11.
- Jain, V., S. Sharma, R. Kumar, S. K. Kabra, V. Bhatia and D. K. Gupta (2012). "Transposed intrathoracic stomach: functional evaluation." Afr J Paediatr Surg **9**(3): 210-216.
- Jensen, T., A. Blanchette, S. Vadasz, A. Dave, M. Canfarotta, W. N. Sayej and C. Finck (2015). "Biomimetic and synthetic esophageal tissue engineering." Biomaterials **57**: 133-141.
- Kalabis, J., Oyama, K., Okawa, T., Nakagawa, H., Michaylira, C. Z., Stairs, D. B., Figueiredo, J. L., Mahmood, U., Diehl, J. A., Herlyn, M., & Rustgi, A. K. (2008). A subpopulation of mouse esophageal basal cells has properties of stem cells with the capacity for self-renewal and lineage specification. The Journal of clinical investigation **118**(12), 3860–3869.
- Kim, I. G., Wu, Y., Park, S. A., Cho, H., Choi, J. J., Kwon, S. K., Shin, J. W., & Chung, E. J. (2019). Tissue-Engineered Esophagus via Bioreactor Cultivation for Circumferential Esophageal Reconstruction. Tissue engineering. Part A, 25(21-22), 1478–1492.
- Kim, J. P., C. A. Hundepool, P. F. Friedrich, S. L. Moran, A. T. Bishop and A. Y. Shin (2018). "The effect of full dose composite tissue allotransplantation immunosuppression on allograft motor nerve regeneration in a rat sciatic nerve model." Microsurgery **38**(1): 66-75.
- Koivusalo, A., M. P. Pakarinen, P. Turunen, H. Saarikoski, H. Lindahl and R. J. Rintala (2005). "Health-related quality of life in adult patients with esophageal atresia--a questionnaire study." J Pediatr Surg **40**(2): 307-312.

Krishnan, U., H. Mousa, L. Dall'Oglio, N. Homaira, R. Rosen, C. Faure and F. Gottrand (2016). "ESPGHAN-NASPGHAN Guidelines for the Evaluation and Treatment of Gastrointestinal and Nutritional Complications in Children With Esophageal Atresia-Tracheoesophageal Fistula." J Pediatr Gastroenterol Nutr **63**(5): 550-570.

Krug, E., J. H. Bergmeijer, J. Dees, R. de Krijger, W. J. Mooi and F. W. Hazebroek (1999). "Gastroesophageal reflux and Barrett's esophagus in adults born with esophageal atresia." Am J Gastroenterol **94**(10): 2825-2828.

Kyrklund, K., M. P. Pakarinen and R. J. Rintala (2017). "Long-term bowel function, quality of life and sexual function in patients with anorectal malformations treated during the PSARP era." Semin Pediatr Surg **26**(5): 336-342.

Lee, E., A. Milan, L. Urbani, P. De Coppi and M. W. Lowdell (2017). "Decellularised material as scaffolds for tissue engineering studies in long gap esophageal atresia." Expert Opin Biol Ther **17**(5): 573-584.

Lehmann, N., T. Christ, A. Daus, O. Bloch and S. Holinski (2017). "EDC Cross-linking of Decellularised Tissue: A Promising Approach?" Tissue Eng Part A **23**(13-14): 675-682.
Litman, R. (2016). Basics of Pediatric Anesthesia, CreateSpace Independent Publishing Platform.

Little, D. C., F. J. Rescorla, J. L. Grosfeld, K. W. West, L. R. Scherer and S. A. Engum (2003). "Long-term analysis of children with esophageal atresia and tracheoesophageal fistula." J Pediatr Surg **38**(6): 852-856.

Little, D. C., F. J. Rescorla, J. L. Grosfeld, K. W. West, L. R. Scherer and S. A. Engum (2003). "Long-term analysis of children with esophageal atresia and tracheoesophageal fistula." Journal of Pediatric Surgery **38**(6): 852-856.

Lopes, M. F., A. Cabrita, J. Ilharco, P. Pessa, J. Paiva-Carvalho, A. Pires and J. Patricio (2006). "Esophageal replacement in rat using porcine intestinal submucosa as a patch or a tube-shaped graft." Dis Esophagus **19**(4): 254-259.

Lopes, M. F., A. Cabrita, J. Ilharco, P. Pessa and J. Patricio (2006). "Grafts of porcine intestinal submucosa for repair of cervical and abdominal esophageal defects in the rat." J Invest Surg **19**(2): 105-111.

Lopez, P. J., C. Keys, A. Pierro, D. P. Drake, E. M. Kiely, J. I. Curry and L. Spitz (2006). "Oesophageal atresia: improved outcome in high-risk groups?" J Pediatr Surg **41**(2): 331-334.

Loukogeorgakis, S. P. and A. Pierro (2013). "Replacement surgery for esophageal atresia." Eur J Pediatr Surg **23**(3): 182-190.

Ludman, L. and L. Spitz (2003). "Quality of life after gastric transposition for oesophageal atresia." J Pediatr Surg **38**(1): 53-57; discussion 53-57.

Lynen Jansen, P., Klinge, U., Anurov, M., Titkova, S., Mertens, P. R., & Jansen, M. (2004). Surgical mesh as a scaffold for tissue regeneration in the esophagus. European surgical

research. *Europäische chirurgische Forschung. Recherches chirurgicales européennes*, 36(2), 104–111.

Maghsoudlou, P., Ditchfield, D., Klepacka, D. H., Shangaris, P., Urbani, L., Loukogeorgakis, S. P., Eaton, S., & De Coppi, P. (2014). Isolation of esophageal stem cells with potential for therapy. *Pediatric surgery international*, 30(12), 1249–1256.

Maghsoudlou, P., S. Eaton and P. De Coppi (2014). "Tissue engineering of the esophagus." *Semin Pediatr Surg* **23**(3): 127-134.

Mapara, M., B. S. Thomas and K. M. Bhat (2012). "Rabbit as an animal model for experimental research." *Dent Res J (Isfahan)* **9**(1): 111-118.

Marzaro, M., S. Vigolo, B. Oselladore, M. T. Conconi, D. Ribatti, S. Giuliani, B. Nico, G. Perrino, G. G. Nussdorfer and P. P. Parnigotto (2006). "In vitro and in vivo proposal of an artificial esophagus." *J Biomed Mater Res A* **77**(4): 795-801.

Maughan, E. F., C. R. Butler, C. Crowley, G. Z. Teoh, M. den Hondt, N. J. Hamilton, R. E. Hynds, P. Lange, T. Ansari, L. Urbani, S. M. Janes, P. de Coppi, M. A. Birchall and M. J. Elliott (2017). "A comparison of tracheal scaffold strategies for pediatric transplantation in a rabbit model." *Laryngoscope* **127**(12): E449-e457.

Metzger, M., Caldwell, C., Barlow, A. J., Burns, A. J., & Thapar, N. (2009). Enteric nervous system stem cells derived from human gut mucosa for the treatment of aganglionic gut disorders. *Gastroenterology* **136**(7), 2214–25.e253.

McKinnon, L. J. and A. M. Kosloske (1990). "Prediction and prevention of anastomotic complications of esophageal atresia and tracheoesophageal fistula." *J Pediatr Surg* **25**(7): 778-781.

Miki, H., Ando, N., Ozawa, S., Sato, M., Hayashi, K., & Kitajima, M. (1999). An artificial esophagus constructed of cultured human esophageal epithelial cells, fibroblasts, polyglycolic acid mesh, and collagen. *ASAIO journal (American Society for Artificial Internal Organs : 1992)*, 45(5), 502–508.

Nakase, Y., Nakamura, T., Kin, S., Nakashima, S., Yoshikawa, T., Kuriu, Y., Sakakura, C., Yamagishi, H., Hamuro, J., Ikada, Y., Otsuji, E., & Hagiwara, A. (2008). Intrathoracic esophageal replacement by in situ tissue-engineered esophagus. *The Journal of thoracic and cardiovascular surgery*, 136(4), 850–859.

Natsume, T., Ike, O., Okada, T., Takimoto, N., Shimizu, Y., & Ikada, Y. (1993). Porous collagen sponge for esophageal replacement. *Journal of biomedical materials research*, 27(7), 867–875.

Neethling, W. M. L., K. Puls and A. Rea (2018). "Comparison of physical and biological properties of CardioCel(R) with commonly used bioscaffolds." *Interact Cardiovasc Thorac Surg* **26**(6): 985-992.

Ng, J., S. P. Loukogeorgakis, A. Pierro, E. M. Kiely, P. De Coppi, K. Cross and J. Curry (2014). "Comparison of minimally invasive and open gastric transposition in children." *J Laparoendosc Adv Surg Tech A* **24**(10): 742-749.

Nishikawa, R., Hotta, R., Shimojima, N., Shibata, S., Nagoshi, N., Nakamura, M., Matsuzaki, Y., Okano, H. J., Kuroda, T., Okano, H., & Morikawa, Y. (2015). Migration and differentiation of transplanted enteric neural crest-derived cells in murine model of Hirschsprung's disease. Cytotechnology **67**(4), 661–670.

Okamoto, T., S. Takamizawa, H. Arai, Y. Bitoh, M. Nakao, A. Yokoi and E. Nishijima (2009). "Esophageal atresia: prognostic classification revisited." Surgery **145**(6): 675-681.

Orford, J., D. T. Cass and M. J. Glasson (2004). "Advances in the treatment of oesophageal atresia over three decades: the 1970s and the 1990s." Pediatr Surg Int **20**(6): 402-407.

Ozeki, M., Y. Narita, H. Kagami, N. Ohmiya, A. Itoh, Y. Hirooka, Y. Niwa, M. Ueda and H. Goto (2006). "Evaluation of decellularised esophagus as a scaffold for cultured esophageal epithelial cells." J Biomed Mater Res A **79**(4): 771-778.

Park, S. Y., J. W. Choi, J. K. Park, E. H. Song, S. A. Park, Y. S. Kim, Y. S. Shin and C. H. Kim (2016). "Tissue-engineered artificial oesophagus patch using three-dimensionally printed polycaprolactone with mesenchymal stem cells: a preliminary report." Interact Cardiovasc Thorac Surg **22**(6): 712-717.

Pedersen, R. N., E. Calzolari, S. Husby, E. Garne and E. W. group (2012). "Oesophageal atresia: prevalence, prenatal diagnosis and associated anomalies in 23 European regions." Arch Dis Child **97**(3): 227-232.

Peetsold, M. G., H. A. Heij, J. A. Deurloo and R. J. Gemke (2010). "Health-related quality of life and its determinants in children and adolescents born with oesophageal atresia." Acta Paediatr **99**(3): 411-417.

Poghosyan, T., R. Sfeir, L. Michaud, P. Bruneval, T. Domet, V. Vanneaux, M. Luong-Nguyen, S. Gaujoux, F. Gottrand, J. Larghero and P. Cattani (2015). "Circumferential esophageal replacement using a tube-shaped tissue-engineered substitute: An experimental study in minipigs." Surgery **158**(1): 266-277.

Rauch, U., Hänsgen, A., Hagl, C., Holland-Cunz, S., & Schäfer, K. H. (2006). Isolation and cultivation of neuronal precursor cells from the developing human enteric nervous system as a tool for cell therapy in dysganglionosis. International journal of colorectal disease **21**(6), 554–559.

Revicki, D. W., M.; Wiklund, A.; Crawley, J.; (1998). "Reliability and validity of the gastrointestinal symptom rating scale in patients with gastroesophageal reflux disease." Quality of Life Research **7**: 75 - 83.

Roberts, K., J. Karpelowsky, D. A. Fitzgerald and S. S. Soundappan (2016). "Outcomes of oesophageal atresia and tracheo-oesophageal fistula repair." J Paediatr Child Health **52**(7): 694-698.

Saito, M., T. Sakamoto, M. Fujimaki, K. Tsukada, T. Honda and M. Nozaki (2000). "Experimental study of an artificial esophagus using a collagen sponge, a latissimus dorsi muscle flap, and split-thickness skin." Surg Today **30**(7): 606-613.

Sandblom, P. (1948). "The treatment of congenital atresia of the esophagus from a technical point of view." Acta Chir Scand **97**(1): 25-34.

Saxena A. K. (2014). Esophagus tissue engineering: designing and crafting the components for the "hybrid construct" approach. *European journal of pediatric surgery : official journal of Austrian Association of Pediatric Surgery ... [et al] = Zeitschrift fur Kinderchirurgie*, 24(3), 246–262.

Saxena, A. K., Baumgart, H., Komann, C., Ainoedhofer, H., Soltysiak, P., Kofler, K., & Höllwarth, M. E. (2010). Esophagus tissue engineering: in situ generation of rudimentary tubular vascularized esophageal conduit using the ovine model. Journal of pediatric surgery **45**(5), 859–864.

Saxena, A. K., Ainoedhofer, H., & Höllwarth, M. E. (2009). Esophagus tissue engineering: in vitro generation of esophageal epithelial cell sheets and viability on scaffold. *Journal of pediatric surgery*, 44(5), 896–901.

Schneider, A., F. Gottrand, M. Bellaiche, F. Becmeur, A. Lachaux, L. Bridoux-Henno, J. L. Michel, C. Faure, P. Philippe, Y. Vandenplas, C. Dupont, A. Breton, J. Gaudin, T. Lamireau, L. Muysont, G. Podevin, S. Viola, V. Bertrand, D. Caldari, S. Colinet, C. Wanty, E. Sauleau, E. Leteurtre and L. Michaud (2016). "Prevalence of Barrett Esophagus in Adolescents and Young Adults With Esophageal Atresia." Ann Surg **264**(6): 1004-1008.
Schneider, A., L. Michaud and F. Gottrand (2013). "Esophageal atresia: metaplasia, Barrett." Dis Esophagus **26**(4): 425-427.

Schneider, A., L. Michaud and F. Gottrand (2016). "Prevalence of Barrett Esophagus in Adolescents and Young Adults With Esophageal Atresia." Ann Surg.

Selden, C., & Fuller, B. (2018). Role of Bioreactor Technology in Tissue Engineering for Clinical Use and Therapeutic Target Design. *Bioengineering (Basel, Switzerland)*, 5(2), 32.

Sharma, S. and D. K. Gupta (2011). "Primary gastric pull-up in pure esophageal atresia: technique, feasibility and outcome. A prospective observational study." Pediatr Surg Int **27**(6): 583-585.

Sistonen, S., P. Malmberg, K. Malmstrom, T. Haahtela, S. Sarna, R. J. Rintala and M. P. Pakarinen (2010). "Repaired oesophageal atresia: respiratory morbidity and pulmonary function in adults." Eur Respir J **36**(5): 1106-1112.

Sistonen, S. J., A. Koivusalo, H. Lindahl, E. Pukkala, R. J. Rintala and M. P. Pakarinen (2008). "Cancer after repair of esophageal atresia: population-based long-term follow-up." J Pediatr Surg **43**(4): 602-605.

Sistonen, S. J., A. Koivusalo, U. Nieminen, H. Lindahl, J. Lohi, M. Kero, P. A. Karkkainen, M. A. Farkkila, S. Sarna, R. J. Rintala and M. P. Pakarinen (2010). "Esophageal morbidity and function in adults with repaired esophageal atresia with tracheoesophageal fistula: a population-based long-term follow-up." Ann Surg **251**(6): 1167-1173.

- Spitz, L. (1984). "Gastric transposition via the mediastinal route for infants with long-gap esophageal atresia." J Pediatr Surg **19**(2): 149-154.
- Spitz, L. (2007). "Oesophageal atresia." Orphanet journal of rare diseases **2**: 24-24.
- Spitz, L. (2009). "Gastric transposition in children." Semin Pediatr Surg **18**(1): 30-33.
- Spitz, L. (2014). "Esophageal replacement: overcoming the need." J Pediatr Surg **49**(6): 849-852.
- Spitz, L., E. Kiely and A. Pierro (2004). "Gastric transposition in children--a 21-year experience." J Pediatr Surg **39**(3): 276-281; discussion 276-281.
- Spoel, M., C. J. Meeussen, S. J. Gischler, W. C. Hop, N. M. Bax, R. M. Wijnen, D. Tibboel, J. C. de Jongste and H. Ijsselstijn (2012). "Respiratory morbidity and growth after open thoracotomy or thoracoscopic repair of esophageal atresia." J Pediatr Surg **47**(11): 1975-1983.
- Spunda, R., J. Hruby, P. Mericka, M. Mlcek, O. Pecha, K. Splith, M. Schmelzle, F. Krenzien, J. Lindner, I. Matia and M. Spacek (2018). "Immunosuppressive protocols with tacrolimus after cryopreserved aortal allotransplantation in rats." PLoS One **13**(8): e0201984.
- Sun, C., Serra, C., Lee, G., & Wagner, K. R. (2020). Stem cell-based therapies for Duchenne muscular dystrophy. Experimental neurology, 323, 113086.
- Svedlund, J., I. Sjodin and G. Dotevall (1988). "GSRS--a clinical rating scale for gastrointestinal symptoms in patients with irritable bowel syndrome and peptic ulcer disease." Dig Dis Sci **33**(2): 129-134.
- Svoboda, E., J. Fruithof, A. Widenmann-Grolig, G. Slater, F. Armand, B. Warner, S. Eaton, P. De Coppi and E. Hannon (2017). "A patient led, international study of long term outcomes of esophageal atresia: EAT 1." J Pediatr Surg.
- Takagi R, Yamato M, Kanai N, et al. (2012) Cell sheet technology for regeneration of esophageal mucosa. World J Gastroenterol. **18**(37):5145-5150.
- Takimoto, Y., Nakamura, T., Yamamoto, Y., Kiyotani, T., Teramachi, M., & Shimizu, Y. (1998). The experimental replacement of a cervical esophageal segment with an artificial prosthesis with the use of collagen matrix and a silicone stent. The Journal of thoracic and cardiovascular surgery, **116**(1), 98-106.
- Takimoto, Y., Teramachi, M., Okumura, N., Nakamura, T., & Shimizu, Y. (1994). Relationship between stenting time and regeneration of neoesophageal submucosal tissue. ASAIO journal (American Society for Artificial Internal Organs: 1992), **40**(3), M793-M797.
- Tannuri, U., J. G. Maksoud-Filho, A. C. Tannuri, W. Andrade and J. G. Maksoud (2007). "Which is better for esophageal substitution in children, esophagocoloplasty or gastric transposition? A 27-year experience of a single center." J Pediatr Surg **42**(3): 500-504.
- Tennant, P. W., M. S. Pearce, M. Bythell and J. Rankin (2010). "20-year survival of children born with congenital anomalies: a population-based study." Lancet **375**(9715): 649-656.

Totonelli, G., P. Maghsoudlou, J. M. Fishman, G. Orlando, T. Ansari, P. Sibbons, M. A. Birchall, A. Pierro, S. Eaton and P. De Coppi (2012). "Esophageal tissue engineering: a new approach for esophageal replacement." World J Gastroenterol **18**(47): 6900-6907.

Totonelli, G., P. Maghsoudlou, F. Georgiades, M. Garriboli, K. Koshy, M. Turmaine, M. Ashworth, N. J. Sebire, A. Pierro, S. Eaton and P. De Coppi (2013). "Detergent enzymatic treatment for the development of a natural acellular matrix for oesophageal regeneration." Pediatr Surg Int **29**(1): 87-95.

Urbani, L., C. Camilli, D. E. Phylactopoulos, C. Crowley, D. Natarajan, F. Scottoni, P. Maghsoudlou, C. J. McCann, A. F. Pellegata, A. Urciuolo, K. Deguchi, S. Khalaf, S. F. Aruta, M. C. Signorelli, D. Kiely, E. Hannon, M. Trevisan, R. R. Wong, M. O. Baradez, D. Moulding, A. Virasami, A. Gjinovci, S. Loukogeorgakis, S. Mantero, N. Thapar, N. Sebire, S. Eaton, M. Lowdell, G. Cossu, P. Bonfanti and P. De Coppi (2018). "Multi-stage bioengineering of a layered oesophagus with in vitro expanded muscle and epithelial adult progenitors." Nat Commun **9**(1): 4286.

Urita, Y., H. Komuro, G. Chen, M. Shinya, S. Kaneko, M. Kaneko and T. Ushida (2007). "Regeneration of the esophagus using gastric acellular matrix: an experimental study in a rat model." Pediatr Surg Int **23**(1): 21-26.

Uygun, I., & Bayram, S. (2020). Corrosive ingestion managements in children. *Esophagus* : official journal of the Japan Esophageal Society, 17(4), 365–375

Uygun, I., M. H. Okur, B. Aydogdu, S. Ozekinci and S. Otcu (2013). "Esophageal transplantation in the rat." J Pediatr Surg **48**(8): 1670-1675.

Uysal, E. and M. Dokur (2017). "Comparison of effects of the tacrolimus and cyclosporine A on the colon anastomosis recovery of rats." Ann Surg Treat Res **92**(6): 402-410.

Wang, F., Maeda, Y., Zachar, V., Ansari, T., Emmersen, T. (2018) Regeneration of the oesophageal muscle layer from oesophagus acellular matrix scaffold using adipose-derived stem cells. *Biochemical and Biophysical Research Communications*, 503(6);271-277

Watson, E., Tatara, A. M., van den Beucken, J., Jansen, J. A., Wong, M. E., & Mikos, A. G. (2020). An Ovine Model of In Vivo Bioreactor-Based Bone Generation. *Tissue engineering. Part C, Methods*, 26(7), 384–396.

Wei, R. Q., B. Tan, M. Y. Tan, J. C. Luo, L. Deng, X. H. Chen, X. Q. Li, X. Zuo, W. Zhi, P. Yang, H. Q. Xie and Z. M. Yang (2009). "Grafts of porcine small intestinal submucosa with cultured autologous oral mucosal epithelial cells for esophageal repair in a canine model." Exp Biol Med (Maywood) **234**(4): 453-461.

Zani, A., S. Eaton, M. E. Hoellwarth, P. Puri, J. Tovar, G. Fasching, P. Bagolan, M. Lukac, R. Wijnen, J. F. Kuebler, G. Cecchetto, R. Rintala and A. Pierro (2014). "International survey on the management of esophageal atresia." Eur J Pediatr Surg **24**(1): 3-8.

Zani, A., A. Pierro, N. Elvassore and P. De Coppi (2009). "Tissue engineering: an option for esophageal replacement?" Semin Pediatr Surg **18**(1): 57-62.

Zboralske FF, Karasek MA (1984) Growth characteristics of human esophageal epithelial cells in primary explant and serial culture. In Vitro **20**:109–11