

Case Reports

A Case of Treatment Resistance and Complications in a Patient with Stiff Person Syndrome and Cerebellar Ataxia

Lliwen A. Jones¹, Waqar Baber², Mark Wardle¹, Neil P. Robertson¹, Huw R Morris^{3,4,5}, Alistair Church³, John G. Llewelyn^{1,3} & Kathryn J. Peall^{6*}

¹Neurology Department, University Hospital of Wales, Heath Park, Cardiff, UK, ²School of Medicine, Cardiff University, Wales, UK, ³Royal Gwent Hospital, Cardiff Road, Newport, UK, ⁴Royal Free Hospital, Pond Street, London, UK, ⁵Department of Clinical Neuroscience, UCL Institute of Neurology, London, UK, ⁶Neuroscience and Mental Health Research Institute, Hadyn Ellis Building, Cardiff University, Cardiff, UK

Abstract

Background: Antibodies against glutamic acid decarboxylase (GAD) are associated with Stiff Person Syndrome (SPS).

Case report: A 50-year-old woman presented with symptoms progressed over 9 years, resulting in a cerebellar ataxia and right upper limb tremor. Investigations revealed elevated serum and CSF anti-GAD antibody titres (98.6 and 53.4 µ/ml, respectively). Treatment included intravenous immunoglobulin and immunomodulation (infliximab and rituximab), improving her stiffness, but with no impact on the ataxia-related symptoms. Subsequent high-dose steroids led to diabetic ketoacidosis and unmasking of an insulin-dependent diabetes mellitus.

Discussion: This case illustrates several key features: (1) the combined clinical picture of SPS and cerebellar ataxia is a rare phenotype associated with anti-GAD antibodies; (2) the cerebellar ataxia described was progressive and poorly responsive to immunomodulatory therapy; and (3) the potential for development of further autoimmune sequelae in response to immunosuppression, namely, the development of insulin-dependent diabetes in response to treatment with high-dose oral steroids.

Keywords: Stiff Person Syndrome, GAD autoantibodies, cerebellar ataxia, movement disorder, cerebellum, autoimmune, anti-GAD, treatment

Citation: Jones LA, Baber W, Wardle M, Robertson NP, Morris HR, Church A, et al. A Case of Treatment Resistance and Complications in a Patient with Stiff Person Syndrome and Cerebellar Ataxia. Tremor Other Hyperkinet Mov. 2019; 9. doi: 10.7916/tohm.v0.677

*To whom correspondence should be addressed. E-mail: PeallKJ@cardiff.ac.uk

Editor: Elan D. Louis, Yale University, USA

Received: May 1, 2019; **Accepted:** August 12, 2019; **Published:** October 1, 2019

Copyright: © 2019 Jones et al. This is an open-access article distributed under the terms of the Creative Commons Attribution–Noncommercial–No Derivatives License, which permits the user to copy, distribute, and transmit the work provided that the original authors and source are credited; that no commercial use is made of the work; and that the work is not altered or transformed.

Funding: None.

Financial Disclosures: None.

Conflicts of Interest: The authors report no conflicts of interest.

Ethics Statement: All patients that appear on video have provided written informed consent; authorisation for the videotaping and for publication of the videotape was provided.

Introduction

Antibodies against glutamic acid decarboxylase (GAD), the rate-limiting enzyme involved in γ -aminobutyric acid (GABA) synthesis, are associated with several neurological disorders, including Stiff Person Syndrome (SPS), epilepsy, myasthenia gravis, limbic encephalitis and cerebellar ataxia.^{1,2} However, concurrent presentation of SPS, cerebellar ataxia and positive anti-GAD antibodies has only been reported in a limited number of cases previously.^{3–5} Here, we describe such a case which demonstrates (1) this rare combination of clinical features, including SPS and cerebellar ataxia, with limb and bulbar features; (2) symptom resistance, most notably the cerebellar ataxia, to multiple immunomodulatory therapies; and

(3) development of further autoimmune sequelae, namely, insulin-dependent diabetes, following treatment with high-dose steroids. Figure 1 summarises symptom progression, treatment and anti-GAD titres over a 12-year period. The patient discussed has provided written informed consent for the publication of this report.

Case description

The patient first presented at the age of 50 years, with a 9-month history of intermittent right lower limb stiffness, described by the patient as ‘spasms’. She described an inability to use her right foot on the brake pedal of her car and had difficulty placing her right heel on the ground.

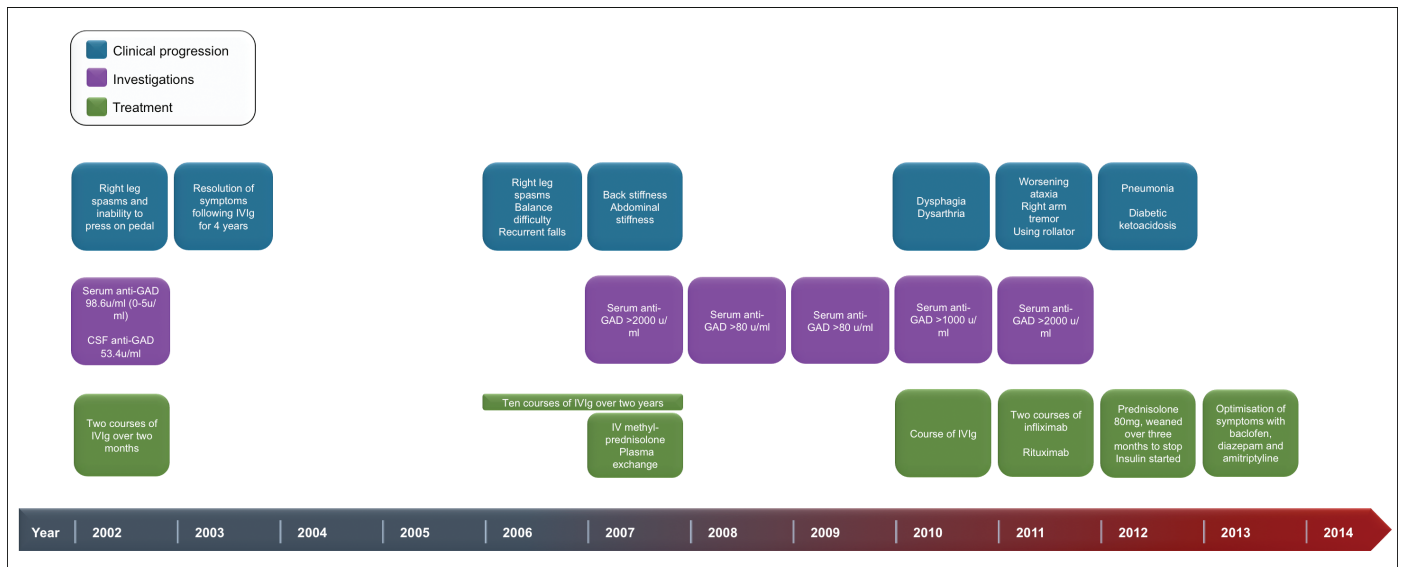


Figure 1. Schematic Timeline of the Clinical Progression of Symptoms, Investigations and Treatment Received over a 12-Year Period. X-axis, progression of years; Blue boxes, progression of symptoms; Purple boxes, trend of antibody titres; Green boxes, treatment given; anti-GAD, anti-glutamic acid decarboxylase; IVIg, intravenous immunoglobulin.

There was no previous medical or medication history. There was a strong family history of thyroid disease (brother, mother, two maternal aunts, maternal grandmother) and adult-onset diabetes mellitus (DM) (mother and father). She had involuntary contraction of the right lower limb muscles with the right foot held in plantar flexion. The remainder of the neurological examination was normal. Serum, imaging and neurophysiological investigations were unremarkable, with the exception of strongly positive anti-GAD antibodies in both serum and CSF at 98.6 $\mu\text{m}/\text{ml}$ (normal range: 0–5 $\mu\text{m}/\text{ml}$) and 53.4 $\mu\text{m}/\text{ml}$ (positive), respectively. She underwent two courses of intravenous immunoglobulin (IVIg) treatment (2 g/kg) over two consecutive months with complete symptom resolution.

Four years later her symptoms returned with additional balance difficulties and recurrent falls. She reported no autonomic or sensory symptoms, and cognition was normal. These symptoms progressed over the subsequent year limiting activities of daily living. Clinical examination at this time demonstrated ongoing involuntary stiffness of the right side, but no overt clinical signs of ataxia. Ten further courses of IVIg over the subsequent 2 years provided only temporary functional improvement to her symptoms of stiffness, lasting 6–8 weeks at a time, with further symptom progression, including dysarthria, dysphagia for liquids, right upper limb weakness and tremor. Examination at this time (5 years after initial presentations) revealed dysarthria, increased right-sided limb tone, mild right upper limb weakness, rigidity and hypertrophy of the paraspinal muscles. Repeat serum anti-GAD antibody titres were elevated at >2,000 $\mu\text{m}/\text{ml}$ (0–5 $\mu\text{m}/\text{ml}$) (5 years post-initial presentation; Figure 1); all other serum and CSF investigations, including serum copper, ataxia genetics screen, anti-tissue transglutaminase (TTG), -Caspr, -Lgi1, -Purkinje cell, -Hu, -Yo and -Ri antibodies, were negative or

within normal limits. CSF anti-GAD antibody titres were not repeated after their initial measurement at presentation (53.4 $\mu\text{m}/\text{ml}$, 2002; Figure 1). Treatment with IV methylprednisolone (500 mg/day for 5 days) and plasma exchange (3 cycles in 5 days) provided no objective improvement.

Eight years after her initial presentation, the patient reported increased difficulties with balance, swallowing and blurred vision. Clinical examination at this point revealed dysarthria, increased right-sided limb tone, with moderate finger to nose ataxia (right-side only) and dysdiadochokinesia. Examination of her eye movements demonstrated square wave jerks in the primary position, broken smooth pursuit movements and rotatory nystagmus at the extremes of gaze. There was evidence of paraspinal muscle spasm, rigidity and hypertrophy. She was able to walk unaided with circumduction and stiffness of the right leg.

The patient's symptoms continued to progress, and 9 years after symptom onset, there was evidence of impaired horizontal saccades, gaze-evoked nystagmus, dysarthria, immobility and a right-side predominant, upper limb cerebellar ataxia with evidence of dysmetria and intention tremor (Videos 1, 2 and 3). In spite of a course of immunomodulatory treatment (two infusions of infliximab and a single dose of rituximab), her symptoms continued to deteriorate with no functional use of the right hand and limited mobility. Examination at this time demonstrated broken-down smooth pursuit movements with gaze evoked nystagmus and mild dysarthria. She had moderate-to-severe finger to nose ataxia on the right, alongside mild alternating movement ataxia. Finger-to-nose movement and rapid alternating movements were normal on the left. There was moderate heel-knee-shin ataxia and ongoing paraspinal muscle spasm. Drawing a spiral demonstrated



Video 1. Demonstrates Intention Tremor and Past-Pointing with Finger-Nose Testing in the Right Upper Limb. The video were undertaken at the same time point (2012), 10 years following symptom onset (Figure 1).



Video 2. Demonstrates Slowed and Hypometric Right Horizontal Saccades. The video were undertaken at the same time point (2012), 10 years following symptom onset (Figure 1).

unsteadiness on the right, but was normal on the left. Oral prednisolone (80 mg/day) was commenced, but she rapidly developed pneumonia and diabetic ketoacidosis (DKA) having had no previous diabetic symptoms. She was admitted to critical care for the management of sepsis,

DKA and respiratory failure and commenced on regular insulin following recovery. Anti-GAD antibody titres remained elevated ($>2,000 \mu\text{ml}$), and treatment was focused on symptom optimisation with diazepam, baclofen and amitriptyline.



Video 3. Demonstrates Dysarthria with Staccato Speech. The video were undertaken at the same time point (2012), 10 years following symptom onset (Figure 1).

Discussion

This case illustrates some of the systemic features of disease associated with GAD auto-antibodies, which are more typically associated with the destruction of pancreatic islet beta cells in autoimmune type 1 diabetes.⁶ Interestingly, in spite of >45 case reports and case series describing cohorts of individuals with features of SPS and raised anti-GAD titres,⁷ the constellation of symptoms described in this case, namely, the combination of SPS and insidious-onset but progressive cerebellar ataxia, remains rarely reported. This potentially indicates a sub-group, or more severe phenotype, of this disorder that warrants further, independent investigation.

Another key feature of this case is the differential response of the distinct symptom groups to immunomodulatory therapy. Initial treatment with IVIg proved successful in improving the SPS symptoms, maintaining good symptom control for more than 4 years. However, with subsequent onset of the cerebellar ataxia, neither more frequent treatment with IVIg nor escalation of immunomodulatory treatment (including steroids, plasma exchange and Rituximab) provided symptomatic relief. Hence, 5 years after symptom onset and an initial good response to treatment, this patient effectively developed a “treatment resistance” to all available forms of immunosuppression, with an ongoing worsening of her clinical signs and symptoms.

Finally, attempts at treatment escalation with further immunosuppressive therapies ultimately resulted in the development of additional autoimmune sequelae. While development of DM following steroid treatment is widely recognised, the importance of GAD function in pancreatic islet beta cells potentially makes this patient group more vulnerable to the serious potential side effects of immunosuppressive and immunomodulatory therapy. This emphasises the importance of patient information and education regarding the potential side effects of therapy before embarking on a treatment programme, and to advise seeking prompt medical advice in the case of illness.

Acknowledgements

The authors would like to thank the patient discussed for providing consent to publication.

References

1. Solimena M, Folli F, Denis-Donini S, Comi GC, Pozza G, De Camilli P, et al. Autoantibodies to glutamic acid decarboxylase in a patient with Stiff-Man Syndrome, epilepsy, and type I diabetes mellitus. *N Engl J Med* 1990;322(22):1555–1560.
2. Ariño H, Gresa-Arribas N, Blanco Y, Martínez-Hernández E, Sabater L, Petit-Pedrol M, et al. Cerebellar ataxia and glutamic acid decarboxylase antibodies: immunologic profile and long-term effect of immunotherapy. *JAMA Neurol* 2014;71(8):1009–1016. doi: 10.1001/jamaneurol.2014.1011
3. Rakocevic G, Raju R, Semino-Mora C, Dalakas MC. Stiff person syndrome with cerebellar disease and high-titer anti-GAD antibodies. *Neurology* 2006;67(6):1068–1070. doi: 10.1212/01.wnl.0000237558.83349.d0
4. Schaefer SM, Moeller JJ. Anti-GAD antibody syndrome with concomitant cerebellar ataxia, stiff person syndrome, and limbic encephalitis. *Neurol Clin Pract* 2015;5(6):502–504. doi: 10.1212/CPJ.0000000000000148
5. Kono S, Miyajima H, Sugimoto M, Suzuki Y, Takahashi Y, Hishida A. Stiff-person syndrome associated with cerebellar ataxia and high glutamic acid decarboxylase antibody titer. *Intern Med* 2001;40(9):968–971.
6. Ali F, Rowley M, Jayakrishnan B, Teuber S, Gershwin ME, Mackay IR. Stiff-person syndrome (SPS) and anti-GAD-related CNS degenerations: protean additions to the autoimmune central neuropathies. *J Autoimmun* 2011;37(2):79–87. doi: 10.1016/j.jaut.2011.05.005
7. Sarva H, Deik A, Ullah A, Severt WL, Disease P, Sinai M, et al. Clinical spectrum of Stiff Person Syndrome: a review of recent reports. *Tremor Other Hyperkinet Mov (NY)* 2016;6:34.