

Little Evidence for Fast Mapping in Adults with Developmental Amnesia: A Commentary on Cooper, Greve & Henson

Authors: Rachael L. Elward^a, Anna M. Dzieciol^a & Faraneh Vargha-Khadem^a

^aUniversity College London Great Ormond Street Institute of Child Health, London, UK

Little Evidence for Fast Mapping in Adults with Developmental Amnesia: A Commentary on Cooper, Greve & Henson

Cooper, Greve, & Henson (2018) conclude that hippocampal-independent learning, as operationalised by "fast mapping" (FM), is unlikely to facilitate learning in adults. We provide evidence from patients with Developmental Amnesia (DA), who acquire language and semantic knowledge despite early hippocampal pathology. We administered an FM paradigm to three patients with DA and controls. Patients showed no benefit of FM compared to explicit encoding. These data support the conclusion that FM is unlikely to facilitate learning in amnesia, regardless of age at onset. Hippocampal-independent learning may be possible in adults with DA, but such learning requires a prolonged consolidation period.

Keywords: fast mapping; semantic learning; developmental amnesia

Cooper, Greve, & Henson (2018) review the evidence that the Fast Mapping (FM) paradigm supports vocabulary learning in adults with amnesia resulting from hippocampal injury (Sharon, Moscovitch, & Gilboa, 2011). Unfortunately, the FM paradigm has not had consistent success in enabling patients with acquired hippocampal damage to compensate for their memory loss. We will contribute to this critical review with unpublished data from patients with Developmental Amnesia (DA).

Developmental amnesia results from hypoxia-induced hippocampal injury sustained early in life, often during the neonatal period. Importantly, the bilateral hippocampal injury occurs before any memory or language ability has developed. Notwithstanding this injury, patients with DA develop age-appropriate speech, language, and motor function. When formally assessed in childhood or adulthood, they show good

intellectual abilities, working memory, language and semantic knowledge. Against this remarkable set of cognitive abilities, an episodic memory deficit emerges during middle childhood. This impairment gains in negative impact with increasing age and expectations, compromising recall of events, and “autonoetic awareness” of a personal history. While the episodic memory deficit may be related to bilateral hippocampal injury, the effortless development of semantic knowledge and language may be attributed to an alternative cortical learning system working in tandem with the heightened plasticity that is available to the immature brain.

Although this alternative cortical system is highly effective in retrieving consolidated post-morbid semantic knowledge, it is not clear how rapidly it accrues new information that is available to recall. Indeed, when new semantic information is taught in a laboratory setting to patients with DA, performance is severely diminished in relation to controls (Baddeley, Vargha-Khadem, & Mishkin, 2001; Gardiner, Brandt, Baddeley, Vargha-Khadem, & Mishkin, 2008). In a recent review (Elward & Vargha-Khadem, 2018), we suggested that new information is typically stored in two memory traces; a semantic memory trace in the cortex which is nascent and insufficient to support accurate recall of novel information, and an episodic memory trace of the learning event which is supported by the hippocampus. Over time, the semantic memory will mature via consolidation. Patients with DA cannot rely on episodic memory to support performance over the shorter delays employed in the laboratory setting.

Nonetheless, given that patients with DA do acquire general knowledge via the putative direct cortical route, it follows that encoding strategies that lean on cortical structures (e.g. FM) could conceivably facilitate this learning process. Therefore, these patients might be best placed to benefit from a cortical learning strategy. To test this hypothesis,

we used a FM protocol identical to that used by (Smith, Urgolites, Hopkins, & Squire (2014, Experiment 2). The data (Fig 1) fit with the pattern described by Cooper et al. (2018). Controls show better performance in explicit encoding (EE) than in FM conditions. Patients with DA show no benefit of FM compared to EE. Indeed, patients showed better recognition performance after EE than FM. The published literature and the data presented here indicate that patients with DA do not rapidly acquire new semantic information that is available to recall via FM.

Given that patients with DA present with such impressive semantic knowledge, how do these patients acquire such representations? One possibility is that simple recognition may support hippocampal-independent learning. Like FM, item recognition via familiarity can be achieved without support from the hippocampus. Recognition performance is relatively preserved in DA, even before consolidation has occurred (Patai et al., 2015); however, the familiarity signal is not sufficient to support recall. Therefore, a period of consolidation may be required for cortical learning (e.g. via familiarity) to mature into an integrated semantic memory representation in DA.

Acknowledgements, This work was supported by the Medical Research Council (programme grant number G03000117/65439) and the Central and East London Research Network (5177). We thank Larry Squire and colleagues for making available their test protocols.

References

- Baddeley, A., Vargha-Khadem, F., & Mishkin, M. (2001). Preserved recognition in a case of developmental amnesia: implications for the acquisition of semantic memory? *Journal of Cognitive Neuroscience*, 13(3), 357–369.
<https://doi.org/10.1162/08989290151137403>
- Cooper, E., Greve, A., & Henson, R. N. (2018). Little evidence for Fast Mapping (FM) in adults: A review and discussion. *Cognitive Neuroscience*,
<https://doi.org/10.1080/17588928.2018.1542376>
- Dzieciol, A. M., Bachevalier, J., Saleem, K. S., Gadian, D. G., Saunders, R., Chong, W. K. K., & Vargha-Khadem, F. (2017). Hippocampal and diencephalic pathology in developmental amnesia. *Cortex*, 86, 33–44.
<https://doi.org/10.1016/j.cortex.2016.09.016>
- Elward, R. L., & Vargha-Khadem, F. (2018). Semantic memory in developmental amnesia. *Neuroscience Letters*, 680(October 2017), 23–30.
<https://doi.org/10.1016/j.neulet.2018.04.040>
- Gardiner, J. M., Brandt, K. R., Baddeley, A. D., Vargha-Khadem, F., & Mishkin, M. (2008). Charting the acquisition of semantic knowledge in a case of developmental amnesia. *Neuropsychologia*, 46(11), 2865–2868.
<https://doi.org/10.1016/j.neuropsychologia.2008.05.021>
- Patai, E. Z., Gadian, D. G., Cooper, J. M., Dzieciol, A. M., Mishkin, M., & Vargha-Khadem, F. (2015). Extent of hippocampal atrophy predicts degree of deficit in recall. *Proceedings of the National Academy of Sciences of the United States of America*, 112 (41), 12830–12833. <https://doi.org/10.1073/pnas.1511904112>
- Sharon, T., Moscovitch, M., & Gilboa, A. (2011). Rapid neocortical acquisition of long-term arbitrary associations independent of the hippocampus. *Proceedings of the National Academy of Sciences of the United States of America*, 108(3), 1146–51. <https://doi.org/10.1073/pnas.1005238108>
- Smith, C. N., Urgolites, Z. J., Hopkins, R. O., & Squire, L. R. (2014). Comparison of explicit and incidental learning strategies in memory-impaired patients. *Proceedings of the National Academy of Sciences of the United States of America*, 111(1), 475–9. <https://doi.org/10.1073/pnas.1322263111>

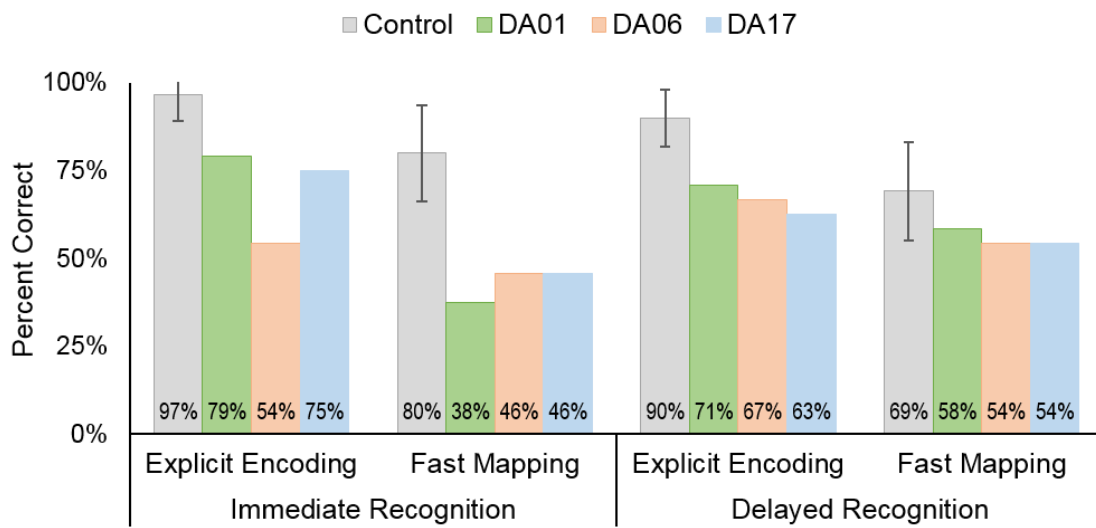


Figure 1. Fast Mapping Performance in patients with DA (N=3, mean age = 30 years) and Controls (N=5, mean age = 21 years). All patients are described in Dzieciol et al., 2017. Controls were recruited through UCL and provided informed consent to participate as approved by the Hampstead NHS Research Ethics Committee, London, UK.