

Prenatal spina bifida: what has changed in diagnosis and management

MAKRINA SAVVIDOU, CHELSEA AND WESTMINSTER HOSPITAL, LONDON, UK
ERIC JAUNIAUX, INSTITUTE FOR WOMEN'S HEALTH, UCL, LONDON, UK

Spinal dysraphisms have been known to medicine since antiquity and descriptions of the condition are found in the writing of Hippocrates, Galen and others (Goodrich JT, A Historical Review of the Surgical Treatment of Spina Bifida. In: The Spina Bifida. Springer 2008). The earliest definitive description of the condition is that of the Dutch physician Peter van Forest (1522-1597) but it was Nicolaes Tulp (1593-1674), the famous Dutch surgeon, depicted in Rembrandt painting "The anatomy lesson of Dr Nicolaes Tulp" who is credited to have first used the term spina bifida to describe a split spine in his book "Observationes Medicae". Before the introduction of antibiotics in the 1940s and the use of shunts in the 1950s most infants born with myelomeningocele died from meningitis or from hydrocephalus (Pruitt LJ, Paediatrics 2012;130:181-3).

With the development of maternal serum screening test and ultrasound imaging it became possible to diagnose spina bifida antenatally, giving the parents the choice to continue or not with the pregnancy. Brock and Sutcliffe (Lancet. 1972;2:197-9), were the first to report on the associated between raised alpha fetoprotein (AFP) in the amniotic fluid and fetal neural tube defects whereas Michell and Bradley-Watson were the first to diagnose a fetal meningocoele at 38 weeks of gestation with B-scan ultrasound (J Obstet Gynaecol Br Commonw.1973;80;1100-1). They described it as a "vague ring shadow deep to the double ring" (fetal head) (Figure 1). In the same issue of BJOG Randle and Cumberbatch (J Obstet Gynaecol Br Commonw.1973;80;1054-8) demonstrated there is a gradual decrease in amniotic fluid AFP levels in normal pregnancies with advancing gestation but that pregnancies complicated by neural tube defects, the levels of AFP remained higher.

Before the advent of high resolution ultrasound in the 1980s, the prenatal diagnosis of spina bifida remained difficult. In 1974, the Australian obstetrician Aileen F Connors reported on a series of amniographies performed in women at high risk of spina bifida due to prior affected pregnancies (J Obstet Gynaecol Br Commonw.1974;81:753-60). The technique included an amniocentesis to measure amniotic fluid AFP followed by injection of Urografin into the amniotic cavity. The patient was then, rotated and placed in a head down position, so that the dye can mix well with the amniotic fluid, and X-ray was performed. The technique had a 100% negative predictive value for spina bifida but was invasive, time consuming and not practical for population screening program. Measurements of AFP in maternal serum (Bond EB et al. BJOG. 197;784:574-7), provided the ideal screening test for spina bifida and, when combined with ultrasound, achieved high detection rates. With improvement in ultrasound equipment and better training, AFP measurements became obsolete.

Nowadays, with spina bifida detection rates close to 100%, the emphasis has moved to management. The best mode of delivery remains a debate for its long-term motor outcome. Is vaginal delivery the best option, despite the concern of sac rupture, or should a Caesarean section be carried out? Realistically, answers to this question can only come from retrospective studies which however are likely to suffer from some selection bias, as the size of spina bifida will always play a role in this decision. Percutaneous fetoscopic repair of myelomeningocele, may reduce long term maternal risks and also allow for a vaginal delivery, ending the debate about the optimal method of delivery.

Disclosure of interests

None declared

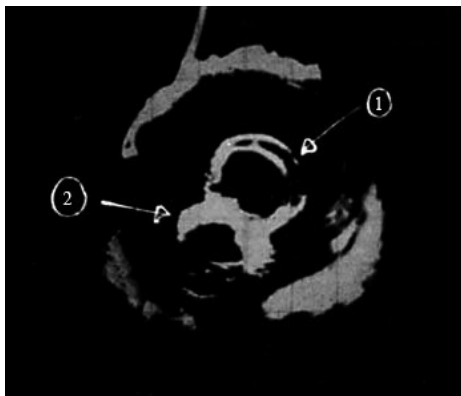


Figure 1. Transabdominal ultrasound scan showing (1) the double ring of the meningocele with (2) the fetal head lying deep to it. (Reproduced with permission from Michell et al., *J Obstet Gynaecol Br Commonw* 1973;80:1100-1).