

To be submitted to AGA Council and SAR Board

To be submitted to Society of Pediatric Radiology Board for endorsement

Consensus Guidelines for Evaluation, Interpretation and Utilization of CT and MR

Enterography in Small Bowel Crohn's Disease Patients

Society of Abdominal Radiology Crohn's Disease-focused Panel*

David Bruining, Division of Gastroenterology and Hepatology, Mayo Clinic, Rochester, Minnesota

Ellen M. Zimmermann, Department of Gastroenterology, University of Florida

Edward V. Loftus, Jr., Division of Gastroenterology and Hepatology, Mayo Clinic, Rochester, Minnesota

William J. Sandborn, Division of Gastroenterology, University of California San Diego

Cary G. Sauer, MD, Emory School of Medicine

Scott A. Strong, MD, Division of GI and Oncologic Surgery, Northwestern Medicine

Members of Society of Abdominal Radiology Crohn's Disease-focused Panel: Mahmoud Al-Hawary, Suhda Anupindi, Mark Baker, David Bruining, Kassa Darge, Jonathan Dillman, David Einstein, Jeff L. Fidler, Joel G. Fletcher, Michael S. Gee, David Grand, Flavius Guglielmo, Amy K. Hara, Tracy Jaffe, Dean Maglinte, Alec Megibow, Seong Ho Park, Joel Platt, Daniel Podberesky, Jordi Rimola, Dushyant V. Sahani, Jorge Soto, Stuart Taylor

Corresponding author: Joel G. Fletcher, MD, Mayo Clinic

E-mail: Fletcher.joel@mayo.edu

Introduction

Computed tomography (CT) and magnetic resonance (MR) enterography have emerged as the most effective methods for imaging the small bowel in patients with Crohn's disease^{1,2}. Cross sectional enterography techniques complement ileocolonoscopy and can visualize intramural or proximal small bowel inflammation in approximately 50% of Crohn's disease patients who have endoscopically normal exams³⁻⁵. CT and MR enterography are useful tools for Crohn's disease diagnosis, determining distribution of disease involvement, and detecting complications of the disease^{1,2}. Recent data suggest that cross sectional imaging may be useful in determining response to therapy, assessing bowel healing, and monitoring disease progression⁶. The Society for Abdominal Radiology (SAR) formed a Crohn's Disease-focused panel, which has established guidelines for the technical performance of these examinations^{7,8}. CT and MR enterography are now performed across a range of institutions, with the radiologic literature focusing on the technical aspects of diagnosis and grading of mural inflammation or penetrating complications, such as fistula and abscess, using various acquisition methods and imaging findings. Important prior consensus statements including those of the European Crohn's and Colitis Organization and European Society of Gastrointestinal and Abdominal Radiology and SAR recommendations for the performance of CT and MR enterography establish critical and necessary rationale for when and how imaging of inflammatory bowel disease patients should be performed, respectively^{2,7,8}. To date, however, there are no agreed upon expectations for structures that should be evaluated at cross-sectional enterography, no standardized nomenclature for describing imaging findings in Crohn's disease, no guidance for how to describe severity and burden of different Crohn's disease imaging findings to best guide medical and surgical management, and no consensus between U.S. gastroenterology and radiology

societies on when these tests should be performed. The purpose of this work is to establish a common system for mapping specific imaging findings to clinically useful impressions and for description of Crohn's disease phenotypes that can guide gastroenterologists and surgeons in making important treatment decisions for Crohn's disease patients. The standardization will both advance patient care through improved understanding of the communicated imaging findings and improve comparison of reported research in the field.

Because CT and MR enterography findings change patient management in a substantial proportion of symptomatic patients^{9,10}, systematic review of CT and MR enterography images is essential to maximize patient benefit. A motivating example for how a systematic review of imaging findings and standard nomenclature might improve patient care can be found in the standard reporting template for pancreatic cancer: an interdisciplinary group of radiologists, medical oncologists, pancreatologists and pancreatic surgeons recommended a systematized reporting template for pancreatic carcinoma, designed to capture objective imaging findings to guide and improve therapeutic decisions¹¹. In Crohn's disease, the use of imaging is evolving over time. Cross-sectional imaging was initially used to detect and stage Crohn's disease⁵, but it is increasingly being used to gauge therapeutic response^{4,12}, providing objective measures to guide treatment decisions that can potentially alter the natural history of the disease¹³. Mucosal healing as detected by colonoscopy in Crohn's disease results in improved outcome¹⁴⁻¹⁷; however, more recently cross-sectional imaging, primarily MR enterography, has demonstrated a high correlation between mucosal healing at endoscopy and mural healing at cross-sectional imaging, with improved outcomes when detected¹⁸⁻²⁰. Thus, there needs to be a shared understanding of the goals of imaging between referring clinicians and radiologists: while numerous investigators have consequently examined the relationship between objective and

subjective imaging findings and the severity of endoscopic and histologic inflammation^{4, 21-24}, others have described the extent of intestinal damage using cross-sectional findings²⁵.

Information conveying length of involvement, severity of inflammation or bowel dilatation, and surgical resections are required when assessing for therapeutic response.

While the existing Montreal classification (and pediatric Paris classification) sub-classify phenotypes of Crohn's disease, including non-stricturing and non-penetrating inflammatory disease, stricturing disease, penetrating complications and perianal fistula^{26, 27}, they do not describe the length and severity of inflammatory involvement or the anatomic relationship of co-existing phenotypes that are necessary to make important surgical and medical management decisions. More specifically, the Montreal/Paris classifications do not take into account the dynamic, continuum of the disease, the overlap or co-existence of stricturing and penetrating disease (two separate types of disease complications occurring from disease progression)^{28, 29}, as well as the fact that active inflammation is most often present in stricturing complications^{21, 28, 30}. Both CTE and MRE can detect the morphologic continuum and co-existing "complications" with regularity, thus prompting the need for radiologists to reliably define and reproducibly describe the anatomic burden of inflammation and Crohn's disease complications.

These guidelines define imaging findings that should be evaluated, how disease burden should be described, and pathophysiologic conclusions that will improve the ability of gastroenterologists and intestinal surgeons to best make management decisions. For example, radiologists should examine for Crohn's disease strictures, which are defined in this guideline as small bowel segments with luminal narrowing and unequivocal proximal (upstream) dilation. Moreover, these guidelines emphasize that when strictures are found, the length of the stricture and radiologic findings of concurrent inflammation and obstruction should be described. These

elements provide much of the critical information a gastroenterologist will need to consider in determining options for medical, surgical or endoscopic therapy. The benefits of a shared understanding and improved communication of cross-sectional enterography exams will facilitate:

- Improved use of imaging to guide treatment options, and assess for therapeutic response.
- Improved understanding for how to compare and assess Crohn's inflammatory burden
- Improved systematic assessment of important complications
- Improved ability to track and understand the natural history of Crohn's disease.

Methods

The SAR Crohn's Disease-focused Panel was established in March 2014 to disseminate knowledge and improve the quality and availability of small bowel and Crohn's disease imaging techniques, with an overall aim to improve the care of patients with Crohn's disease. After approval from the SAR Board of Directors and the AGA Institute Council, this panel met with representatives from the American Gastroenterology Association's Imaging and Advanced Technology (AGA_IAT) section in person, via e-mail, and through conference calls, to develop a shared understanding of imaging findings across enterography techniques and their physiologic substrates. Representatives with expertise in Crohn's disease were also sought and included from the European Society of Gastrointestinal and Abdominal Radiology (ESGAR), the Society for Surgery of the Alimentary Tract (SSAT), American Society of Colon and Rectal Surgeons (ASCRS) and the North American Society for Pediatric Gastroenterology, Hepatology and

Nutrition (NASPGHAN). Through electronic communications and conference calls, consensus guidelines were reached and submitted to the SAR Board and AGA Council for approval.

A primary aim of this work was to define and describe key imaging findings that relate to the diagnosis, severity and type of Crohn's disease involvement in the small bowel. To this end, the evidence of Crohn's disease inflammation for specific imaging findings at CT and MR enterography was evaluated according to the Grading of Recommendations Assessment, Development and Evaluation (GRADE) system for evaluation of diagnostic tests³¹⁻³³. For this purpose, CT and MR enterography were not considered as stand-alone tests, but as part of an imaging strategy combined with clinical assessment and ileocolonoscopy³¹. Practical conclusions were reached relating to each imaging finding reviewed, with the quality of the evidence for each conclusion graded along a four-point scale (i.e., very low, low, moderate, high) based on consensus evaluation of the medical literature by panel members. High-quality studies were those that enrolled consecutive patients in a clinically relevant cohort, with universal application of an endoscopic or histologic reference standard, clear blinding of readers, and site-specific correlation between reference and reader findings. Quality was downgraded if these criteria were not met, if there was substantial variation between studies without a clear explanation, or if there was major uncertainty about the effect of false positives and negatives. Based on these conclusions, recommendations for use of CT or MR enterography or incorporation of each imaging finding into a clinical report is given, with strong recommendations indicating confidence that incorporation will have desirable effects on patient outcomes and outweigh undesirable effects or alternatives³⁴. The strength of the recommendation also takes into account alternative management strategies. After approval of all guidelines by all authors, this document was submitted to the AGA Council, and the Board of

Directors for SAR and the Society of Pediatric Radiology (of which 3 SAR Disease-focused Panel members are representative) for approval.

Imaging Findings (Tables 1-3)

Table 1 defines and describes imaging findings of mural inflammation at CT and MR enterography, along with important diagnostic considerations and practical conclusions. **Figure 1** pictorially illustrates an imaging-based morphologic construct that demonstrates the role of mural inflammation in driving Crohn's disease exacerbations and response as seen at cross-sectional enterography, and which will be explained in greater depth after individual imaging findings have been reviewed. The pictorial representation of a single bowel loop is used to facilitate a unified understanding of how mural inflammation can change independent of signal properties of cross-sectional imaging modalities. Multiple studies have shown that in patients with Crohn's disease, imaging findings of inflammation are strongly associated with the presence of histologic inflammation³⁵⁻³⁹. Evidence describing and supporting the use of these imaging findings for small bowel inflammation is provided in references within **Table 1**. By extension and inference, similar findings can reflect enteric inflammation in the stomach and colon.

While the co-existence of segmental hyperenhancement and wall thickening are used in combination as imaging findings reflecting Crohn's disease inflammation^{39,40}, a number of other conditions can result in these imaging findings even when segmental involvement is multifocal^{41,42}. Additionally, other imaging findings often seen in small bowel Crohn's disease inflammation such as mural stratification and intramural edema can also be seen in a number of other conditions. Asymmetric inflammation in the bowel wall in Crohn's disease is commonly

more severe along the mesenteric border and is probably a specific feature in Crohn's disease⁴³ (**Fig. 2**). The co-existence of mural inflammation and penetrating complications should also suggest Crohn's disease, in the absence of other known causes of penetrating complications such as appendicitis, diverticulitis, tumor, and tuberculosis. Given these considerations, radiologists should diagnose inflammatory small bowel Crohn's disease either (i) in known Crohn's disease patients when the non-specific findings of inflammation are present, or (ii) when enteric inflammation is asymmetric or co-exists with the typical penetrating complications of Crohn's disease. In the absence of a clinical diagnosis of Crohn's disease or asymmetric inflammation (with or without penetrating complications), radiologists should describe the location and length of non-specific small bowel inflammation. Gastroenterologists can then correlate these non-specific radiologic findings with endoscopic and other clinical data to guide further management.

In addition to describing the length of intestinal inflammatory involvement, radiologists should describe the severity of inflammation based on wall thickness, and presence of luminal ulcerations, and increased intramural T2 signal^{4, 22, 44, 45} (**Fig. 2**). Luminal ulcerations appear as small focal breaks in the intraluminal surface of the bowel wall with focal extension of air or enteric contrast into the inflamed bowel wall (**Fig. 3**). Because Crohn's disease itself, as well as physiologic factors and technical factors affecting acquisition, can affect the degree of bowel wall contrast-enhancement, hyperenhancement is a sign of active inflammation, but is not used to describe severity unless quantitative measures are utilized⁴⁶. Mild inflammation is described when segmental hyperenhancement is present with minimal wall thickening of 3-5 mm and rarely causes luminal narrowing. Severe inflammation is present if ulcerations or high T2 intramural signal are identified (**Fig. 3**). Restricted diffusion is a non-specific sign of Crohn's disease mural inflammation, but when other typical findings of mural inflammation are present

on contrast-enhanced and/or T2-weighted images, restricted diffusion is a complementary and supportive finding that has been shown to correlate with severe inflammation at endoscopy²⁴. Restricted diffusion is present when intramural hyper intensity is present on high b-value images (often similar to reactive lymph nodes), and should prompt a careful assessment for other signs over severe inflammation. Radiologists should be aware that false positives can be due to many factors including suboptimal fluid distention. The diagnosis of active Crohn's disease should not be made on the basis of restricted diffusion alone, and that the normal jejunum demonstrates increased relative non-focal restricted diffusion in comparison to the normal ileum^{45, 47}.

Crohn's disease strictures result from complex interactions between inflammatory cells, cytokines, mesenchymal cells, and enteric flora, and result in variable degrees of luminal narrowing⁴⁸. The majority of Crohn's disease strictures have both an inflammatory as well as fibrotic component due to repeated inflammation and reparative damage^{49, 50}, and estimating the relative contribution of inflammation, fibrosis, and smooth muscle hypertrophy in dominant strictures has been an area of active imaging investigation^{51, 52}. However, there is no universally accepted clinical or histologic scoring system for stricture-related fibrosis⁴⁸. Gastroenterologists and radiologists generally refer to different physical findings when identifying a stricture. Endoscopists generally think of luminal narrowing as a stricture. Radiologists generally rely on the presence of proximal dilation (often defined as > 3 cm), as many bowel segments with Crohn's-related inflammation demonstrate luminal narrowing, and cross-sectional imaging cannot assess luminal compliance or readily differentiate between spasm or fixed narrowing at a single time point. Moreover, both predominantly fibrotic and predominantly inflammatory strictures can fail to respond to medical therapy and ultimately require surgical intervention. Several imaging techniques and findings such as magnetization transfer, ultrasound elastography,

diffusion-weighted imaging and relative contrast enhancement on delayed MR imaging with gadolinium are actively being investigated for their ability to estimate fibrosis in Crohn's disease strictures, but none of them have been validated. However, multi-phase cinematic thick slab imaging with balanced steady state precession (e.g., true-FISP or FIESTA) can be helpful in detecting and increasing confidence in stricture presence at MR enterography^{53, 54}. Until prospective studies validating the relationship of imaging findings to histologic fibrosis are completed and a consensus emerges, Crohn's disease strictures can be reliably identified by both luminal narrowing and unequivocal upstream dilation in order to minimize false positive findings (Table 1)⁵⁰. Fixed luminal narrowing without upstream dilation cannot reliably be diagnosed as a stricture on a single image, but when multiple pulse sequences, fluoroscopic observation, or serial imaging exams demonstrate fixed narrowing without upstream dilation, it is appropriate for radiologists should describe that a probable stricture is present. Enteroclysis assessment can be helpful in equivocal cases as it is more sensitive for stricture presence. Radiologists and clinicians should be aware that when strictures are in close proximity to each other, the ability to radiographically detect downstream small bowel strictures is compromised, as an upstream stricture is already causing an obstruction.

Following stricture identification, radiologists should state whether findings of inflammation are present or absent within the stricture (**Fig. 4**). Findings of inflammation within a stricture are critical as current medical treatments can alleviate inflammation and avoid or delay surgery, while true fibrotic strictures are likely to require strictureplasty, excision or endoscopic bowel dilation. Additionally, strictures should be evaluated for symmetry, nodularity or extension of soft tissue into the adjacent mesentery that may signal development of a neoplasm⁵⁵. Radiologists should report the number, location and length of Crohn's disease

strictures in patients so that gastroenterologists and surgeons can decide on the best therapeutic option and approach. While it is understood that the degree of bowel dilation proximal to a stricture is a result of many factors including chronicity and ingested material, the degree of upstream dilation is often useful to endoscopists and surgeons in deciding if treatment is warranted, or which strictures to treat, if multiple strictures are present. The combination of presence/absence and severity of inflammation, stricture length, and degree of upstream dilation and fistulas can provide clinicians with necessary information for treatment decisions⁵⁶.

Table 2 summarizes imaging findings in penetrating complications and mesenteric findings in Crohn's disease. Penetrating complications result from transmural inflammation and include sinus tracts, fistulas, inflammatory masses abscesses, and rarely, free intraperitoneal perforation. Sinus tracts can be blind-ending in the mesentery, terminate at fascial planes, or extend longitudinally within the bowel wall. Fistulas should be described by the two epithelial structures they connect (e.g., enteroenteric, enterocolic, enterocutaneous, rectovaginal, or enterovesical). Enteric fistulas within the abdominal cavity should be described as simple or complex similar to perianal fistulas⁵⁷. Complex, asterisk-shaped fistula complexes are often seen that tether multiple loops of small bowel and/or colon (**Fig. 5**). Inflammatory mass describes dense inflammatory mesenteric inflammation adjacent to severe mural inflammation or penetrating complications that is not an abscess and does not have a well-defined fluid component. The term "phlegmon" should not be used. It should be noted that clinical experience and the pathologic literature supports the strong association between stricture formation and penetrating disease^{28,29}. Thus, when penetrating disease is present, visual inspection should be directed at the site of fistula origin for an inflamed and stenotic bowel segment with upstream dilation, as these are nearly always present. Conversely, the proximal

end of inflamed and stenotic bowel segment should be scrutinized for detection of penetrating complications as most arise from that part of the involved segment. We acknowledge that a weakness of the current proposal is that some inflamed small bowel segments giving rise to fistulas will not cause proximal small bowel dilation as the upstream pressure gradient causes decompression through the fistula rather than dilation of the proximal bowel; these segments would not be identified or termed “strictures” based on a strict interpretation of our proposed scheme. However, because the evidence is overwhelming, when a complex fistula is seen to arise from a small bowel segment with active inflammation, and no upstream dilation is present, one might consider an impression in the clinical report such as, “complex penetrating disease with active inflammatory small bowel Crohn’s disease with luminal narrowing; stricture with imaging findings of active inflammation highly likely.”

Because approximately one-quarter of Crohn’s disease patients present with an anorectal fistula, complete imaging of the anal sphincters and perineum is imperative for every CT and MR enterography exam (**Fig. 6**). Artifacts often occur over the anus due to the placement of exterior phased-array coils at MR enterography, but adequate anal imaging can be performed in such cases using the body coil that is intrinsic to the magnet itself. It has been demonstrated that evaluation of the anorectal structures is best done with a pelvic magnetic resonance imaging (MRI) with a dedicated perianal fistula protocol⁵⁸. In clinical care, gastroenterologists often are most interested in the presence or absence of a perianal fistula or abscess; detailed fistula anatomy is often not required. In the absence of an abscess, therapy with immunosuppressive or biologic medications can proceed, whereas an abscess will require antibiotic treatment and/or drainage prior to the initiation or continuation of therapy, depending on its size. The question of the presence or absence of an anorectal abscess can typically be answered with CT or MR

enterography. It should be noted that perianal disease is not considered penetrating disease in either this guideline or the Paris classification²⁶. The mechanism of perianal disease is distinctly different than that of classic penetrating disease⁵⁹. In addition to the anus and colorectum, radiologists should carefully inspect the appendix, as it is frequently involved with ileocolonic Crohn's disease^{60,61}, and appendicitis is rarely the first presentation of Crohn's disease. Imaging findings of appendiceal Crohn's disease involvement are similar to those in the small bowel, and ileal-appendiceal fistulas are consequently not uncommon.

The spectrum of mesenteric vein thrombosis or occlusion has recently been described in Crohn's disease patients^{62,63}. Radiologists should evaluate for and distinguish between acute mesenteric thrombosis and sequela from prior thrombosis, sometimes referred to as chronic mesenteric vein thrombosis, but more accurately termed chronic mesenteric venous occlusion. Acute portal and superior mesenteric vein thrombus can be seen in Crohn's disease patients as a hypoattenuating thrombus, expanding the vein. These thrombi have been observed to generally resolve without anticoagulation. However, peripheral mesenteric venous thrombi frequently evolve into chronic peripheral mesenteric venous occlusion on follow-up imaging, with segmental pruning of the mesenteric arcade with development of collateral pathways or small bowel varices. Chronic peripheral mesenteric venous occlusions typically correspond anatomically to small bowel segments with active or prior Crohn's disease inflammation (**Fig. 7**). Coronal imaging with maximum intensity projections are especially helpful in visualizing the mesenteric venous arcade. Acute and chronic mesenteric venous thromboses have been correlated to increased risk for stricture or surgery in a retrospective series⁶³, but their impact on the natural history of disease is poorly understood.

Table 3 lists extra-intestinal findings related to Crohn's disease (or Crohn's disease therapies) that should be searched for in every CT and MR enterography exam. The most clinically important findings are sacroiliitis, primary sclerosing cholangitis (PSC) and avascular necrosis (AVN), most often involving the femoral heads. Many patients with Crohn's disease complain of low back pain. Identifying the changes of sacroiliitis identifies the cause and facilitates therapy. Early PSC is often first identified on enterography, and is manifest by the presence of discontinuous, intrahepatic bile ducts that do not connect to non-dilated central ducts. Once identified, the patient can be followed more closely for complications of PSC, typically with MRI/magnetic resonance cholangiopancreatography (MRCP) and endoscopic retrograde cholangiopancreatography (ERCP). Lastly, identifying AVN will again assist the care of a patient with hip pain and prompt avoidance of steroids when possible.

Characterization of Disease Activity

Table 4 lists recommendations for clinical practice based upon the evidence for specific imaging findings. Each recommendation is accompanied by a description of the strength of the recommendation (i.e., strong vs. weak), with strong recommendations having anticipated desirable effects on patient outcomes³⁴. These recommendations set forth imaging criteria for the imaging diagnosis of Crohn's, as well as describing its severity and complications at CT and MR enterography. Furthermore, they recommend cross-sectional enterography be performed at diagnosis to detect small bowel involvement that may not be identified by other methods, and recommend it be considered in disease monitoring when small bowel disease or penetrating complications are present (**Fig. 8**).

Table 5 lists recommended impressions in radiology reports for summarizing imaging findings and grouping them into recognized patterns of disease in a manner that is useful to referring physicians, and accounts for exacerbations and response to therapy as seen at cross-sectional enterography (**Fig. 1**). This imaging-based morphologic construct comes from an observation of the dynamic nature of Crohn's inflammation. As observed by Cosnes and Lemann^{25, 64}, active inflammation is thought to eventually progress to stricturing and penetrating disease complications in a high proportion of patients, with some patients presenting with penetrating or stricturing disease complications, which may portend a more aggressive course. With mild inflammation, wall thickening and hyperenhancement is often seen without luminal narrowing. As inflammation progresses and becomes more severe, enterographic images may display increased intramural T2 signal, restricted diffusion and ulcer formation in conjunction with luminal narrowing. Adoption of a consistent and well-defined reporting mechanism that links imaging findings of inflammation, stricturing disease and penetrating complications with estimates of disease severity will facilitate selection of optimal therapies and communicate disease progression and reversibility⁶⁵, and directly parallel similar linkages provided in the Lemann index without the onerous per-segment analysis required by the research tool (**Appendix**)⁶⁵.

Several terms should be used in describing the pathophysiological significance of imaging findings associated with current or prior small bowel inflammation. Active Crohn's disease inflammation should be identified based on the pre-defined criteria, as should non-specific inflammation. Active inflammation may respond to medical therapy. When no imaging findings of active inflammation are identified in patients with suspected Crohn's disease, this should be explicitly stated in the radiologic report. Complete resolution of small bowel or

colonic inflammatory findings can occur in Crohn's disease patients, with the bowel returning to a normal appearance. In these cases, it is also correct to report that no small bowel inflammation is seen. Partial response to medical therapy may be indicated by a decrease in the severity of imaging findings within an inflamed segment, or evolution to much shorter and patchy areas of involvement over the length of the involved segment (**Fig. 1**)¹². Alternatively, inflammation may resolve with residual findings such as asymmetric fat deposits within the small bowel wall, residual pseudosacculation and scarring, or mild wall thickening, without luminal narrowing or other morphologic or signal changes reflecting active inflammation (i.e., absent T2 signal hyperintensity, hyperenhancement, restricted diffusion). When sequelae of prior inflammation are present without active inflammation, "Crohn's disease with no imaging signs of active inflammation is present" should be stated in the conclusion of the report. Terms such as "quiescent" or "chronic" are discouraged as their meaning may be erroneously interpreted, especially by patients who now, in many institutions, have access to their imaging reports. . Gastroenterologists and patients making clinical decisions based on imaging findings should be aware that active vs. inactive disease based on imaging criteria does not always equate to histologically, endoscopically or clinically active or inactive disease. There is a relationship between these assessment modalities, but the properties assessed with different modalities vary.

Stricture formation occurs when there is focal or segmental luminal narrowing with unequivocal upstream dilation. Imaging findings of concomitant active inflammation are most often present⁴⁹, and we have termed this pattern "stricture with findings of active inflammation" (**Figs. 1 and 4**). Strictures without imaging findings of inflammation may also exist. In this situation, the bowel wall is thickened without other imaging findings of inflammation. Adler et al. found that such strictures did not have more fibrosis than strictures with inflammation, and

lack of imaging findings of inflammation did not imply that histologic inflammation was absent³⁰. While there is a paucity of published data on the subject, in the experience of the radiologist co-authors, penetrating disease has not been seen to arise in the setting of a stricture without inflammation. Imaging criteria for fibrosis are currently being developed and evaluated^{50, 52}.

Internal, penetrating disease (not perianal disease) may occur at any time point during the course of the disease, but occurs overwhelmingly in patients with strictures associated with active inflammation. Sinus tract and fistula formation, abscess, and free perforation are all findings of penetrating disease. Fistulas may be simple or complex. Simple fistulas are comprised of a single tract connecting a bowel loop to adjacent bowel or other structures such as the urinary bladder. Complex fistulas connect multiple adjacent bowel loops or structures. With both simple and complex fistulas, the bowel loops affected are often angulated and appear tethered by the fistula tract (**Fig. 5**). Furthermore, it is common to see small, interloop abscesses along the course of these complex fistulas. If no active inflammation is associated with a fistula, this should also be stated. Post-operative fistulas are often not associated with inflammation, but obviously arise at or near the site of anastomoses.

Colonoscopy is considered the reference standard for colorectal inflammation. This guideline only addresses small bowel Crohn's disease and complications frequently seen on CT and MR enterography in these patients. A comprehensive guide for describing colorectal inflammation at cross-sectional imaging is beyond the scope of this work, as we considered CT and MR enterography as part of an imaging strategy combined with clinical assessment and ileocolonoscopy. Transabdominal ultrasound (with or without intravenous contrast) and video capsule endoscopy are used at many institutions in the diagnosis and surveillance of Crohn's disease, and their role in clinical management continues to evolve; however, integration of their

imaging findings is also beyond the scope of this work, which focuses on exclusively on CT and MR enterography for small bowel Crohn's disease.

Structured Reporting

Structured reporting templates are used by many radiologic practices for specific clinical scenarios to insure important clinical information is always captured in a systematic fashion. They have been shown to improve the quality of information conveyed to referring clinicians ⁶⁶. Several groups have advocated for structured reporting for CT and MR enterography. **Table 6** demonstrates a structured cross-sectional enterography report, and is adapted from Baker et al ⁷.

Conclusion

CT and MR enterography can provide key information to guide treatment relating to the presence, severity, and extent of Crohn's disease and its complications that is not available from clinical and endoscopic evaluation, for both adult and pediatric patients. This guideline establishes a common expectation of structures that can be systematically evaluated in enterographic images, a shared understanding of imaging findings, and agreed upon terms for describing imaging findings in Crohn's disease. A shared approach for linking specific imaging findings to clinically useful impressions can be used to better guide therapeutic decision-making in the short-term, and improve our understanding of the natural history of long-term complications of Crohn's disease. As imaging techniques, new therapies, and a better understanding of the Crohn's disease pathophysiology are developed, this shared approach can also evolve to reflect these new advances.

References

1. Fletcher JG, Fidler JL, Bruining DH, Huprich JE. New concepts in intestinal imaging for inflammatory bowel diseases. *Gastroenterology* 2011;140:1795-806.
2. Panes J, Bouhnik Y, Reinisch W, Stoker J, Taylor SA, Baumgart DC, Danese S, Halligan S, Marincek B, Matos C, Peyrin-Biroulet L, Rimola J, Rogler G, van Assche G, Ardizzone S, Ba-Ssalamah A, Bali MA, Bellini D, Biancone L, Castiglione F, Eehalt R, Grassi R, Kucharzik T, Maccioni F, Maconi G, Magro F, Martin-Comin J, Morana G, Pendse D, Sebastian S, Signore A, Tolan D, Tielbeek JA, Weishaupt D, Wiarda B, Laghi A. Imaging techniques for assessment of inflammatory bowel disease: joint ECCO and ESGAR evidence-based consensus guidelines. *J Crohns Colitis* 2013;7:556-85.
3. Faubion WA, Jr., Fletcher JG, O'Byrne S, Feagan BG, de Villiers WJ, Salzberg B, Plevy S, Proctor DD, Valentine JF, Higgins PD, Harris JM, Diehl L, Wright L, Tew GW, Luca D, Basu K, Keir ME. EMerging BiomARKers in Inflammatory Bowel Disease (EMBARK) study identifies fecal calprotectin, serum MMP9, and serum IL-22 as a novel combination of biomarkers for Crohn's disease activity: role of cross-sectional imaging. *The American journal of gastroenterology* 2013;108:1891-900.
4. Rimola J, Rodriguez S, Garcia-Bosch O, Ordas I, Ayala E, Aceituno M, Pellise M, Ayuso C, Ricart E, Donoso L, Panes J. Magnetic resonance for assessment of disease activity and severity in ileocolonic Crohn's disease. *Gut* 2009;58:1113-20.
5. Samuel S, Bruining DH, Loftus EV, Jr., Becker B, Fletcher JG, Mandrekar JN, Zinsmeister AR, Sandborn WJ. Endoscopic Skipping of the Distal Terminal Ileum in Crohn's Disease Can Lead to Negative Results From Ileocolonoscopy. *Clin Gastroenterol Hepatol* 2012;10:1253 - 9.
6. Deepak P, Fletcher JG, Fidler JL, Barlow JM, Sheedy SP, Kolbe AB, Harmsen WS, Loftus EV, Hansel SL, Becker BD, Bruining DH. Radiological Response Is Associated With Better Long-Term Outcomes and Is a Potential Treatment Target in Patients With Small Bowel Crohn's Disease. *The American journal of gastroenterology* 2016;111:997-1006.
7. Baker ME, Hara AK, Platt JF, Maglinte DD, Fletcher JG. CT enterography for Crohn's disease: optimal technique and imaging issues. *Abdominal imaging* 2015.
8. Grand DJ, Guglielmo FF, Al-Hawary MM. MR enterography in Crohn's disease: current consensus on optimal imaging technique and future advances from the SAR Crohn's disease-focused panel. *Abdominal imaging* 2015;40:953-64.
9. Bruining DH, Siddiki HA, Fletcher JG, Sandborn WJ, Fidler JL, Huprich JE, Mandrekar JN, Harmsen WS, Evans PE, Faubion WA, Hanson KA, Ingle SB, Pardi DS, Schroeder KW, Tremaine WJ, Loftus EV, Jr. Benefit of computed tomography enterography in Crohn's disease: effects on patient management and physician level of confidence. *Inflammatory bowel diseases* 2012;18:219-25.

10. Higgins PD, Caoili E, Zimmermann M, Bhuket TP, Sonda LP, Manoogian B, Platt JF, Zimmermann EM. Computed tomographic enterography adds information to clinical management in small bowel Crohn's disease. *Inflamm Bowel Dis* 2007;13:262-8.
11. Al-Hawary MM, Francis IR, Chari ST, Fishman EK, Hough DM, Lu DS, Macari M, Megibow AJ, Miller FH, Morteale KJ, Merchant NB, Minter RM, Tamm EP, Sahani DV, Simeone DM. Pancreatic ductal adenocarcinoma radiology reporting template: consensus statement of the society of abdominal radiology and the american pancreatic association. *Gastroenterology* 2014;146:291-304 e1.
12. Bruining DH, Loftus EV, Jr., Ehman EC, Siddiki HA, Nguyen DL, Fidler JL, Huprich JE, Mandrekar JN, Harmsen WS, Sandborn WJ, Fletcher JG. Computed tomography enterography detects intestinal wall changes and effects of treatment in patients with Crohn's disease. *Clinical gastroenterology and hepatology : the official clinical practice journal of the American Gastroenterological Association* 2011;9:679-683 e1.
13. Bruining DH, Bhatnagar G, Rimola J, Taylor S, Zimmermann EM, Fletcher JG. CT and MR enterography in Crohn's disease: current and future applications. *Abdominal imaging* 2015.
14. Baert F, Moortgat L, Van Assche G, Caenepeel P, Vergauwe P, De Vos M, Stokkers P, Hommes D, Rutgeerts P, Vermeire S, D'Haens G. Mucosal healing predicts sustained clinical remission in patients with early-stage Crohn's disease. *Gastroenterology* 2010;138:463-8; quiz e10-1.
15. Beppu T, Ono Y, Matsui T, Hirai F, Yano Y, Takatsu N, Ninomiya K, Tsurumi K, Sato Y, Takahashi H, Ookado Y, Koga A, Kinjo K, Nagahama T, Hisabe T, Takaki Y, Yao K. Mucosal healing of ileal lesions is associated with long-term clinical remission after infliximab maintenance treatment in patients with Crohn's disease. *Digestive endoscopy : official journal of the Japan Gastroenterological Endoscopy Society* 2015;27:73-81.
16. Sakuraba A, Annunziata ML, Cohen RD, Hanauer SB, Rubin DT. Mucosal healing is associated with improved long-term outcome of maintenance therapy with natalizumab in Crohn's disease. *Inflammatory bowel diseases* 2013;19:2577-83.
17. Schnitzler F, Fidler H, Ferrante M, Noman M, Arijs I, Van Assche G, Hoffman I, Van Steen K, Vermeire S, Rutgeerts P. Mucosal healing predicts long-term outcome of maintenance therapy with infliximab in Crohn's disease. *Inflammatory bowel diseases* 2009;15:1295-301.
18. Hashimoto S, Shimizu K, Shibata H, Kanayama S, Tanabe R, Onoda H, Matsunaga N, Sakaida I. Utility of computed tomographic enteroclysis/enterography for the assessment of mucosal healing in Crohn's disease. *Gastroenterology research and practice* 2013;2013:984916.
19. Ordas I, Rimola J, Rodriguez S, Paredes JM, Martinez-Perez MJ, Blanc E, Arevalo JA, Aduna M, Andreu M, Radosevic A, Ramirez-Morros AM, Pino S, Gallego M, Jauregui-Amezaga A, Ricart E, Panes J. Accuracy of magnetic resonance enterography in

- assessing response to therapy and mucosal healing in patients with Crohn's disease. *Gastroenterology* 2014;146:374-82 e1.
20. Sauer CG, Middleton JP, McCracken C, Loewen J, Braithwaite K, Alazraki A, Martin DR, Kugathasan S. Magnetic Resonance Enterography Healing and Magnetic Resonance Enterography Remission Predicts Improved Outcome in Pediatric Crohn Disease. *Journal of pediatric gastroenterology and nutrition* 2016;62:378-83.
 21. Zappa M, Stefanescu C, Cazals-Hatem D, Bretagnol F, Deschamps L, Attar A, Larroque B, Treton X, Panis Y, Vilgrain V, Bouhnik Y. Which magnetic resonance imaging findings accurately evaluate inflammation in small bowel Crohn's disease? A retrospective comparison with surgical pathologic analysis. *Inflammatory bowel diseases* 2011;17:984-93.
 22. Rimola J, Ordas I, Rodriguez S, Garcia-Bosch O, Aceituno M, Llach J, Ayuso C, Ricart E, Panes J. Magnetic resonance imaging for evaluation of Crohn's disease: validation of parameters of severity and quantitative index of activity. *Inflammatory bowel diseases* 2011;17:1759-68.
 23. Steward MJ, Punwani S, Proctor I, Adjei-Gyamfi Y, Chatterjee F, Bloom S, Novelli M, Halligan S, Rodriguez-Justo M, Taylor SA. Non-perforating small bowel Crohn's disease assessed by MRI enterography: derivation and histopathological validation of an MR-based activity index. *European journal of radiology* 2012;81:2080-8.
 24. Kim KJ, Lee Y, Park SH, Kang BK, Seo N, Yang SK, Ye BD, Kim SY, Baek S, Ha HK. Diffusion-weighted MR enterography for evaluating Crohn's disease: how does it add diagnostically to conventional MR enterography? *Inflammatory bowel diseases* 2015;21:101-9.
 25. Pariente B, Cosnes J, Danese S, Sandborn WJ, Lewin M, Fletcher JG, Chowers Y, D'Haens G, Feagan BG, Hibi T, Hommes DW, Irvine EJ, Kamm MA, Loftus EV, Jr., Louis E, Michetti P, Munkholm P, Oresland T, Panes J, Peyrin-Biroulet L, Reinisch W, Sands BE, Schoelmerich J, Schreiber S, Tilg H, Travis S, van Assche G, Vecchi M, Mary JY, Colombel JF, Lemann M. Development of the Crohn's disease digestive damage score, the Lemann score. *Inflammatory bowel diseases* 2011;17:1415-22.
 26. Levine A, Griffiths A, Markowitz J, Wilson DC, Turner D, Russell RK, Fell J, Ruemmele FM, Walters T, Sherlock M, Dubinsky M, Hyams JS. Pediatric modification of the Montreal classification for inflammatory bowel disease: the Paris classification. *Inflammatory bowel diseases* 2011;17:1314-21.
 27. Silverberg MS, Satsangi J, Ahmad T, Arnott ID, Bernstein CN, Brant SR, Caprilli R, Colombel JF, Gasche C, Geboes K, Jewell DP, Karban A, Loftus EV, Jr., Pena AS, Riddell RH, Sachar DB, Schreiber S, Steinhart AH, Targan SR, Vermeire S, Warren BF. Toward an integrated clinical, molecular and serological classification of inflammatory bowel disease: report of a Working Party of the 2005 Montreal World Congress of Gastroenterology. *Canadian journal of gastroenterology = Journal canadien de gastroenterologie* 2005;19 Suppl A:5A-36A.

28. Oberhuber G, Stangl PC, Vogelsang H, Schober E, Herbst F, Gasche C. Significant association of strictures and internal fistula formation in Crohn's disease. *Virchows Archiv : an international journal of pathology* 2000;437:293-7.
29. Kelly JK, Preshaw RM. Origin of fistulas in Crohn's disease. *Journal of clinical gastroenterology* 1989;11:193-6.
30. Adler J, Punglia DR, Dillman JR, Polydorides AD, Dave M, Al-Hawary MM, Platt JF, McKenna BJ, Zimmermann EM. Computed tomography enterography findings correlate with tissue inflammation, not fibrosis in resected small bowel Crohn's disease. *Inflammatory bowel diseases* 2012;18:849-56.
31. Schunemann HJ, Oxman AD, Brozek J, Glasziou P, Jaeschke R, Vist GE, Williams JW, Jr., Kunz R, Craig J, Montori VM, Bossuyt P, Guyatt GH. Grading quality of evidence and strength of recommendations for diagnostic tests and strategies. *BMJ* 2008;336:1106-10.
32. Guyatt GH, Oxman AD, Kunz R, Vist GE, Falck-Ytter Y, Schunemann HJ. What is "quality of evidence" and why is it important to clinicians? *BMJ* 2008;336:995-8.
33. Guyatt GH, Oxman AD, Vist GE, Kunz R, Falck-Ytter Y, Alonso-Coello P, Schunemann HJ. GRADE: an emerging consensus on rating quality of evidence and strength of recommendations. *BMJ* 2008;336:924-6.
34. Guyatt GH, Oxman AD, Kunz R, Falck-Ytter Y, Vist GE, Liberati A, Schunemann HJ. Going from evidence to recommendations. *BMJ* 2008;336:1049-51.
35. Bodily KD, Fletcher JG, Solem CA, Johnson CD, Fidler JL, Barlow JM, Bruesewitz MR, McCollough CH, Sandborn WJ, Loftus EV, Jr., Harmsen WS, Crownhart BS. Crohn Disease: mural attenuation and thickness at contrast-enhanced CT Enterography--correlation with endoscopic and histologic findings of inflammation. *Radiology* 2006;238:505-16.
36. Church PC, Turner D, Feldman BM, Walters TD, Greer ML, Amitai MM, Griffiths AM. Systematic review with meta-analysis: magnetic resonance enterography signs for the detection of inflammation and intestinal damage in Crohn's disease. *Alimentary pharmacology & therapeutics* 2015;41:153-66.
37. Horsthuis K, Bipat S, Bennink RJ, Stoker J. Inflammatory bowel disease diagnosed with US, MR, scintigraphy, and CT: meta-analysis of prospective studies. *Radiology* 2008;247:64-79.
38. Qiu Y, Mao R, Chen BL, Li XH, He Y, Zeng ZR, Li ZP, Chen MH. Systematic review with meta-analysis: magnetic resonance enterography vs. computed tomography enterography for evaluating disease activity in small bowel Crohn's disease. *Alimentary pharmacology & therapeutics* 2014;40:134-46.

39. Siddiki H, Fletcher JG, Hara AK, Kofler JM, McCollough CH, Fidler JL, Guimaraes L, Huprich JE, Sandborn WJ, Loftus EV, Jr., Mandrekar J, Bruining DH. Validation of a lower radiation computed tomography enterography imaging protocol to detect Crohn's disease in the small bowel. *Inflammatory bowel diseases* 2011;17:778-86.
40. Baker ME, Walter J, Obuchowski NA, Achkar JP, Einstein D, Veniero JC, Vogel J, Stocchi L. Mural attenuation in normal small bowel and active inflammatory Crohn's disease on CT enterography: location, absolute attenuation, relative attenuation, and the effect of wall thickness. *AJR. American journal of roentgenology* 2009;192:417-23.
41. Macari M, Balthazar EJ. CT of bowel wall thickening: significance and pitfalls of interpretation. *AJR. American journal of roentgenology* 2001;176:1105-16.
42. Plumb AA, Pendse DA, McCartney S, Punwani S, Halligan S, Taylor SA. Lymphoid nodular hyperplasia of the terminal ileum can mimic active crohn disease on MR enterography. *AJR. American journal of roentgenology* 2014;203:W400-7.
43. Meyers MA, McGuire PV. Spiral CT demonstration of hypervascularity in Crohn disease: "vascular jejunitization of the ileum" or the "comb sign". *Abdominal imaging* 1995;20:327-32.
44. Tielbeek JA, Makanyanga JC, Bipat S, Pendse DA, Nio CY, Vos FM, Taylor SA, Stoker J. Grading Crohn disease activity with MRI: interobserver variability of MRI features, MRI scoring of severity, and correlation with Crohn disease endoscopic index of severity. *AJR. American journal of roentgenology* 2013;201:1220-8.
45. Park SH. DWI at MR Enterography for Evaluating Bowel Inflammation in Crohn Disease. *AJR. American journal of roentgenology* 2016:1-9.
46. Makanyanga J, Punwani S, Taylor SA. Assessment of wall inflammation and fibrosis in Crohn's disease: value of T1-weighted gadolinium-enhanced MR imaging. *Abdominal imaging* 2012;37:933-43.
47. Morani AC, Smith EA, Ganeshan D, Dillman JR. Diffusion-weighted MRI in pediatric inflammatory bowel disease. *AJR. American journal of roentgenology* 2015;204:1269-77.
48. Rieder F, Zimmermann EM, Remzi FH, Sandborn WJ. Crohn's disease complicated by strictures: a systematic review. *Gut* 2013;62:1072-84.
49. Chiorean MV, Sandrasegaran K, Saxena R, Maglinte DD, Nakeeb A, Johnson CS. Correlation of CT enteroclysis with surgical pathology in Crohn's disease. *The American journal of gastroenterology* 2007;102:2541-50.
50. Barkmeier DT, Dillman JR, Al-Hawary M, Heider A, Davenport MS, Smith EA, Adler J. MR enterography-histology comparison in resected pediatric small bowel Crohn disease strictures: can imaging predict fibrosis? *Pediatric radiology* 2016;46:498-507.

51. Higgins PD, Fletcher JG. Characterization of inflammation and fibrosis in Crohn's disease lesions by magnetic resonance imaging. *The American journal of gastroenterology* 2015;110:441-3.
52. Rimola J, Planell N, Rodriguez S, Delgado S, Ordas I, Ramirez-Morros A, Ayuso C, Aceituno M, Ricart E, Jauregui-Amezaga A, Panes J, Cuatrecasas M. Characterization of inflammation and fibrosis in Crohn's disease lesions by magnetic resonance imaging. *The American journal of gastroenterology* 2015;110:432-40.
53. Tielbeek JA, Ziech ML, Li Z, Lavini C, Bipat S, Bemelman WA, Roelofs JJ, Ponsioen CY, Vos FM, Stoker J. Evaluation of conventional, dynamic contrast enhanced and diffusion weighted MRI for quantitative Crohn's disease assessment with histopathology of surgical specimens. *European radiology* 2014;24:619-29.
54. Wnorowski AM, Guglielmo FF, Mitchell DG. How to perform and interpret cine MR enterography. *Journal of magnetic resonance imaging : JMRI* 2015;42:1180-9.
55. Weber NK, Fletcher JG, Fidler JL, Barlow JM, Pruthi S, Loftus EV, Jr., Pardi DS, Smyrk TC, Becker BD, Pasha SF, Bruining DH. Clinical characteristics and imaging features of small bowel adenocarcinomas in Crohn's disease. *Abdominal imaging* 2015;40:1060-7.
56. Martin DR, Kalb B, Sauer CG, Alazraki A, Goldschmid S. Magnetic resonance enterography in Crohn's disease: techniques, interpretation, and utilization for clinical management. *Diagnostic and interventional radiology* 2012;18:374-86.
57. Morris J, Spencer JA, Ambrose NS. MR imaging classification of perianal fistulas and its implications for patient management. *Radiographics : a review publication of the Radiological Society of North America, Inc* 2000;20:623-35; discussion 635-7.
58. Gecse KB, Bemelman W, Kamm MA, Stoker J, Khanna R, Ng SC, Panes J, van Assche G, Liu Z, Hart A, Levesque BG, D'Haens G, World Gastroenterology Organization IOFIBDIESoC, Robarts Clinical T, World Gastroenterology Organization International Organisation for Inflammatory Bowel Diseases IESoC, Robarts Clinical T. A global consensus on the classification, diagnosis and multidisciplinary treatment of perianal fistulising Crohn's disease. *Gut* 2014;63:1381-92.
59. Tozer PJ, Whelan K, Phillips RK, Hart AL. Etiology of perianal Crohn's disease: role of genetic, microbiological, and immunological factors. *Inflammatory bowel diseases* 2009;15:1591-8.
60. Bass JA, Goldman J, Jackson MA, Gasior AC, Sharp SW, Drews AA, Saunders CJ, St Peter SD. Pediatric Crohn disease presenting as appendicitis: differentiating features from typical appendicitis. *European journal of pediatric surgery : official journal of Austrian Association of Pediatric Surgery ... [et al] = Zeitschrift fur Kinderchirurgie* 2012;22:274-8.

61. Soyer P, Boudiaf M, Dray X, Sirol M, Martin-Grivaud S, Duchat F, Fargeaudou Y, Hamzi L, Tiah D, Marteau P, Rymer R. Crohn's disease: multi-detector row CT-enteroclysis appearance of the appendix. *Abdominal imaging* 2010;35:654-60.
62. Vietti Violi N, Fournier N, Duran R, Schmidt S, Bize P, Guiu B, Denys A. Acute mesenteric vein thrombosis: factors associated with evolution to chronic mesenteric vein thrombosis. *AJR. American journal of roentgenology* 2014;203:54-61.
63. Violi NV, Schoepfer AM, Fournier N, Guiu B, Bize P, Denys A. Prevalence and clinical importance of mesenteric venous thrombosis in the Swiss Inflammatory Bowel Disease Cohort. *AJR. American journal of roentgenology* 2014;203:62-9.
64. Cosnes J, Cattan S, Blain A, Beaugerie L, Carbonnel F, Parc R, Gendre JP. Long-term evolution of disease behavior of Crohn's disease. *Inflamm Bowel Dis* 2002;8:244-50.
65. Pariente B, Mary JY, Danese S, Chowers Y, De Cruz P, D'Haens G, Loftus EV, Jr., Louis E, Panes J, Scholmerich J, Schreiber S, Vecchi M, Branche J, Bruining D, Fiorino G, Herzog M, Kamm MA, Klein A, Lewin M, Meunier P, Ordas I, Strauch U, Tontini GE, Zagdanski AM, Bonifacio C, Rimola J, Nachury M, Leroy C, Sandborn W, Colombel JF, Cosnes J. Development of the Lemann index to assess digestive tract damage in patients with Crohn's disease. *Gastroenterology* 2015;148:52-63 e3.
66. Schwartz LH, Panicek DM, Berk AR, Li Y, Hricak H. Improving communication of diagnostic radiology findings through structured reporting. *Radiology* 2011;260:174-81.
67. Coimbra AJ, Rimola J, O'Byrne S, Lu TT, Bengtsson T, de Crespigny A, Luca D, Rutgeerts P, Bruining DH, Fidler JL, Sandborn WJ, Santillan CS, Higgins PD, Al-Hawary MM, Vermeire S, Vanbeckevoort D, Vanslebrouck R, Peyrin-Biroulet L, Laurent V, Herrmann KA, Panes J. Magnetic resonance enterography is feasible and reliable in multicenter clinical trials in patients with Crohn's disease, and may help select subjects with active inflammation. *Alimentary pharmacology & therapeutics* 2016;43:61-72.
68. Fiorino G, Bonifacio C, Peyrin-Biroulet L, Minuti F, Repici A, Spinelli A, Fries W, Balzarini L, Montorsi M, Malesci A, Danese S. Prospective comparison of computed tomography enterography and magnetic resonance enterography for assessment of disease activity and complications in ileocolonic Crohn's disease. *Inflammatory Bowel Diseases* 2011;17:1073-80.
69. Johnson KT, Hara AK, Johnson CD. Evaluation of colitis: usefulness of CT enterography technique. *Emergency radiology* 2009;16:277-82.
70. Punwani S, Rodriguez-Justo M, Bainbridge A, Greenhalgh R, De Vita E, Bloom S, Cohen R, Windsor A, Obichere A, Hansmann A, Novelli M, Halligan S, Taylor SA. Mural inflammation in Crohn disease: location-matched histologic validation of MR imaging features. *Radiology* 2009;252:712-20.

71. Maccioni F, Staltari I, Pino AR, Tiberti A. Value of T2-weighted magnetic resonance imaging in the assessment of wall inflammation and fibrosis in Crohn's disease. *Abdominal Imaging* 2012;37:944-57.
72. Choi SH, Kim KW, Lee JY, Kim KJ, Park SH. Diffusion-weighted Magnetic Resonance Enterography for Evaluating Bowel Inflammation in Crohn's Disease: A Systematic Review and Meta-analysis. *Inflammatory bowel diseases* 2015.
73. Hordonneau C, Buisson A, Scanzi J, Goutorbe F, Pereira B, Borderon C, Da Ines D, Montoriol PF, Garcier JM, Boyer L, Bommelaer G, Petitcolin V. Diffusion-weighted magnetic resonance imaging in ileocolonic Crohn's disease: validation of quantitative index of activity. *American Journal of Gastroenterology* 2014;109:89-98.
74. Buisson A, Joubert A, Montoriol PF, Da Ines D, Hordonneau C, Pereira B, Garcier JM, Bommelaer G, Petitcolin V. Diffusion-weighted magnetic resonance imaging for detecting and assessing ileal inflammation in Crohn's disease.[Erratum appears in *Aliment Pharmacol Ther.* 2013 May;37(10):1031 Note: Ines, D D [corrected to Da Ines, D]]. *Alimentary Pharmacology & Therapeutics* 2013;37:537-45.
75. Seo N, Park SH, Kim KJ, Kang BK, Lee Y, Yang SK, Ye BD, Kim SY, Baek S, Han K, Ha HK. MR Enterography for the Evaluation of Small-Bowel Inflammation in Crohn Disease by Using Diffusion-weighted Imaging without Intravenous Contrast Material: A Prospective Noninferiority Study. *Radiology* 2016;278:762-72.
76. James S, Balfe DM, Lee JK, Picus D. Small-bowel disease: categorization by CT examination. *AJR. American journal of roentgenology* 1987;148:863-8.
77. Weber NK, Fletcher JG, Fidler JL, Barlow JM, Pruthi S, Loftus EV, Jr., Pardi DS, Smyrk TC, Becker BD, Pasha SF, Bruining DH. Clinical characteristics and imaging features of small bowel adenocarcinomas in Crohn's disease. *Abdominal imaging* 2014.
78. Frye JM, Hansel SL, Dolan SG, Fidler JL, Song LM, Barlow JM, Smyrk TC, Flicek KT, Hara AK, Bruining DH, Fletcher JG. NSAID enteropathy: appearance at CT and MR enterography in the age of multi-modality imaging and treatment. *Abdominal imaging* 2015;40:1011-25.
79. Soyer P, Boudiaf M, Sirol M, Dray X, Aout M, Duchat F, Vahedi K, Fargeaudou Y, Martin-Grivaud S, Hamzi L, Vicaut E, Rymer R. Suspected anastomotic recurrence of Crohn disease after ileocolic resection: evaluation with CT enteroclysis. *Radiology* 2010;254:755-64.
80. Fornasa F, Benassuti C, Benazzato L. Role of Magnetic Resonance Enterography in Differentiating between Fibrotic and Active Inflammatory Small Bowel Stenosis in Patients with Crohn's Disease. *Journal of clinical imaging science* 2011;1:35.
81. Solem CA, Loftus EV, Jr., Fletcher JG, Baron TH, Gostout CJ, Petersen BT, Tremaine WJ, Egan LJ, Faubion WA, Schroeder KW, Pardi DS, Hanson KA, Jewell DA, Barlow JM, Fidler JL, Huprich JE, Johnson CD, Harmsen WS, Zinsmeister AR, Sandborn WJ.

- Small-bowel imaging in Crohn's disease: a prospective, blinded, 4-way comparison trial. *Gastrointestinal Endoscopy* 2008;68:255-66.
82. Sinha R, Murphy P, Sanders S, Ramachandran I, Hawker P, Rawat S, Roberts S. Diagnostic accuracy of high-resolution MR enterography in Crohn's disease: comparison with surgical and pathological specimen. *Clinical Radiology* 2013;68:917-27.
 83. Cullmann JL, Bickelhaupt S, Froehlich JM, Szucs-Farkas Z, Tutuian R, Patuto N, Dawson H, Patak MA. MR imaging in Crohn's disease: correlation of MR motility measurement with histopathology in the terminal ileum. *Neurogastroenterology and motility : the official journal of the European Gastrointestinal Motility Society* 2013;25:749-e577.
 84. Froehlich JM, Waldherr C, Stoupis C, Erturk SM, Patak MA. MR motility imaging in Crohn's disease improves lesion detection compared with standard MR imaging. *European radiology* 2010;20:1945-51.
 85. Menys A, Helbren E, Makanyanga J, Emmanuel A, Forbes A, Windsor A, Punwani S, Halligan S, Atkinson D, Taylor SA. Small bowel strictures in Crohn's disease: a quantitative investigation of intestinal motility using MR enterography. *Neurogastroenterology and motility : the official journal of the European Gastrointestinal Motility Society* 2013;25:967-e775.
 86. Menys A, Atkinson D, Odille F, Ahmed A, Novelli M, Rodriguez-Justo M, Proctor I, Punwani S, Halligan S, Taylor SA. Quantified terminal ileal motility during MR enterography as a potential biomarker of Crohn's disease activity: a preliminary study. *European radiology* 2012;22:2494-501.
 87. Booya F, Akram S, Fletcher JG, Huprich JE, Johnson CD, Fidler JL, Barlow JM, Solem CA, Sandborn WJ, Loftus EV, Jr. CT enterography and fistulizing Crohn's disease: clinical benefit and radiographic findings. *Abdominal imaging* 2009;34:467-75.
 88. Vogel J, da Luz Moreira A, Baker M, Hammel J, Einstein D, Stocchi L, Fazio V. CT enterography for Crohn's disease: accurate preoperative diagnostic imaging. *Diseases of the colon and rectum* 2007;50:1761-9.
 89. Spinelli A, Fiorino G, Bazzi P, Sacchi M, Bonifacio C, De Bastiani S, Malesci A, Balzarini L, Peyrin-Biroulet L, Montorsi M, Danese S. Preoperative magnetic resonance enterography in predicting findings and optimizing surgical approach in Crohn's disease. *Journal of Gastrointestinal Surgery* 2014;18:83-90; discussion 90-1.
 90. Lee SS, Kim AY, Yang SK, Chung JW, Kim SY, Park SH, Ha HK. Crohn disease of the small bowel: comparison of CT enterography, MR enterography, and small-bowel follow-through as diagnostic techniques. *Radiology* 2009;251:751-61.
 91. Bruining DH, Siddiki HA, Fletcher JG, Tremaine WJ, Sandborn WJ, Loftus EV, Jr. Prevalence of penetrating disease and extraintestinal manifestations of Crohn's disease detected with CT enterography. *Inflammatory Bowel Diseases* 2008;14:1701-6.

92. Garcia-Bosch O, Ordas I, Aceituno M, Rodriguez S, Ramirez AM, Gallego M, Ricart E, Rimola J, Panes J. Comparison of Diagnostic Accuracy and Impact of Magnetic Resonance Imaging and Colonoscopy for the Management of Crohn's Disease. *Journal of Crohn's & colitis* 2016;10:663-9.
93. Spencer JA, Chapple K, Wilson D, Ward J, Windsor AC, Ambrose NS. Outcome after surgery for perianal fistula: predictive value of MR imaging. *AJR Am J Roentgenol* 1998;171:403-6.
94. Parks AG, Gordon PH, Hardcastle JD. A classification of fistula-in-ano. *Br J Surg* 1976;63:1-12.
95. Hammer MR, Dillman JR, Smith EA, Al-Hawary MM. Magnetic resonance imaging of perianal and perineal crohn disease in children and adolescents. *Magnetic resonance imaging clinics of North America* 2013;21:813-28.
96. de Miguel Criado J, del Salto LG, Rivas PF, del Hoyo LF, Velasco LG, de las Vacas MI, Marco Sanz AG, Paradela MM, Moreno EF. MR imaging evaluation of perianal fistulas: spectrum of imaging features. *Radiographics : a review publication of the Radiological Society of North America, Inc* 2012;32:175-94.
97. Beets-Tan RG, Beets GL, van der Hoop AG, Kessels AG, Vliegen RF, Baeten CG, van Engelshoven JM. Preoperative MR imaging of anal fistulas: Does it really help the surgeon? *Radiology* 2001;218:75-84.
98. Schwartz DA, Wiersema MJ, Dudiak KM, Fletcher JG, Clain JE, Tremaine WJ, Zinsmeister AR, Norton ID, Boardman LA, Devine RM, Wolff BG, Young-Fadok TM, Diehl NN, Pemberton JH, Sandborn WJ. A comparison of endoscopic ultrasound, magnetic resonance imaging, and exam under anesthesia for evaluation of Crohn's perianal fistulas. *Gastroenterology* 2001;121:1064-72.
99. Gecse KB, Bemelman W, Kamm MA, Stoker J, Khanna R, Ng SC, Panes J, van Assche G, Liu Z, Hart A, Levesque BG, D'Haens G. A global consensus on the classification, diagnosis and multidisciplinary treatment of perianal fistulising Crohn's disease. *Gut* 2014;63:1381-92.
100. Colombel JF, Solem CA, Sandborn WJ, Booya F, Loftus EV, Jr., Harmsen WS, Zinsmeister AR, Bodily KD, Fletcher JG. Quantitative measurement and visual assessment of ileal Crohn's disease activity by computed tomography enterography: correlation with endoscopic severity and C reactive protein. *Gut* 2006;55:1561-7.
101. Fichera A, Cicchiello LA, Mendelson DS, Greenstein AJ, Heimann TM. Superior mesenteric vein thrombosis after colectomy for inflammatory bowel disease: a not uncommon cause of postoperative acute abdominal pain. *Diseases of the colon and rectum* 2003;46:643-8.
102. Paparo F, Bacigalupo L, Garello I, Biscaldi E, Cimmino MA, Marinaro E, Rollandi GA. Crohn's disease: prevalence of intestinal and extraintestinal manifestations detected by

computed tomography enterography with water enema. Abdominal imaging
2012;37:326-37.

Table 1. Imaging findings associated with small bowel Crohn’s disease inflammation. Bold items are required descriptive terms that should be used when present. Conclusions are based on criteria identified in the Methods, with the level of evidence summarized accordingly as very low, low, moderate or high.

Imaging Findings	Description/Definition	DDX Considerations/Comments	Conclusions (Level of evidence)
Segmental Mural Hyperenhancement	Increased attenuation/signal intensity on contrast-enhanced scan in non-contracted segment in comparison to nearby normal small bowel segments	<ul style="list-style-type: none"> • Predictive but non-specific sign^{35, 40} • Causes include Crohn’s disease-related mural inflammation, backwash ileitis, infectious enteritis, mucositis, graft vs. host disease, contraction or underdistension, radiation enteritis, NSAID enteropathy, angioedema, vasculitis, and ischemia. • Altered enhancement in Crohn’s disease can also reflect processes other than inflammation such as fibrosis or chronic mesenteric venous occlusion • More likely indicates Crohn’s disease when asymmetric and combined with other mural and mesenteric findings below 	<ol style="list-style-type: none"> 1. Segmental mural hyperenhancement and wall thickening have a moderately high sensitivity and specificity for small bowel Crohn’s disease at CT or MR enterography. (<u>Moderate</u>)³⁶⁻³⁹ 2. Mural hyperenhancement without wall thickening is a non-specific imaging sign, and may reflect inflammation or other processes. (<u>Moderate</u>)^{23, 36, 39, 40} 3. CT and MR enterography may detect small bowel inflammation not seen at ileocolonoscopy. (<u>Moderate</u>)^{3, 5, 67} 4. CT and MR enterography with oral contrast only will not detect or stage colonic inflammation as well as ileocolonoscopy. (<u>Moderate</u>)⁶⁷⁻⁶⁹
Asymmetric	Asymmetric in cross-sectional or longitudinal direction compared to the lumen. Mesenteric border is often more affected than anti-mesenteric border	<ul style="list-style-type: none"> • Specific finding for Crohn’s disease⁴⁰ • Can refer to morphologic pattern of hyperenhancement, wall thickening or stratification 	
Stratified (Bi- or Tri- Laminar)	Inner-wall hyperenhancement or halo sign	<ul style="list-style-type: none"> • In Crohn’s disease, can be due to submucosal edema, intramural fat deposition or inflammatory infiltration 	

		<ul style="list-style-type: none"> • Can also be due to other causes of segmental mural hyperenhancement above • “Mucosal hyperenhancement” is erroneous descriptor as mucosa is often absent at endoscopy in inflamed loops with stratified segmental hyperenhancement • Intramural fat indicates chronicity and is unrelated to whether inflammation is present or not • Intramural edema indicates active inflammation if due to Crohn’s disease • At this time, no clinical significance is attributed to either the bi- or tri-laminar pattern; the tri-laminar pattern is more often identified on contrast enhanced MR, likely owing to its superior contrast resolution vis-à-vis CT 	<p>5. Hyperintense T2-weighted signal and restricted diffusion at MR enterography is correlated with moderate to severe endoscopic inflammation. (Moderate)^{24, 36, 70-72}</p> <p>6. Unenhanced MR enterography with diffusion-weighted imaging has a moderate sensitivity and specificity for detection of ileal Crohn’s disease. (Moderate)^{24, 73-75}</p>
Homogeneous, symmetric	Transmural hyperenhancement	<ul style="list-style-type: none"> • Can be due to many causes including edema, collagen deposition, infiltration, ischemia, shock bowel 	
Wall Thickening		<ul style="list-style-type: none"> • Only measured or estimated in bowel loops distended by enteric contrast • Measure the thickest portion of most distended segment or site of most severe inflammation 	
Mild	3 - 5 mm ^{22, 23, 25, 40}		
Moderate	5 - 9 mm		

Severe	$\geq 10 \text{ mm}$ ²¹	<ul style="list-style-type: none"> Look for signs of tumor for focal stenoses > 1.5 cm in diameter—mass, extension into adjacent mesentery, etc... 3, 76, 77 	
Intramural edema	Hyperintense signal on fat-saturated T2-weighted images; only on MR (cannot comment on intramural edema with CT) ²³	<ul style="list-style-type: none"> In comparison to normal small bowel. Increased hyperintensity on T2-weighted images is associated with more severe inflammation²³ In regions of Crohn's disease-related inflammation on gadolinium-enhanced images, increased diffusion-weighted signal abnormality is associated with more severe inflammation²⁴ 	
Stricture	<p>Luminal narrowing in area of Crohn's disease:</p> <ul style="list-style-type: none"> With unequivocal upstream dilation 	<ul style="list-style-type: none"> Location and length should be described for potential subsequent surgical or endoscopic intervention Remember that strictures also arise from NSAID and radiation enteropathy, and adhesions can mimic Crohn's disease strictures⁷⁸ 	<p>7. Most Crohn's disease strictures have both inflammation and fibrosis. (High)^{21, 49, 50, 52}</p> <p>8. A stricture is present when the lumen is narrowed, and there is proximal small bowel dilation. (High)^{30, 49, 50, 68, 79}</p>
without upstream dilation	<ul style="list-style-type: none"> Upstream lumen < 3 cm When multiple pulse sequences, fluoroscopic observation, or serial imaging exams demonstrated fixed narrowing without upstream dilation, it is appropriate to describe that a probable stricture is present 	<ul style="list-style-type: none"> Degree of upstream dilation can be highly variable based on many factors including chronicity, ingested material, etc... Focal reduction in luminal diameter despite adequate enteric contrast in a bowel loop with imaging findings of Crohn's disease 	<p>9. Proximal small bowel dilation may correlate with a higher burden of fibrotic disease. (Low)^{21, 30, 49, 50, 80}</p> <p>10. CT and MR enterography can detect unsuspected small bowel strictures in Crohn's disease patients. (Low)^{10, 81}</p>

with <i>mild</i> upstream dilation	Upstream lumen = 3- 4 cm		
with moderate to severe upstream dilation	Upstream lumen > 4 cm	<ul style="list-style-type: none"> When present, careful assessment of the transition point should be performed in order to determine the cause of the bowel obstruction. Differential diagnosis includes mixed stenotic and active inflammatory Crohn's disease, adhesive disease and tumor; when moderate to severe may be appropriate to state in Impression "small bowel obstruction" 	
Ulcerations	Appear as small focal breaks in the intraluminal surface of the bowel wall with focal extension of air or enteric contrast into the inflamed bowel wall. Do not extend beyond the bowel wall	<ul style="list-style-type: none"> When seen at cross-sectional imaging, correlates with severe endoscopic inflammation ^{4,22} Avoid the term "penetrating ulcer" so that it is not confused with penetrating disease such as fistula or abscess If transmural, useful in Lemann score 	11. Visualization of ulcers at cross-sectional enterography is a marker of severe inflammation. (High) ^{4, 19, 22, 82}
Sacculations	Broad-based outpouchings that occur along the anti-mesenteric border due to acute or chronic mesenteric border inflammation	<ul style="list-style-type: none"> Sequela of asymmetric mural inflammation with shortening of the gut along the mesenteric border 	
Diminished motility	Alerts radiologist to locations of potential disease	<ul style="list-style-type: none"> Rely on conventional imaging features of intestinal inflammation for diagnosis and severity assessment Cine true-FISP imaging can display peristalsis and may be helpful in improving confidence that inflammation is absent 	12. Altered motility can be helpful in identifying Crohn's inflammation. (Moderate) ⁸³⁻⁸⁶

Table 2. Imaging findings of penetrating disease and mesenteric inflammation in Crohn’s disease.

Imaging Findings	Description/Definition	Comments	Finding
FISTULAS			
Simple fistula	Appears as an extra-enteric tract, with or without internal air or fluid ⁸⁷ ; affected loops are often angulated or tethered ⁸⁸	<ul style="list-style-type: none"> • Fistulas should be described by bowel loop origin and structure to which they connect • Usually arise from within or just proximal to a stricture ^{28, 29} • Usually arise proximal to or from a stricture with active inflammation • Consider post-operative leak in addition to fistulizing Crohn’s disease when examining extra-enteric tracks originating in the region of enteric anastomoses 	<p>13. CTE and MRE have similar and moderately high accuracy for penetrating Crohn’s disease (fistulas, inflammatory mass, abscess).(Moderate) ^{49, 68, 87-90}</p> <p>14. Penetrating complications detected at CT and MR enterography may occur in unsuspected patients. (Low) ^{87, 91, 92}</p>
Complex Fistulas	Multiple tracts often forming an asterisk-shaped or “clover-leaf” appearance, or “star sign”; affected loops often angulated or tethered; an interloop abscess or inflammatory mass may be present		
Sinus Tract	Wall defect that extends outside bowel wall but not to adjacent organs or skin (usually		

	accompanied by angulation and tethering of adjacent bowel or urinary bladder)		
Perianal fistulas	Arise from rectum or anus and extend to skin in perineal region or vagina	<ul style="list-style-type: none"> Describe according to Parks' or St. James' Classification^{93, 94}, and recommend dedicated pelvic MR for assessment prior to surgical intervention or for activity assessment Imaging of the anus mandatory part of any CT or MR enterography exam About one-quarter present at or before time of Crohn's disease diagnosis Incidence varies by age and location of disease^{95, 96} 	15. Pelvic MRI is the most accurate test for the detection and characterization of perianal Crohn's disease, but every CTE and MRE should image the anal sphincter complex and perineum. (High) ⁹⁷⁻⁹⁹
Inflammatory Mass	Ill-defined mass-like process of mixed fat and/or soft tissue attenuation/signal intensity (not water attenuation/signal intensity) usually associated with penetrating disease such as complex fistulas	<ul style="list-style-type: none"> Associated with inflammatory stranding in mesenteric tissues. Use of the term "phlegmon" is discouraged 	N/A
Abscess	Mesenteric/Peritoneal/Perianal Fluid Collection with rim enhancement and/or internal air	<ul style="list-style-type: none"> May be difficult to distinguish from confined leak in post op setting 	N/A
Perienteric edema/inflammation	Increased attenuation (CT) or high T2 signal or restricted diffusion (MR) in mesenteric fat adjacent to abnormal bowel loops; if perirectal, then	<ul style="list-style-type: none"> Often associated with mesenteric border inflammation. Associated with elevated CRP¹⁰⁰ 	

	circumferential		
Engorged vasa recta	Engorged vasa recta that supply an inflamed bowel loop (“comb sign” ⁴³)	<ul style="list-style-type: none"> • May be a marker of inflammation but may also reflect past inflammation 	
Fibrofatty Proliferation	Increased fat adjacent to abnormal bowel, displacing bowel loops; usually along mesenteric border, but can be circumferential	<ul style="list-style-type: none"> • Also called “creeping fat” 	
Mesenteric venous thrombosis/occlusion	<ul style="list-style-type: none"> • If acute, an intraluminal thrombus is seen • If chronic, narrowed central mesenteric veins are seen, with dilated peripheral collaterals forming via mesenteric branches and small bowel varices. If chronic suggest using term chronic mesenteric venous occlusion 	<ul style="list-style-type: none"> • Central, acute mesenteric thromboses in PV/SMV often resolve, but peripheral mesenteric thromboses often become chronic⁶² • Associated with stricture formation and surgery⁶³ 	16. Acute mesenteric vein thromboses and chronic mesenteric vein occlusions can be detected at CT and MR in Crohn’s disease patients, and may be central or peripheral. (<u>Low</u>) ^{63, 88, 101}
Adenopathy	Lymph node > 1.5 cm in short axis	<ul style="list-style-type: none"> • Reactive lymphadenopathy 1 – 1.5 cm in short axis diameter is considered normal in Crohn’s disease 	

Table 3. Extra-intestinal findings relevant to Crohn’s disease and seen at CT and MR enterography.

Imaging Findings	Description/Definition	Comments
Sacroiliitis	Subtle erosions to frank fusion of SI joint, including increased T2 signal, subchondral marrow edema or enhancement; contrary to dogma, this is often asymmetric with only one side affected or one side more affected than the other	
Primary sclerosing cholangitis (PSC)	Discontinuous, intrahepatic biliary ductal visualization and/or extrahepatic ductal wall thickening / enhancement without significant upstream dilation	
Avascular necrosis	Focal sclerosis along the anterior aspect of the femoral head, best seen on coronal views with bone windows	Describe if articular collapse is present or not
Pancreatitis	Can be medication-induced, due to cholelithiasis or idiopathic duct centric pancreatitis (steroid-responsive pancreatitis; formerly type II autoimmune pancreatitis)	
Nephrolithiasis & cholelithiasis ¹⁰²		Describe presence and burden
Cutaneous findings	Including pyoderma gangrenosum, erythema nodosum or cutaneous vasculitis	Can be seen in multiple locations (e.g., thighs, abdominal wall, vulvar)

Table 4. Recommendations for use of CT or MR enterography, and incorporation of imaging findings into the clinical report.

A strong recommendation indicates confidence that the desirable effects of the test or interpretation will result in a positive impact on patient care. A weak recommendation indicates that uncertainty exists relating to the positive and negative impacts on patient care.

1. Radiologists should indicate that inflammatory small bowel Crohn's disease is likely when either (i) in known Crohn's patients when mural hyperenhancement and wall thickening are present, or (ii) when enteric inflammation is asymmetric or co-exists with the typical penetrating complications of Crohn's disease. (STRONG)
2. Radiologists should report the number of involved bowel segments, approximate location (proximity to ileocecal valve or ligament of Treitz), length and degree of upstream dilation of Crohn's strictures so that gastroenterologists and surgeons can decide on the best therapeutic option and approach. (STRONG)
3. When describing bowel loops having a Crohn's stricture or penetrating disease (sinus tract, abscess or enteric fistula), radiologists should state if imaging findings of mural inflammation are present (STRONG).
4. Cross-sectional enterography should be performed at diagnosis of Crohn's Disease to detect small bowel inflammation and penetrating complications beyond the reach of standard ileocolonoscopy. (STRONG)
5. Cross-sectional enterography should be considered in disease monitoring paradigms when small bowel disease or penetrating disease complications are present. (STRONG)
6. Dedicated pelvic MR (Perianal fistula MRI protocol) is required for the adequate preoperative assessment of perianal Crohn's disease and its complications (number of fistula tracts, location and relationship to anal sphincter muscle complex, and presence of abscess), but every CTE or MRE should image the anus, and radiologists should comment if findings suspicious for perianal disease (fistula or abscess) are present. (STRONG)
7. Because intramural T2 hyperintensity, restricted diffusion, peri-enteric stranding, wall thickness and mural ulcerations seen at cross-sectional enterography generally correlate with severity of endoscopic and histologic inflammation, radiologists should comment on these findings and describe them when present. (STRONG)
8. MRE should be used rather than CT enterography, when possible, for estimating response to medical treatment in asymptomatic Crohn's disease, as its multiparametric nature permits evaluation of multiple imaging parameters that reflect inflammation and avoids radiation. (WEAK)
9. If cross-sectional enterography is indicated and IV contrast cannot be administered, non-contrast MR enterography with T2-weighted and diffusion-weighted imaging should be used as an acceptable alternative. (WEAK)

10. CTE and MRE exams should be carefully evaluated for evidence of mesenteric venous thromboses or occlusions and small bowel varices. (STRONG)

Table 5. Recommended impressions summarizing imaging findings of small bowel Crohn’s disease at CT and MR enterography. Colonoscopy is considered the reference standard for colorectal inflammation. Recommendations for CT and MR enterography descriptions of colorectal inflammation are not provided, but can parallel descriptions of small bowel inflammation, stricture and penetration.

Impression	Imaging Findings	Comment
<u>Inflammation</u>		
Non-specific small bowel inflammation	<ul style="list-style-type: none"> • Segmental hyperenhancement and/or wall thickening in a patient without known Crohn’s disease 	<ul style="list-style-type: none"> • Please see segmental hyperenhancement in Table 1 above for differential diagnosis
Active Inflammatory Small Bowel Crohn’s disease -Without Luminal Narrowing -With Luminal Narrowing	<ul style="list-style-type: none"> • Asymmetric wall thickening, hyperenhancement and mural edema (i.e., intramural T2-weighted signal) are specific for Crohn’s disease involvement. • Ulcers, wall thickening, restricted diffusion and perienteric stranding indicate more severe disease • Asymmetry is not required at sites of known prior disease or in a known Crohn’s disease patient 	<ul style="list-style-type: none"> • Describe sites, lengths, and add descriptors representing severity • Compare lengths and severity of disease if assessing for disease response or progression • Severe inflammation is manifested by ulcerations, marked T2-weighted signal hyperintensity and restricted diffusion, and severe wall thickening • Mild disease is manifested by hyperenhancement, mild wall thickening, and absence of severe signs of inflammation
Crohn’s disease with no imaging signs of active inflammation (known prior active inflammatory Crohn’s disease with residual radiologic findings)	<ul style="list-style-type: none"> • Imaging findings of inflammation are absent • Patchy intramural fat or residual pseudosacculation/scarring without inflammation may be seen • Imaging findings of inflammation 	<ul style="list-style-type: none"> • Mural healing can only be described when the present study demonstrates a normal bowel segment that was inflamed on a prior exam

<p>No imaging signs of active inflammation</p>	<p>are absent</p>	<ul style="list-style-type: none"> •
<p><u>Stricture</u> With imaging findings of active inflammation</p>	<ul style="list-style-type: none"> • Persistent luminal narrowing in area of Crohn’s disease with upstream dilation • Accompanying imaging findings of active inflammation • Consider adding “with small bowel obstruction” if upstream dilation moderate to severe 	<ul style="list-style-type: none"> • Describe locations and lengths of strictures and degree of obstruction • Describe degree of inflammation
<p>Without imaging findings of active inflammation</p>	<ul style="list-style-type: none"> • Persistent segmental luminal narrowing with upstream dilation • Wall thickening is present, but with absence of inflammatory findings on imaging 	<ul style="list-style-type: none"> • Describe location, length, degree of obstruction
<p>Penetrating Crohn’s Disease (added <i>in addition to</i> determination of inflammatory Crohn’s disease and stricture)</p>	<ul style="list-style-type: none"> • Fistula and/or sinus tract; inflammatory mass; abscess; free perforation 	<ul style="list-style-type: none"> • Describe location and type, as well as association with Crohn’s disease stricture or inflamed bowel segment. • State if fistulas are simple or complex • Carefully examine for asterisk-shaped fistulas complexes
<p>Perianal Crohn’s Disease</p>	<ul style="list-style-type: none"> • Perianal fistula – simple, complex • Perianal abscess – present/absent 	<ul style="list-style-type: none"> • Describe perianal disease including associated abscess with size according to accepted criteria, if possible⁵⁸

- Recommend consideration of pelvic MRI

Other complications

- Mesenteric venous thrombosis or occlusion, AVN, PSC, sacroiliitis, pancreatitis, neoplasm, cholelithiasis or kidney stone

Table 6. Suggested reporting template adapted from Baker et al ⁷.

MR or CT Enterography with intravenous contrast

Appropriate entries for patient history, CT technique, oral and intravenous contrast media, other medications and radiation dose as per institutional guidelines.

Comparison:

Findings:

- Disease location (stomach, duodenum, jejunum, mid or distal ileum, terminal ileum, colon, rectum, anus)
- Number of diseased segments
- Type(s) of disease (if all segments have similar findings then report once; if one or more segments are different then report each separately)
 - *Inflammation*
 - Describe imaging findings of inflammation (hyperenhancement, enhancement pattern, bowel wall thickening, intramural edema, ulcerations, restricted diffusion)
 - Describe location, length and severity (see **Table 1**), and describe stability or increase or decrease compared to prior studies
 - Other mesenteric findings (e.g., mesenteric vein thrombosis, perienteric edema, comb sign, fibrofatty proliferation)
 - *Stricture*
 - State if imaging findings of inflammation is/are present
 - Describe location and length
 - Describe degree of upstream dilation (mild <4 cm, moderate to severe ≥ 4 cm)
 - *Penetrating complications* – describe sinus tract, fistula, inflammatory mass, abscess or perforation
 - Site
 - Complexity
 - Relationship to inflamed bowel or stricture
 - *Perianal Disease*
 - *Site*
 - *Complexity/classification*
 - *Associated abscess – presence or absence*

- *Response to therapy*
 - Compare to earlier exams to describe resolution or exacerbation of inflammatory findings
- Extra-intestinal findings - sacroiliitis, AVN, PSC, cholelithiasis, nephrolithiasis,
- Other complications or unrelated findings – e.g., chronic mesenteric vein thrombosis

Impressions (add modifiers as shown in Table 4):

- **Inflammation statement:** *If inflammation is present, specify location and length, estimate severity or change*
 - *Non-specific small bowel inflammation*
 - *Active inflammatory small bowel Crohn's disease (± luminal narrowing)*
 - *Crohn's disease with no imaging signs of active inflammation*
 - *No imaging signs of small bowel inflammation*
- **Stricture Statement:**
 - *Stricture with signs of active inflammation – specify length of stricture and degree of proximal obstruction*
 - *Stricture without signs of active inflammation - specify length and degree of proximal obstruction*
- **Penetrating Statement** – *describe type of fistula, simple or complex, and other penetration, and association with strictures and enteric inflammation*
- *Perianal fistula (if present)*
- *± Other complications*

Figures

Fig. 1 -Imaging-based morphologic construct that demonstrates the role of mural inflammation in driving small bowel Crohn's disease and its stricturing and penetrating complications. Mild non-specific mural inflammation can progress into asymmetric disease with greater and more characteristic mucosal and mural inflammation. Similarly, small bowel loops affected by active inflammatory small bowel Crohn's disease can progress to stricturing and penetrating complications, revert to normal in appearance, or have residual sequela of prior inflammation such as asymmetric mural fat and pseudosacculation but without imaging signs of inflammation.

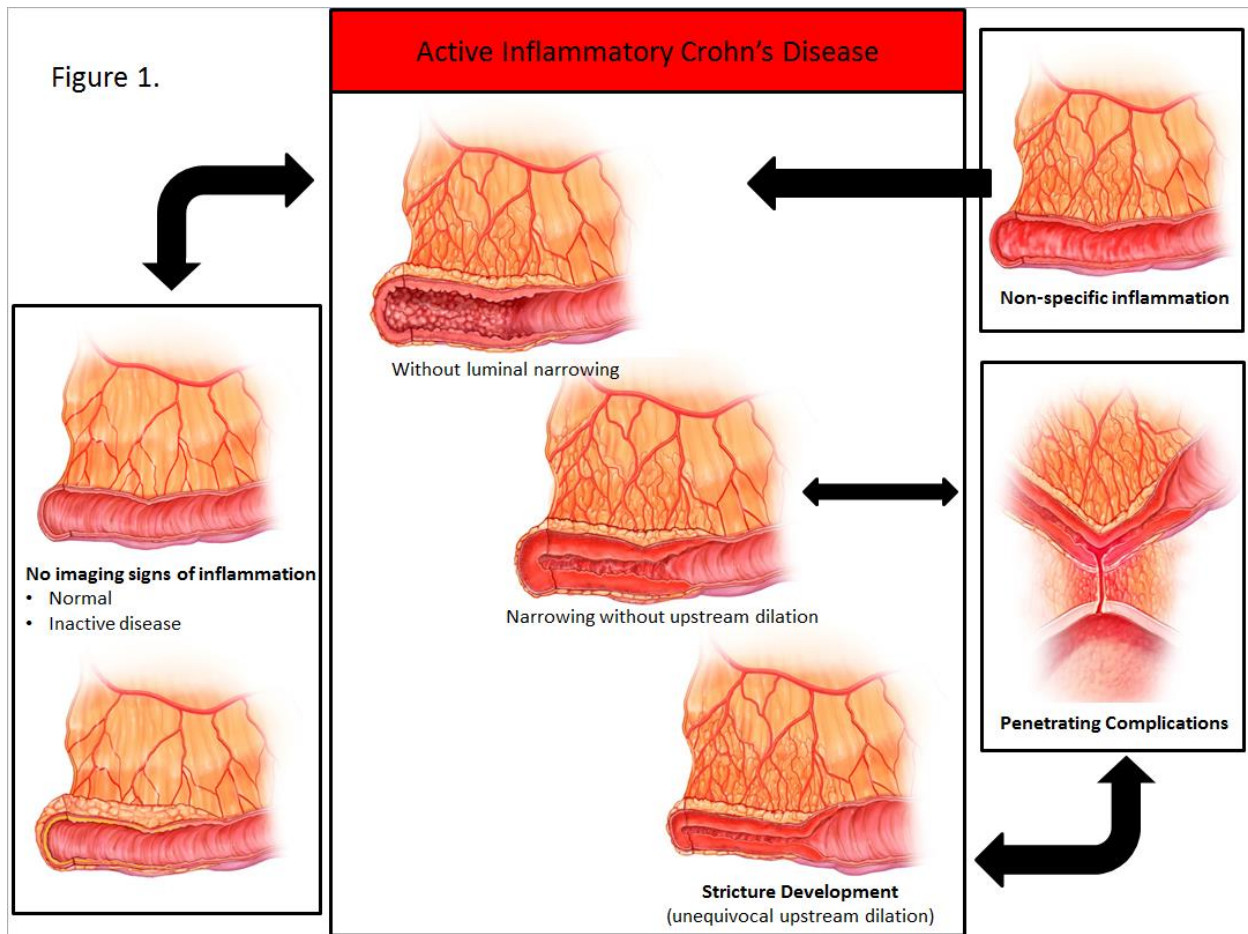


Fig. 2 – Asymmetric imaging findings of inflammation are characteristic of active inflammatory small bowel Crohn’s disease and occur most prominently along the mesenteric border. CT enterography images show patchy mesenteric border inflammation in the terminal ileum (top left, arrows), which nearly completely resolves after patient received combination therapy over one year (top right). Another patient demonstrates marked inflammation along the mesenteric border with wall thickening and hyperenhancement (bottom left, arrows), engorged vasa recta and restricted diffusion (bottom left, inset). A third patient shows findings of asymmetric involvement with mesenteric border wall thickening (bottom right, white arrow) and antimesenteric pseudosacculation (bottom right, black arrow).

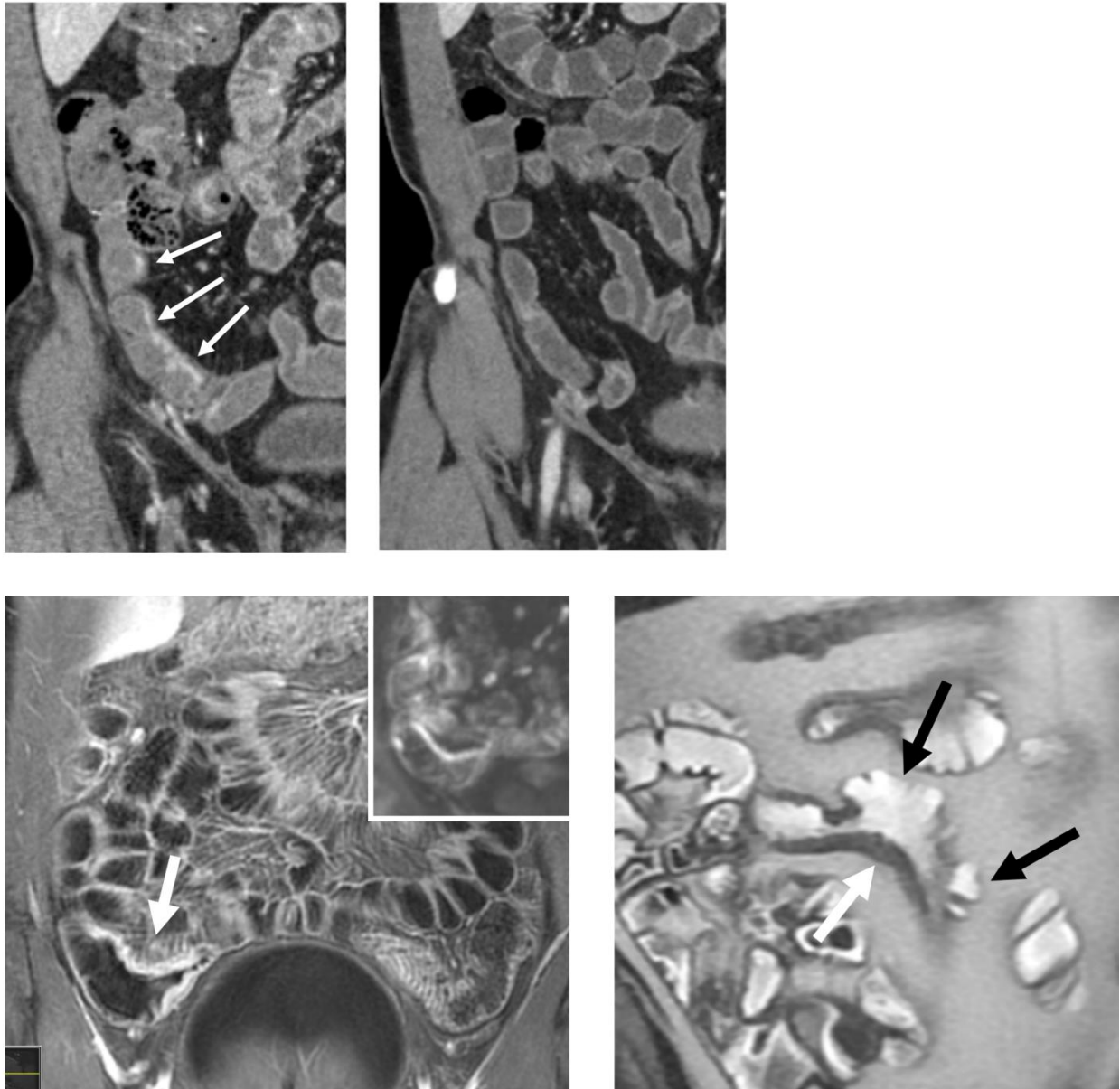


Fig. 3 – Imaging findings of severe small bowel inflammation at MR and CT enterography in three different patients. Top row shows substantial wall thickening, intramural edema on T2-weighted fat-saturated image, restricted diffusion, and small ulcerations on gadolinium enhanced images. Middle row shows findings of inflammation with wall thickening with ulcerations, intramural fat on enteric phase imaging indicating chronicity, and persistent layered enhancement indicating active inflammation on delayed imaging. Bottom row shows CT enterography images demonstrating severe inflammation with marked wall thickening and ulcerations (bottom row, white arrows).

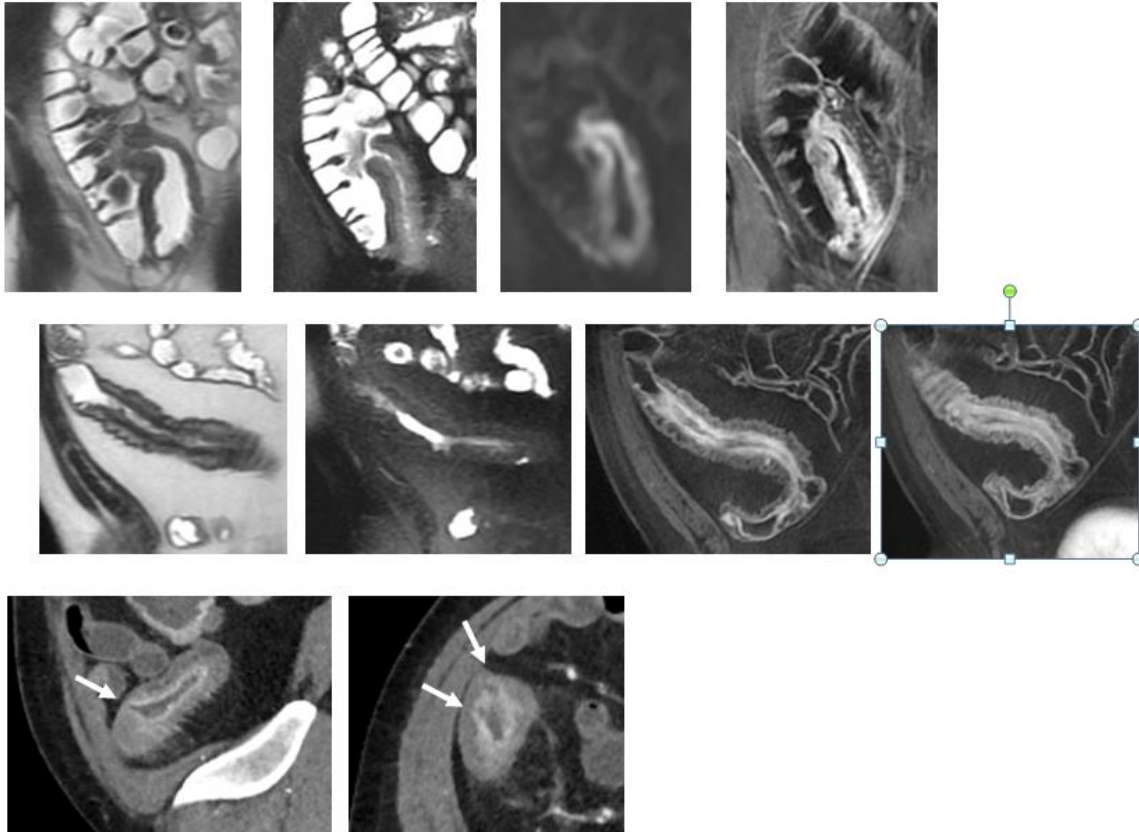


Fig 4. – Imaging findings of small bowel strictures in Crohn’s disease patients. Coronal image from CT enterography in patient with prior ileocecectomy demonstrates short segment stenosis (top left, arrow) without imaging findings of inflammation, with subsequent endoscopy not identifying any evidence of mucosal inflammation either. Two jejunal strictures in another patient (top middle and right, arrows) with proximal small bowel dilation (top middle and right, P) demonstrate imaging findings of inflammation with mural hyperenhancement and stratification with wall thickening. Subsequent surgical resection demonstrated stricture formation with transmural inflammation in all layers of the bowel wall. Bottom row shows small bowel dilation (bottom left, P) proximal to a long segment stricture with inflammation (bottom middle and right, arrows), with single-shot fast spin-echo image showing wall thickening and ulceration (bottom middle, small arrow) and 7-minute delayed gadolinium image showing mural stratification (bottom right).

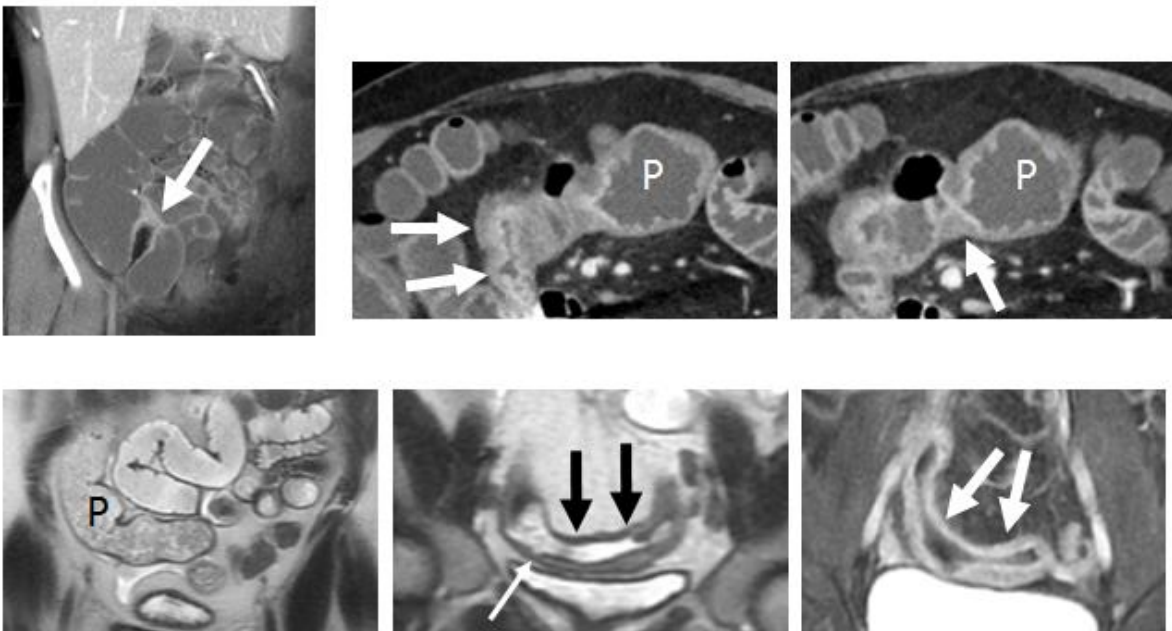


Fig. 5 – Coronal single-shot fast spin-echo images show a thickened ileal loop (top left, arrow) that is tethered and angulated to an asterisk-shaped fistula complex (arrowhead) involving multiple loops of ileum (I), sigmoid colon (S), cecal pole (C) and bladder (B). An enterocutaneous fistula also connects to this fistula complex, but is not shown. Note inflammation, as evidenced by hyperenhancement (bottom left) and restricted diffusion (bottom right), in the ileum and cecal pole (arrows).

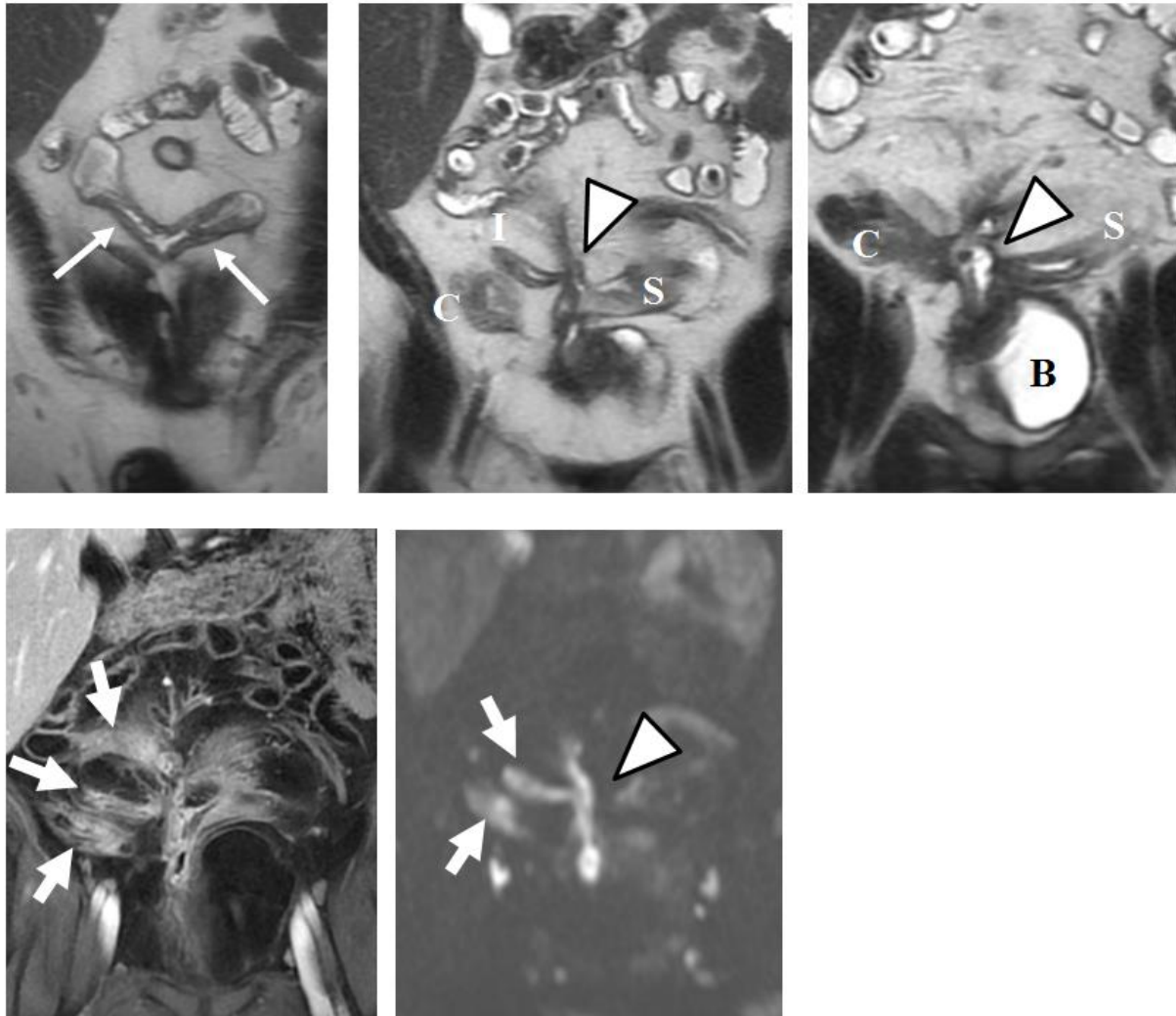


Fig. 6 – CT enterography performed to evaluate Crohn’s disease inflammation in patient with known enterocutaneous fistula demonstrates small perianal abscess adjacent to right puborectalis (left, arrow) and intersphincteric horseshoe ramifications (middle, arrows), with inferior ramification to left gluteal crease (top right, arrow). The enhancement of the normal internal anal sphincter (middle, black arrow) permits differentiation from the surrounding external anal sphincter. Patient subsequently underwent examination under anesthesia with drainage of abscess and seton placement.

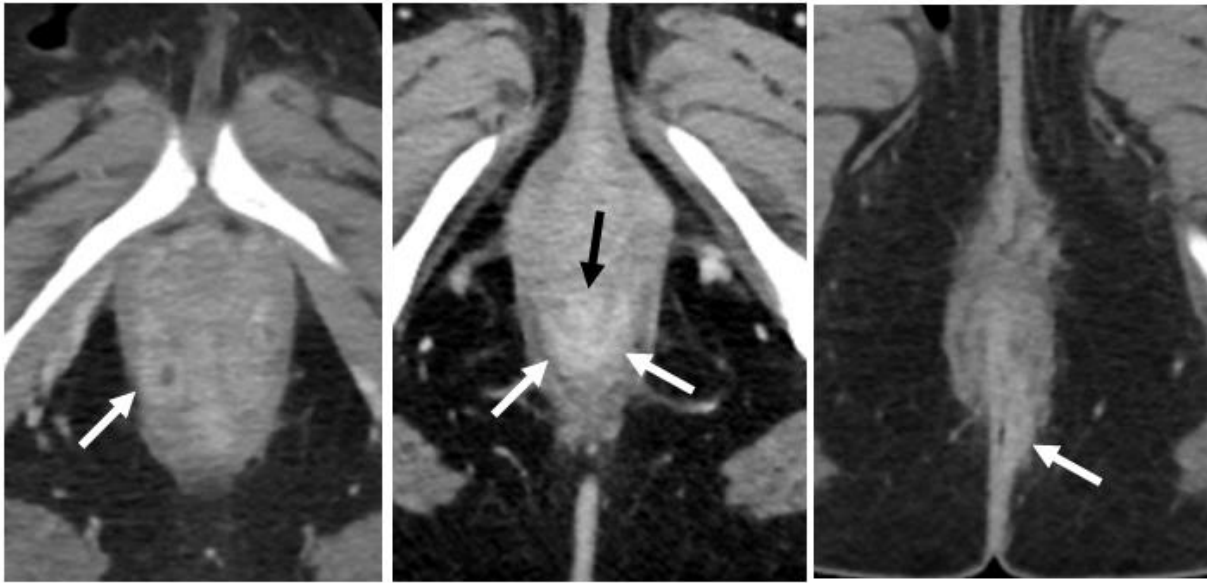

Fig. 7 – Thick coronal maximum intensity projection images from CT enterography show typical findings of chronic mesenteric venous occlusion with narrowed peripheral mesenteric vein (top left, white arrows) and dilated peripheral marginal veins (top right and bottom left, white arrowheads) that return blood back to the portal system through collateral pathways. Note distal active mural small bowel inflammation (arrow, bottom right).

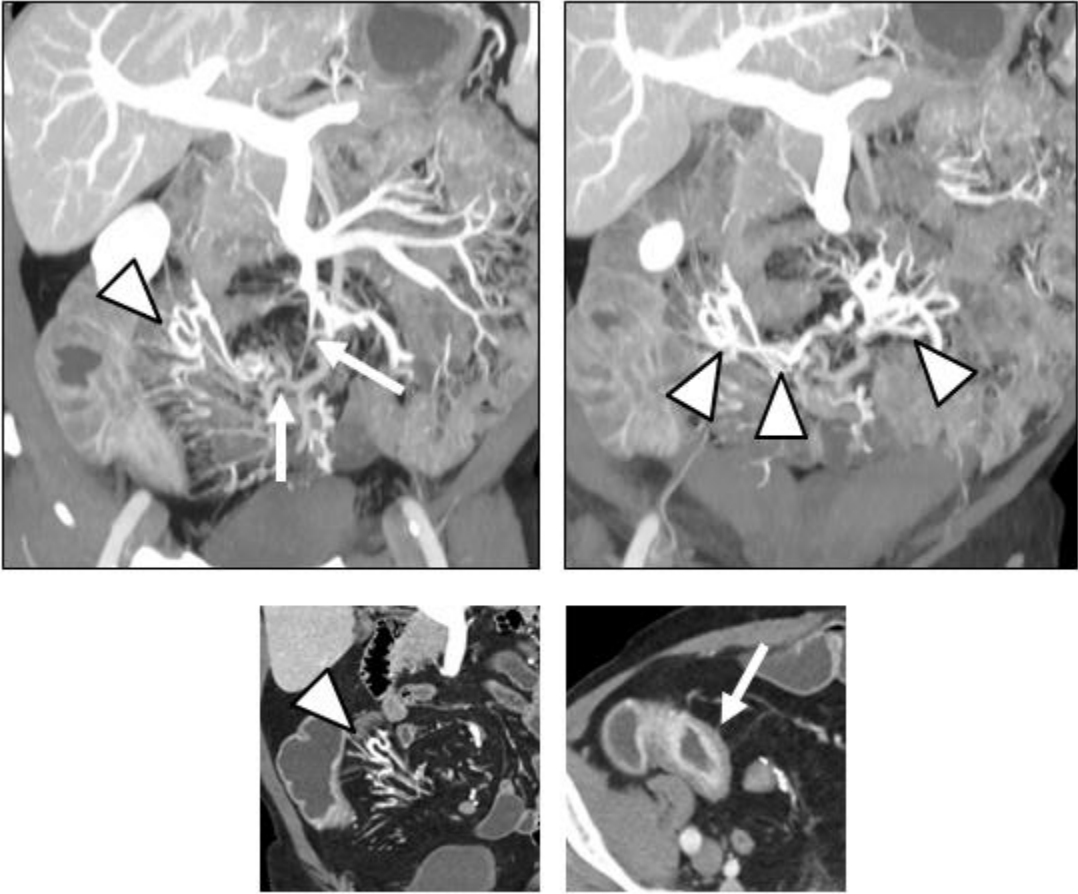
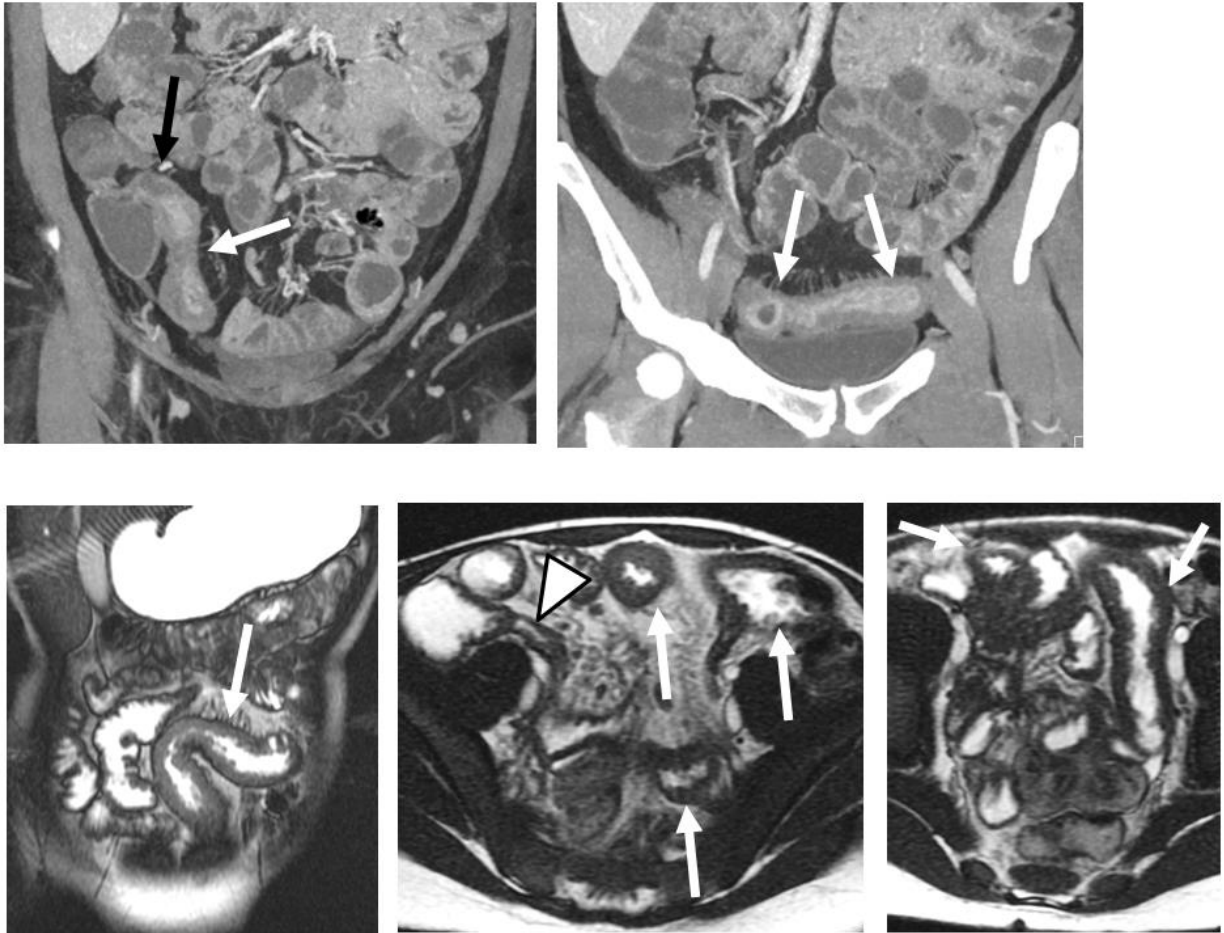


Fig. 8 – CT enterography performed two weeks after normal ileocolonoscopy show that the very distal terminal ileum (top left, black arrow) appears normal, but moderate to severe asymmetric inflammation indicating Crohn’s disease is present in the more proximal terminal ileum for approximately 20 cm (top row, white arrow). On bottom row in a different patient, MR enterography images demonstrate severe active small bowel inflammation (arrows) involving long segments of jejunum and ileum, but normal-appearing terminal ileum (arrowhead). Subsequent ileoscopy and biopsy were normal.



Appendix. Linkage between Lemann Index of Digestive Disease Damage & SAR Terms for Disease State (Impressions)

The Lemann Index or Score was developed to describe the digestive disease location, severity, extent, progression and reversibility of Crohn’s disease as measured by imaging findings and surgery. The scale is based upon three aspects: stricturing lesions, penetrating lesions and the history of surgery or any other interventional procedure. For each aspect, a grade is assigned from 0-3, and is summarized below ^{25, 65}.

Grade	Stricturing Lesion	Penetrating Lesion
0	Normal	Normal
1	Wall thickening < 3 mm or segmental enhancement; No prestenotic dilation	-
2	Wall Thickening ≥ 3 mm or mural stratification; No prestenotic dilation	Deep Transmural Ulceration
3	Stricture with Prestenotic Dilation	Abscess or Fistula

The endorsed Consensus terms for Disease State are analogous to the Lemann index , facilitating the transfer of imaging reporting into disease damage (below), the primary difference being that the Lemann index does not necessarily state that imaging findings of inflammation are present for grade 1 or 2 strictures. For example, findings of prior inflammation such as intramural fat could cause wall thickening, which would be classified as grade 2 strictures using Lemann, and which would not be classified as active inflammation or strictures under the current proposal. Additionally, the current proposal creates a stronger linkage to stricturing disease when penetrating complications are present.

Consensus Disease State	Lemann Stricture Grade	Lemann Penetrating Grade
No imaging signs of active inflammation	0	0
Active Inflammatory without Luminal Narrowing	1	Unlikely to occur (2 if deep transmural ulcers present; otherwise score of 0)
Active Inflammatory with Luminal Narrowing	2	2 if deep transmural ulcers present; otherwise score of 0
Stricture with Active Inflammation	3	2 if deep transmural ulcers present; otherwise score of 0
Penetrating Disease	0	3