

Myocardial Function in Long-Term Survivors of Childhood Cancer: Insights Using Conventional and Novel Cardiovascular Magnetic Resonance Techniques

Quyam S¹, Steeden J¹, Chowdhary T³, Muthurangu V¹ and Hughes ML^{2*}

¹UCL Centre for Cardiovascular Imaging, University College London, 30 Guildford Street, London, United Kingdom

²Cardiorespiratory Unit, Great Ormond Street Hospital for Children, London, United Kingdom

³Haematology & Oncology Department, Great Ormond Street Hospital for Children, London, United Kingdom

*Corresponding author: Marina Hughes,
Email: marina.hughes@gosh.nhs.uk

Received: 08 April 2017; Accepted: 21 June 2017; Published: 29 June 2017

Abstract

Aim: Using conventional and novel cardiac magnetic resonance (CMR) techniques, we examined cardiac function in a cohort of late cancer survivors, previously studied with echocardiography in childhood. We compared to healthy controls, to characterize current state in the context of longitudinal functional data.

Methods: 30 patients treated with anthracyclines in childhood and 19 matched controls underwent echocardiography and CMR. Additionally, CMR myocardial T1 maps were obtained using a Modified Look-Locker Inversion Recovery (MOLLI) sequence, and CMR tissue phase mapping (TPM) was performed using a rotating golden-angle spiral acquisition.

Results: Patients were a median (range) age 33 (25-43) years, and were studied 27(16-33) years following a cumulative anthracycline dose of 220 (90-370) mg/m². Mean extracellular volume fraction (ECV) in patients was 0.26 ± 0.04, and was higher in patients receiving cumulative doses of >300mg/m² (0.25 ± 0.02 vs. 0.28 ± 0.05, p=0.02). Native myocardial T1 was similar between patients and controls (967 ± 37 vs. 960 ± 37, p=0.53). TPM-derived LV radial and longitudinal systolic velocities, and longitudinal E:A ratio were not significantly reduced. Current CMR-derived LV ejection fraction was normal, although reduced compared to controls (61% ± 6 vs. 65% ± 5, p<0.01). This correlated negatively with cumulative anthracycline dose (R² 0.26, p<0.01) and positively with historic echo fractional shortening (R² 0.27, p<0.03).

Conclusion: This detailed CMR assessment of a cohort of survivors, 25 years following childhood anthracycline chemotherapy, showed persistent impairment, but often sub-clinical and dose-dependent. Novel CMR myocardial characterization and motion analysis found no differences compared to controls, but with greater numbers, these techniques may provide insight into long-term features of myocardial damage and remodeling.

Keywords: Anthracycline; Cardiotoxicity; Magnetic resonance imaging; Tissue phase mapping

Background

Progressive advances in treatment strategies for childhood cancer have resulted in great improvements in survival, with overall 5-year

survival almost 80% [1]. However, cardiovascular complications are a leading cause of morbidity and mortality in long-term survivors [2].

Compared to the general population, survivors of childhood cancer are at an increased risk of developing congestive cardiac failure, and are at increased risk of premature death due to cardiac causes [2]. There is a strong, dose-dependent relationship between anthracycline chemotherapy and risk of congestive cardiac failure, which is further increased by exposure to chest radiation.

In survivors of childhood cancer, there is often a long latency period between the cardiotoxic exposure to anthracyclines and clinically evident disease. North American and European groups have recently harmonized clinical practice guidelines for monitoring survivors of childhood cancer [3]. Among many recommendations from this group, is advice for long-term echocardiographic surveillance, in the first instance [4]. However, echocardiography is less sensitive than cardiac MRI when detecting sub-clinical myocardial abnormality [5]. Detecting subtle abnormality and predicting ongoing risk of dysfunction is crucial to rational surveillance, because early medical therapy to ameliorate loading, may alter progression.

Cardiovascular magnetic resonance is the reference standard for assessment of ventricular volume, myocardial mass and systolic function, but also has proven utility in the detection of subtle abnormalities of myocardial structure and motion.

Post mortem studies of the explanted hearts of patients transplanted for anthracycline-induced cardiomyopathy describe myocyte loss with diffuse replacement fibrosis [6]. CMR uses gadolinium-based contrast, and because this contrast remains extracellular, the resulting expansion in extracellular space can be both detected and quantified by CMR. The derived extracellular volume fraction (ECV) has been shown to correlate with diffuse myocardial fibrosis in histological specimens [7]. The extracellular volume has been shown to be elevated in adult patients treated with anthracyclines, seven years after therapy [8]. The work of Tham et al in older children showed ECV to correlate with cumulative anthracycline dose 8 years after completion of therapy [9]. However, to our knowledge, no CMR study has examined the functional and tissue characteristics of the ventricular myocardium in childhood cancer survivors beyond these earlier and middle-range periods.

Novel CMR techniques are being developed, with the ability to quantify both global and regional myocardial motion. Tissue phase mapping (TPM) allows assessment of the separate directional components of myocardial wall motion, as well as their regional distribution, with high spatial resolution [10]. By determining peak systolic and diastolic myocardial velocities in three planes, (radial, tangential and longitudinal) TPM enables quantification of both systolic and diastolic function, globally and regionally.

Combining conventional and novel CMR techniques, the aim of this study was to examine a cohort of late cancer survivors who had all previously been studied with echocardiography in childhood, in our institution. We hoped to acquire crucial longitudinal data in these patients, and at the same time assess the feasibility of CMR to characterize both subtle and overt current myocardial abnormalities, in comparison to healthy, aged-matched control subjects.

Methods

Study design

This was a cross-sectional, observational study. However, patients were recruited from cohorts of previously-studied patients, and historical data allowed longitudinal comparisons.

Study population

Eligible patients were recruited from databases of three previous research studies at our institution, Great Ormond Street Hospital for Children, in London UK [11,12]. These previous studies had utilized transthoracic echocardiography (TTE) in most patients, to describe the early cardiac effects of anthracycline chemotherapy in paediatric patients with acute lymphoblastic leukaemia (ALL), acute myeloid leukaemia (AML) and Wilms tumour (WT).

Patients from these studies, who remained under the care of the Oncology Late Effects team within our linked, adult institution, were contacted through their oncologist and invited to participate in our study.

Patients who had received a cardiac transplant following anthracycline treatment or who had concomitant congenital heart disease were excluded. Patients with standard contraindications to CMR (e.g. metallic devices, claustrophobia) were also excluded.

Ethics

The study was approved by the Great Ormond Street Hospital research Ethics Committee. All patients had normal renal function, and the use of gadolinium contrast agent was considered to be low risk. Written, informed consent was obtained from all individual participants included in the study.

Echocardiography

Transthoracic echocardiography was performed using a Philips IE33 echocardiography system (Philips Healthcare, Best, Netherlands). Conventional systolic functional parameters were measured. These included: ejection fraction (EF) by Simpson's biplane method, and fractional shortening (FS) measured in the parasternal long axis view.

Trans-mitral inflow velocities were acquired using pulsed-wave Doppler with the sample volume placed at the tip of the mitral valve leaflets in the apical 4-chamber view. The peak E-wave velocity (cm/s), peak A-wave velocity (cm/s), and ratio of E-wave to A-wave (E:A) velocities were recorded.

Tissue Doppler Imaging (TDI) myocardial velocities were measured using a standard pulsed-wave Doppler technique. Images were acquired over two consecutive cardiac cycles using low-velocity, high-intensity myocardial signals at a high frame rate (>120 MHz). The sample volume was placed at the junction of the LV wall with the mitral annulus at the septal and lateral myocardial segments in the apical 4-chamber view. Peak E' velocities (cm/s) were measured on-line and corresponding E:E' ratios were calculated.

Cardiac magnetic resonance

All CMR imaging was performed on a 1.5-T MR Scanner (Avanto, Siemens, Erlangen, Germany). A 12-element phased-array coil was used for signal reception and a vectorcardiogram system was used for cardiac gating.

Retrospective-gated steady-state free precession cine images of the heart were acquired in the vertical long axis and the 4-chamber view. Biventricular volumetric and functional assessment was performed using 10-13 contiguous short-axis cine images, covering the entirety of both ventricles.

Each individual image slice was acquired during a single breath-hold. Image variables were: repetition time 2.4ms, echo time 1.2ms, flip angle 68 degrees, slice thickness 10mm, matrix 200x240, field of view 350-400mm, and temporal resolution optimized to achieve 20 true phases.

Through-plane pulmonary artery and aortic valve flow data was acquired using a spiral triggered flow sequence during breath-hold [13].

Myocardial T1 mapping was performed using a modified Look-Locker Inversion Recovery (MOLLI) sequence [14]. Images were captured in the standard mid-cavity short axis and long axis 4 chamber views in diastole, both pre-contrast (native T1) and 15 minutes post contrast injection. Scan parameters for the MOLLI protocol were: FOV, 8mm slice thickness, flip angle 30, T1 100ms.

Gadopentetate dimeglumine (Gd-DTPA; Magnevist; Schering, Berlin, Germany) was administered at a dose of 0.15 mmol per 1 kg body weight at an injection rate of 2ml/s followed by a 10ml saline flush.

Late gadolinium-enhanced images were acquired 5 minutes after intravenous injection of contrast. TI was calculated to null the myocardium.

Hematocrit was measured at the time of CMR, by taking a blood sample at the time of peripheral intravenous access for contrast administration.

Tissue phase mapping

CMR tissue phase mapping (TPM) was performed using a respiratory self-navigated, rotating golden angle spiral acquisition with retrospective cardiac gating [10]. A single acquisition was performed at the mid-ventricular position in the short axis orientation.

Cardiac MR image analysis

All images were processed using in-house plug-ins for the open-source DICOM software OsiriX (OsiriX Foundation, Geneva, Switzerland) [15].

The biventricular end-diastolic volume (EDV) and end-systolic volume (ESV) were measured by manual segmentation of the short axis cine images. The endocardial borders were traced at end-diastole and end-systole, excluding trabeculations and papillary muscles from the blood pool. End-diastolic volume (EDV) and end-systolic volume (ESV) were calculated for each ventricle using Simpson's rule. Ventricular stroke volume (SV) was calculated with the difference between the EDV and ESV, and ventricular ejection fraction (%) was $(SV/EDV) \times 100$.

All volume measurements were indexed for the body surface area and expressed in mL/m².

Internal validation of the ventricular stroke volume data was attained by quantifying aortic and pulmonary valve forward flow volume, using a semi-automatic vessel edge-detection algorithm with operator correction.

The late-enhancement images were independently reviewed by 2 cardiologists (S.Q, M.L.H.) in a blinded fashion.

ECV values were calculated as previously described (*REF MOON) using the following formulas: $\Delta R1_{myo} = 1/T1_{myo-post} - 1/T1_{myo-pre}$; $\Delta R1_{blood} = 1/T1_{blood-post} - 1/T1_{blood-pre}$; and $ECV = \Delta R1_{myo} / \Delta R1_{blood} \times (100 - HCT)$.

For the TPM data, the endocardial and epicardial myocardial borders were manually segmented throughout the cardiac cycle, using the modulus images. Following motion correction, the inplane velocities were transformed to an internal polar coordinate system, positioned at the centre-of-mass of the segmented ventricle. This allowed motion to be identified as contraction (radial velocities) and shortening (longitudinal velocities) as previously described [16].

Colour-coded maps were generated for each velocity component to allow easy visualization of the results. Additionally, graphs of regional and global myocardial motion patterns over time were calculated, by averaging the velocity components within the region of interest. The peak velocities in the S (systolic), E (early diastolic), and A (atrial

systolic) waves were measured for the longitudinal and radial velocities within the entire myocardium

Statistical analysis

Data are presented as mean ± SD or median (range) as appropriate. Normal distribution of data was confirmed using the Shapiro-Wilk test.

Baseline demographic, CMR and echo parameters were compared between anthracycline patients and controls. A 2-sided t-test was used for normally distributed variables. Kolmogorov-Smirnov test was used for skewed data. Fisher’s exact test was used for categorical variables.

All statistical analysis was performed using Stata SE12.

Results

Study population

A total of 30 patients replied to the invitation to participate in this study, and were assessed alongside 19 age and sex-matched controls.

Patient and control group baseline characteristics were not significantly different, and are summarized in Table 1.

The patients had a median age 33 (25-43) years. The completion of their single anthracycline chemotherapy regimen had been a median 27 (16-33) years prior to this assessment.

The patients’ oncology diagnosis had been acute lymphocytic leukaemia (ALL) in 23 (77%), acute myelocytic leukaemia (AML) in 2 (7%) and Wilms Tumour (WT) in 5 (17%). They had received a median cumulative anthracycline dose of 270mg/m² (range 90-370mg/m²). Twenty five patients had received radiotherapy (16 cranial only, 9 total body or chest and abdominal) with a median dose of 18 (12-48) Gy. Seven (23%) patients had undergone bone marrow transplantation (BMT).

Five (17%) patients were known to have systolic dysfunction (defined as echocardiographic FS <25%) and were being treated with angiotensin converting enzyme inhibitors (ACEi), Angiotensin receptor blockers (ARB) or beta blockers.

Echocardiographic parameters

Twenty three patients had historical FS data available from the previous studies in our centre. This data had been obtained a median of 9 (3-20) years after completing anthracycline therapy. In these 23 patients, median previous FS was 32% (26-46)%, within the normal range.

In the present study, FS was repeated in patients and acquired in controls. The patients’ current median FS was 29% (23-37%). In these patients with longitudinal data, the previous echo FS, correlated with the current measure (R² 0.27, p <0.03) (Figure 1).

The current echo FS was not significantly different between patients and controls. Mean left ventricular internal diameter in diastole (LVIDD) was larger in patients (mean 49 ± 6mm) but did not differ significantly from controls.

Echo-derived mitral inflow velocities were normal and did not differ between patient and control groups. Peak E velocity was 0.85 ± 0.1 vs. 0.9 ± 0.1 p=0.39 and Peak A velocity was 0.53 ± 0.6 vs. 0.52 ± 0.1 with normal E:A (1.7 ± 0.3 vs. 1.7 ± 0.4 p=0.95).

Tissue Doppler imaging showed significantly reduced medial E’ velocities in patients, but no difference in lateral E prime or medial or lateral E:E’.

Conventional MRI parameters

Data in Table 2 demonstrates that global measures of left ventricular systolic function were within established normal range, but were significantly lower in patients as compared to controls. This is

explained by the increased LV end-systolic volume in patients (30 ± 8 mL/m² vs 25 ± 6mL/m², p=0.05).

In line with this, the mitral annular peak systolic excursion, measured using CMR long-axis cine images, was decreased in patients compared to controls (13 ± 2.6mm vs 15 ± 1.1mm, p=0.02).

LV mass and LV mass index were normal in the cohort, with no difference between patients and controls.

Focal mid-wall late gadolinium enhancement was present in 2 patients one of whom was known to have LV systolic dysfunction treated with ACEi.

T1 Mapping

Precontrast (“native”) T1 values for the myocardium were obtained in control subjects and patients. There was no significant difference in the mean myocardial T1 between the groups.

However, within the patient group, there was higher myocardial native T1 found in the patients who had previously received greater than 300g/m² cumulative dose of anthracyclines.

Table 1: Baseline patient and control group characteristics*.

Variable	Control (n = 19)	Patients (n = 30)	P value
Female n (%)	10 (53)	17 (57)	0.86
Current Age (years)	32 (26-39)	32 (23-42)	0.96
Height (cm)	171 ± 6.3	169 ± 9.2	0.30
Weight (kg)	67 ± 8	75 ± 21	0.10
NYHA I / II	19 (100) / 0 (0)	28 (93) / 2 (7)	0.44
Systolic BP (mmHg)	120 ± 10	123 ± 15	0.46
Diastolic BP (mmHg)	73 ± 7	75 ± 11	0.60
AML n (%)	-	2 (7)	-
ALL n (%)	-	23 (77)	-
Wilms n (%)	-	6 (17)	-
Age at diagnosis (years)	-	4.6 (1-15)	-
Time since chemo (years)	-	27 (16-33)	-
Anth Dose (mg/m ²)	-	270 (90-370)	-
Radiotherapy n (%)	-	25 (83)	-
BMT n (%)	-	7 (23)	-

* Values expressed as mean ± SD.

NYHA = New York Heart Association; BP = blood pressure; AML = acute myelocytic leukaemia; ALL = acute lymphocytic leukaemia; BMT = bone marrow transplant.

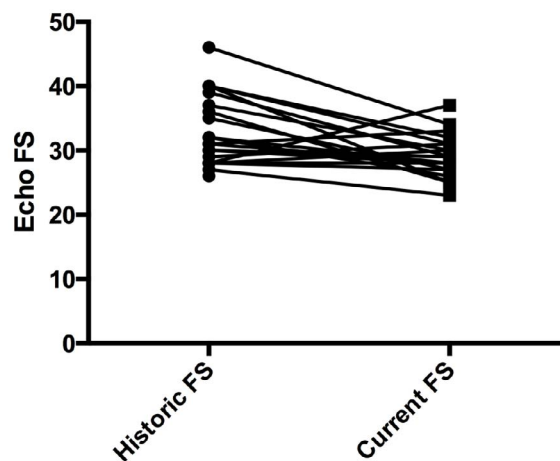


Figure 1: Fractional Shortening (%) measured with echocardiography; historic compared to current.

Table 2: Cardiovascular MR data, comparing patients and controls*.

Variable	Control (n =19)	Patients (n = 30)	p Value
LVEDV index (ml/m ²)	72 ± 8	73 ± 12	0.92
LVESV index (ml/m ²)	25 ± 6	30 ± 8	*0.05
LV EF (%)	65 ± 5	61 ± 6	*0.01
LV mass index (g/m ²)	60 ± 10	58 ± 11	0.53
RVEDV index (ml/m ²)	76 ± 8	69 ± 12	0.10
RVESV index (ml/m ²)	29 ± 6	28 ± 14	0.68
RV EF (%)	62 ± 4	63 ± 5	0.39
MAPSE (cm)	15 ± 1.1	13 ± 2.6	*0.02
Left Atrial Area (cm ²)	20 ± 2.3	21 ± 3.1	0.47
Native myocardial T1	960 ± 37	967 ± 37	0.53
Native blood pool T1	1484 ± 76	1463 ± 118	0.50
ECV	-	0.26 ± 0.04	
LGE	-	2 (7)	

*Values expressed as mean ± SD.

LVEDV = left ventricular end diastolic volume; LVESV = left ventricular end systolic volume; LVEF = left ventricular ejection fraction; RVEDV = right ventricular end diastolic volume; RVESV = right ventricular end systolic volume; RVEF = right ventricular ejection fraction; MAPSE = mitral annular plane systolic excursion; ECV = Extracellular volume fraction; LGE = Late gadolinium enhancement

Table 3: CMR data comparing patients with high cumulative anthracycline dose to patients with lower cumulative anthracycline dose*.

Cardiovascular MR data	Low dose <300mg/m ² (n =22)	High dose >300mg/m ² (n = 8)	p Value
LVEDV index (ml/m ²)	71 ± 11	80 ± 14	0.10
LVESV index (ml/m ²)	28 ± 8	36 ± 6	*0.03
LV EF (%)	65 ± 5	54 ± 6	*0.01
LV Mass index (g/m ²)	58 ± 11	59 ± 9	0.94
RVEDV index (ml/m ²)	70 ± 10	69 ± 17	0.87
RVESV index (ml/m ²)	28 ± 15	26 ± 7	0.77
RV EF (%)	63 ± 5	62 ± 2	0.46
MAPSE (cm)	13 ± 2.1	13 ± 4.1	0.72
Left Atrial Area (cm ²)	21 ± 3	21 ± 4	0.94
Native T1	960 ± 39	992 ± 24	*0.05
Native blood pool T1	1464 ± 79	1527 ± 38	*0.05
ECV	0.25 ± 0.02	0.28 ± 0.05	*0.02
LGE	1 (14)	1 (5)	

*Values expressed as mean ± SD.

MR = magnetic resonance; LVEDV = left ventricular end diastolic volume; LVESV = left ventricular end systolic volume; LVEF = left ventricular ejection fraction; RVEDV = right ventricular end diastolic volume; RVESV = right ventricular end systolic volume; RVEF = right ventricular ejection fraction; MAPSE = mitral annular plane systolic excursion; ECV = Extracellular volume fraction; LGE = Late gadolinium enhancement

Within the patient group, the mean myocardial extracellular volume fraction (ECV) was within a normal reference range (0.26 ± 0.04). However, again, the patients who had previously received >300mg/m² anthracyclines had significantly higher ECV fraction than patients who had received lower doses. ECV fraction was not associated with either diastolic functional parameters or regional myocardial systolic function.

Tissue phase mapping

Compared with normal subjects, patients tended to show lower

mean values of peak radial systolic velocities, but this difference was not significant. Generally, compared to normal subjects, the graphs of regional and global myocardial motion patterns over time showed that patients had a greater range of values of peak systolic radial and longitudinal velocities, demonstrating greater variability in regional wall motion characteristics. (Figure 2)

There was no difference in the TPM peak systolic radial and longitudinal velocities between patients who had received higher or lower dose anthracycline therapy.

Discussion

To our knowledge, this is the first study to describe detailed myocardial function and tissue characteristics of cancer survivors approximately 25 years after therapy, measured with echocardiography and CMR.

Although this cohort of late survivors had a normal mean CMR-derived LV ejection fraction, our data shows a subtle, asymptomatic reduction of LVEF, and a significant effect of higher-dose anthracycline regimens. Additionally, the novel CMR measures of myocardial tissue characterization demonstrated a significant dose-effect, with increased myocardial ECV fraction in patients late after receiving higher cumulative doses of anthracycline therapy.

These findings are consistent with the findings of Tham et al. [9] who studied patients eight years after childhood anthracycline therapy.

The risk of developing anthracycline-induced cardiomyopathy has previously been shown to be a function of cumulative anthracycline dose [17].

Although the mechanisms and pathophysiology of anthracycline-induced cardiomyopathy remains incompletely resolved, myocyte loss by necrosis has been demonstrated and such cell death has also been shown in progenitor cell populations [18].

Echocardiographic studies have long since shown that myocardial mass is decreased in patients long-term after anthracycline therapy, but the effect on mass is not evident with echocardiographic imaging until late in the process.

This has led to the postulation that more subtle myocyte loss could be demonstrated at an earlier stage, by using CMR tissue characterization techniques, including native T1 mapping and measurement of ECV fraction. ECV fraction has been suggested as a potential biomarker for the early detection of generalized myocyte damage.

Our study did not find a significantly higher mean ECV fraction among the whole group of patients compared to previously published normal data, but we did find a significant difference in the ECV fraction within our patients who had received a high cumulative anthracycline dose compared with those who had received lower doses.

Comparison between ECV values from different studies requires caution due to inherent differences in CMR sequences and acquisition techniques. To our knowledge there have been 3 major studies reporting ECV fraction after anthracycline therapy, all of which have focused on the period 8-10 years after therapy. Tham et al used the SASHA sequence and report and mean ECV fraction of 0.21 ± 0.04 in older children 7 years after therapy [9]; Neilan et al. used a Lock locker sequence and reported higher ECV value of 0.36 ± 0.03 in adult patients 8 years after anthracycline therapy [8]; Toro-Salazar et al used a MLLSR sequence and found ECV to be normal as compared with controls (0.25 ± 0.01) a mean of 10 years after therapy [19]. In all three studies, the patient cohorts had received similar median anthracycline doses.

Although measuring the ECV fraction using gadolinium-based contrast is a promising CMR technique for assessing increased myocardial interstitial space, better standardization of scanning protocols between institutions and more robust knowledge of the range

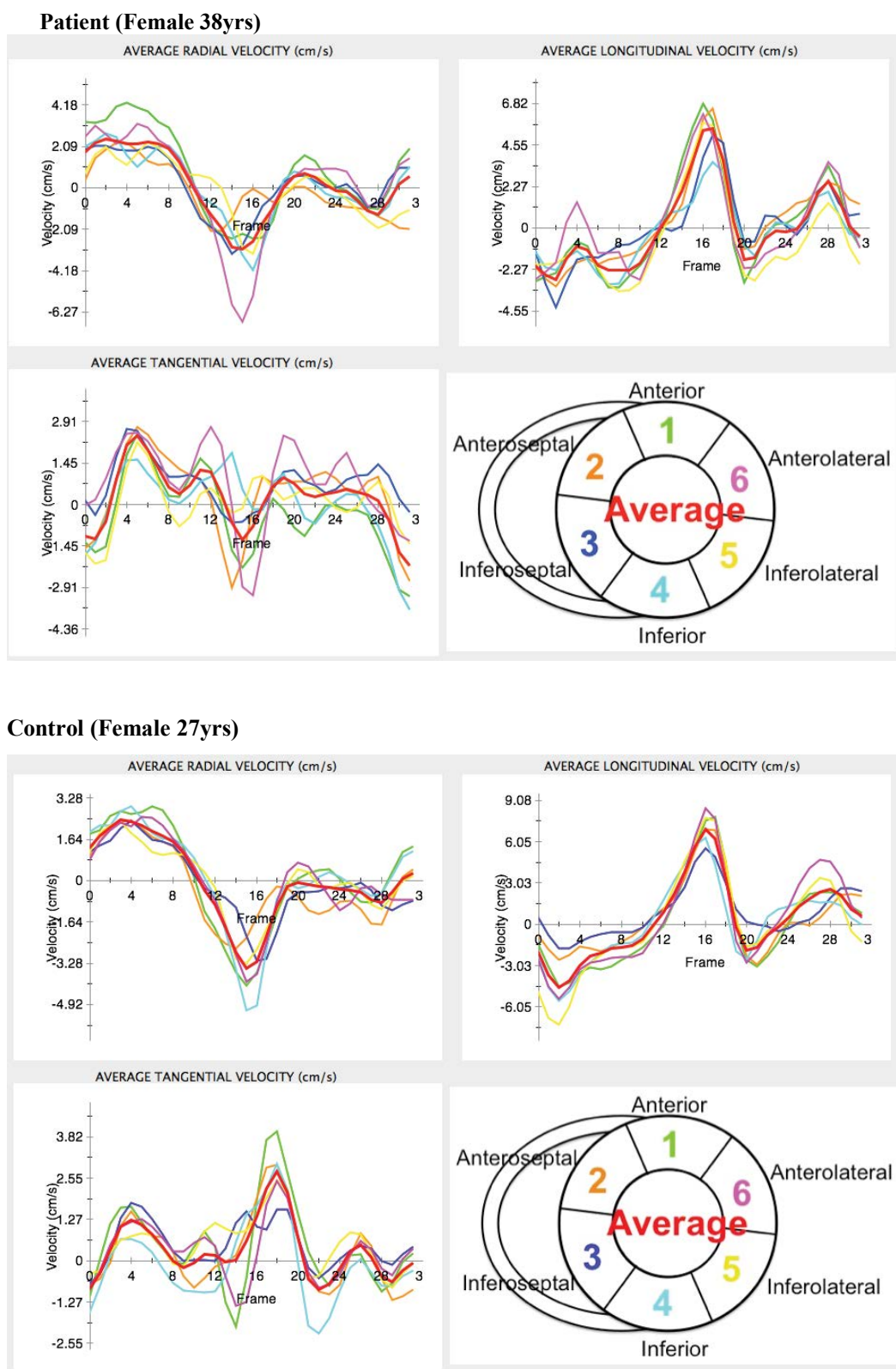


Figure 2: A graphical representation of Tissue Phase Mapping data from both a patient and a control, including the radial, longitudinal and tangential velocities of the mid-left ventricular myocardium over a single cardiac cycle.

of normal values with established protocols is necessary for this technique to have widespread clinical value.

There is possibly more potential clinical value in characterizing myocardial tissue using quantitative T1 mapping without the use of contrast; thereby revealing interstitial characteristics without contrast risks. Our study showed that the anthracycline group as a whole did not demonstrate significantly different myocardial native T1 values,

however within the anthracycline-treated group, those who had received higher doses had increased native myocardial T1 signal. This suggests pathological change, which may be an early indicator of subclinical cardiomyopathy. In patients with aortic valve stenosis, native T1 values correlated with the degree of biopsy-quantified fibrosis [20]. Our study showed that this technique is feasible in a clinical setting and could be used as a non-invasive, non-contrast assessment of diffuse fibrosis. Work is needed to determine more precisely the role in risk stratification

or the role in monitoring potential future myocardial protection techniques or antifibrotic treatments.

The novel MRI technique of tissue phase mapping (TPM) also shows promise as a method for detecting subtle changes in wall motion and quantifying these in a regional manner, unhampered by poor acoustic windows. Many studies, including that by Armstrong et al [5], have shown the suboptimal sensitivity of transthoracic echocardiography in detecting subtle changes in ventricular systolic contraction, limiting the screening performance of echocardiography. In our study CMR TPM showed good feasibility, and suggested important changes in the function of anthracycline-exposed myocardium. However, our study may have been underpowered to show significant patterns of abnormality in patients, compared to controls. In agreement with other studies we report a wide variation in individual TPM findings in patients, not entirely explained by cumulative anthracycline dose. In agreement with others, this finding suggests additional potential modulators of the myocyte response to anthracycline exposure, which are, as yet, incompletely elucidated.

Limitations

This study was designed to explore the feasibility of novel CMR markers of subtle myocardial tissue and motion characteristics.

The study cohort was small, and voluntary, from a group of long term survivors who remained in follow up at our local adult institution.

The cohort was also relatively heterogeneous, in terms of their original cancer diagnosis, additional radiation therapy and varying treatment protocols. All these factors are important likely sources of variability for all findings, and may contribute to decreased statistical power.

No gadolinium contrast was given to the age-sex matched controls in our study, so we were not able to record normal values of the post-contrast myocardial T1 map, using the MOLLI sequence in our institution. We relied on previously published normal values. Although we mimicked the methodology from similar studies, this is a rapidly developing field, and image variability contributed by the magnet type, the scanning sequence, dosing regimen and timing of image acquisition will impair the comparability of the findings to those from other centres.

Conclusions

This study is one of the first to examine in detail the very long-term cardiac effects of anthracycline, in survivors of childhood treatment. The study explored conventional and novel, non-invasive and non-toxic methods of CMR imaging.

The study showed persistent, often sub-clinical and dose-dependent myocardial impairment. Novel CMR myocardial characterization and motion analysis was feasible and effective. Although in this small cohort, little difference was found compared to controls, improving and validating these promising methods may be the best way to further unravel the complex mechanisms of myocyte injury, to monitor patients and to find means of preventing long-term anthracycline-related cardiomyopathy in the future.

Compliance with Ethical Standards

Ethical approval was given as stated previously in this manuscript. Informed consent was obtained from all individual participants included in the study.

All authors, including Sadia Quyam, Jennifer Steeden, Tanzina Chowdhary, Vivek Muthurangu and Marina Hughes declare that they have no conflict of interest.

Funding

This study was funded by a 'Start-up' grant from Cancer for Children UK, grant number 12-137.

References

1. Phillips SM, Padgett LS, Leisenring WM, Stratton KK, Bishop K, Krull KR, et al. Survivors of childhood cancer in the United States: prevalence and burden of morbidity. *Cancer Epidemiol Biomarkers Prev*. 2015; 24:653-63.
2. Lipshultz SE, Adams MJ, Colan SD, Constine LS, Herman EH, Hsu DT, et al. Long-term cardiovascular toxicity in children, adolescents, and young adults who receive cancer therapy: pathophysiology, course, monitoring, management, prevention, and research directions: a scientific statement from the American Heart Association. *Circulation*. 2013; 128:1927-1995.
3. Kremer LC, Mulder RL, Oeffinger KC, Bhatia S, Landier W, Levitt G, et al. A worldwide collaboration to harmonize guidelines for the long-term follow-up of childhood and young adult cancer survivors: a report from the International Late Effects of Childhood Cancer Guideline Harmonization Group. *Pediatr Blood Cancer*. 2013; 60:543-9.
4. Armenian SH, Hudson MM, Mulder RL, Chen MH, Constine LS, Dwyer, M et al. Recommendations for cardiomyopathy surveillance for survivors of childhood cancer: a report from the International Late Effects of Childhood Cancer Guideline Harmonization Group. *Lancet Oncol*. 2015; 16:e123-36.
5. Armstrong GT, Plana JC, Zhang N, Srivastava D, Green DM, Ness KK, et al. Screening adult survivors of childhood cancer for cardiomyopathy: comparison of echocardiography and cardiac magnetic resonance imaging. *J Clin Oncol*. 2012; 30:2876-2884.
6. Bernaba BN, Chan JB, Lai CK, Fishbein MC. Pathology of late-onset anthracycline cardiomyopathy. *Cardiovasc Pathol*. 2010; 19:308-311.
7. Flett AS, Hayward MP, Ashworth MT, Hansen MS, Taylor AM, Elliott PM, et al. Equilibrium contrast cardiovascular magnetic resonance for the measurement of diffuse myocardial fibrosis: preliminary validation in humans. *Circulation*. 2010; 122:138-44.
8. Neilan TG, Coelho-Filho OR, Shah RV, Feng JH, Pena-Herrera D, Mandry D, et al. Myocardial extracellular volume by cardiac magnetic resonance imaging in patients treated with anthracycline-based chemotherapy. *Am J Cardiol*. 2013; 111:717-22.
9. Tham EB, Haykowsky MJ, Chow K, Spavor M, Kaneko S, Khoo NS, et al. Diffuse myocardial fibrosis by T1-mapping in children with subclinical anthracycline cardiotoxicity: relationship to exercise capacity, cumulative dose and remodeling. *J Cardiovasc Magn Reson*. 2013; 15:48.
10. Steeden JA, Knight DS, Bali S, Atkinson D, Taylor AM, Muthurangu V. Self-navigated tissue phase mapping using a golden-angle spiral acquisition-proof of concept in patients with pulmonary hypertension. *Magn Reson Med*. 2014; 71:145-155.
11. Sorensen K, Levitt GA, Bull C, Dorup I, Sullivan ID. Late anthracycline cardiotoxicity after childhood cancer: a prospective longitudinal study. *Cancer*. 2003; 97:1991-1998.
12. Dorup I, Levitt G, Sullivan I, Sorensen K. Prospective longitudinal assessment of late anthracycline cardiotoxicity after childhood cancer: the role of diastolic function. *Heart*. 2004; 90:1214-1216.
13. Steeden JA, Atkinson D, Hansen MS, Taylor AM, Muthurangu V. Rapid flow assessment of congenital heart disease with high-spatiotemporal-resolution gated spiral phase-contrast MR imaging. *Radiology*. 2011; 260:79-87.
14. Messroghli DR, Radjenovic A, Kozerke S, Higgins DM, Sivanathan MU, Ridgway JP. Modified Look-Locker inversion recovery (MOLLI) for high-resolution T1 mapping of the heart. *Magn Reson Med*. 2004; 52:141-146.
15. Rosset A, Spadola L, Ratib O. OsiriX: an open-source software for navigating in multidimensional DICOM images. *J Digit Imaging*. 2004; 17:205-216.
16. Jung B, Markl M, Foll D, Hennig J. Investigating myocardial motion by MRI using tissue phase mapping. *Eur J Cardiothorac Surg*. 2006; 29 Suppl 1:S150-7.
17. Shan K, Lincoff AM, Young JB. Anthracycline-induced cardiotoxicity. *Ann Intern Med*. 1996; 125:47-58.

18. De Angelis A, Piegari E, Cappetta D, Marino L, Filippelli A, Berrino L, et al. Anthracycline cardiomyopathy is mediated by depletion of the cardiac stem cell pool and is rescued by restoration of progenitor cell function. *Circulation*. 2010; 121:276-292.
19. Toro-Salazar OH, Gillan E, O'Loughlin MT, Burke GS, Ferranti J, Stainsby J, et al. Occult cardiotoxicity in childhood cancer survivors exposed to anthracycline therapy. *Circ Cardiovasc Imaging*. 2013; 6:873-80.
20. Bull S, White SK, Piechnik SK, Flett AS, Ferreira VM, Loudon M, et al. Human non-contrast T1 values and correlation with histology in diffuse fibrosis. *Heart*. 2013; 99:932-937.