

Necrotising Enterocolitis

Nigel J Hall, Simon Eaton, Agostino Pierro

Surgery Unit, UCL Institute of Child Health and Great Ormond Street Hospital for Children, London, UK

Correspondence address:

Nigel Hall
Clinical Lecturer
Surgery Unit
UCL Institute of Child Health,
30 Guilford Street
London, UK
WC1N 1EH
Tel: 020 7905 2254
E-mail: nigel.hall@ucl.ac.uk

INTRODUCTION

Necrotising enterocolitis (NEC) is a devastating disease of infants and the commonest gastrointestinal emergency in the newborn period. It is a condition characterised by intestinal necrosis affecting the ileum and/or colon. There is a wide spectrum of clinical manifestations. In the least severe cases there may be mild inflammation of the intestinal wall in a baby with mild abdominal distension and minimal systemic upset. The most severely affected cases, however, may show evidence of full thickness intestinal necrosis with perforation, respiratory and cardiovascular collapse, multi-system organ failure and in some cases death.

The term 'necrotizing enterocolitis' first appeared in the European literature in the 1950s when Schmid and Quaiser described infants dying from necrotic lesions of the gastrointestinal tract [1]. However, it was not until the 1960s, when Santulli *et al* reported a series of 64 infants with NEC that it became recognized as a distinct clinical entity [2]. Since then, the condition has been increasingly recognised, at least partly due to the advances made in neonatal care in the past 40 years and the increasing survival of infants at the extremes of prematurity creating a larger population at risk of developing NEC.

Currently, the reported incidence of NEC varies from 0.5 to 5 per 1000 live births [3] but NEC is predominantly a disease of preterm infants and those of low birth weight. The incidence is as high as 14% in infants less than 1000g [4] and more than 90% of affected infants are born prematurely. Despite several decades of active research in the field of NEC, the mortality rate remains unchanged [5] and is over 30% in infants weighing less than 1000g [6]. New treatments are desperately needed to improve outcome from this devastating condition.

PATHOGENESIS AND RISK FACTORS

Several theories and mechanisms of injury have been proposed to explain the aetiology of NEC. However, despite over 30 years of research the aetiology remains unclear and no single mechanism at present can account for the pathogenesis in all cases. The interaction of multiple factors is likely to be responsible in the majority of cases. Several risk factors have been shown to be associated with NEC, and others implicated by strong association. Intestinal immaturity of premature infants, particularly those of extremely low birth weight, is thought to be central to the pathogenesis, although the precise nature of this immaturity and the mechanisms by which disease ensues are unclear. Proposed risk factors are summarised in *Table 1*.

Peripartum events

There are several risk factors related to pre- and peri- natal events which are associated with NEC. Absent or reversed end diastolic blood flow in the umbilical artery has been reported as a predisposing factor [7] most likely due to creating a degree of chronic relative intestinal ischaemia. In addition there is an association with maternal eclampsia, fetal distress and premature rupture of membranes. In the immediate postnatal period, risk factors include asphyxia, hypothermia, respiratory distress syndrome, apnoeic episodes, cyanotic congenital heart disease, persistent fetal circulation, persistent ductus arteriosus and sepsis. It is likely that all result at least in part in a degree of relative intestinal ischaemia or hypoxia perhaps predisposing the infant to developing NEC in the presence of subsequent risk factors.

Feeding regimen

The majority of infants who develop NEC have been fed enterally. There is often pressure to provide feeds of increased calorific density in order to meet the growth requirements of the premature neonate. Such feeds are often hyperosmolar and may result in mucosal damage in the pre-existing immature intestine and thereby contributing to the development of NEC. Breast milk appears to

offer some protection against NEC, probably as a result of its immunologically active components including immunoglobulins, cytokines and complement proteins [8;9].

Altered blood supply

NEC has been associated with a number of predisposing factors which are believed to result in intestinal vascular insufficiency and subsequent selective mesenteric ischaemia. The causes of this vascular insufficiency include pre- and perinatal stress (e.g. reversed umbilical arterial blood flow, maternal pre-eclampsia), umbilical catheterization, exchange transfusion, congenital cardiac disease and indomethacin treatment. This results in the loss of the protective mucosal barrier, autodigestion and presents an opportunity for bacterial invasion. In addition to these associations, evidence for a vascular component in the aetiology of NEC comes from an experimental animal model in which a disease like NEC is observed following an intestinal ischaemia reperfusion injury [10].

Bacterial involvement

While the precise role of bacterial agents in the development of NEC is unclear, several factors their involvement. Occasionally NEC is seen to occur in clusters, in which a higher than expected number of cases are observed in one centre [11]. Identical organisms are grown from babies within these clusters and the initiation of infection control measures has been shown to control such outbreaks [12]. However, different organisms are grown from separate outbreaks so it cannot be claimed that a single organism is involved in development of NEC. Bacterial involvement in the pathogenesis of NEC is also implicated by association; endotoxaemia [13;14] and positive blood cultures are common in infants with NEC and the gastrointestinal pneumatosis found in NEC contains 30% hydrogen, a gas produced solely by bacterial metabolism [15]. Furthermore, in experimental animals, an NEC-like illness can be induced by ingestion of *Clostridium* species [16] and administration of bacterial endotoxin [17;18].

PREVENTION

A variety of interventions have been proposed to prevent NEC. This is the most logical approach to combating a disease for which there are no specific therapies. Given the multifactorial aetiology of the disease any intervention decreasing the incidence of one of the recognized risk factors may decrease the incidence of NEC. Although interventions such as immunoglobulin administration [19] or prophylactic enteral antibiotics have been shown to reduce incidence of NEC in individual studies, subsequent reviews and concerns over adverse effects have precluded their widespread usage [20;21].

Other novel agents have been suggested for the prevention of NEC including lactoferrin [22], recombinant erythropoietin [23], glutamine [24] and arginine [25]. Whilst there is some evidence to support a reduction in incidence of NEC with these compounds, the mechanisms of action are unclear and may be attributable to other secondary effects. None is in current widespread use, although further studies of these and other agents are warranted.

The most robust evidence for interventions to prevent development of NEC exists for the administration of probiotics and modulation of feeding regimes in infants at highest risk of NEC. The role of bacteria in the pathogenesis of NEC has led investigators to determine the effect of probiotics on the incidence on NEC. Several randomised controlled trials have demonstrated a significant reduction in incidence of NEC following routine probiotic administration [26;27] and meta-analysis of these studies appears to confirm this exciting finding [28]. However, concern has been expressed that currently sufficient evidence may still be lacking to support widespread adoption of this practice as existing studies do not include the highest risk population of extremely low birth weight infants - who are also at greatest risk of side effects of probiotics. Furthermore, there remain unanswered

questions as to which probiotic should be used and at what dose [29]. It is hoped that outcomes of ongoing randomised controlled trials may address these issues.

There is little doubt that one of the most important preventative measures is that of feeding infants at risk of NEC with breast milk as opposed to formula milk. This effect has been known for more than 20 years [8], but despite changes in infant formula, breast milk still appears to offer significant protection [9;30]. Quigley *et al*, in a Cochrane review, demonstrated a significantly lower incidence of NEC in human milk-fed infants [31]. If fortification of breast milk is necessary to achieve adequate growth then a fortifier based on human milk appears to lower the incidence of NEC (and NEC requiring surgery) compared to a cow's milk based fortifier [30]. However, availability of either human milk and/or human milk based products is problematic.

In addition to this it has been a long held belief that the time at which enteral feeds are first introduced and the rate at which they are increased may affect the incidence of NEC. In an attempt to demonstrate this definitively, several groups have recently published results of well-designed randomised controlled trials investigating the effect of early versus delayed enteral feeding in infants at risk of NEC [32;33]. Whilst both demonstrated a trend towards reduction in incidence of NEC with delayed enteral feeding, neither study in isolation demonstrated a statistically significant effect, and current meta-analyses do not support the use of a delayed introduction or slower rate of enteral feeds to prevent NEC.

Clusters of cases of NEC have been described, and anecdotally there is marked geographic variation in prevalence between countries and/or centres. How much of this is due to differences in feeding practise or other aspects of neonatal care, and how much of it may be due to genetic or environmental factors is unknown. Although there is some evidence that certain genotypes may predispose infants to NEC [34-36], the effects of these genotypes are not strong and most of the studies have been relatively small-scale.

CLINICAL FEATURES AND DIAGNOSIS

Infants with NEC usually display both specific and non-specific gastrointestinal signs. In the early stages of the disease, abdominal distension with or without tenderness, feeding intolerance with increased gastric residuals, vomiting and occult blood in the stools may all be present. These findings may become more severe as the disease progresses to include abdominal wall oedema, erythema and ascites. A small proportion of infants with NEC present with a palpable abdominal mass (usually due to matted loops of bowel around an area of gangrene or perforation) and/or persistent intestinal obstruction.

In addition to these gastrointestinal signs, generalized non-specific signs indicative of systemic deterioration or sepsis are often present. In their mildest form, these include temperature instability, hypovolaemia, tachycardia, and mild respiratory distress. In more advanced disease, clinical features of a systemic inflammatory response frequently develop including hypotension requiring inotropes, respiratory failure requiring ventilatory support, coagulopathy and renal failure.

Whilst there are no defining laboratory parameters of use in the diagnosis of NEC, a number of haematological and biochemical abnormalities may be observed including raised or depressed white cell count, thrombocytopenia, metabolic acidosis, glucose instability and elevated C-reactive protein levels [14;37-39], although none of these are universally present in all cases. There also potentially some other more specific markers of intestinal damage, such as intestinal fatty-acid binding protein [40;41], but these are not yet suitable for routine clinical use.

Radiographic imaging is essential in the diagnosis of NEC. The pathognomonic radiological finding is that of pneumatosis intestinalis (*Figure 1*) representing gas within the wall of the bowel, which is believed to originate from pathogenic bacteria. If this gas becomes absorbed into the mesenteric circulation it may result in the presence of portal venous gas seen as a narrow, linear air-dense area in the hepatic region on X-ray. The most significant radiological finding is that of pneumoperitoneum (*Figure 2*) resulting from intestinal perforation, as this is a clear indication that surgery is required. Free air may be seen in a number of ways including:

- The football sign (free gas outlining the falciform ligament and umbilical arteries)
- As a triangular gas shadow clearly not within the intestinal lumen often bordered by the subhepatic space and hepatorenal fossa
- As Rigler's sign, in which there is clear visualization of the outer as well as the inner wall of a loop of bowel

In many cases the identification of perforation is challenging and a lateral decubitus or lateral shoot through radiograph may be useful (*Figure 3*). There are cases in which intestinal perforation may be represented by a completely gasless abdomen and it is not unusual to find a sealed perforation at laparotomy in the absence of free air on the abdominal radiograph. An abdominal ultrasound scan may be helpful for diagnosis in these cases. Colour doppler ultrasound has been advocated in some centres, but this requires specific training [42;43] and has the disadvantage of being very operator dependent.

STAGING

This combination of clinical features, laboratory indices and radiological findings have been grouped together to form a staging system (*Figure 4*) for NEC known as Bell's staging [44]. The use of such a staging system has been used by some surgeons to select the most appropriate treatment but its value is probably greatest in defining severity of disease in determining the effectiveness of therapy on survival and outcome. Some authors have attempted to define staging on the basis of only radiographic findings [45], but this has not found widespread usage.

CLINICAL MANAGEMENT

Medical management

Most infants with suspected (Bell's Stage 1) or less advanced (Stage 2A or B) NEC are managed non-surgically although they may require intensive medical care. This may be described as predominantly supportive as there are no specific treatments for NEC. This supportive treatment includes appropriate ventilatory support, adequate fluid resuscitation, inotropic support as required and correction of acid-base imbalance, coagulopathy, and thrombocytopenia. The intestine is rested and decompressed with a nasogastric tube and broad spectrum antibiotics are given usually for 7-10 days. Antibiotics may be modified appropriately in light of microbiological culture results.

Although there are no specific therapies for NEC, various therapeutic agents or manoeuvres have been tested in experimental models of NEC. These include captopril [46], platelet activating factor antagonists [47], moderate controlled hypothermia [48], and stem cells [49;50]. However, because of the experimental models studied, it is not clear whether some of these agents are effective at prevention or as therapy. Of note, moderate therapeutic hypothermia was found to be feasible and safe in infants with NEC [51] and a randomised controlled trial to test effectiveness is currently in progress (CoolNEC).

Serial clinical and radiological examination is of extreme importance to monitor progression of disease and detect any evidence of intestinal perforation or other indication for surgical

intervention. In the absence of such indication, medical management should continue for 7-10 days depending on severity of illness. Following this, feeds may be slowly reintroduced paying particular attention to feed intolerance suggestive of a repeat episode of NEC or intestinal stricture. From the time of diagnosis to re-establishment of full enteral feeds it is essential to maintain nutritional input with parenteral nutrition (PN) adequate for tissue healing and repair, and body growth.

Surgical management

Despite aggressive medical treatment, a proportion of infants with NEC require acute surgical intervention. Surgeons differ over indications for surgery since there is the potential to cause serious harm by operating on a fragile, critically unwell preterm infant [52]. Indications for surgery are listed in *Table 2*.

The principles of surgical treatment for acute NEC are to remove necrotic intestine and control intra-abdominal sepsis whilst preserving as much intestinal length as possible. Within these principles, a number of surgical options exist and the procedure of choice is somewhat contentious. The traditional surgical approach to NEC has been to perform a laparotomy, resect all areas of necrotic intestine and exteriorize the bowel to allow adequate time for healing and growth before restoring intestinal continuity at a later stage. However, stomas, and in particular ileostomies are poorly tolerated by preterm infants as they may predispose to nutritional and metabolic disturbances and poor growth as a consequence of fluid and electrolyte depletion. Some surgeons therefore advocate primary anastomosis following intestinal resection for NEC wherever possible and this is feasible even in small, critically unwell infants [53]. However, there is no good evidence to support one approach over the other. In children who are unstable during surgery or have intra-operative complications such as haemorrhage the quickest approach is usually preferable; this is usually to fashion a stoma.

Some children have more than one section of bowel affected by NEC, so-called multifocal disease. For this a number of operations have been proposed including multiple resections and multiple primary anastomoses. A 'clip and drop' approach may also be useful in multifocal disease followed 24-48hrs later by a 'second-look' laparotomy [54].

Unfortunately a number of infants present at laparotomy with extensive or panintestinal NEC. Surgical options in this scenario are limited and many surgeons would consider withdrawing care faced with an infant with panintestinal gangrene (NEC totalis). However, some infants with very extensive disease may benefit from a high diverting jejunostomy [55].

A final surgical manoeuvre used in infants with perforated NEC is placement of a peritoneal drain. Primary peritoneal drainage (PPD) was initially proposed as a method of stabilizing infants with intestinal perforation prior to definitive surgical treatment [56]. Subsequently, it was reported as definitive treatment for intestinal perforation as some infants required no further surgical treatment [57;58]. There have been two recent prospective randomised controlled trials investigating the use of PPD in infants with perforated NEC compared to laparotomy [59;60]. Neither definitely demonstrated an advantage of either PPD or laparotomy over the other, and this was also true when a meta-analysis of the two trials was performed ([59]; *Figure 5*). However, one study concluded that PPD was not an effective definitive procedure for perforated NEC as its use was followed by a rescue laparotomy in approximately $\frac{3}{4}$ of the infants [59]. Whether there remains a role for PPD in the stabilisation of a critically unwell child with perforated NEC and respiratory compromise prior to transfer to another centre for a laparotomy remains unclear [61].

The authors' proposed surgical management of NEC is illustrated in *Figure 6*.

OUTCOME

Despite intensive medical and surgical treatment a number of infants do not survive the acute episode of NEC. These fall broadly into two groups: those who have panintestinal disease whose intestine cannot be salvaged and those who have surgically and medically and treatable disease but who develop a significant inflammatory response syndrome resulting in multi-organ dysfunction syndrome. Whilst overall mortality from NEC is may be as high as 35%, birth weight is a significant determinant predictor of mortality such that the mortality from NEC is as high as 42% in infants born <750g [6]. With increasing birth weight, mortality from NEC decreases (*Figure 7*). However, the mortality of those infants requiring surgery does not seem to be birth weight dependent [5].

In those who survive the acute episode of NEC, a proportion will develop an intestinal stricture either related to medically treated NEC or at the site of a previous anastomosis. Surgical resection of such strictures is usually necessary. Longer term outcome is related to remaining intestinal length and its capacity for adequate nutrient absorption. Malabsorption may result from a variety of factors including gut dysmotility, enzyme deficiency, abnormal intestinal mucosa, bacterial overgrowth, decreased bowel length and vitamin B12 deficiency secondary to ileal resection. Short bowel syndrome is the most serious gastrointestinal complication associated with NEC and great efforts are taken to avoid resection of more bowel length than is absolutely necessary. Supporters of resection and primary anastomosis cite this as one of the advantages over stoma formation.

PN-related complications are commonly encountered in infants with NEC and include sepsis, suppression of the immune response and impairment of liver function. Standard strategies to minimise the risk of these complications are used aggressively as some of these infants may have a long term PN dependency.

In addition to the intestinal sequelae of NEC, it is being increasingly recognised that NEC has a deleterious neurodevelopmental effect, the mechanisms of which are not understood [62;63]. Whilst it is recognised that many preterm infants suffer from neurodevelopmental impairment, neurodevelopmental outcome appears worse in infants who have had NEC. In addition to the intestinal function following NEC it is essential that this important outcome measure is monitored as we strive towards novel therapeutic strategies that are desperately needed.

Table 1 – Proposed risk factors for NEC

Peripartum events

- absent or reversed end diastolic umbilical artery blood flow
- maternal eclampsia
- fetal distress
- premature rupture of membranes
- delivery by Caesarean section
- perinatal asphyxia
- perinatal hypothermia

Neonatal period

- respiratory distress syndrome
- apnoeic episodes
- congenital heart disease
- persistent fetal circulation,
- persistent ductus arteriosus (PDA)
- sepsis
- umbilical catheterisation
- exchange transfusion
- NSAID treatment of PDA

Feeding regimen

- formula feed (as opposed to breast milk)
- high density milk formulae
- early enteral feeding
- rapid advancement of enteral feeding

Bacterial involvement

- Precise role unclear (intraluminal bacteria probably essential for the development of NEC)

Table 2 – Indications for surgery in acute NEC

Absolute indications

- Pneumoperitoneum
- Clinical deterioration despite maximal medical treatment
- Abdominal mass with persistent intestinal obstruction

Relative indications

- Increased abdominal tenderness, distension and/or discolouration
- Portal vein gas

Figure 1 – Plain AXR demonstrating pneumatosis intestinalis in an infant with suspected NEC

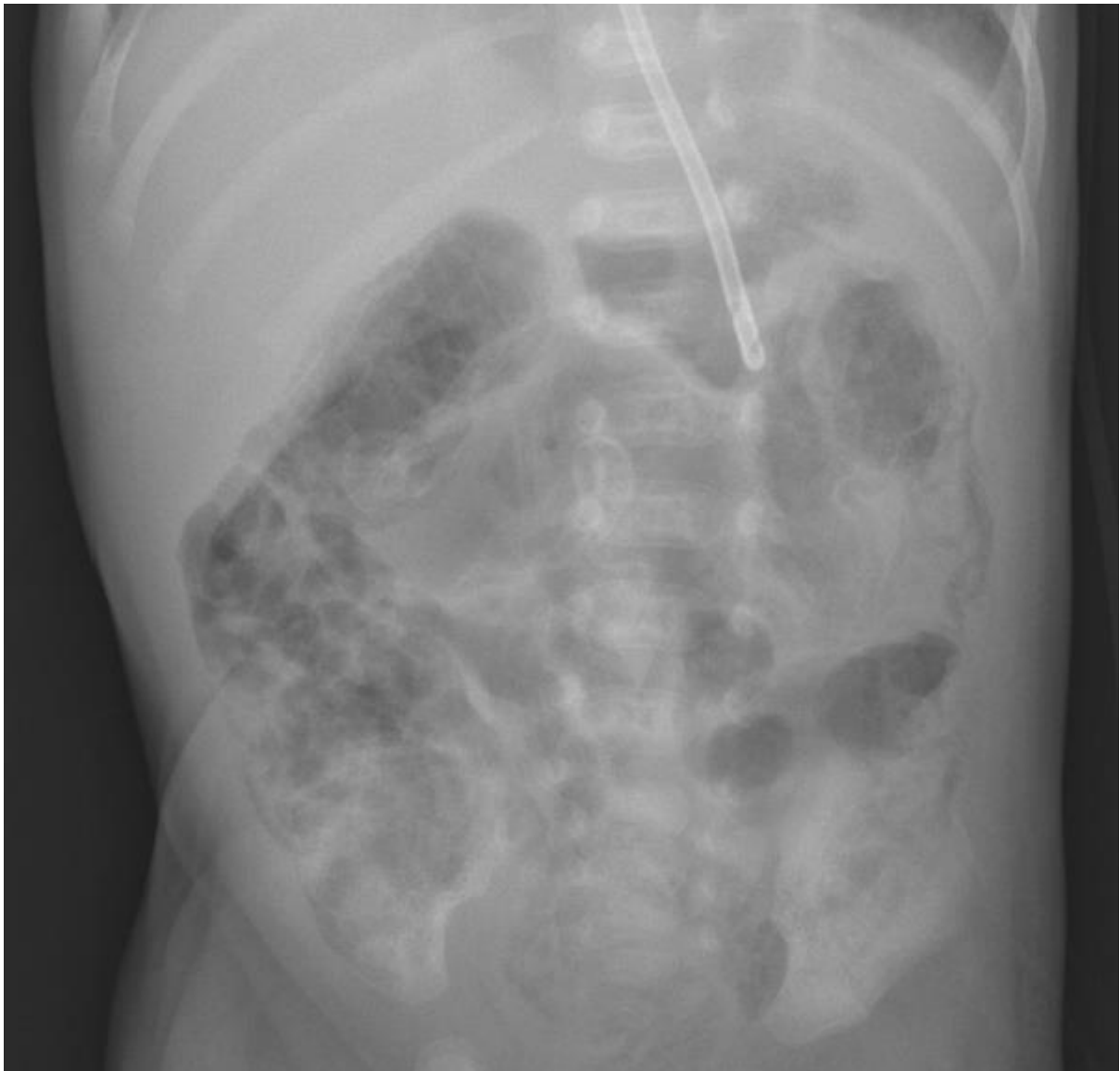


Figure 2 – Plain AXR demonstrating pneumoperitoneum in an infant with NEC

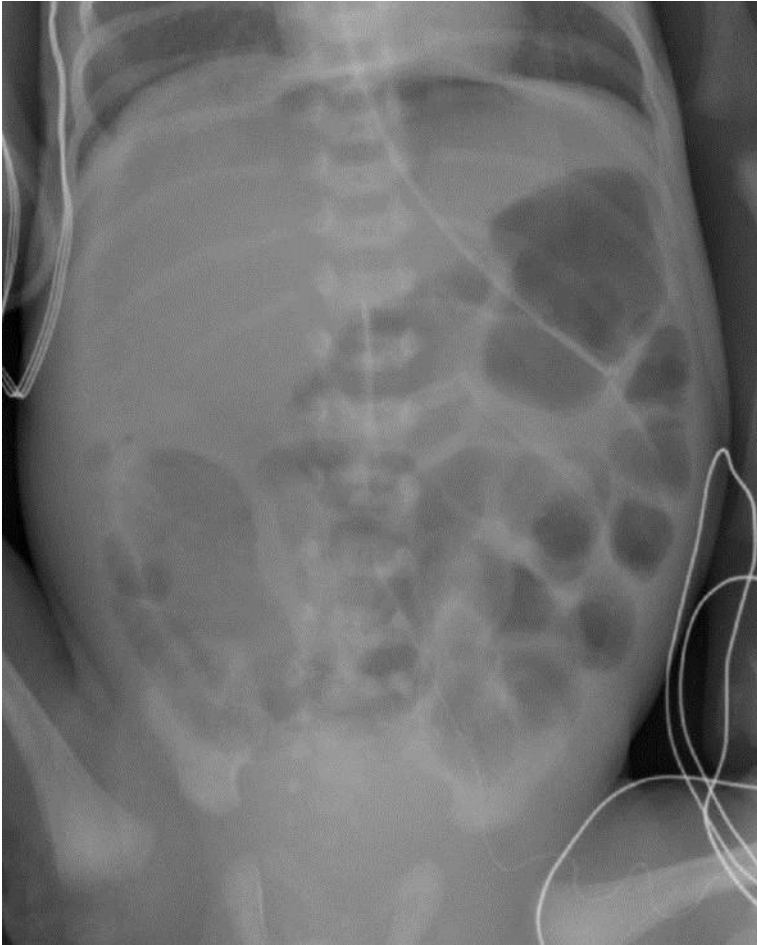


Figure 3 – Lateral shoot-through AXR in an infant with NEC demonstrating pneumoperitoneum

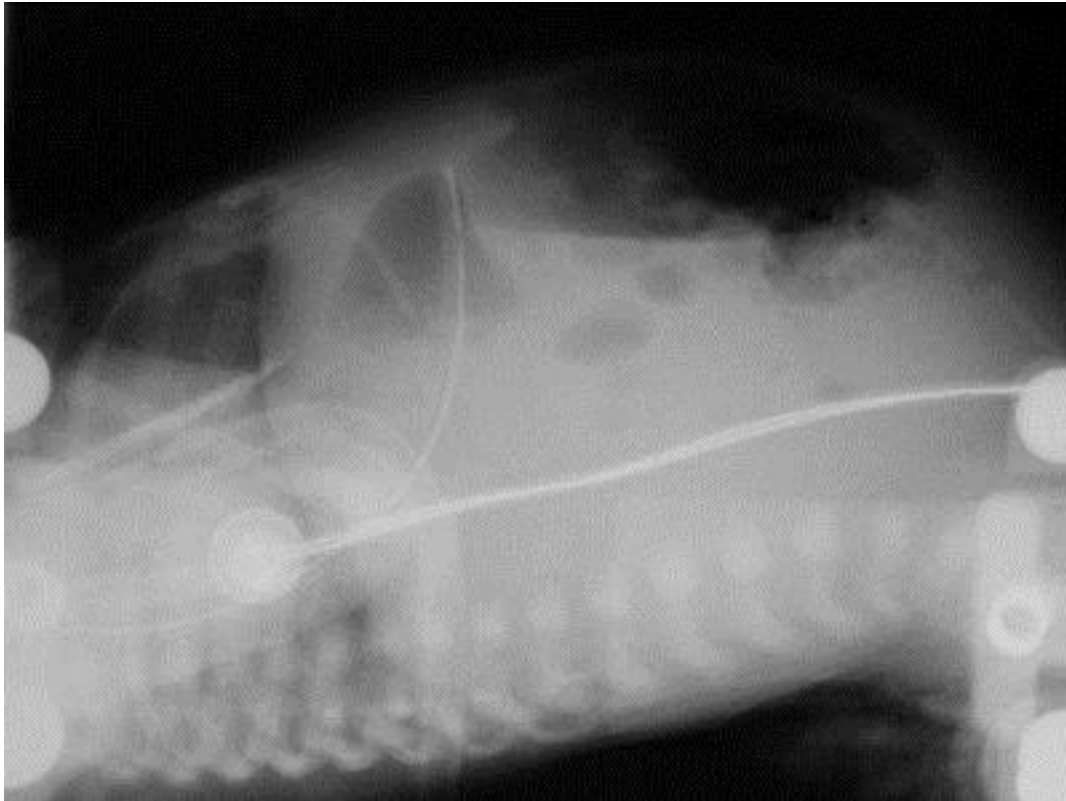


Figure 4 – Modified Bell staging criteria for NEC. Modified from [44].

Stage	I	IIA	IIB	IIIA	IIIB
Description	Suspected NEC	Mild NEC	Moderate NEC	Severe NEC	Severe NEC
Systemic signs	Temperature instability, apnoea, bradycardia	Similar to stage I	Mild acidosis, thrombocytopenia	Respiratory and metabolic acidosis, mechanical ventilation, hypotension, oliguria, DIC	Further deterioration and shock
Intestinal signs	Increased gastric residuals, mild abdominal distension, occult blood in the stool	Marked abdominal distension ± tenderness, absent bowel sounds, grossly bloody stools	Abdominal wall oedema and tenderness ± palpable mass	Worsening wall oedema with erythema and induration	Evidence of perforation
Radiographic signs	Normal or mild ileus	Ileus, dilated bowel loops, focal pneumatosis	Extensive pneumatosis, early ascites ± PVG	Prominent ascites, fixed bowel loop, no free air	Pneumoperitoneum

DIC = disseminated intravascular coagulopathy; PVG = portal venous gas.

Figure 5 Meta-analysis of primary peritoneal drainage vs. primary laparotomy for NEC. Outcome is mortality. Data from [59, 60].

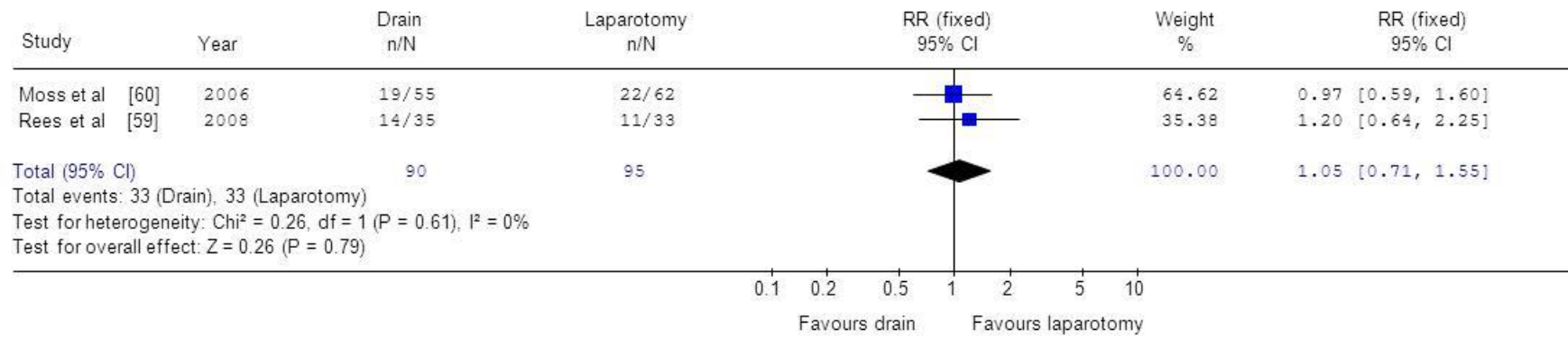


Figure 6 – Proposed surgical strategy for NEC (modified from Hall & Pierro [64])

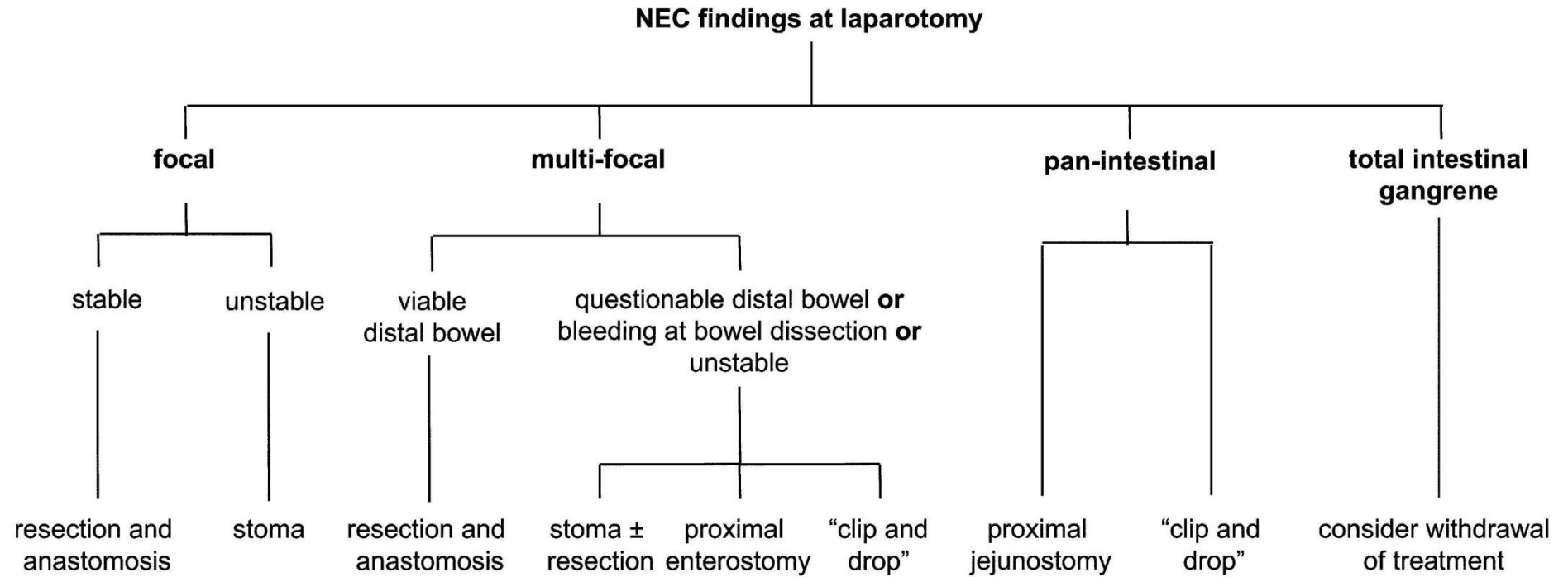
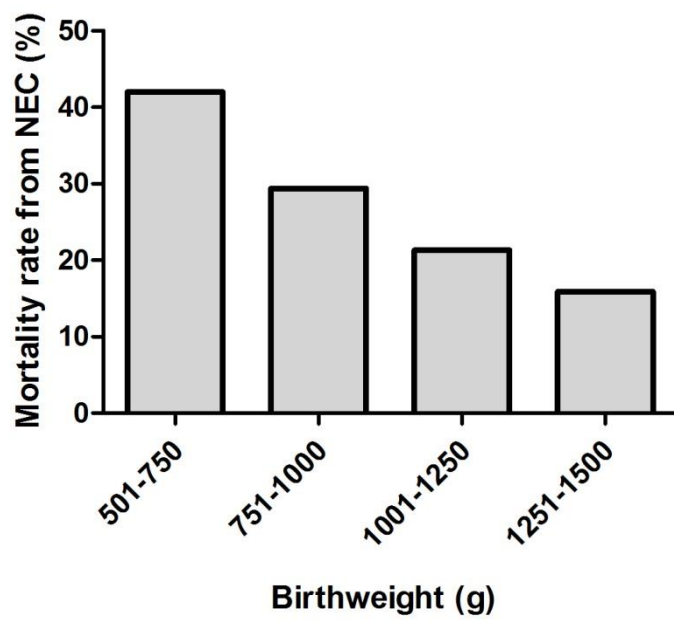


Figure 7 – Mortality of NEC by birthweight category (data from Fitzgibbons *et al.*[6])



Reference List

- (1) Schmid KO, Quaiser K. Über eine besonders schwer verlaufende Form von Enteritis beim Säugling. Österreichische Zeitschrift für Kinderchirurgie 1953;(8):114.
- (2) Barlow B, Santulli TV, Heird WC, Pitt J, Blanc WA, Schullinger JN. An experimental study of acute neonatal enterocolitis--the importance of breast milk. J Pediatr Surg 1974 Oct;9(5):587-95.
- (3) Lin PW, Stoll BJ. Necrotising enterocolitis. Lancet 2006 Oct 7;368(9543):1271-83.
- (4) Rees CM, Eaton S, Pierro A. National prospective surveillance study of necrotizing enterocolitis in neonatal intensive care units. J Pediatr Surg 2010 Jul;45(7):1391-7.
- (5) Thyoka M, De Coppi P, Eaton S, Hall NJ, Khoo AK, Curry JI, et al. Advanced necrotizing enterocolitis part 1: mortality. Eur J Pediatr Surg 2011;In press.
- (6) Fitzgibbons SC, Ching Y, Yu D, Carpenter J, Kenny M, Weldon C, et al. Mortality of necrotizing enterocolitis expressed by birth weight categories. J Pediatr Surg 2009 Jun;44(6):1072-5.
- (7) Malcolm G, Ellwood D, Devonald K, Beilby R, Henderson-Smart D. Absent or reversed end diastolic flow velocity in the umbilical artery and necrotising enterocolitis. Arch Dis Child 1991 Jul;66(7 Spec No):805-7.
- (8) Lucas A, Cole TJ. Breast milk and neonatal necrotising enterocolitis. Lancet 1990 Dec 22;336(8730):1519-23.
- (9) Meizen-Derr J, Poindexter B, Wrage L, Morrow AL, Stoll B, Donovan EF, et al. Role of human milk in extremely low birth weight infants' risk of necrotizing enterocolitis or death. Journal of Perinatology 2009;29(1):57-62.
- (10) Vejchapipat P, Eaton S, Fukumoto K, Parkes HG, Spitz L, Pierro A. Hepatic glutamine metabolism during endotoxemia in neonatal rats. Nutrition 2002 Apr;18(4):293-7.
- (11) van AJ, de SF, Muyldermans G, Bougateg A, Naessens A, Lauwers S. Outbreak of necrotizing enterocolitis associated with Enterobacter sakazakii in powdered milk formula. J Clin Microbiol 2001 Jan;39(1):293-7.
- (12) Rotbart HA, Levin MJ. How contagious is necrotizing enterocolitis? Pediatr Infect Dis 1983 Sep;2(5):406-13.
- (13) Scheifele DW. Role of bacterial toxins in neonatal necrotizing enterocolitis. J Pediatr 1990 Jul;117(1 Pt 2):S44-S46.
- (14) Scheifele DW, Olsen EM, Pendray MR. Endotoxemia and thrombocytopenia during neonatal necrotizing enterocolitis. Am J Clin Pathol 1985 Feb;83(2):227-9.
- (15) Engel RR. Origin of mural gas in necrotizing enterocolitis. Pediatr Res 1973;7:292.
- (16) Lawrence G, Bates J, Gaul A. Pathogenesis of neonatal necrotising enterocolitis. Lancet 1982 Jan 16;1(8264):137-9.

- (17) Caplan MS, Hsueh W. Necrotizing enterocolitis: role of platelet activating factor, endotoxin, and tumor necrosis factor. *J Pediatr* 1990 Jul;117(1 Pt 2):S47-S51.
- (18) Zani A, Cordischi L, Cananzi M, De Coppi P, Smith VV, Eaton S, et al. Assessment of a Neonatal Rat Model of Necrotizing Enterocolitis. *Eur J Pediatr Surg* 2008;18(6):423-6.
- (19) Eibl MM, Wolf HM, Furnkranz H, Rosenkranz A. Prevention of necrotizing enterocolitis in low-birth-weight infants by IgA-IgG feeding. *N Engl J Med* 1988 Jul 7;319(1):1-7.
- (20) Foster J, Cole M. Oral immunoglobulin for preventing necrotizing enterocolitis in preterm and low birth-weight neonates. *Cochrane Database Syst Rev* 2004;(1):CD001816.
- (21) Bury RG, Tudehope D. Enteral antibiotics for preventing necrotizing enterocolitis in low birthweight or preterm infants. *Cochrane Database Syst Rev* 2001;(1):CD000405.
- (22) Manzoni P, Rinaldi M, Cattani S, Pagni L, Romeo MG, Messner H, et al. Bovine lactoferrin supplementation for prevention of late-onset sepsis in very low-birth-weight neonates: a randomized trial. *JAMA* 2009 Oct 7;302(13):1421-8.
- (23) Ledbetter DJ, Juul SE. Erythropoietin and the incidence of necrotizing enterocolitis in infants with very low birth weight. *J Pediatr Surg* 2000 Feb;35(2):178-81.
- (24) Tubman TR, Thompson SW, McGuire W. Glutamine supplementation to prevent morbidity and mortality in preterm infants. *Cochrane Database Syst Rev* 2008;(1):CD001457.
- (25) Amin HJ, Zamora SA, McMillan DD, Fick GH, Butzner JD, Parsons HG, et al. Arginine supplementation prevents necrotizing enterocolitis in the premature infant. *J Pediatr* 2002 Apr;140(4):425-31.
- (26) Lin HC, Hsu CH, Chen HL, Chung MY, Hsu JF, Lien RI, et al. Oral probiotics prevent necrotizing enterocolitis in very low birth weight preterm infants: a multicenter, randomized, controlled trial. *Pediatrics* 2008 Oct;122(4):693-700.
- (27) Samanta M, Sarkar M, Ghosh P, Ghosh J, Sinha M, Chatterjee S. Prophylactic probiotics for prevention of necrotizing enterocolitis in very low birth weight newborns. *J Trop Pediatr* 2009 Apr;55(2):128-31.
- (28) Deshpande G, Rao S, Patole S, Bulsara M. Updated meta-analysis of probiotics for preventing necrotizing enterocolitis in preterm neonates. *Pediatrics* 2010 May;125(5):921-30.
- (29) Soll RF. Probiotics: are we ready for routine use? *Pediatrics* 2010 May;125(5):1071-2.
- (30) Sullivan S, Schanler RJ, Kim JH, Patel AL, Trawoger R, Kiechl-Kohlendorfer U, et al. An exclusively human milk-based diet is associated with a lower rate of necrotizing enterocolitis than a diet of human milk and bovine milk-based products. *J Pediatr* 2010 Apr;156(4):562-7.
- (31) Quigley MA, Henderson G, Anthony MY, McGuire W. Formula milk versus donor breast milk for feeding preterm or low birth weight infants. *Cochrane Database Syst Rev* 2007;(4):CD002971.
- (32) Leaf A. Alimentazione del neonato pretermine IUGR: studio multicentrico ADEPT (Abnormal Doppler Enteral Prescription Trial). (Feeding the IUGR premature newborn infant: the multicenter ADEPT study). *Minerva Pediatr* 2010 Jun;62(3 Suppl 1):31-3.

- (33) Karagianni P, Briana DD, Mitsiakos G, Elias A, Theodoridis T, Chatziioannidis E, et al. Early versus delayed minimal enteral feeding and risk for necrotizing enterocolitis in preterm growth-restricted infants with abnormal antenatal Doppler results. *Am J Perinatol* 2010 May;27(5):367-73.
- (34) Moonen RM, Paulussen AD, Souren NY, Kessels AG, Rubio-Gozalbo ME, Villamor E. Carbamoyl Phosphate Synthetase Polymorphisms as a Risk Factor for Necrotizing Enterocolitis. *Pediatr Res* 2007 Aug;62(2):188-90.
- (35) Treszl A, Tulassay T, Vasarhelyi B. Genetic basis for necrotizing enterocolitis - risk factors and their relations to genetic polymorphisms. *Frontiers in Bioscience* 2006;11:570-80.
- (36) Sampath V, Le M, Lane L, Patel AL, Cohen JD, Simpson PM, et al. The NFKB1 (g.-24519delATTG) Variant is Associated with Necrotizing Enterocolitis (NEC) in Premature Infants. *J Surg Res* 2011;169(1):E51-E57.
- (37) Ragazzi S, Pierro A, Peters M, Fasoli L, Eaton S. Early full blood count and severity of disease in neonates with necrotizing enterocolitis. *Pediatr Surg Int* 2003 Jul;19(5):376-9.
- (38) Ververidis M, Kiely EM, Spitz L, Drake DP, Eaton S, Pierro A. The clinical significance of thrombocytopenia in neonates with necrotizing enterocolitis. *J Pediatr Surg* 2001 May;36(5):799-803.
- (39) Evennett NJ, Alexander N, Petrov M, Pierro A, Eaton S. A systematic review of serologic tests in the diagnosis of necrotizing enterocolitis. *J Pediatr Surg* 2009;44(11):2192-201.
- (40) Derikx JP, Evennett NJ, Degraeuwe PL, Mulder TL, van Bijnen AA, van Heurn LW, et al. Urine based detection of intestinal mucosal cell damage in neonates with suspected necrotising enterocolitis. *Gut* 2007 Oct;56(10):1473-5.
- (41) Evennett NJ, Hall NJ, Pierro A, Eaton S. Urinary intestinal fatty acid-binding protein concentration predicts extent of disease in necrotizing enterocolitis. *J Pediatr Surg* 2010 Apr;45(4):735-40.
- (42) Faingold R, Daneman A, Tomlinson G, Babyn PS, Manson DE, Mohanta A, et al. Necrotizing enterocolitis: assessment of bowel viability with color doppler US. *Radiology* 2005 May;235(2):587-94.
- (43) Silva CT, Daneman A, Navarro OM, Moore AM, Moineddin R, Gerstle JT, et al. Correlation of sonographic findings and outcome in necrotizing enterocolitis. *Pediatr Radiol* 2007 Mar;37(3):274-82.
- (44) Walsh MC, Kliegman RM. Necrotizing enterocolitis: treatment based on staging criteria. *Pediatr Clin North Am* 1986 Feb;33(1):179-201.
- (45) Coursey CA, Hollingsworth CL, Wriston C, Beam C, Rice H, Bisset G, III. Radiographic predictors of disease severity in neonates and infants with necrotizing enterocolitis. *AJR Am J Roentgenol* 2009 Nov;193(5):1408-13.
- (46) Zani A, Eaton S, Leon FF, Malerba A, Hall NJ, De Coppi P, et al. Captopril reduces the severity of bowel damage in a neonatal rat model of necrotizing enterocolitis. *J Pediatr Surg* 2008 Feb;43(2):308-14.

- (47) Lu J, Pierce M, Franklin A, Jilling T, Stafforini DM, Caplan M. Dual roles of endogenous platelet-activating factor acetylhydrolase in a murine model of necrotizing enterocolitis. *Pediatr Res* 2010 Sep;68(3):225-30.
- (48) Stefanutti G, Pierro A, Parkinson EJ, Smith VV, Eaton S. Moderate hypothermia as a rescue therapy against intestinal ischemia and reperfusion injury in the rat. *Crit Care Med* 2008 May;36(5):1564-72.
- (49) Tayman C, Uckan D, Kilic E, Ulus AT, Tonbul A, Murat H, I, et al. Mesenchymal stem cell therapy in necrotizing enterocolitis: a rat study. *Pediatr Res* 2011 Nov;70(5):489-94.
- (50) Zani A, Cananzi M, Eaton S, Pierro A, De CP. Stem cells as a potential treatment of necrotizing enterocolitis. *J Pediatr Surg* 2009 Mar;44(3):659-60.
- (51) Hall NJ, Eaton S, Peters MJ, Hiorns MP, Alexander N, Azzopardi DV, et al. Mild Controlled Hypothermia in Preterm Neonates With Advanced Necrotizing Enterocolitis. *Pediatrics* 2010 Feb 1;125(2):e300-e308.
- (52) Rees CM, Hall NJ, Eaton S, Pierro A. Surgical strategies for necrotizing enterocolitis: a survey of practice in the United Kingdom. *Arch Dis Child* 2005;90:F152-F155.
- (53) Hall NJ, Curry J, Drake DP, Spitz L, Kiely EM, Pierro A. Resection and primary anastomosis is a valid surgical option for infants with necrotizing enterocolitis who weigh less than 1000 g. *Arch Surg* 2005 Dec;140(12):1149-51.
- (54) Ron O, Davenport M, Patel S, Kiely E, Pierro A, Hall NJ, et al. Outcomes of the "clip and drop" technique for multifocal necrotizing enterocolitis. *J Pediatr Surg* 2009;44(4):749-54.
- (55) Thyoka M, Eaton S, Kiely EM, Curry JI, Drake DP, Cross KM, et al. Outcomes of diverting jejunostomy for severe necrotizing enterocolitis. *J Pediatr Surg* 2011 Jun;46(6):1041-4.
- (56) Book LS, Herbst JJ, Atherton SO, Jung AL. Necrotizing enterocolitis in low-birth-weight infants fed an elemental formula. *J Pediatr* 1975 Oct;87(4):602-5.
- (57) Lessin MS, Luks FI, Wesselhoeft CW, Jr., Gilchrist BF, Iannitti D, DeLuca FG. Peritoneal drainage as definitive treatment for intestinal perforation in infants with extremely low birth weight (<750 g). *J Pediatr Surg* 1998 Feb;33(2):370-2.
- (58) Rovin JD, Rodgers BM, Burns RC, McGahren ED. The role of peritoneal drainage for intestinal perforation in infants with and without necrotizing enterocolitis. *J Pediatr Surg* 1999 Jan;34(1):143-7.
- (59) Rees CM, Eaton S, Kiely EM, Wade AM, McHugh K, Pierro A. Peritoneal drainage or laparotomy for neonatal bowel perforation? A randomized controlled trial. *Ann Surg* 2008 Jul;248(1):44-51.
- (60) Moss RL, Dimmitt RA, Barnhart DC, Sylvester KG, Brown RL, Powell DM, et al. Laparotomy versus peritoneal drainage for necrotizing enterocolitis and perforation. *N Engl J Med* 2006 May 25;354(21):2225-34.
- (61) Pierro A, Eaton S, Rees CM, De CP, Kiely EM, Peters MJ, et al. Is there a benefit of peritoneal drainage for necrotizing enterocolitis in newborn infants? *J Pediatr Surg* 2010 Nov;45(11):2117-8.

- (62) Rees CM, Pierro A, Eaton S. Neurodevelopmental outcomes of neonates with medically and surgically treated necrotizing enterocolitis. Arch Dis Child Fetal Neonatal Ed 2007 May;92(3):F193-F198.
- (63) Hintz SR, Kendrick DE, Stoll BJ, Vohr BR, Fanaroff AA, Donovan EF, et al. Neurodevelopmental and growth outcomes of extremely low birth weight infants after necrotizing enterocolitis. Pediatrics 2005 Mar;115(3):696-703.
- (64) Pierro A, Hall N. Surgical treatment of infants with necrotizing enterocolitis. Semin Neonatol 2003 Jun;8(3):223-32.