

Simultaneous intracranial EEG and fMRI of interictal epileptic discharges in humans

^{1,2}Serge Vulliemoz*, ¹David W. Carmichael*, ¹Karin Rosenkranz, ^{1,3}Beate Diehl,

¹Roman Rodionov, ¹Matthew C. Walker, ⁴Andrew W. McEvoy, ¹Louis Lemieux

**These authors contributed equally to the manuscript*

¹Department of Clinical and Experimental Epilepsy, UCL Institute of Neurology and National Hospital for Neurology and Neurosurgery, Queen Square, London, UK

²EEG and Epilepsy Unit, Neurology, University Hospital and Faculty of Medicine, Geneva, Switzerland

³Department of Neurophysiology, National Hospital for Neurology and Neurosurgery, Queen Square, London, UK

⁴Victor Horsley Dept. Neurosurgery, National Hospital for Neurology and Neurosurgery, Queen Square, London, UK

Running title: simultaneous intracranial EEG and fMRI in humans

Key words: epilepsy, intracranial EEG, fMRI

Abstract: 248 words; Main text: 3676

Figures: 4 (2 colour figures) + 1 supplementary figure

References: 39

Corresponding author:

Prof. Louis Lemieux

MRI Unit, National Society for Epilepsy

Chesham Lane

Chalfont St Peter

Buckinghamshire SL9 0RJ

United Kingdom

l.lemieux@ion.ucl.ac.uk

Tel: ++44 1494 601 300

Fax: ++44 1494 875 666

DISCLOSURE:

Brain Products (Munich, Germany) are manufacturers of the EEG recording equipment used in this work and they provided EKG recording equipment on loan.

None of the authors has any other conflict of interest to disclose.

ABSTRACT

Simultaneous scalp EEG-fMRI measurements allow the study of epileptic networks and more generally, of the coupling between neuronal activity and haemodynamic changes in the brain. Intracranial EEG (icEEG) has greater sensitivity and spatial specificity than scalp EEG but limited spatial sampling. We performed simultaneous icEEG and functional MRI recordings in epileptic patients to study the haemodynamic correlates of intracranial Interictal Epileptic Discharges (IED).

Two patients undergoing icEEG with subdural and depth electrodes as part of the presurgical assessment of their pharmaco-resistant epilepsy participated in the study. They were scanned on a 1.5T MR scanner following a strict safety protocol. Simultaneous recordings of fMRI and icEEG were obtained at rest. IED were subsequently visually identified on icEEG and their fMRI correlates were mapped using a General Linear Model (GLM).

On scalp EEG-fMRI recordings performed prior to the implantation, no IED were detected. icEEG-fMRI was well tolerated and no adverse health effect was observed. Intra-MR icEEG was comparable to that obtained outside the scanner. In both cases, significant haemodynamic changes were revealed in relation to IED, both close to the most active electrode contacts and at distant sites. In one case, results showed an epileptic network including regions that could not be sampled by icEEG, in agreement with findings from magneto-encephalography, offering some explanation for the persistence of seizures after surgery.

Hence, icEEG-fMRI allows the study of whole-brain human epileptic networks with unprecedented sensitivity and specificity. This could help improve our understanding of epileptic networks with possible implications for epilepsy surgery.

INTRODUCTION

In patients with epilepsy, electroencephalographic (EEG) recordings remain the main tool to investigate functional brain abnormalities and reveal characteristic paroxysmal events such as Interictal Epileptiform Discharges (IED), reflecting synchronised changes in post-synaptic potentials of large populations of cortical pyramidal neurons. Over the last 15 years, the advent of simultaneous scalp EEG and functional Magnetic Resonance Imaging (fMRI) recordings has allowed the non-invasive mapping of often complex and widespread transient haemodynamic responses (Blood Oxygenation Level Dependant or 'BOLD' changes) associated to IED and ictal events in focal epilepsy (Ives, Warach et al. 1993; Seeck, Lazeyras et al. 1998; Krakow, Allen et al. 2000; Al-Asmi, Benar et al. 2003; Salek-Haddadi, Diehl et al. 2006; Tyvaert, Hawco et al. 2008). IED-related multifocal positive and negative haemodynamic changes have been commonly revealed both distant and local to the presumed epileptic focus (Kobayashi, Bagshaw et al. 2006; Salek-Haddadi, Diehl et al. 2006). These findings have raised questions about the behaviour of the networks associated with epileptiform discharges, and in particular how haemodynamic responses are coupled to these events (Logothetis 2008) as the neurovascular coupling could be altered in pathological states such as epilepsy (Hamandi, Laufs et al. 2008; Lemieux, Laufs et al. 2008; Grouiller, Vercueil et al. 2010; Masterton, Harvey et al. 2010). Moreover, scalp EEG-fMRI fails to reveal convincing haemodynamic changes in a significant proportion of cases, possibly due to the limited sensitivity of scalp EEG and consequent poor characterisation of the baseline and inefficient modelling of the fMRI signal (Al-Asmi, Benar et al. 2003; Salek-Haddadi, Diehl et al. 2006). In patients who are candidates for epilepsy surgery, intracranial EEG (icEEG) remains the gold-standard to localise the epileptogenic zone and reveal propagation of epileptic activity. The technique has high sensitivity and spatial discrimination compared to scalp recording but limited spatial sampling. Simultaneous fMRI could mitigate these limitations and provide a new source of information about the organisation of

distributed epileptic networks. Additionally, by allowing the recording of epileptic electrical activity and fMRI signals within the same small region, the underlying local neurovascular coupling can be investigated.

We have recently established the parameters whereby simultaneous intracranial EEG and fMRI (icEEG-fMRI) can be recorded in humans without significant additional health risk (Carmichael, Thornton et al. 2010). Here, we present haemodynamic changes correlated with intracranial epileptiform activity in the first two patients with focal epilepsy who underwent icEEG-fMRI.

METHODS

Patients

All patients with refractory focal epilepsy undergoing intracranial EEG for presurgical assessment of their epilepsy **between June and September 2009 were considered for participation in the study between the end of the clinical icEEG recording and planned removal of the intracranial electrodes. We present the first 2 patients whom we were able to recruit and scan during this period. Patients were only recruited if they were in good general health, tolerated a post-operative clinical MRI electrode localisation scan and did not have evidence of damage to any electrodes (based on CT and clinical recordings).**

The study was approved by the Joint UCL/UCLH Committees on the Ethics of Human Research **and patients gave written informed consent.**

Prior to implantation of intracranial electrodes (AdTech, Racine, WI, USA), both patients underwent scalp EEG-fMRI acquisitions using our standard protocol (Vulliemoz, Thornton et al. 2009), during which no epileptiform abnormality was detected.

Case reports:

Patient 1 was a 42 year-old left-handed female with pharmaco-resistant cryptogenic left frontal lobe epilepsy. From the age of 18 she suffered from multiple daily complex motor seizures starting with stiffening or **a feeling of tension** in the right arm, sometimes **evolving to impaired** awareness. Structural MRI (3 Tesla) was unremarkable. Long-term video-EEG recording showed occasional (ca. 10/hour) low-amplitude left paracentral IED with no localisable ictal pattern. **Magnetoencephalography (MEG, 275-channel CTF Omega whole cortex magneto-meter, VSM MedTech, Coquitlam, BC, Canada; 40 min recording) was also performed. Source analysis of the 30 IED recorded during MEG (Equivalent Current Dipole**

on the patient's own segmented cortex and a 3-shell boundary element method realistic head model) suggested left frontal IED propagating from a posterior frontal medial focus to the pericentral cortex near the hand motor cortex.

Intracranial subdural electrodes were implanted for coverage of the left frontal lobe (Figure 1.a). Subdural recording from the left medial frontal cortex was not possible due to prominent bridging veins. During the clinical recording, icEEG showed small amplitude very focal IED over the pre- and post-central cortex. Seizures onset was localized to the pre- and post-central cortex. Cortical resection in this region was tailored by icEEG findings and electrocorticography. Follow-up 3 months after surgery revealed persistent simple partial seizures (70% frequency reduction) and moderate weakness of the left hand.

Patient 2 was a 31 year-old right-handed female with pharmaco-resistant cryptogenic left temporal epilepsy. From the age of 6 she has suffered from complex partial seizures with epigastric aura, dysgueusia followed by loss of awareness, eye and head version to the right, followed by secondary tonic-clonic generalisation. Structural MRI showed no abnormality. Long-term video-EEG recording demonstrated IED and seizures onset in the left temporal electrodes.

Intracranial electrodes were implanted for coverage of the left lateral and mesial temporal lobe (Figure 2.a) The clinical icEEG revealed IED involving almost exclusively the left amygdala and hippocampus, with some propagation to the basal temporal lobe and only rare IED involving the lateral grid. Seizure onset was localised to the left hippocampus. She subsequently underwent left anterior temporal lobectomy. At follow-up 3 months after surgery, seizures were less severe but simple partial seizures remained.

Data acquisition

MRI

MRI was performed using a 1.5T Siemens Avanto scanner (Siemens, Erlangen, Germany) between the end of the diagnostic invasive EEG recording and removal of the icEEG electrodes. To limit heating, we used a head transmit and receive RF coil, low SAR (Specific Absorption Rate) sequences ($\leq 0.1\text{W/Kg}$, head average), as described elsewhere (Carmichael, Thornton et al. 2008; Carmichael, Thornton et al. 2010). The following scans were performed: 1) localiser, 2) FLASH T1-volume (TR 3s/TE 40 ms/flip angle 90), 3) two 10-minute gradient echo EPI fMRI scans (TR 3s/TE 78ms/ 38 slices/200 volumes, 3x3x3mm), during which intracranial EEG was recorded.

icEEG

EEG electrode leads were routed directly to the vertex before replacing the bandage. The cables connecting the electrodes to the amplifiers for the clinical recordings were replaced by shorter cables (length 90 cm) to minimize radio-frequency induced risk of heating and laid out precisely in relation to the scanner (Carmichael, Thornton et al. 2008; Carmichael, Thornton et al. 2010). EEG was recorded using an MR-compatible amplifier system (Brain Products, Munich, Germany) and dedicated recording software (Brain **Vision** Recorder) during the fMRI acquisitions. **The EEG recording system sampling at 5000Hz was synchronised to the scanner's 20kHz gradient clock.**

Data analysis

icEEG

Scanning-related artefacts were removed using standard implementation of template subtraction and filtering (Allen, Josephs et al. 2000) in Brain **Vision** Analyzer (V1.3). On the corrected icEEG, pulse-related artefacts were small compared to the epileptiform activity and did not interfere with IED identification. IED were detected and labelled by an expert electroencephalographer (SV). For the purpose of fMRI modelling, IED were grouped according to their most active contact and spatial extent (number of contacts involved).

fMRI

fMRI analysis was performed using SPM5 software package (www.fil.ion.ucl.ac.uk/SPM). fMRI time-series were corrected for slice acquisition time, realigned to the mean image and spatially smoothed with an isotropic Gaussian kernel of 8 mm full width at half maximum.

Mapping epileptic networks: whole brain IED-related BOLD changes

Pre-processed fMRI time-series data were analysed using a General Linear Model (GLM) to map regional IED-related changes of the BOLD signal. Discharges were modelled as zero-duration events (unit impulse, or 'delta', functions) or as blocks in case of sustained IED activity and then convolved with the canonical Haemodynamic Response Function (HRF (Friston, Fletcher et al. 1998)). Motion-related effects were included in the GLM in the form of the 6 realignment parameters.

T contrasts (positive and negative) were used to generate SPM{t} maps, with a significance threshold of $p < 0.001$ uncorrected for multiple comparisons overlaid onto T1-weighted volumetric images obtained in the same session and co-registered to the EPI images (Ashburner and Friston 1997).

Detecting focal BOLD changes in the irritative zone

Given the potential for local signal alteration around the icEEG electrodes **and resulting BOLD sensitivity reduction (Deichmann, Josephs et al. 2002)**, we wanted to confirm that local correlation between epileptic icEEG events and BOLD signal could be measured with our technique. Clinical intracranial macro-electrode contacts typically record electric signals within a distance of about 1 cm (Lachaux, Rudrauf et al. 2003) **and therefore record events directly from a known brain region (in contrast to scalp EEG-fMRI recordings, where the EEG represents the weighted sum of distributed generators). Therefore we looked for IED-correlated BOLD changes in this region using a similar volume of interest (VOI: 1-cm radius sphere around the electrode contact location with the strongest epileptic activity).**

Having an a priori defined VOI, the p-value of the local maxima at a given threshold (here $p < 0.05$) represents the statistical significance of the result with strong control of Family-wise type I error (Friston 1997). **The VOI analysis is an application of the small volume correction tool in SPM. Instead of establishing the significance of a correlation between the predicted and measured BOLD signal for each voxel over the entire brain (using random field theory for multiple comparisons) it performs the statistical threshold correction over the pre-specified VOI, taking into account its shape and volume. Therefore the result is not a map, but rather the presence or absence of a significant finding within the VOI.**

RESULTS

Neither patient reported any discomfort, headache or neurological symptom during or immediately following the icEEG-fMRI sessions. During electrode removal, careful visual inspection of the neighbouring brain tissue did not reveal any sign of adverse effect and no unusual abnormality was noted in histological examination.

In both patients, the corrected icEEG and intracranial IED were similar to icEEG recorded outside the scanner with the same equipment (**Figures 1 and 2**) and with the previous clinical EEG recording. MRI image quality was sufficient to obtain significant correlations to IED (see below and **Figure S1**).

Patient 1

Similarly to the clinical icEEG findings, very abundant (persistent and at times almost continuous >100/min) low amplitude IED were recorded over the left pre-central and post-central cortex (**Figures 1 and 3, Table 1**). IED were marked in the contact with most IED (and corresponding to seizure onset zone) in the pre-central cortex. They occurred in runs of spikes, spike-waves and polyspike-waves and these runs were modelled as constant-amplitude blocks in the fMRI modelling.

Whole brain SPM{t} maps revealed negative BOLD changes in the left post-central gyrus in close proximity to the spiking contacts near the hand motor cortex (peak BOLD magnitude: -0.5%, **peak t-value: 3.35**; extent: 4 voxels, estimated distance between cluster maximum and most active contact = 13 mm), and in the left frontal medial cortex (-1%; **peak t-value 3.38**; 13 voxels, 18 mm to most active contact). There was good spatial concordance between these BOLD changes and the localisation of IED sources estimated from the MEG recording **for the medial frontal cluster and the lateral frontal cluster (Euclidian centre-to-centre distance = 7 mm and 14 mm, respectively) (Figure 3 and S1)**. The VOI analysis confirmed significant local **negative correlation** around the most spiking contact ($p=0.005$).

Patient 2

Very frequent IED (>30/min) were observed, involving the left amygdala (depth electrode), the left hippocampus (depth electrode), and, less frequently, the left basal temporal cortex (strip electrode) (**Figures 2 and 4, Table 1**). Rare IED (N = 2) were recorded on the lateral temporal grid. SPM{t} maps of IED with the largest field (involving the amygdala, hippocampus and basal temporal lobe) showed strong negative BOLD changes in the medial parietal (-1%; **peak t-value: 4.27**; 101 voxels) and lateral parieto-occipito-temporal cortex bilaterally. **These BOLD changes show very good spatial concordance with the posterior part of the Default Mode Network (Raichle, MacLeod et al. 2001)**. The VOI-based analysis revealed positive **correlation** in the anterior hippocampus (p=0.002).

DISCUSSION

To the best of our knowledge this is the first report of simultaneous icEEG and fMRI recording in humans. Following a strict data acquisition protocol, no adverse effects were observed and icEEG data quality allowed clear identification of IED. **Our objectives were 2-fold: firstly, to demonstrate the technique's capability to reveal IED-related BOLD changes over the whole brain using a simple modelling approach similar to that used for scalp EEG-fMRI; secondly, to verify if it was possible to detect significant IED-BOLD coupling from signals recorded from within the same region.** We showed significant IED-related BOLD changes in the immediate vicinity of the focus localised by icEEG, suggesting good spatial concordance between neuronal and BOLD changes in focal epileptic activity. Distant BOLD changes related to specific interictal discharge patterns were also observed illustrating a potential advantage of simultaneous icEEG-fMRI for investigating whole-brain epileptic networks over icEEG alone and scalp EEG-fMRI.

Methodological considerations

To ensure patient safety, we used the following data acquisition protocol: a 1.5T scanner with a head transmit-receive coil; RF power limited to 0.1W/Kg head-average; exact cable lengths and placement in the scanner bore; exact EEG recording equipment configuration. This approach was devised based on previous specific testing on a test object with the same arrangement and a safety margin to account for any differences between in-vitro safety studies and patient/electrode configurations (Carmichael, Thornton et al. 2008; Carmichael, Thornton et al. 2010).

Despite MR image artefacts (distortion and drop out) near the intracranial electrode contacts, IED-related BOLD changes within 1.0 cm of the active electrode were detected. This demonstrates that the technique can detect BOLD signal changes local to the electrode contacts and can therefore be applied to investigate local icEEG-fMRI coupling in epilepsy. A more systematic investigation of data quality issues that will require a larger group of subjects

with different implantation strategies, is currently underway in our laboratory. In the future, optimisation of imaging sequences and intracranial electrodes (e.g. using material with lower magnetic susceptibility) should further improve fMRI data quality and detection sensitivity.

Differences in the event-to-slice timing can be accounted for by using a flexible basis set. Due to the frequency of events in this study the time from events to slice acquisition was critical to define expected signal changes hence we used slice timing correction. Uncertainty in the scalp EEG-derived model can be addressed by using a flexible basis set for the HRF; because of the exquisite definition of the events in our data and for the sake of simplicity we assumed that the IED-related BOLD changes are canonical as previously demonstrated for focal discharges recorded on the scalp (Lemieux, Laufs et al. 2008). Nonetheless, the availability of co-localised icEEG-fMRI signals will allow more systematic assessment of inter-regional and inter-individual variability in epileptic event-related haemodynamic changes and the study of the EEG correlates of this variability.

The SPM{t} maps showed significant IED-related BOLD changes with magnitude (0.5 to 1%) and extent (4 to 101 voxels) within the range of commonly observed scalp IED-related BOLD effects at this field strength (Krakow, Woermann et al. 1999; Benar, Gross et al. 2002). The location of the clusters was concordant with **non-invasive electroclinical data or with distant regions known to show haemodynamic changes related to focal temporal lobe IED** (Laufs, Hamandi et al. 2007). Thus, it is highly unlikely that these results are due to insufficient control of false positives. Given icEEG's much greater sensitivity, the generators of detected IED on icEEG can be weaker and of smaller spatial extent than for IED detected on scalp EEG. We would therefore expect the associated haemodynamic changes to occur over a smaller brain region and to be of smaller magnitude. Although simultaneous scalp recordings were not available, the small IED field and, in patient 2, the deep localisation of the IED

focus make it unlikely that these events would have been detected with scalp EEG electrodes, consistent with the lack of IED in previous scalp EEG-fMRI recording for both patients. The high frequency of events narrows the dynamic range of the relatively slow haemodynamic response compared to expected BOLD changes in scalp EEG-fMRI studies, which model rarer events that originate from larger areas of active cortex (Tao, Ray et al. 2005). In addition, possible non-linear effects (de Zwart, van Gelderen et al. 2009) related to very close occurrence of successive IED might also play a role (Bagshaw, Hawco et al. 2005; Salek-Haddadi, Diehl et al. 2006).

In addition to the fMRI artefacts due to the depth electrode, the detection of IED-related hippocampal BOLD changes with scalp EEG-fMRI is limited by the difficulty of recording temporal mesial IED even when using fMRI protocols optimised for the basal temporal lobe (Bagshaw, Torab et al. 2006; Kobayashi, Bagshaw et al. 2006). In patient 2, we found a highly significant correlation between hippocampal IED and BOLD signal changes **from within the same region**.

Neurophysiological relevance

In fMRI studies the starting hypothesis is that focal neuronal activity is coupled to haemodynamic changes, so that focal BOLD changes can be interpreted as reflecting changes of neuronal activity (Logothetis 2008). In non-human primates, BOLD changes are best correlated to synaptic activity (local field potential) (Logothetis, Pauls et al. 2001) but the coupling between cortical evoked potentials and haemodynamic responses might not show perfect spatial match (Disbrow, Slutsky et al. 2000). In humans, non-invasive cerebral perfusion measurements suggested preserved neurovascular coupling in relation to generalised IED (Stefanovic, Warnking et al. 2005; Carmichael, Hamandi et al. 2008; Hamandi, Laufs et al. 2008). The non-invasive study of the neurovascular coupling during epileptic activity in humans is limited by the poor sensitivity and low spatial resolution of scalp EEG (Alarcon, Guy et al. 1994) and the resulting suboptimal characterisation of the baseline state. By contrast, simultaneous recording of local neuronal activity and haemodynamic

changes presented here revealed co-localised haemodynamic changes to the most active icEEG contact as well as distant changes, concordant with invasive animal studies (Englot, Mishra et al. 2008).

In patient 1, we observed negative BOLD changes at the site of IED. Negative BOLD changes, linked to decreased local field potential, have been reported in monkeys in response to decreased visual stimulus and have been related to reduced neuronal activity (Shmuel, Yacoub et al. 2002). The situation is more complicated for negative BOLD changes correlated to scalp IED in focal epilepsy, that have been found predominantly distantly but also in close proximity to the presumed epileptic focus in humans (Kobayashi, Bagshaw et al. 2006; Salek-Haddadi, Diehl et al. 2006; Vulliemoz, Thornton et al. 2009). Deviations from the norm in the shape of the focal IED-related haemodynamic response (initial dip, peak, undershoot) and BOLD changes preceding scalp detected IED have been reported (Jacobs, Levan et al. 2009), although their significance in epileptic activity is unclear (Salek-Haddadi, Diehl et al. 2006; Lemieux, Laufs et al. 2008). The negative BOLD changes observed here could reflect such alterations of the neurovascular coupling due to local pathology or reflect an imbalance between excitatory and inhibitory neuronal processes (Logothetis 2008) with decreased metabolic demand in the case of the very focal IED. This could be reversed in the case of IED involving larger patches of cortex and detectable on scalp EEG, consistent with the observation that, in scalp-EEG studies, most IED-correlated BOLD changes concordant with the epileptic zone are positive (Kobayashi, Bagshaw et al. 2006; Salek-Haddadi, Diehl et al. 2006).

In patient 2, we found a highly significant local correlation between hippocampal IED and BOLD signal changes within the same region (1 cm around the most spiking contact) by using the spatial specificity of the icEEG recording. We also observed prominent slow wave activity in the hippocampus (**Figure 2**), whereas slow waves were not a prominent feature of spiking contacts in Patient 1 (**Figure 1**). This is consistent with previous reports of increased slow wave

spectral power at electrodes close to positive vs. negative BOLD changes (Benar, Grova et al. 2006). **In addition, we found distant IED-related negative BOLD changes in the medial parietal cortex (precuneus) and lateral occipito-temporo-parietal cortex that are localised in regions shown to participate in the Default Mode Network (DMN) of the brain (Raichle, MacLeod et al. 2001). This is consistent with previous observations of DMN involvement in temporal lobe epileptic activity (Kobayashi, Bagshaw et al. 2006; Salek-Haddadi, Diehl et al. 2006; Laufs, Hamandi et al. 2007) and with the coupling between the hippocampus and the DMN revealed by functional connectivity studies (Raichle, MacLeod et al. 2001).**

Clinical relevance

The mapping of BOLD changes related to intracranial IED can provide useful information about the epileptic network, circumventing low spatial resolution (typically 1cm^3 around the electrode contact (Lachaux, Rudrauf et al. 2003)) and restricted brain coverage. In the two patients studied here, intracranially recorded IED were very focal and invisible to scalp EEG so that only icEEG allowed modelling of the BOLD changes to confirm focal icEEG findings or to reveal changes at sites not explored by icEEG electrodes.

In patient 1, **scalp IED were recorded during long-term EEG (mostly during drowsiness or sleep) and during MEG but not during scalp EEG-fMRI. These differences in activity are common and can result from source orientation or fluctuations of brain state across recording sessions.** icEEG-fMRI showed left frontal medial IED-related BOLD change and a weaker left lateral BOLD change, concordant with MEG results showing left medial frontal IED onset with propagation to left lateral frontal cortex (**Figure 3**). The concordance of the two results and persistence of the seizures after surgery limited to portions of the left lateral pre- and post-central cortex support an important role of the medial frontal cortex in the epileptic network of this patient. This could not be investigated by icEEG alone for technical reasons (see case report), while icEEG-fMRI allowed for whole brain

investigation providing complementary information. **This example suggests that the icEEG-fMRI results, and the consequently improved knowledge of the epileptic network, could result in a better planning of epilepsy surgery and estimation of the odds of seizure freedom.** Larger studies will allow better definition of the sensitivity, specificity and clinical relevance of icEEG-fMRI as a presurgical mapping tool for patients with pharmaco-resistant epilepsy.

ACKNOWLEDGEMENTS

We would like to thank Catherine Scott and Dr Stjepana Kovac in the Epilepsy Telemetry Unit, Prof. John Duncan in the Epilepsy Department and Lisa Strycharczuk, Catherine Green, Alison Duncan, Prashanth Kesara, Bruce Metheringham and John Thornton in the Neuroradiology Department at NHNN (UCLH) for their help. We are also grateful to Dr. Fergus Rugg-Gunn for the MEG analysis and to Will Penny for useful discussions about statistics. S. Vulliemoz is supported by a fellowship for advanced researcher and by SNF grant 33CM30-124089 (SPUM Epilepsy) from the Swiss National Science Foundation. We acknowledge the financial support of the UK Medical Research Council (MRC grant G0301067). This work was undertaken at UCLH/UCL who received a proportion of funding from the Department of Health's NIHR Biomedical Research Centres funding scheme.

REFERENCES

- Al-Asmi, A., C. G. Benar, et al. (2003). "fMRI activation in continuous and spike-triggered EEG-fMRI studies of epileptic spikes." *Epilepsia* **44**(10): 1328-39.
- Alarcon, G., C. N. Guy, et al. (1994). "Intracerebral propagation of interictal activity in partial epilepsy: implications for source localisation." *J Neurol Neurosurg Psychiatry* **57**(4): 435-49.
- Allen, P. J., O. Josephs, et al. (2000). "A method for removing imaging artifact from continuous EEG recorded during functional MRI." *Neuroimage* **12**(2): 230-9.
- Ashburner, J. and K. Friston (1997). "Multimodal image coregistration and partitioning--a unified framework." *Neuroimage* **6**(3): 209-17.
- Bagshaw, A. P., C. Hawco, et al. (2005). "Analysis of the EEG-fMRI response to prolonged bursts of interictal epileptiform activity." *Neuroimage* **24**(4): 1099-112.
- Bagshaw, A. P., L. Torab, et al. (2006). "EEG-fMRI using z-shimming in patients with temporal lobe epilepsy." *J Magn Reson Imaging* **24**(5): 1025-32.
- Benar, C. G., D. W. Gross, et al. (2002). "The BOLD response to interictal epileptiform discharges." *Neuroimage* **17**(3): 1182-92.
- Benar, C. G., C. Grova, et al. (2006). "EEG-fMRI of epileptic spikes: concordance with EEG source localization and intracranial EEG." *Neuroimage* **30**(4): 1161-70.
- Carmichael, D. W., K. Hamandi, et al. (2008). "An investigation of the relationship between BOLD and perfusion signal changes during epileptic generalised spike wave activity." *Magn Reson Imaging* **26**(7): 870-3.
- Carmichael, D. W., J. S. Thornton, et al. (2008). "Safety of localizing epilepsy monitoring intracranial electroencephalograph electrodes using MRI: radiofrequency-induced heating." *J Magn Reson Imaging* **28**(5): 1233-44.
- Carmichael, D. W., J. S. Thornton, et al. (2010). "Feasibility of simultaneous intracranial EEG-fMRI in humans: a safety study." *Neuroimage* **49**(1): 379-90.
- de Zwart, J. A., P. van Gelderen, et al. (2009). "Hemodynamic nonlinearities affect BOLD fMRI response timing and amplitude." *Neuroimage* **47**(4): 1649-58.
- Deichmann, R., O. Josephs, et al. (2002). "Compensation of susceptibility-induced BOLD sensitivity losses in echo-planar fMRI imaging." *Neuroimage* **15**(1): 120-35.
- Disbrow, E. A., D. A. Slutsky, et al. (2000). "Functional MRI at 1.5 tesla: a comparison of the blood oxygenation level-dependent signal and electrophysiology." *Proc Natl Acad Sci U S A* **97**(17): 9718-23.
- Englot, D. J., A. M. Mishra, et al. (2008). "Remote effects of focal hippocampal seizures on the rat neocortex." *J Neurosci* **28**(36): 9066-81.
- Friston, K. J. (1997). "Testing for anatomically specified regional effects." *Hum Brain Mapp* **5**(2): 133-6.
- Friston, K. J., P. Fletcher, et al. (1998). "Event-related fMRI: characterizing differential responses." *Neuroimage* **7**(1): 30-40.
- Grouiller, F., L. Vercueil, et al. (2010). "Characterization of the hemodynamic modes associated with interictal epileptic activity using a deformable model-based analysis of combined EEG and functional MRI recordings." *Hum Brain Mapp* [Epub ahead of print].
- Hamandi, K., H. Laufs, et al. (2008). "BOLD and perfusion changes during epileptic generalised spike wave activity." *Neuroimage* **39**(2): 608-18.
- Ives, J. R., S. Warach, et al. (1993). "Monitoring the patient's EEG during echo planar MRI." *Electroencephalogr Clin Neurophysiol* **87**(6): 417-20.
- Jacobs, J., P. Levan, et al. (2009). "Hemodynamic changes preceding the interictal EEG spike in patients with focal epilepsy investigated using simultaneous EEG-fMRI." *Neuroimage* **45**(4): 1220-31.
- Kobayashi, E., A. P. Bagshaw, et al. (2006). "Temporal and extratemporal BOLD responses to temporal lobe interictal spikes." *Epilepsia* **47**(2): 343-54.

- Kobayashi, E., A. P. Bagshaw, et al. (2006). "Negative BOLD responses to epileptic spikes." Hum Brain Mapp **27**(6): 488-97.
- Krakov, K., P. J. Allen, et al. (2000). "EEG recording during fMRI experiments: image quality." Hum Brain Mapp **10**(1): 10-5.
- Krakov, K., F. G. Woermann, et al. (1999). "EEG-triggered functional MRI of interictal epileptiform activity in patients with partial seizures." Brain **122 (Pt 9)**: 1679-88.
- Lachaux, J. P., D. Rudrauf, et al. (2003). "Intracranial EEG and human brain mapping." J Physiol Paris **97**(4-6): 613-28.
- Laufs, H., K. Hamandi, et al. (2007). "Temporal lobe interictal epileptic discharges affect cerebral activity in "default mode" brain regions." Hum Brain Mapp **28**(10): 1023-32.
- Lemieux, L., H. Laufs, et al. (2008). "Noncanonical spike-related BOLD responses in focal epilepsy." Hum Brain Mapp **29**(3): 329-45.
- Logothetis, N. K. (2008). "What we can do and what we cannot do with fMRI." Nature **453**(7197): 869-78.
- Logothetis, N. K., J. Pauls, et al. (2001). "Neurophysiological investigation of the basis of the fMRI signal." Nature **412**(6843): 150-7.
- Masterton, R. A., A. S. Harvey, et al. (2010). "Focal epileptiform spikes do not show a canonical BOLD response in patients with benign rolandic epilepsy (BECTS)." Neuroimage **51**(1): 252-60.
- Raichle, M. E., A. M. MacLeod, et al. (2001). "A default mode of brain function." Proc Natl Acad Sci U S A **98**(2): 676-82.
- Salek-Haddadi, A., B. Diehl, et al. (2006). "Hemodynamic correlates of epileptiform discharges: an EEG-fMRI study of 63 patients with focal epilepsy." Brain Res **1088**(1): 148-66.
- Seeck, M., F. Lazeyras, et al. (1998). "Non-invasive epileptic focus localization using EEG-triggered functional MRI and electromagnetic tomography." Electroencephalogr Clin Neurophysiol **106**(6): 508-12.
- Shmuel, A., E. Yacoub, et al. (2002). "Sustained negative BOLD, blood flow and oxygen consumption response and its coupling to the positive response in the human brain." Neuron **36**(6): 1195-210.
- Stefanovic, B., J. M. Warnking, et al. (2005). "Hemodynamic and metabolic responses to activation, deactivation and epileptic discharges." Neuroimage **28**(1): 205-15.
- Tao, J. X., A. Ray, et al. (2005). "Intracranial EEG substrates of scalp EEG interictal spikes." Epilepsia **46**(5): 669-76.
- Tyvaert, L., C. Hawco, et al. (2008). "Different structures involved during ictal and interictal epileptic activity in malformations of cortical development: an EEG-fMRI study." Brain **131**(Pt 8): 2042-60.
- Vulliemoz, S., R. Thornton, et al. (2009). "The spatio-temporal mapping of epileptic networks: combination of EEG-fMRI and EEG source imaging." Neuroimage **46**(3): 834-43.

	Type of IED	Events in 20 min EPI recording
Patient 1	Runs of small amplitude IED in the left peri-central cortex	Total time of IED blocks / baseline = 0.26
Patient 2	Left amygdala >> hippocampus	N= 23
	Left hippocampal>>amygdala IED	N= 59
	L amygdala + hippocampus	N= 202
	L amygdala + hippocampus + basal temporal	N= 146
	L hippocampus : small IED and large amplitude consecutive slow-wave	N= 222

Table 1: Interictal Epileptiform Discharges (IED) recorded during fMRI scanning

(see Figures for illustration of EEG traces and localisation of electrode contacts).

FIGURE LEGENDS

Figure 1:

Representative sample of intracranial EEG from Patient 1, bipolar montage on parts of a 8x8 contacts grid (1-8: superior row front to back; etc). Top: outside the MR scanner; bottom: inside the MR-scanner after correction of MR-gradient artefacts. For the contacts with the most prominent epileptic activity (red circle, see Figure 3 for localisation), the runs of IED were marked as blocks (red boxes). Note the good quality of the corrected EEG inside the scanner and how similar it is to the recording outside the scanner.

Figure 2:

Representative sample of intracranial EEG in Patient 2: colour ellipses correspond to the colours of the electrodes as displayed in Figure 4 (yellow: depth electrode to amygdala, medial to lateral; orange: idem to hippocampus; red: basal subdural strips, medial to lateral; green: sample of temporal lateral subdural grid).

Top: icEEG recorded outside the MR scanner; bottom: ic EEG recorded inside the MR-scanner after correction of MR-gradient artefacts. Short arrows: IED restricted to mesial temporal lobe (hippocampus>amygdala); long arrows: IED recorded in the medial temporal and basal temporal lobe. Empty arrows: prominent slow-wave activity in the hippocampus is also observed. Note the good quality of the corrected EEG inside the scanner and its similarity to the recording outside the scanner.

Figure 3:

Patient 1: a) Subdural electrodes positions overlaid onto post-implantation T1-weighted MRI: one subdural grid (6x8 contacts) over the lateral left frontal lobe (red dots) and three additional strips (1x8 contacts each, blue and green dots) for

comprehensive lateral fronto-temporal coverage. Blue line: irritative zone (were IED are recorded); red line: contact demonstrating maximal epileptic activity;

b-c) Left panels: statistical maps of BOLD changes correlated to IED showed a left medial frontal (at crosshair in b) and a left lateral frontal cluster (at crosshair in c); right panels: Results of MEG analysis showing IED onset in medial frontal lobe propagating to lateral frontal lobe (courtesy of Dr F. Rugg-Gunn). There is good spatial concordance between MEG sources and the BOLD changes.

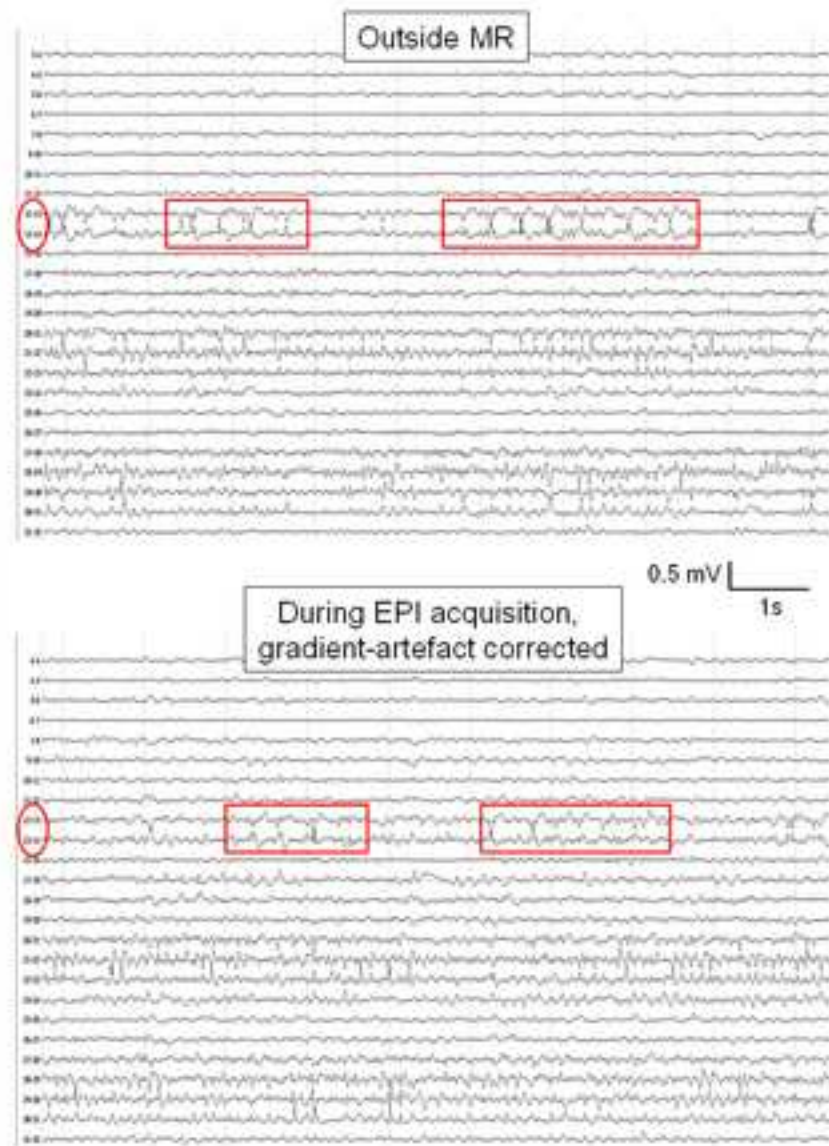
Figure 4:

Patient 2: a) Subdural electrodes positions overlaid onto post-implantation T1-weighted MRI: two six-contact depth electrodes (lateral-medial orientation) in the left amygdala (yellow dots) and hippocampus (orange dots). Lateral temporal coverage was obtained by a subdural grid (4x8 contacts, green dots), basal temporal coverage was accomplished using 3 subdural strips (1x8 contacts, red dots); 1 subdural strip (2x8 contacts, blue dots) was placed over the inferior frontal cortex.

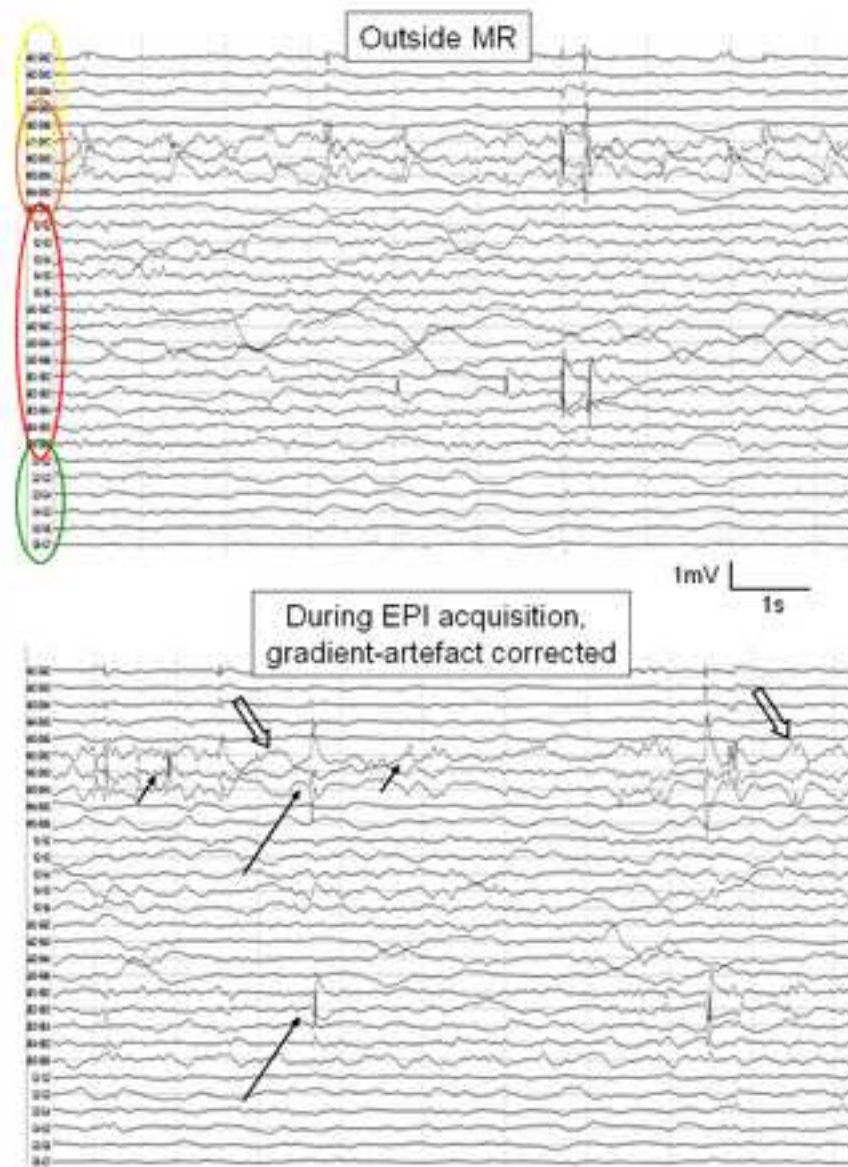
b) Coronal view showing the position of the depth electrode in the hippocampus (orange dots, crosshair at most active contact)

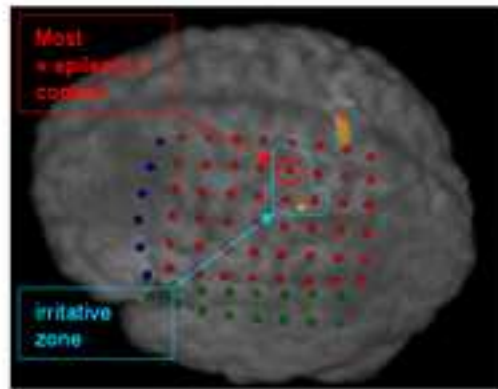
c) Statistical maps of BOLD changes showed bilateral medial and lateral parietal negative changes correlated to IED.

5. Figure 1
[Click here to download high resolution image](#)

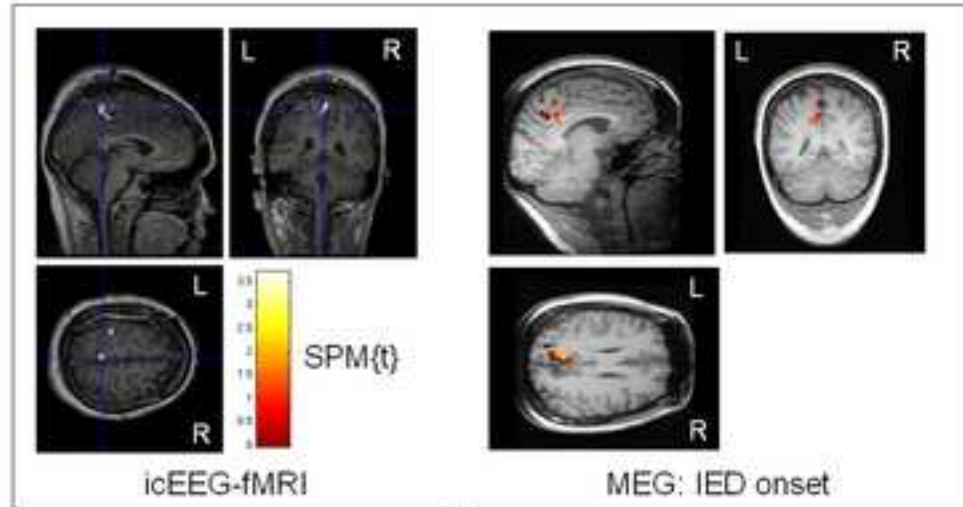


5. Figure 2
[Click here to download high resolution image](#)

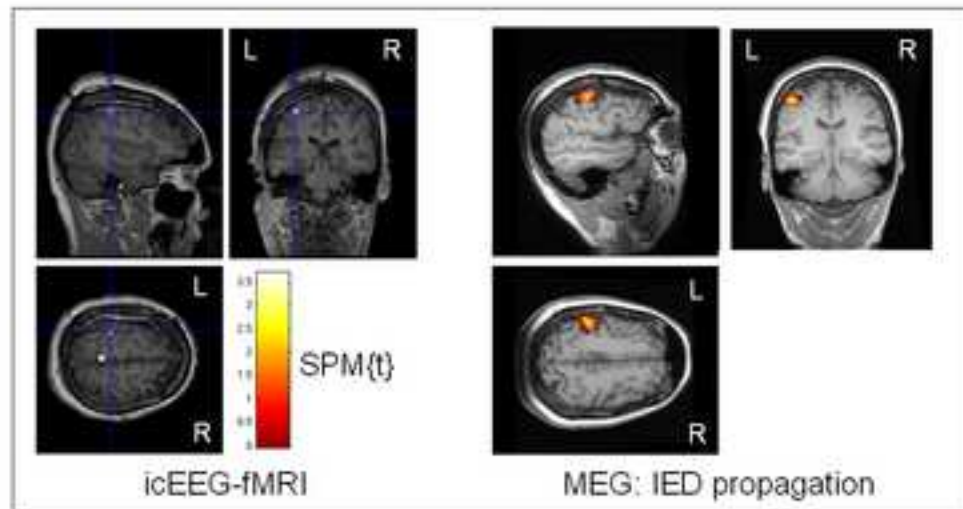




1.a



1.b



1.c

6. Supplementary Material: Figure S1

[Click here to download 6. Supplementary Material: Vulliemoz_icEEGfMRI_FigS1.pdf](#)

6. Supplementary Material: Figure S1 Legend

[Click here to download 6. Supplementary Material: NIMG-10-677_Supplementary_fig_Legend.doc](#)