

# Thorax

## Micro-CT of tracheal stenosis in trisomy 21

Journal:	<i>Thorax</i>
Manuscript ID	thoraxjnl-2018-212966.R1
Article Type:	Images in Thorax
Date Submitted by the Author:	n/a
Complete List of Authors:	Shelmerdine, Susan; Great Ormond Street Hospital For Children NHS Foundation Trust, Clinical Radiology; University College London Great Ormond Street Institute of Child Health Ashworth, Michael; Great Ormond Street Hospital For Children NHS Trust, Paediatric Pathology Calder, Alistair; Great Ormond Street Hospital for Children NHS Foundation Trust, Dept of Radiology Muthialu, Nagarajan; Great Ormond Street Hospital For Children NHS Foundation Trust, Cardiothoracic Surgery Arthurs, Owen; Great Ormond Street Hospital For Children NHS Foundation Trust, Clinical Radiology; University College London Great Ormond Street Institute of Child Health
Keywords:	Imaging/CT MRI etc, Thoracic Surgery, Airway Epithelium, Rare lung diseases

SCHOLARONE™  
Manuscripts

**Title Page****Title:**

Micro-CT of tracheal stenosis in trisomy 21.

**Authors:**

Susan C Shelmerdine, Michael T Ashworth, Alistair D. Calder, Nagarajan Muthialu, Owen J Arthurs

**Affiliations (all authors):**

Great Ormond Street Hospital for Children, London, WC1N 3JH, United Kingdom

**Corresponding Author:**

Name: Dr. Susan Shelmerdine

Job title: Paediatric Radiology Research Fellow

Address: Department of Clinical Radiology,

Great Ormond Street Hospital for Children, London, WC1N 3JH, United Kingdom

Email: susan.shelmerdine@gosh.nhs.uk

Telephone: +44 (0) 20 9200 (x6369)

**Keywords: (MeSH terms)**

x-ray microtomography, autopsy, down syndrome, tracheal stenosis/diagnostic imaging, infant

**Word count:**

565 words

## **Manuscript**

### **Case:**

A male infant with trisomy 21, born at 36 weeks gestation, had care withdrawn at 2 months of age and was referred for postmortem investigations. The child had been ventilator dependent since the first week of life following surgery for intestinal perforation from necrotising enterocolitis. A CT thorax at 1 month of age demonstrated a tight tracheal stenosis, inferior to the tip of the endotracheal tube, with a luminal diameter of 1.2mm over a length of 1cm (Figure 1). There were no associated cardiovascular or bronchial tree anomalies. Despite efforts to optimise the child's condition for tracheal reconstruction, he was subsequently found to have an underlying immune deficit disorder with profound lymphopenia and continued to require inotropic support for haemodynamic compromise. After a further month of expectant clinical management without improvement, care was withdrawn.

The parents gave consent for a limited autopsy of the chest to further investigate the cause for the tracheal stenosis. Given the small size of the infant, and challenging nature of dissection, the excised trachea was imaged using microfocus computed tomography (micro-CT). This technique uses multiple X-rays to create a high resolution 3D imaging dataset at a spatial resolution comparable to light microscopy (voxel size down to 1 micron). It has traditionally been used for non-destructive testing in the aerospace industry and in preclinical animal studies, but is gaining popularity with clinical applications including post-mortem fetal imaging and breast pathological specimen analysis [1].

The trachea was prepared using a solution of formalin and potassium iodide, and imaged at a resolution of 28microns (0.028mm). This was performed on a Med-X Alpha microfocus-CT scanner (Nikon Metrology, Tring, UK) with a molybdenum target and no additional filtering. The tube current was 111 microamps, with energy of 90 kV, power of 10W, gain of 24dB. The exposure time was 354ms, comprising of 2294 projections, 4 X-ray frames per projection, taking approximately 38 minutes to acquire. Scans were reconstructed using modified Feldkamp filtered back projection (with median filter kernel size 3) on proprietary software (CTPro3D; Nikon Metrology), and post-processed using VG Studio MAX (Volume Graphics GmbH, Heidelberg, Germany).

Imaging revealed multiple complete and bifid tracheal rings throughout the level of the stenosis, with associated areas of mucosal ulceration and tracheal wall fibrosis, the latter believed to result from prolonged ventilation and resultant tissue granulation. The findings were subsequently confirmed at histopathological dissection (Figure 2).

Congenital tracheal stenosis is a rare airway anomaly estimated to occur in approximately 1 in 64,500 births, with several small case series reporting an association with trisomy 21 [2]. It is characterized by complete tracheal rings and, over 60% also have complex cardiac anomalies. The condition

1  
2  
3 carries a significant mortality rate (as high as 77%), although with modern surgical reconstruction  
4 techniques, good survival rates (of approximately 88%) can be achieved [3].  
5  
6

7 This case demonstrates the first documented usage of micro-CT technology on human tracheal tissue  
8 in this setting. The non-destructive nature of high resolution imaging creates a digital dataset for 3D  
9 multiplanar visualisation of the whole specimen, at a comparable resolution as the histology. This  
10 technology may be used as an adjunct to plan pathological dissection, or as a replacement for  
11 specimen assessment in future research and clinical applications [4]. The digital nature of the  
12 information lends itself to storage in a virtual repository which would be particularly useful should new  
13 clinical information be revealed and reassessment required at a later date.  
14  
15  
16  
17  
18  
19

## 20 **References:**

- 21 1. Shelmerdine SC, Simcock IC, Hutchinson JC et al. 3D printing from microfocus computed  
22 tomography (micro-CT) in human specimens: education and future implications. *Br J Radiol.* 2018  
23 Jul;91(1088):20180306.
- 24 2. Hewitt RJ, Butler CR, Maughan EF, Elliott MJ. Congenital tracheobronchial stenosis. *Semin Pediatr*  
25 *Surg.* 2016 Jun; 25(3): 144-9.
- 26 3. Butler CR, Speggorin S, Rijnbert FM et al. Outcomes of slide tracheoplasty in 101 children: a 17  
27 year single-center experience. *J Thorac Cardiovasc Surg.* 2014 Jun;147(6):1783-9  
28  
29
- 30 4. Jones MG, Fabre A, Schneider P et al. Three-dimensional characterization of fibroblast foci in  
31 idiopathic pulmonary fibrosis. *JCI Insight.* 2016 Apr 21;1(5).pii:e68375  
32  
33  
34  
35  
36  
37  
38  
39

## 40 **Figure Captions:**

### 41 **Figure 1:**

42 Antemortem CT Thorax obtained one month prior to death. (a) A coronal 5mm minimum intensity  
43 projection (miniP) image, viewed on lung windows, demonstrates the tight tracheal stenosis  
44 immediately distal to the endotracheal tube (red square bracket). Axial CT sections obtained (b)  
45 above, (c) at the level of the stenosis and (d) inferior to the stenosis show the relative narrowing of the  
46 trachea in relation to the intubated and non-stenosed sections (arrows).  
47  
48  
49  
50  
51  
52

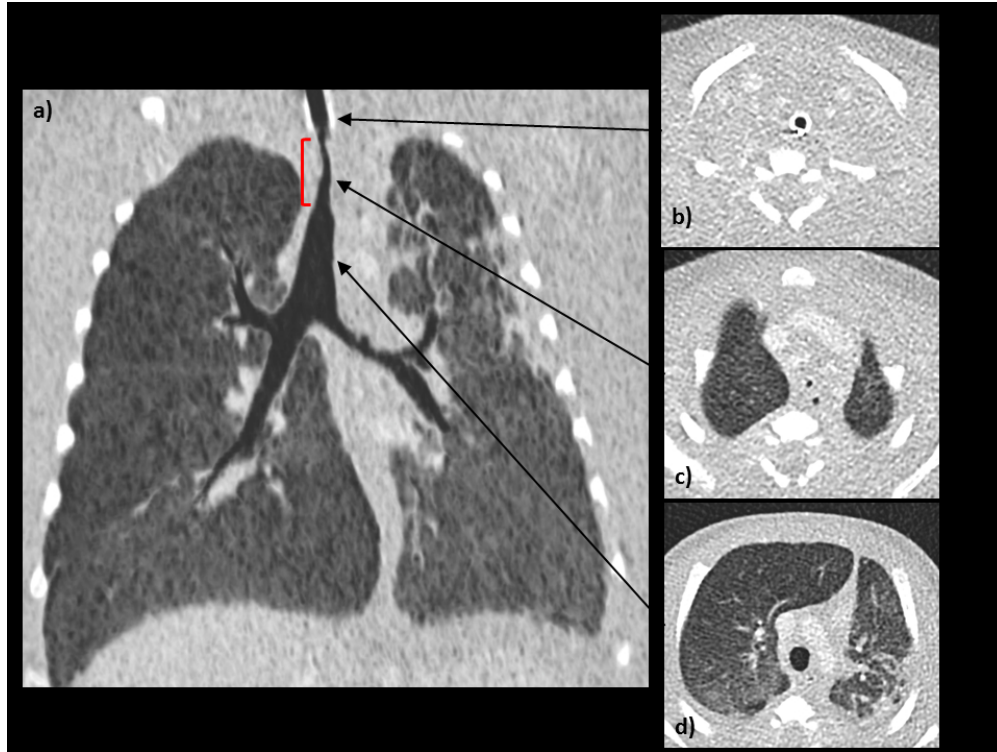### 53 **Figure 2:**

54 Postmortem (a) coronal and (b) sagittal micro-CT images, at 28 micron (0.028mm) resolution of the  
55 excised trachea reveals a short segment, tight tracheal stenosis (red square bracket). Comparative  
56 axial sections through the trachea at the level of stenosis (white arrow) at both (c) micro-CT imaging  
57 and (d) histopathological examination (Alcian blue and Periodic acid-Schiff (PAS) staining) show  
58 fibrosis of the tracheal wall and loss of mucous glands (left column images). The histological and  
59  
60

1  
2  
3 matched micro-CT section images (right column) show cartilage (violet structure on histology, dark  
4 grey on micro-CT) encircling the majority of the tracheal circumference.  
5  
6

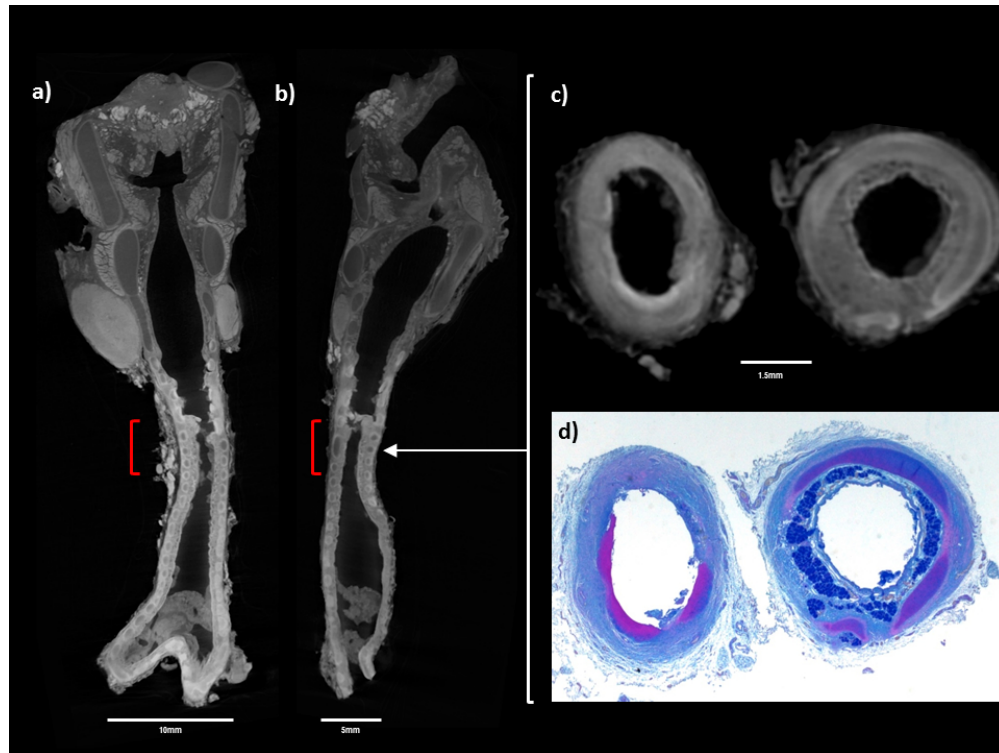
7  
8 **Footnotes:**

- 9
- 10 • Contributors: SCS and OJA prepared the final copy of the manuscript. SCS performed the  
11 micro-CT imaging. SCS, OJA AD interpreted the antemortem CT and postmortem micro-CT  
12 findings. MTA performed the autopsy. SCS and MTA collated the appropriate figures for  
13 inclusion. NM was involved in patient management and obtaining parental consent. All  
14 authors have read and approved the final manuscript.  
15  
16
  - 17 • Funding: SCS is supported by a RCUK/ UKRI Innovation Fellowship and Medical Research  
18 Council (MRC) Clinical Research Training Fellowship. This award is jointly funded by the  
19 Royal College of Radiologists (RCR). OJA is supported by a National Institute for Health  
20 Research (NIHR) Clinician Scientist Fellowship Award.  
21  
22
  - 23 • Competing interests: None declared.  
24  
25
  - 26 • Patient consent: Obtained.  
27  
28  
29  
30  
31  
32  
33  
34  
35  
36  
37  
38  
39  
40  
41  
42  
43  
44  
45  
46  
47  
48  
49  
50  
51  
52  
53  
54  
55  
56  
57  
58  
59  
60



Antemortem CT Thorax obtained one month prior to death. (a) A coronal 5mm minimum intensity projection (miniP) image, viewed on lung windows, demonstrates the tight tracheal stenosis immediately distal to the endotracheal tube (red square bracket). Axial CT sections obtained (b) above, (c) at the level of the stenosis and (d) inferior to the stenosis show the relative narrowing of the trachea in relation to the intubated and non-stenosed sections (arrows).

254x190mm (96 x 96 DPI)



Postmortem (a) coronal and (b) sagittal micro-CT images, at 28 micron (0.028mm) resolution of the excised trachea reveals a short segment, tight tracheal stenosis (red square bracket). Comparative axial sections through the trachea at the level of stenosis (white arrow) at both (c) micro-CT imaging and (d) histopathological examination (Alcian blue and Periodic acid-Schiff (PAS) staining) show fibrosis of the tracheal wall and loss of mucous glands (left column images). The histological and matched micro-CT section images (right column) show cartilage (violet structure on histology, dark grey on micro-CT) encircling the majority of the tracheal circumference.

81x60mm (300 x 300 DPI)